



# ISUOG Basic Training

## The 6-Step Approach

# Learning objectives

At the end of the lecture you will be able to explain how to assess:

- Fetal lie
- Placental localisation
- Amniotic fluid volume (AFV)

# Key questions

What sequences of probe movements are required to assess:

1. Fetal lie and presentation?
2. The number of fetuses?
3. Placental site?
4. Amniotic fluid volume?

# Obstetric ultrasound

## Inherently difficult

- Operator dependent modality
- Complex fetal organ anatomy
- Fetal movements
- Shadowing of target anatomical regions
- Maternal body habitus

# Simplification & standardisation

## Enhances training

- Minimises ultrasound steps
- Introduces consistency in image acquisition & interpretation
- Allows for efficient examination
- Shortens learning curve
- Provides path to automation

# Standardized Six-Step Approach to the Performance of the Focused Basic Obstetric Ultrasound Examination

Alfred Abuhamad, MD<sup>1</sup> Yili Zhao, MD<sup>1</sup> Sharon Abuhamad, RDMS<sup>1</sup> Elena Sinkovskaya, MD, PhD<sup>1</sup>  
Rashmi Rao, MD<sup>2</sup> Camille Kanaan, MD<sup>1</sup> Lawrence Platt, MD<sup>2,3</sup>

- Determination of Fetal Presentation & Lie
- Detection of Fetal Cardiac Activity
- Identification of Number of Fetuses in Uterus
- Determination of Location & Position of Placenta
- Estimation of Amniotic Fluid
- Fetal Biometric Measurements

Am J Perinatol. 2016 Jan, 33(1):90-8

## ISUOG Education Committee recommendations for basic training in obstetric and gynecological ultrasound

**Table 1** Information to be obtained at most basic obstetric ultrasound scans

---

*General checklist for basic obstetric ultrasound scan*

---

Fetal viability and fetal movements

Demonstration of presence of a singleton or multiple pregnancy

Assessment of gestational age and comparison of biometric values with gestational age

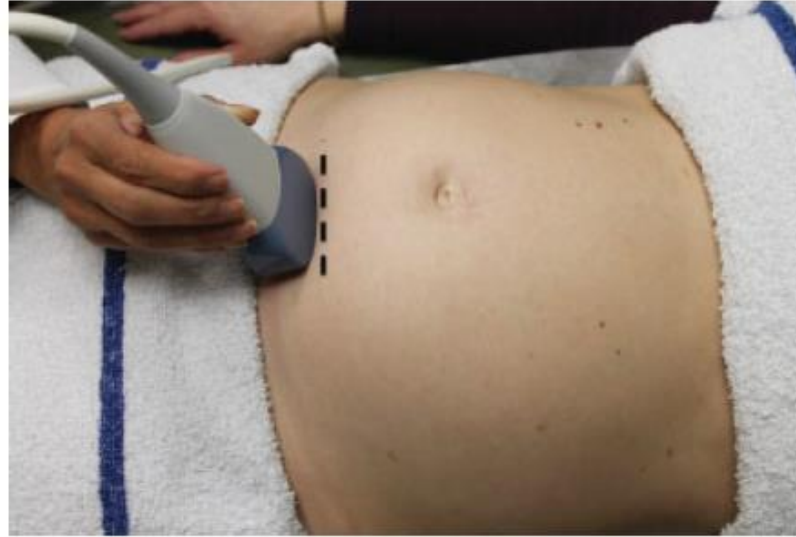Assessment of fetal size by recording biometric measurements

Descriptive evaluation of amount of amniotic fluid

Evaluation of placental appearance and location

Fetal lie

# Step 1: Fetal presentation & lie

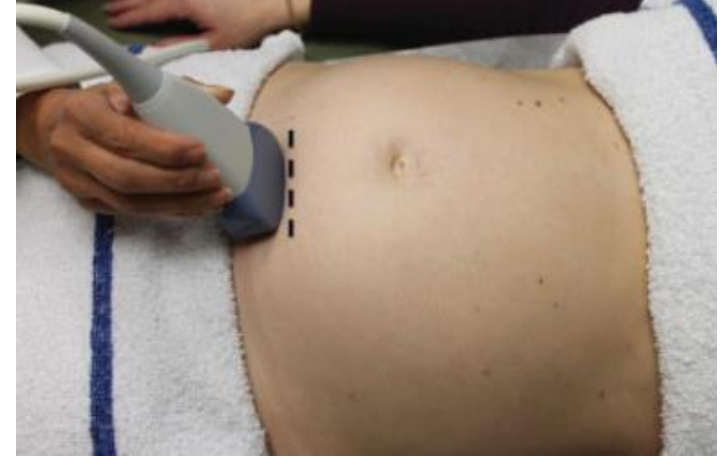
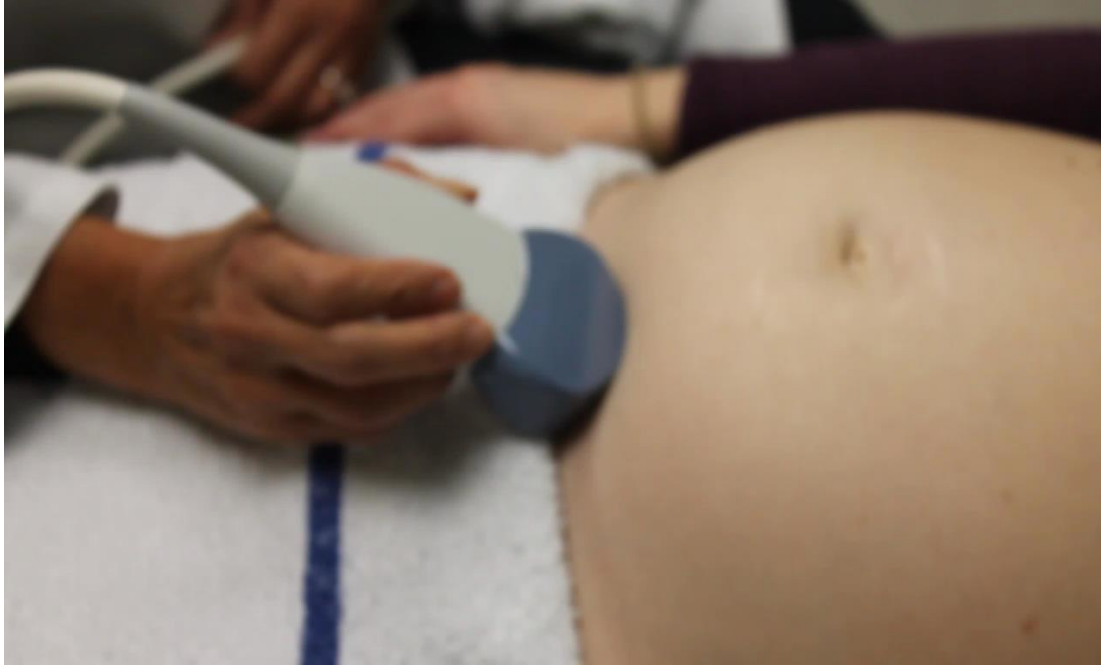
**Fig. 1** Initial transducer placement for determining fetal presentation (step 1). Note that the transducer was placed transversely in the lower abdomen just above the symphysis pubis. This picture was taken from the patient's left side. The dotted line represents the initial position and orientation of the probe.

Am J Perinatol. 2016 Jan, 33(1):90-8

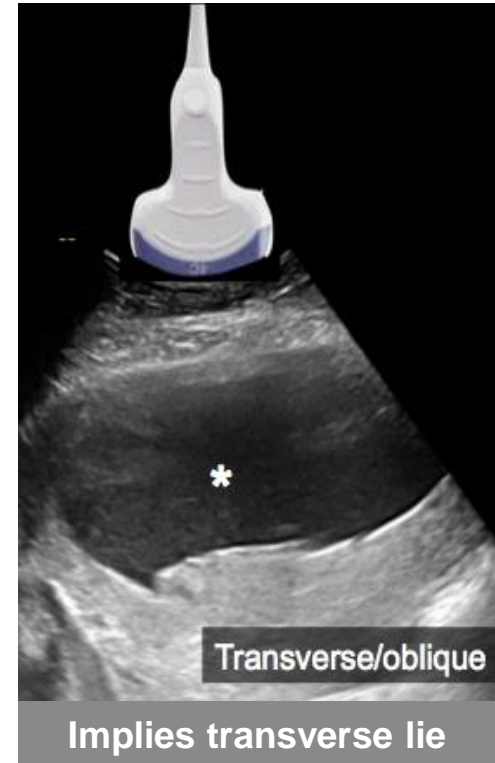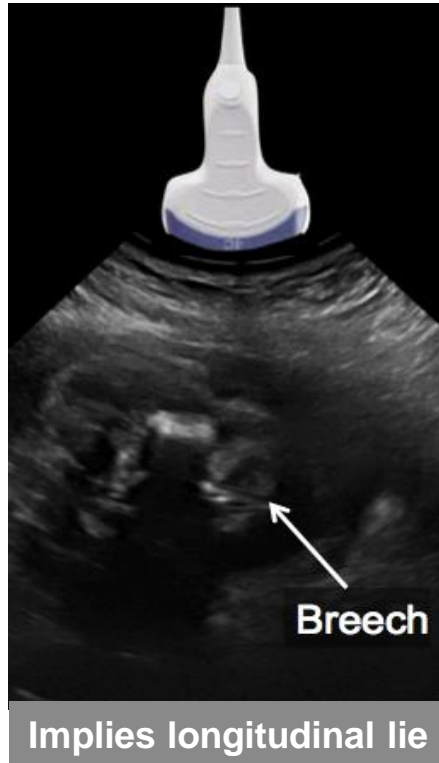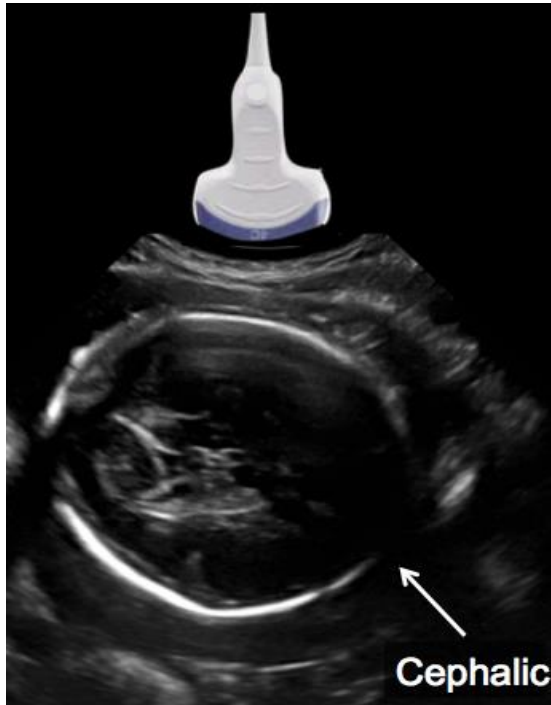


# Step 1: Fetal presentation & lie



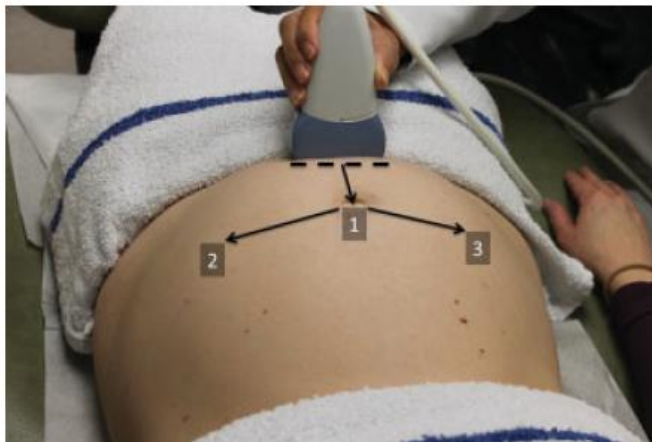Am J Perinatol. 2016 Jan, 33(1):90-8

# Step 1: Fetal presentation & lie



Am J Perinatol. 2016 Jan, 33(1): 90-8

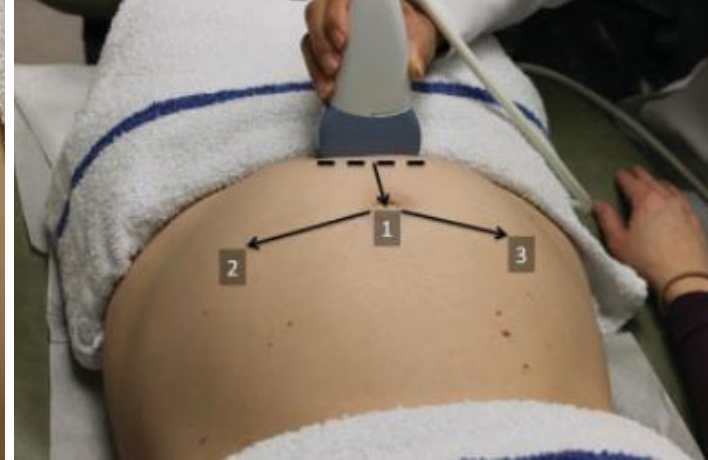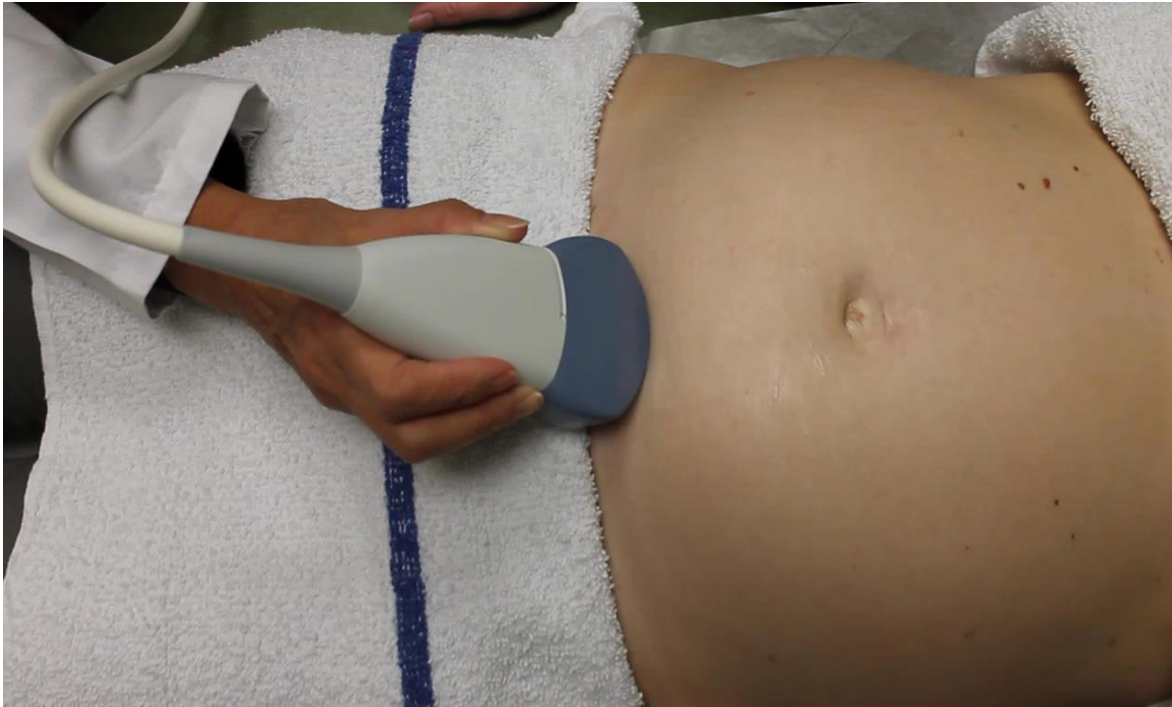# Step 2: Fetal cardiac activity



**Fig. 2** Detection of fetal cardiac activity (step 2): The transducer was placed transversely in the lower abdomen just above the symphysis pubis, and was moved in the midabdomen toward the umbilicus while maintaining the transverse orientation of the ultrasound transducer. If fetal cardiac activity was not seen following this initial step, the transducer was then moved from the umbilicus to the left and/or the right lateral side of the abdomen while maintaining the transverse orientation. The dotted line represents the initial position and orientation of the probe.

Am J Perinatol. 2016 Jan, 33(1):90-8

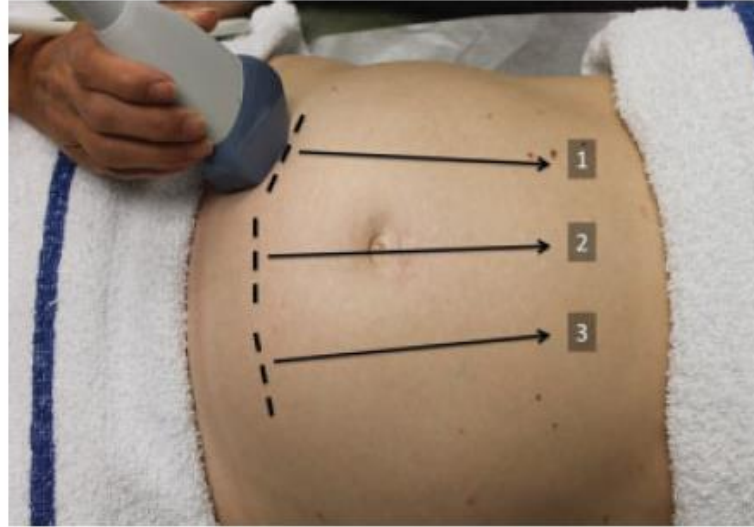
# Step 2: Fetal cardiac activity



Abuhamad et al. American Journal of Perinatology, 2015

# Step 3: Number of fetuses

## Part 1

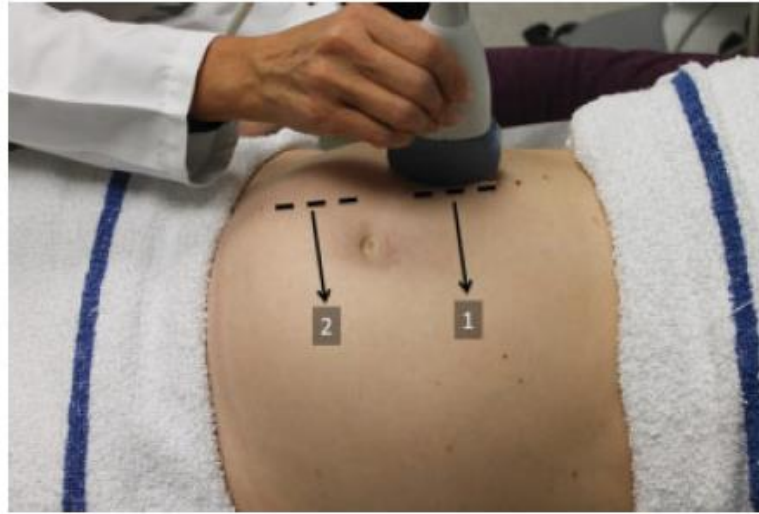


**Fig. 3** Transverse transducer movement for determining number of fetuses in uterine cavity (step 3 [part 1]). Note that the uterine cavity was scanned from the symphysis toward the patient's head along tracks 1, 2, and 3, while maintaining the perpendicular orientation of the transducer to the floor. The dotted line represents the initial position and orientation of the probe for each maneuver.

Am J Perinatol. 2016 Jan;33(1):90-8

# Step 3: Number of fetuses

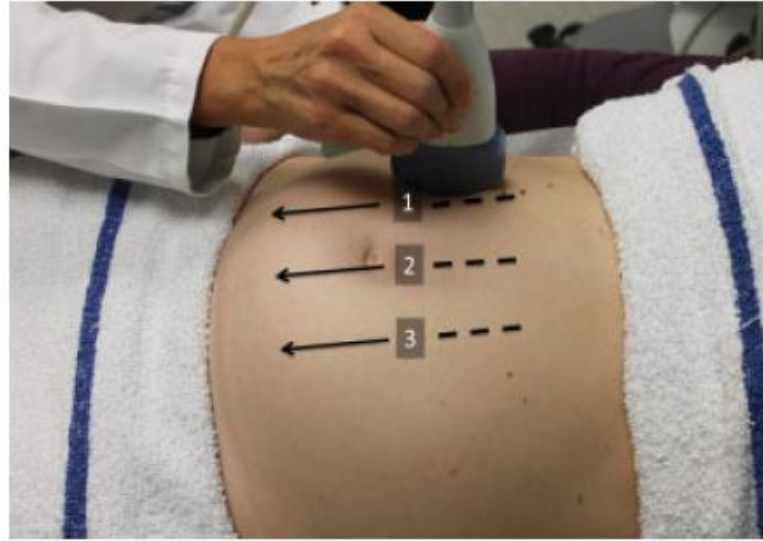
## Part 2



**Fig. 4** Initial sagittal transducer placement for determining number of fetuses in uterine cavity (step 3 [part 2]). Note the sagittal placement in the right upper abdomen and the perpendicular orientation of the transducer to the floor. The transducer was moved from right to left along tracks 1 and 2, while maintaining the perpendicular orientation of the transducer to the floor. The dotted line represents the initial position and orientation of the probe for each maneuver.

Am J Perinatol. 2016 Jan;33(1):90-8

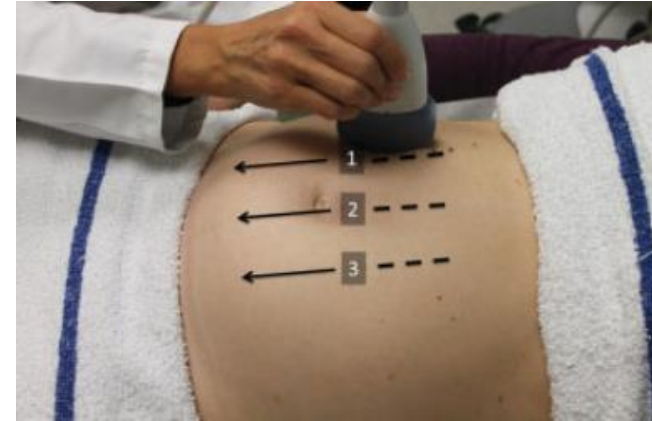
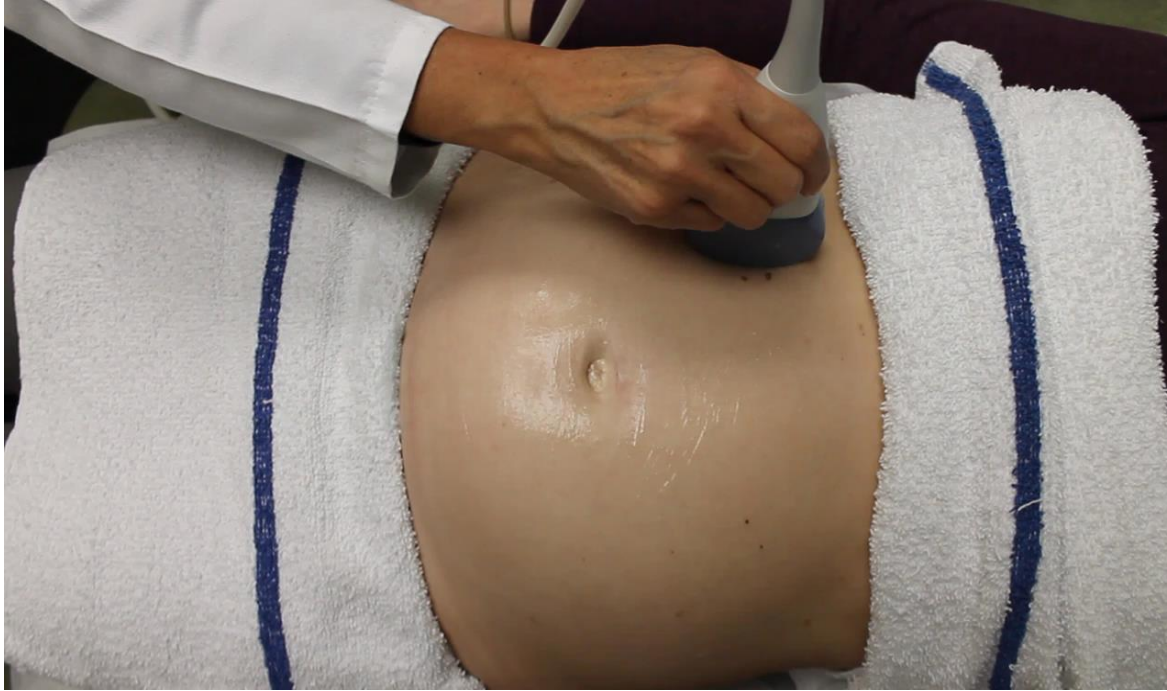# Step 4: Location & position of placenta



**Fig. 5** Sagittal transducer movement for determining placental localization (step 4). Note that the uterine cavity was scanned from the fundus toward the symphysis along tracks 1, 2, and 3 while maintaining the transducer perpendicular to the floor. The dotted line represents the initial position and orientation of the probe for each maneuver.

Am J Perinatol. 2016 Jan;33(1):90-8

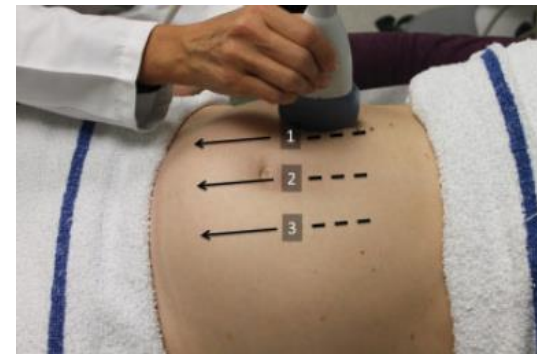
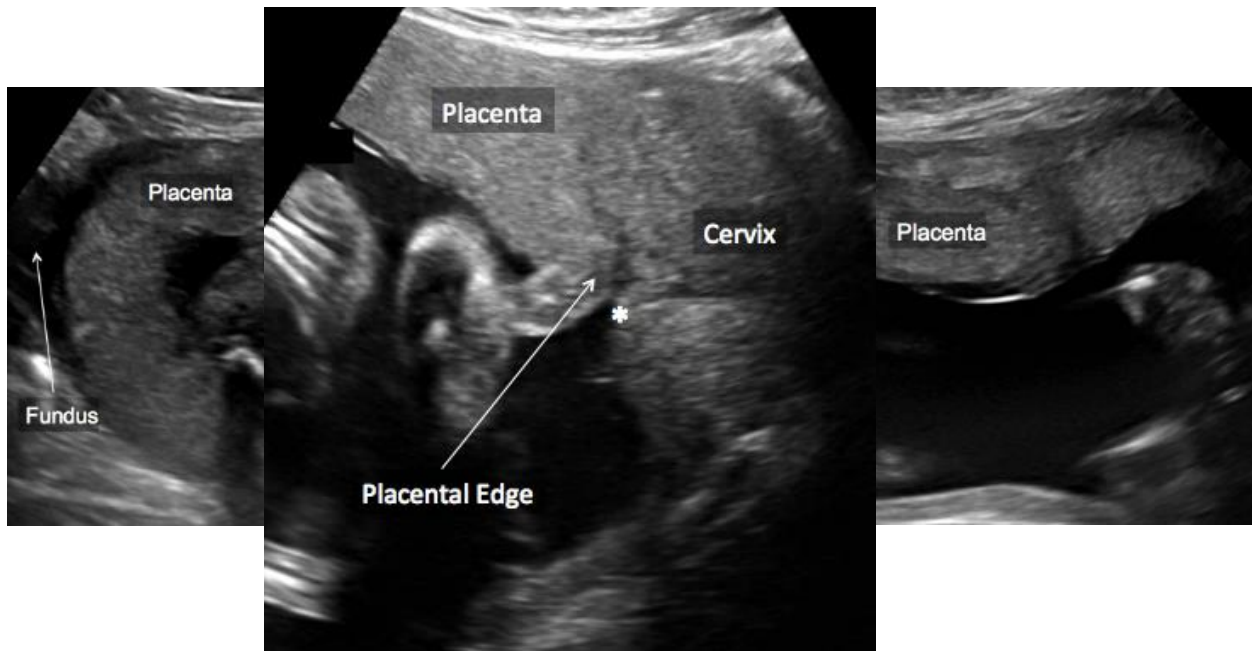
# Step 4: Location & position of placenta



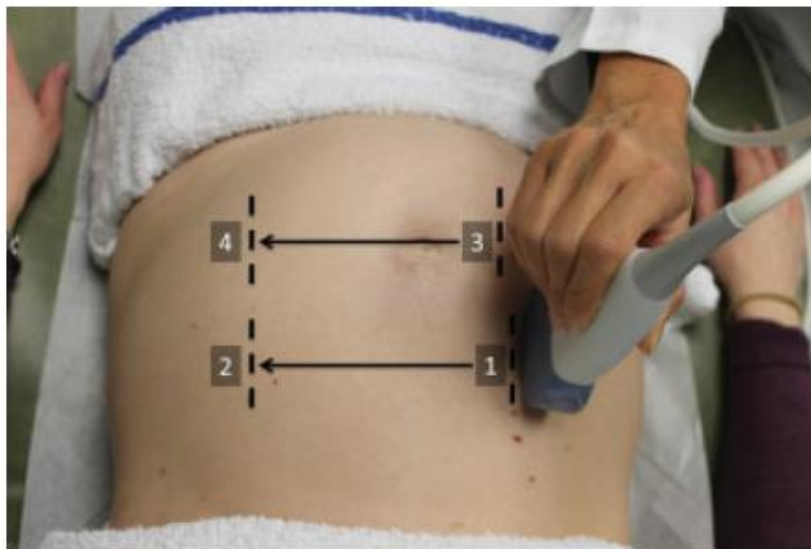Abuhamad et al. American Journal of Perinatology, 2015



# Step 4: Location & position of placenta



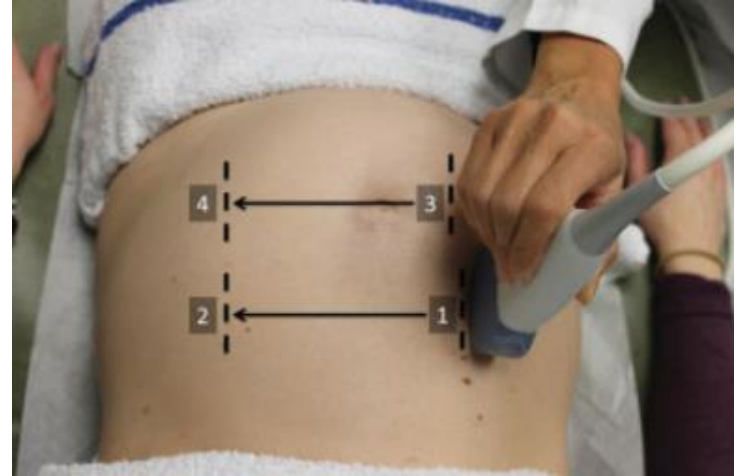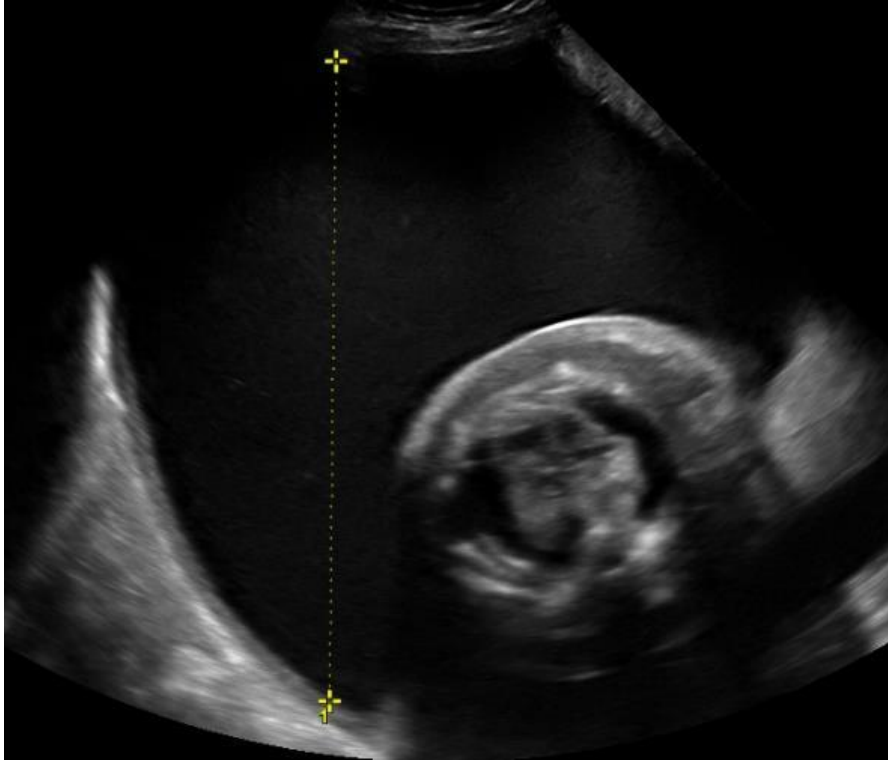
# Step 5: Estimation of amniotic fluid



**Fig. 6** Sagittal transducer movement for amniotic fluid assessment (step 5). Note that the uterine cavity was scanned from right lateral to left lateral along tracks 1 to 2 and 3 to 4, while maintaining the transducer in sagittal orientation and perpendicular to the floor. The dotted line represents the position and orientation of the probe while scanning the four different quadrants.

Am J Perinatol. 2016 Jan, 33(1):90-8

# Step 5: Amniotic fluid volume



Am J Perinatol. 2016 Jan, 33(1):90-8

# Step 6: Fetal biometric measurements

- Biparietal Diameter (BPD)
- Head Circumference (HC)
- Abdominal Circumference (AC)
- Femur Length (FL)

Am J Perinatol. 2016 Jan;33(1):90-8

# Standardized Six-Step Approach to the Performance of the Focused Basic Obstetric Ultrasound Examination

Alfred Abuhamad, MD<sup>1</sup> Yili Zhao, MD<sup>1</sup> Sharon Abuhamad, RDMS<sup>1</sup> Elena Sinkovskaya, MD, PhD<sup>1</sup>  
Rashmi Rao, MD<sup>2</sup> Camille Kanaan, MD<sup>1</sup> Lawrence Platt, MD<sup>2,3</sup>

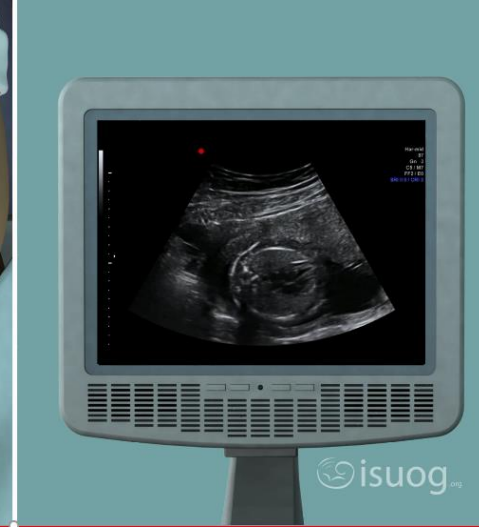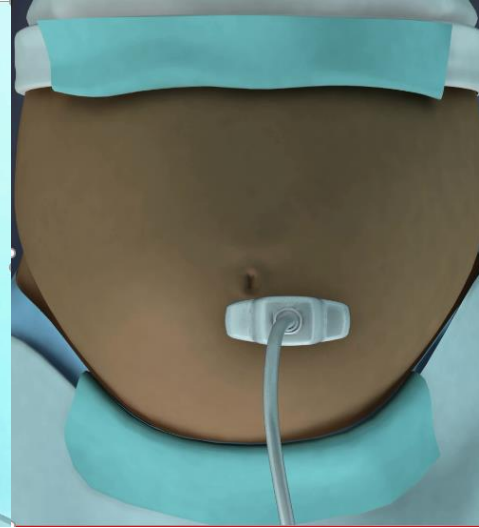
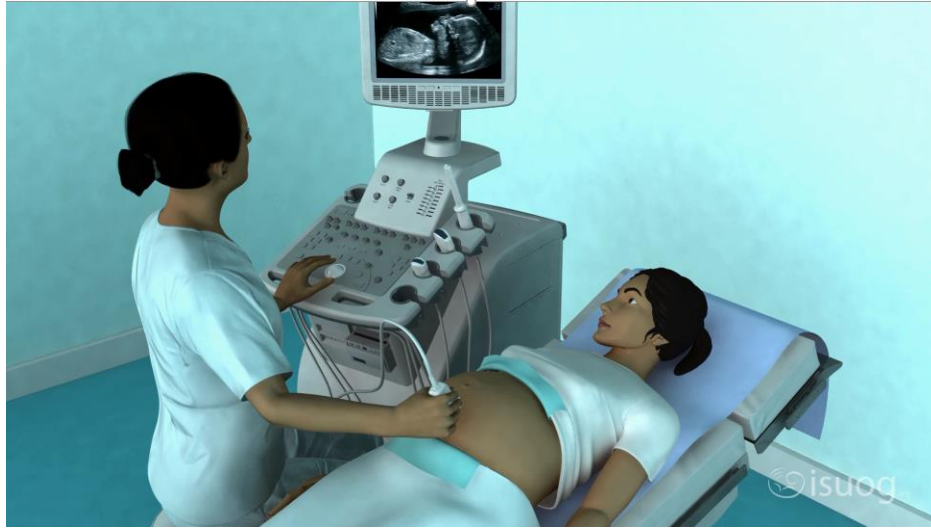
**Table 2** Time (seconds) to complete each step of the standardized six-step approach to the ultrasound examination in the second and third trimester

	Second trimester (N = 100)	Third trimester (N = 100)	p Value
Step 1 (presentation)	15.9 ± 8.7	14.9 ± 4.5	NS
Step 2 (cardiac activity)	19.0 ± 6.8	18.9 ± 7.2	NS
Step 3 (number of fetus[es])	27.4 ± 11.2	30.2 ± 8.5	< 0.05
Step 4 (placental localization)	33.6 ± 14.1	33.3 ± 17.0	NS
Step 5 (amniotic fluid)	41.7 ± 17.1	38.3 ± 13.3	< 0.05
Step 6 (biometry)	130.6 ± 45.7	154.2 ± 57.5	< 0.001
Total	268.2 ± 64.4	292.8 ± 65.2	< 0.001

Abbreviation: NS, not significant.

Note: Time was presented as mean ± SD. Independent t-test was performed between two groups.

# The Basic Steps of an Obstetric Ultrasound



[Video link](#)

# Key points

1. Ultrasound examination in the 2<sup>nd</sup> & 3<sup>rd</sup> trimester of pregnancy should be approached systematically
2. The sequence is fetal presentation, heartbeat, number of fetuses, placental position, amniotic fluid estimation, biometry
3. Standardisation enhances confidence in trainees



ISUOG Basic Training by [ISUOG](https://www.isuog.org) is licensed under a [Creative Commons Attribution-NonCommercial-NoDerivatives 4.0 International License](https://creativecommons.org/licenses/by-nc-nd/4.0/).

Based on a work at <https://www.isuog.org/education/basic-training.html>.

Permissions beyond the scope of this license may be available at <https://www.isuog.org/>