



27th World Congress on Ultrasound in Obstetrics and Gynecology

16 – 19 September 2017, Vienna, Austria

Final Program

Up to 29 CME credits



Join the Congress conversation
#ISUOG2017

 **isuog**.org


Welcome to ISUOG!

As a Congress delegate, you are also an ISUOG member from now until December 2018. Take a moment to visit us at the ISUOG lounge to find out more about the exciting opportunities available to you as an ISUOG member during the Congress and throughout the year.



Upgrade your membership at the Registration desk or on our website to include a subscription to our Journal *Ultrasound in Obstetrics and Gynecology*.

Online learning

- 500+ web lectures and webcasts from ISUOG education courses
- CME platform for continuing education; earn CME credits online
- 1500+ World Congress presentations via ISUOG On Demand
-  **visuog**: a visual encyclopedia for ultrasound in obstetrics and gynecology

Reduced fees to ISUOG events

- 28th World Congress in Singapore, 20-24 October 2018
- International Symposium in Athens, Greece, 20-22 April 2018
- ISUOG's intensive education courses

Regional education

- Opportunities to participate in:
 - ISUOG approved courses
 - satellite education
 - Outreach projects

97.6%
of Members
surveyed in
2016 would
**recommend
ISUOG!**



Be part of our growing community and
join the conversation **#ISUOG2017**



Contents

Welcome to Vienna	4
General Information	
Venue floor plans	6
Opening times	7
General information	8-9
Social program	10
Travel grant winners	11
Supplement your learning	12-13
Invited speakers	14
Speaker declarations	15
Award winners	16
Keynote speakers	17-19
Certificate in Fetal MRI	21
Session types explained	22
Orientation	
Program at a glance	24-27
Masterclasses	28
Short oral presentations	29
Posters	30
Hubs at a glance	32-33
Electronic posters	34
Friday	
Pre-Congress courses	37-39
Saturday	
Program	43-45
Sunday	
Program	47-55
Hubs	56-57
Short oral presentations	58-64
Poster discussions	65-70
Monday	
Program	71-79
Hubs	80-81
Short oral presentations	82-89
Poster discussions	90-96

Tuesday	
Program	99-105
Hubs	106-107
Short oral presentations	108-111
Poster discussions	112-115

Electronic Posters	
Electronic Poster Listing	117-141

Exhibition	
Exhibition floor plan and listing	144-145
Exhibitor profiles	146-154
Hospitality and education suites	156-157
Satellite symposia	158
Industry acknowledgements	159

ISUOG meetings	
ISUOG Board and Committee meetings	160

ISUOG 2017 Organising Committees

Congress Co-Chairs

C. Brezinka, *Austria*
D. Prayer, *Austria*

Local Organising Committee

E. Hafner, *Baden*
T. Helbich, *Vienna*
S. Helmy, *Vienna*
G. Hudelist, *Vienna*
E. Krampfl-Bettelheim, *Vienna*
H. Steiner, *Salzburg*

Advisory Board

W. Arzt, *Linz*
A. Berger, *Innsbruck*
D. Bettelheim, *Vienna*
P. Calda, *Czech Republic*
R. Chaoui, *Germany*
M. Häusler, *Graz*
K. Hecher, *Germany*
K.O. Kagan, *Germany*
G. Kasprian, *Vienna*
P. Klaritsch, *Graz*
B. Perlt, *Graz*
G. Rizzo, *Italy*
N. Tul, *Slovenia*
G. Tulzer, *Linz*
B. Tutschek, *Switzerland*
C. Wolmuth, *Salzburg*

ISUOG President

J.A. Copel, *USA*

Honorary Secretary

A. Papageorgiou, *UK*

ISUOG Scientific Committee

D. Timmerman (Chair), *Belgium*
A. Papageorgiou, *UK*
T. Bourne, *UK*
C. Brezinka, *Austria*
G. Condous, *Australia*
E.A. Hernandez-Andrade, *USA*
J. Hyett, *Australia*
C. Lees, *UK*
D. Prayer, *Austria*
L. Salomon, *France*

ISUOG Secretariat, UK

S. Johnson, Chief Executive Officer
G. Saunders, Event Manager
I. Hanley, Event Assistant
W. Holloway, Operations Manager

Welcome to Vienna

On behalf of ISUOG, its Board of Trustees and the Congress Organising Committees, we are extremely pleased to welcome you to Vienna, for the 27th World Congress on Ultrasound in Obstetrics and Gynecology.

ISUOG's Congress is known for its outstanding scientific content and this year will be no exception. We received a record number of abstracts on cutting edge research and with a great diversity of content which will make for a lively program. We are also joined by world experts who will present key note lectures, masterclasses and invited talks. As usual we have a wide variety of different formats such as hands-on training, poster Hub discussions, special interest groups and much more which we encourage you to attend.

This is a unique event in the scientific calendar bringing clinicians from 89 countries to one place for five days, therefore please make the most of this wonderful networking opportunity and attend the social program, lunches and Hubs. This year we have set out two meeting points at the business lounge and the ISUOG stand. Please use these to help organise your meetings and connect with people using the 'Chat' function on the Congress app.

During your stay with us in Vienna, we recommend you explore and enjoy the city. Historically known for its medieval and baroque architecture, opera and fine arts, Vienna is home to a multitude of palaces, gothic churches, opera houses and galleries. With its fast subways and trams you can quickly get to all the interesting places in the city centre. Close to the ACV venue, you have the Danube and the popular recreation area known as the Donauinsel and Copa Cagrana. If you bring your swimsuit you can swim in Europe's longest river!

Thank you again for joining us for the 27th year of the Congress. Your support as a delegate, member, speaker or industry partner is what makes the Congress possible. We hope you thoroughly enjoy your time in Vienna.



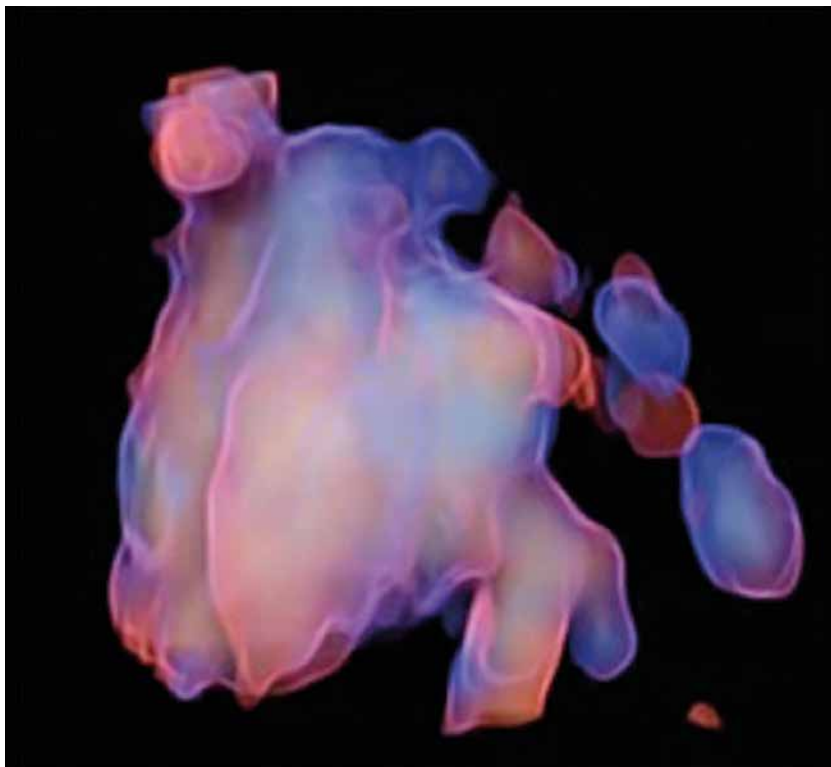
Christoph Brezinka
Congress Chair



Daniela Prayer
Congress Chair

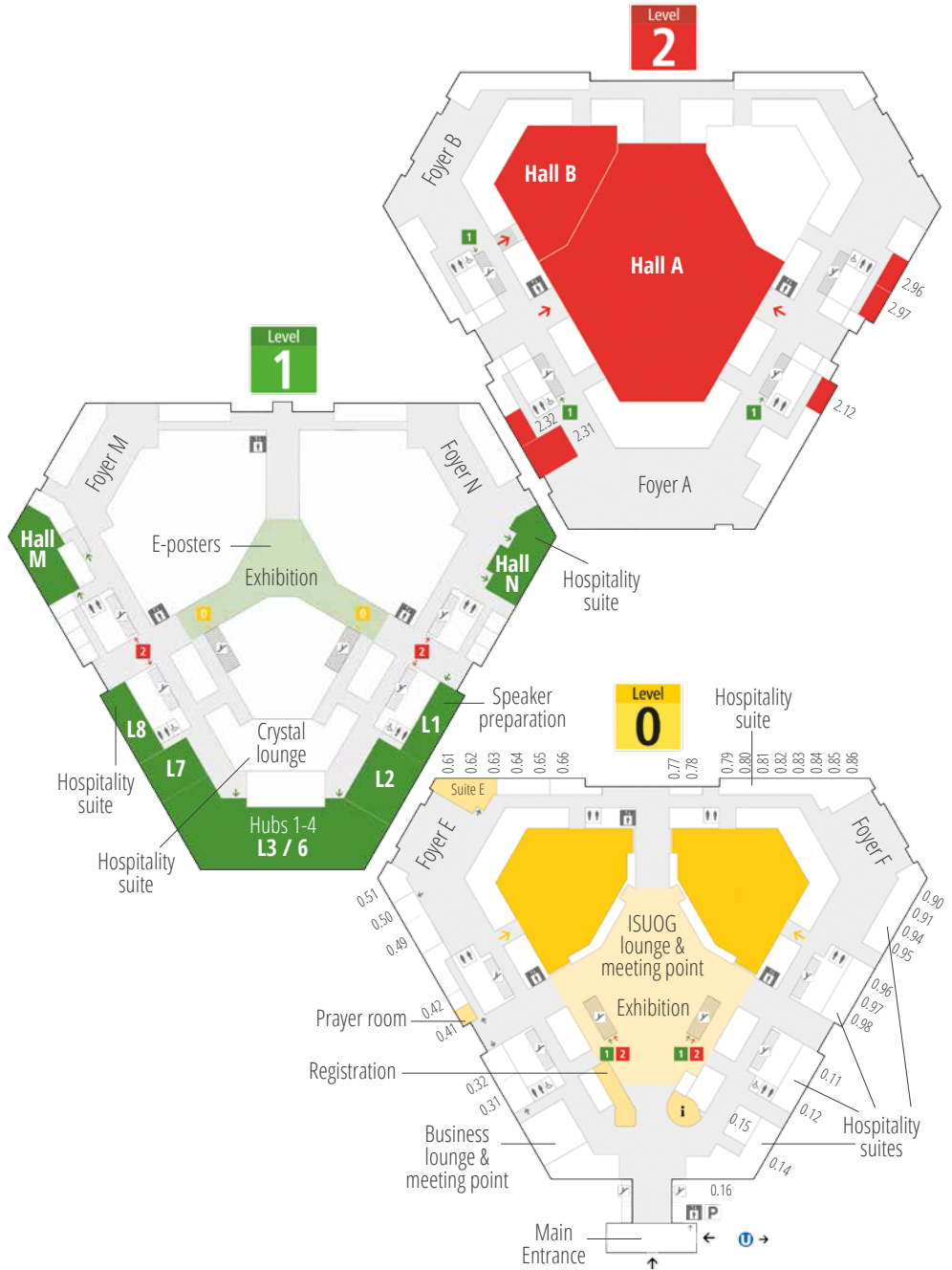
GENERAL INFORMATION

ISUOG 2017



Normal fetal heart with HDlive Flow silhouette mode - Ito M, AboEllail MAM, Yamamoto K, Kanenishi K, Tanaka H, Masaoka H, Hata T. HDlive Flow silhouette mode and spatiotemporal image correlation for diagnosing congenital heart disease. *Ultrasound Obstet Gynecol* 2017; 50: 411–415

Venue floor plans



Opening times

Registration

Friday 15 September	07:00	-	18:00
Saturday 16 September	07:00	-	18:00
Sunday 17 September	07:00	-	17:00
Monday 18 September	07:00	-	17:00
Tuesday 19 September	07:00	-	16:20

The registration desk is located in the main lobby.

Exhibition

Saturday 16 September	09:00	-	19:30
Sunday 17 September	09:00	-	16:00
Monday 18 September	09:00	-	16:00
Tuesday 19 September	09:00	-	13:40

The exhibition is located in the main lobby and on the mezzanine.

Speaker preparation room L1

Friday 15 September	07:00	-	17:00
Saturday 16 September	07:00	-	17:00
Sunday 17 September	07:00	-	17:00
Monday 18 September	07:00	-	17:00
Tuesday 19 September	07:00	-	15:00

The speaker preparation room is located in L1, on the first floor. Poster presenters who have submitted your presentation, you do not need to go to the speaker preparation room; all other oral communication and invited speakers must check-in. If you need to upload or edit a presentation, please make your way to this room as early as possible on the day before presenting, and no later than four hours prior to your start time. Please note there will be no laptop plug/converter in the lecture halls except by prior arrangement.

General information



AGM

All ISUOG members are invited to attend the Annual General Meeting. This takes place on Saturday 16th September in Session Hall A, from 09:50- 10:35.



App

Stay up-to-date with what's going on at the Congress by downloading the ISUOG Congress app. Go to the App Store or Google play and type in 'ISUOG 2017'. You'll be able to create a personalised agenda, engage with other attendees, read all the abstracts, post on social media as well as have your say by rating, voting and filling out our surveys.



Austrian award

This year the Society of Gynaecology and Obstetrics will award €500 to the best presentation presented by a speaker from an Austrian Institution. The winner will be announced at the Closing ceremony on Tuesday 19 September.



Cash machines

There is a cash machine located at the entrance to the ACV building, near the glass doors to registration and the exhibition. Most banks in Vienna are open from Monday to Friday from 08:00 to 12:30 and from 13:30 to 15:00, and until 17:30 on Thursdays. In the city centre, almost all banks are open over lunchtime.



Catering

Tea, coffee and light lunches will be served in the exhibition hall (ground floor foyer and the mezzanine/first floor level) from Saturday morning until Tuesday lunchtime, excluding exhibition build and breakdown times. All breaks are included for all registered personnel.



Certificates of attendance

To receive your certificate of attendance you will need to complete a Congress evaluation form which will be emailed to your registered email address. If you have any questions, please ask at the registration desk.



CME

ISUOG is accredited by the European Accreditation Council for Continuing Medical Education (EACCME) to provide the following CME activity for medical specialists. The EACCME is an institution of the European Union of Medical Specialists (UEMS).

The 27th World Congress on Ultrasound in Obstetrics and Gynecology is designated for a maximum of (or 'for up to') 36 hours of European external CME credits, including pre-Congress courses. Your badge will be scanned at session hall entrances for CME accreditation. Each medical specialist should claim only those hours of credit that they actually spent in educational activity.

Through an agreement between the European Union of Medical Specialists and the American Medical Association, physicians may convert EACCME credits to an equivalent number of AMA PRA Category 1 Credits™. Information on the process to convert EACCME credit to AMA credit can be found at www.ama-assn.org/go/internationalcme.



Co-authors

Please note that only the presenting author is listed in the event Program. The names of the co-authors can be found on the ISUOG app, the online On Demand stations and in the abstract book.



Disclaimer

Best endeavours will be made to present the program as printed. However ISUOG and its agents reserve the right to alter or cancel, without prior notice, any of the arrangements, timetables, plans or other items relating directly or indirectly to the Congress for any reason beyond its reasonable control. ISUOG and its agents are not liable for any loss or inconvenience caused as a result of such alteration.



Electronic Posters (EPs)

All Electronic Posters (EPs) and recorded Congress talks will be available at the ISUOG On Demand stations which are located at the ISUOG Lounge.

**First aid**

Should you require assistance during the Congress hours, please contact the registration desk where an ISUOG member of staff will be able to assist you.

**Future meetings**

All literature regarding future meetings which may be of interest to delegates will be displayed in the exhibition area.

**Lost property**

Please hand any lost property to the staff at the registration desk where it will be made available for collection.

**Mobile phones**

Throughout all of the Congress lectures, workshops and activities, ISUOG request that all mobile phones are kept on silent. Please also ensure that screen resolution remains low to prevent disturbing any other delegates and speakers.

**Name badges**

Please wear your name badge at all times; you will need this to gain admission to the sessions or exhibition area. Please note, our staff members are instructed not to permit entry without your badge, so please understand if you are asked to return to the registration desk.



Full delegates



ISUOG Board



Faculty

Exhibitors (*access to exhibition areas only*)

Staff

Day delegate (*with day printed*)Accompanying persons
(*no access to scientific sessions*)**Official language**

The official language of the Congress is English.

**Parking**

Parking is available at the venue. Please use the Austria Center Vienna's parking garages. Information regarding access and fees can be found online: www.acv.at/teilnehmen/anreise-und-verkehr/travelling-by-car.html

**Prayer room**

The prayer room is located in 0.41, on the ground floor, along the left hand side of the building.

**Recordings/duplications**

All sessions are available to delegates and ISUOG members during and after the Congress, through the ISUOG On Demand web portal*. Other photography, audio taping, video recording, digital taping or any other form of duplication is strictly prohibited in the session halls and poster areas, except with the express consent, in advance, of ISUOG staff and the speakers involved.

**Smoking policy**

Smoking is not permitted in the building.

**Speaker preparation room**

The Speaker preparation room is located in L1, on the first floor.

**Star rating**

In the Congress app you will be able to give each session you attend a star rating. Our session Chairs will remind you throughout the event.

**Tickets**

If you have purchased a ticket for the Congress party or if you have bought an additional Opening ceremony and Welcome drinks pass, tickets will be given to you when you collect your badge from Registration. If you lose your ticket for the Congress party please inform the ISUOG Registration. Tickets are selling fast for the Congress party so please check at Registration if there are any available.

**WiFi**

ISUOG will provide complimentary Wi-Fi in the venue for delegates' usage. Please find the ACV's network on your phone called 'ACV'. Then open up a web page and click 'accept' and then 'continue'. There is no password needed.

*Please note that Hubs will not be recorded.

Social program

Saturday 16 September - 17:30-19:30

Opening ceremony and welcome drinks - ACV

After our keynote plenary speakers, attendees will be treated to a performance of traditional Austrian singing by the Mozart Boys. The evening will continue with more classical music, drinks and snacks served in the exhibition. Take this opportunity to network with fellow delegates from over 80 countries.

With grateful acknowledgement to our sponsor for this event:

**TOSHIBA
MEDICAL**

Canon
CANON GROUP



Sunday 17 September - 19:00-00:30

Congress party - Rathaus City Hall

This is a unique opportunity to enjoy a three-course dinner at the beautiful opulent City Hall of Vienna. Home to some of the grandest balls in the city, attendees will enjoy live band entertainment throughout the dinner, a photo booth to creatively remember the evening and dancing until late with a professional DJ. Dress code: cocktail. Please enquire at Registration if you wish to attend.



Monday 18 September

Free night!

ISUOG has left this night free for attendees to enjoy the city, meet up with fellow colleagues, join sponsors for organised dinners or simply relax.



Tuesday 19 September - 16:20-17:30

Singapore style leaving drinks - Foyer A Level 2

To say farewell to Vienna and to launch the countdown to Singapore, ISUOG will be hosting Singaporean themed leaving drinks. Take the opportunity to enjoy refreshments before heading home.



Travel grant winners

We would like to congratulate our Travel Grant Award winners and wish them a warm welcome to Vienna.

Alim Swarray-Deen

Alim Swarray-Deen is an Obstetrician-Gynecologist at the Korle Bu Teaching Hospital, Ghana with a Masters in Medical Ultrasound from Imperial College, London. His areas of interest include prenatal diagnosis and fetomaternal medicine, particularly fetal anomalies and obstetric Doppler. Alim has also focused research on fetal middle cerebral artery indices and cerebroplacental ratio.

Amira Ayachi

From Bizerta, Tunisia, Amira Ayachi is a University Assistant in Obstetrics and Gynecology at the Teaching Hospital Bougatfa. She is greatly interested in sonography and fetal imaging, and the impact this has on improving health care in her region. Amira is looking forward to implementing changes in her practice from the research presented at the Congress.

Binod Parmar

Binod Parmar is an experienced clinician from Kathmandu, Nepal. Although coming from Nepal, Binod graduated in medicine from Ukraine and received his masters in Norway. He received training in ultrasonography from Japan and is currently working in the Radiology Department at Patan Academy of Health Science (Nepal) as the Coordinator of the ultrasound unit and has special interest in Doppler ultrasound in SGA/FGR fetus.

Celestin Mbonyizina

Joining us from Rwanda, Celestin Mbonyizina is a young researcher and newly graduated Obstetrician and Gynecologist. Celestin has been interested in imaging throughout his studies, in particular fetal anomalies and multiple pregnancy. He is looking forward to hearing about new research in ultrasound.

Hadijat Raji

Hadijat Raji is an Obstetrician-Gynecologist and a Lecturer at the University of Ilorin, Nigeria. Her main area of interest is fetomaternal medicine. She holds an MSc degree in Prenatal Genetics and Fetal Medicine from University College London and is a facilitator at the ISUOG accredited Benin Fetal Medicine and Diagnostic Ultrasound Workshop.

Mariam Raafat

Mariam Raafat is a Lecturer of Radiology in the Department of Radio-diagnosis at Cairo University. She is also currently working as a Lecturer of Radio-diagnosis in Elkasr Elini Hospital, and is a Radiology Consultant in female imaging, specialising in breast and obstetrics and gynecology imaging.

Apply for a 2018 Congress travel grant

ISUOG is again inviting researchers from underserved regions to apply in 2018 to participate at the Congress in Singapore. Travel, accommodation and registration will be offered to six successful applicants who submit an abstract for the Singapore Congress and meet the eligibility criteria. All applications must be accompanied by a submitted abstract. Abstract submission will open in January 2018.

Full terms, conditions and application criteria are available online at:
www.isuog.org/events/world-congress/travel-grant



ULTRASOUND

in Obstetrics & Gynecology

CME
online

Are you looking for further information on a topic featured at the Congress?

Would you like to gain further CME points? Supplement your learning with UOG articles and earn CME via:

www.isuog.org/worldcongress2017/supplement-your-learning

Fetal growth

Saturday

- **Hall A - 09:00**
Keynote lecture: Small babies, large babies and older mothers: when shall we induce?
- **Hall A - 11:45**
Incidence of stillbirth is increased in familial LQTS: a retrospective study from 8 international centres
- **Hall F - 13:45**
Workshop: New approaches to fetal growth: which should I use?

Sunday

- **Hall A - 07:30**
Masterclass: Screening and prevention of stillbirth: possibilities and pitfalls *G. Smith*
- **Hall A - 09:20**
OP01 Placental and maternal factors in IUGR
- **Hall A - 11:25**
OP06 Fetal growth: anatomy and measurements
- **Hub 1 - 14:35**
P08 Fetal growth

Monday

- **Hall F - 07:30**
Masterclass: Management of fetal growth restriction in practice *E. Gratacós; A. Baschat*
- **Hall A - 09:20**
OP13 Small-for-gestational age
- **Hall A - 13:30**
Workshop: Big mothers, big babies: getting the most from your scan
- **Hub 1 - 14:35**
P20 The prognostic value of growth parameters
- **Hall B - 15:40**
Workshop: Late fetal growth restriction

Tuesday

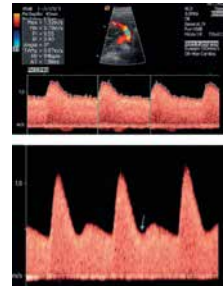
- **Hub 2 - 09:20**
P25 Fetal growth Doppler and hemodynamics

UOG Journal top pick: Severe fetal growth restriction at 26–32 weeks: key messages from the TRUFFLE study

C. L. Bilardo, K. Hecher, G. H. A. Visser, A. T. Papageorgiou, N. Marlow, B. Thilaganathan, C. Lees et al., on behalf of the TRUFFLE Group. Ultrasound Obstet Gynecol 2017; 50: 285–290.

Pre-eclampsia

- **Saturday Hall A - 11:55**
Keynote lecture and top abstracts: Aspirin versus placebo in pregnancies at high-risk of preterm pre-eclampsia: a multicentre, double-blind, placebo-controlled trial
- **Sunday Hall A - 07:30**
Masterclass Screening and prevention of stillbirth: possibilities and pitfalls *G. Smith*
- **Monday Hall B - 10:20**
OP17: Hypertensive disease in pregnancy: screening to diagnosis
- **Tuesday Hall E - 13:30**
Workshop: Pre-eclampsia in 2017
- 4 CME modules online such as 'How important is the evaluation of the placenta?'

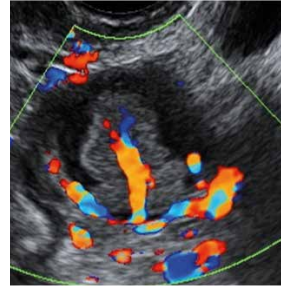

UOG Journal top pick: ASPRE trial: performance of screening for preterm pre-eclampsia

D. L. Rolnik, D. Wright, L. C. Y. Poon, A. Syngelaki, N. O'Gorman, C. De Paco Matalana, R. Akolekar, S. Cicero, D. Janga, M. Singh, F. S. Molina, N. Persico, J. C. Jani, W. Plasencia, G. Papaioannou, K. Tenenbaum-Gawish and K. H. Nicolaides. Ultrasound Obstet Gynecol 2017; DOI: 10.1002/uog.18816.

Imaging in gynecological disease

- **Saturday Hall A - 15:55**
Big multicentre trials and gynecology ultrasound: how research can change clinical practice *D. Timmerman*
- **Sunday Hall F - 10:20**
Workshop: Using ultrasound to help manage oncology patients
- **Sunday Hub 1 - 12:20**
In conversation with *A. Testa*: Diagnosing less common types of ovarian tumor
- **Monday Hall B - 07:30**
Masterclass: Revising IOTA terms and definitions: case examples of how to classify ovarian masses – how I manage non-tubal ectopic pregnancies?
L. Valentin
- **Tuesday Hall - 11:25**
OP31: Using ultrasound to assess pelvic pain and diagnose endometriosis.
- 6 CME modules online such as ‘How can 3D enhance the gynecological ultrasound investigation?’




UOG Journal top pick: Diagnostic accuracy and cost-effectiveness of different strategies to triage women with adnexal masses: a prospective study

E. Piovano, C. Cavallero, L. Fuso, E. Viora, A. Ferrero, G. Gregori, C. Grillo, C. Macchi, G. Mengozzi, M. Mitidieri, E. Pagano and P. Zola
Ultrasound Obstet Gynecol 2017; 50: 395–403.

Updates in genetic screening

- **Saturday Hall A - 15:30**
Cell-free DNA: from prenatal screening to molecular diagnosis of cancer *D. Lo*
- **Sunday Hall B - 11:25**
OP08: Ultrasound and genetics
- **Monday Hall A - 13:30**
OP22 NIPT: issues and implementation
- **Tuesday Hall E - 07:30**
Masterclass: Screening for chromosomal anomalies: cfDNA for all, cFTS for all, microarray for all? *L.J. Salomon*
- 11 CME modules online such as ‘Noonan syndrome: A checkmate?’



UOG Journal top pick: Analysis of cell-free DNA in maternal blood in screening for aneuploidies: updated meta-analysis

M. M. Gil, V. Accurti, B. Santacruz, M. N. Plana and K. H. Nicolaides
Ultrasound Obstet Gynecol 2017; 50: 302–314.

Supplement your learning and earn CME via:

www.isuog.org/worldcongress2017/supplement-your-learning

Invited faculty

- A. Abuhamad (USA)
 R. Abu-Rustum (Lebanon)
 P. Acharya (India)
 J.L. Alcázar (Spain)
 M. Al-Memar (UK)
 O. Ami (France)
 E. Andreeva (Russian Federation)
 W. Arzt (Austria)
 G.A. Báez (UK)
 B. Benacerraf (USA)
 B. Benoit (France)
 D. Bettelheim (Austria)
 A. Bhide (UK)
 C.M. Bילardo (Netherlands)
 M. Blanchette Porter (USA)
 S. Bobdiwala (UK)
 P. Boukobza (France)
 T. Bourne (UK)
 C. Brezinka (Austria)
 P. Brugger (Austria)
 E. Bujold (Canada)
 P. Calda (Czech Republic)
 S. Campbell (UK)
 M. Cardoso Diogo (Portugal)
 J.S. Carvalho (UK)
 G. Chalouhi (France)
 F. Chantraine (Belgium)
 R. Chaoui (Germany)
 T. Chudleigh (UK)
 T. Cohen-Overbeek (Netherlands)
 S. Collins (UK)
 G. Condou (Australia)
 Y. Copado Mendoza (Mexico)
 J.A. Copel (USA)
 F. Crispí (Spain)
 F. da Silva Costa (Australia)
 J. Deng (UK)
 G. DeVore (USA)
 G. Di Renzo (Italy)
 H.P. Dietz (Australia)
 K. Dimassi (Tunisia)
- T.M. Eggebø (Norway)
 C. Egoroff (France)
 S. Eik-Nes (Norway)
 E. Epstein (Sweden)
 H. Feltovich (USA)
 S. Ferrero (Italy)
 F. Figueras (Spain)
 D. Fischerová (Czech Republic)
 C. Fotopoulou (UK)
 W. Froyman (Belgium)
 T. Frusca (Italy)
 P. Gabor (France)
 A. Gagnon (Canada)
 H. Gardiner (USA)
 J. Gardosi (UK)
 I. Geiss (Austria)
 T. Ghi (Italy)
 L. Gindes (Israel)
 P. Glanc (Canada)
 E. Gratacós (Spain)
 G. Gruber (Austria)
 S. Guerriero (Italy)
 L. Guibaud (France)
 G. Haddad (France)
 E. Hafner (Austria)
 L. Hanson (USA)
 H. Härting (Austria)
 K. Hecher (Germany)
 S. Helmy (Austria)
 E.A. Hernandez-Andrade (USA)
 M. Herrera (Colombia)
 G. Hudelist (Austria)
 L. Hui (Australia)
 P. Husslein (Austria)
 J. Hyett (Australia)
 L. Impey (UK)
 A. Johnson (USA)
 D. Jurkovic (UK)
 K.O. Kagan (Germany)
 G. Kasprlan (Austria)
 A. Khalil (UK)
- E. Kirk (UK)
 T. Kiserud (Norway)
 P. Klaritsch (Austria)
 H. Koelbl (Austria)
 E. Krampfl-Bettelheim (Austria)
 S. Laifer-Narin (USA)
 C. Landolfo (Italy)
 U. Lang (Austria)
 W. Lee (USA)
 C. Lees (UK)
 F. Leone (Italy)
 D. Lo (Hong Kong)
 S. Lobmaier (Germany)
 G. Malingier (Israel)
 K. Maršál (Sweden)
 M. Massoud (France)
 A. Melo (Brazil)
 E. Merz (Germany)
 J. Miller (USA)
 A.E. Millischer (France)
 C. Mitter (Austria)
 E. Mlczoch (Austria)
 J.E. Morice (France)
 A. Ngu (Australia)
 M. Norton (USA)
 A. Odibo (USA)
 D. Paladini (Italy)
 A.T. Papageorghiou (UK)
 T. Pepera-Hibbert (UK)
 L.D. Platt (USA)
 L. Poon (Hong Kong)
 D. Prayer (Austria)
 D. Pugash (Canada)
 D. Rabinovici (Austria)
 N.J. Raine-Fenning (UK)
 C. Redman (UK)
 G. Rizzo (Italy)
 R. Romero (USA)
 L.J. Salomon (France)
 M. Sanz Cortes (Spain)
 P. Schwärzler (Austria)
- S. Seshadri (India)
 L. Sentilhes (France)
 P. Sladkevicius (Sweden)
 G. Smith (UK)
 T. Spector (UK)
 H. Steiner (Austria)
 J. Stirnemann (France)
 F. Stuhr (Austria)
 G. Szabo (Hungary)
 A. Tabor (Denmark)
 G. Ter Haar (UK)
 A.C. Testa (Italy)
 B. Thilaganathan (UK)
 J. Thornton (UK)
 D. Timmerman (Belgium)
 I. Timor-Tritsch (USA)
 A. Toi (Canada)
 G. Tulzer (Austria)
 B. Tutschek (Switzerland)
 D. Twickler (USA)
 F. Ushakov (UK)
 L. Valentin (Sweden)
 B. Van Calster (Belgium)
 T. Van den Bosch (Belgium)
 D. Van Schoubroeck (Belgium)
 S. Verlohren (Germany)
 Y. Ville (France)
 G. Visser (Netherlands)
 N. Vrachnis (Greece)
 J. Weichert (Germany)
 S. Westerway (Australia)
 L. Wilkins-Haug (USA)
 C. Wohlmuth (USA)
 Q. Wu (China)
 E. Xilakis (UK)
 S. Yagel (Israel)
 M. Yamamoto (Chile)
 G. Yeo (Singapore)
 L. Yeo (USA)
 A. Youssef (Italy)



Speaker declarations

The following speaker declarations have been received:

M. Al-Memar	Paid an honorarium by Samsung to lecture on the IOTA ADNEX model
T.A. Andersen and H.C. Arneberg	Thomas Scholbach co-developed the PixelFlux software and is medical advisor as well as co-owner of the Chameleon-software company (P21.07, EP22.07)
J.S. Carvalho	Will perform a live scan and will refer to Hitachi equipment used. No direct financial interest with manufacturers; however Hitachi supports teaching courses, providing equipment for practical 'hands-on' or 'live scan' sessions
R. Chaoui	Gives talks for GE on 3D and receives an honorarium for this
J.A. Copel	Equipment loan from Philips Ultrasound
A. Dall'Asta	Samsung Medison has provided unrestricted travel and subsistence grant for this research (OC19.05, OP30.06)
G. DeVore	Consultant for GE Healthcare; uses images from their machines
H.P. Dietz	Received unrestricted educational grants and honoraria from GE Medical, of a total value of AUD 10,000 over the last ten years (OP28.03, OP28.04, OP28.06, OP28.08, P07.05, P07.06)
H. Feltovich	Received engineering support, equipment loans and intellectual property from Siemens Ultrasound USA (EP22.12)
J. Gardosi	Customised growth charts ('GROW') are licensed to ensure users have appropriate education and training. Is Director of the Perinatal Institute which provides, quality assures and derives income from licensing the electronic applications of the customised growth chart (GROW App)
A. Johnson	Receives royalties from Up-To-Date as an author of chapters on TTTS
K.O. Kagan	Poster about Cytotect (Immunoglobine for CMV infection); Presentation about cfDNA (Harmony-Test)
M.Y. Lee	Study supported by The National Health Clinical Research Program Grant from the KHIDI, Republic of Korea (HC15C1336) (P22.04)
W. Lee	Samsung WS80a ultrasound system (Live Scan); 5D Limb Volume software. Receives research support from Samsung
L.D. Platt	Research support and speakers bureau GE Medical Systems; Medical Adviser, Illumina
N. Raine-Fenning	May refer to GE Voluson machines. Is a Luminary/advisor for GE Healthcare, Ferring and Merck Serono
C. Redman	Dawes Redman Computerised CTG system, marketed by Hunteigh Health Care, Cardiff, UK. Is an unpaid consultant for Hunteigh but receives financial assistance to attend meetings
I. Salim	Study supported by Philips Ultrasound (P08.11)
S. Santhirakumaran	Supported by loan equipment from Samsung and an unrestricted research grant from Samsung to Genesis Research Trust (EP22.10, EP22.13)
M. Schmid	Authors are employees of Roche Sequencing Solutions, Inc. (OP22.04, EP06.13)
H. Shah	Funding provided by Genesis Research Trust by way of an educational grant and the loan of Samsung Equipment by Samsung Medison Co. Ltd., South Korea (OP30.11, P09.07, EP22.23)
N.N. Subbarao	Employee of Samsung Medison (EP27.03)
A. Tabor	Participation in a yearly meeting with Ariosa/Roche and with Illumina
S. Verlohren	Consultant/Speaker for Roche Diagnostic, ThermoFisher, Ferring
J. Weichert	SAMSUNG HME. Receives workshop and lecture fees

The following presentations will include discussion of commercial products/services:

OC01.02, OC01.04, OC07.02, OC08.05, OC09.02, OC13.07, OC15.03, OC17.05, OC19.05, OC22.04, OP05.04, OP05.07, OP08.06, OP08.07, OP13.01, OP14.05, OP16.07, OP17.09, OP19.06, OP21.06, OP22.04, OP24.08, OP25.04, OP30.06, OP30.10, OP30.11, OP31.02, P04.08, P07.04, P09.07, P11.05, P13.08, P14.06, P15.06, P16.02, P16.06, P16.10, P21.07, P22.03, P26.09, P29.02, EP06.13, EP07.09, EP14.21, EP16.15, EP16.19, EP17.03, EP18.11, EP19.12, EP22.07, EP22.10, EP22.12, EP22.13, EP22.20, EP22.23, EP22.24, EP23.02, EP28.14

The following presentations will include discussion of investigative or off label uses of products:

OC01.04, OC01.05, OC04.04, OC08.03, OC16.02, OP24.08, P15.07, EP04.08, EP14.01, EP14.20, EP16.19, EP17.03, EP22.12, EP27.04

The following presentations will include discussion of clinical studies:

OC01.02, OC01.04, OC01.05, OC02.01, OC02.05, OC04.01, OC04.04, OC04.05, OC05.05, OC07.02, OC08.01, OC08.03, OC08.04, OC09.03, OC09.04, OC10.04, OC10.05, OC13.03, OC13.07, OC15.03, OC15.04, OC16.02, OC18.02, OC18.03, OC18.05, OC21.04, OC21.05, OC22.04, OC22.05, OC23.01, OP01.05, OP02.01, OP02.09, OP02.11, OP03.01, OP04.09, OP05.06, OP07.01, OP08.02, OP08.06, OP10.01, OP10.02, OP10.04, OP10.10, OP11.04, OP12.03, OP12.05, OP12.09, OP13.05, OP13.06, OP14.09, OP15.04, OP15.07, OP16.11, OP17.05, OP17.10, OP18.05, OP19.03, OP20.06, OP21.04, OP22.05, OP23.03, OP23.09, OP24.08, OP25.04, OP25.05, OP26.09, OP27.03, OP27.07, OP28.03, OP28.05, OP28.06, OP28.08, OP30.10, OP31.06, P01.02, P03.02, P03.04, P04.04, P04.05, P04.06, P05.05, P05.07, P05.11, P07.06, P08.05, P11.08, P13.05, P14.10, P15.07, P19.07, P19.08, P21.04, P22.06, P22.07, P22.08, P23.07, P25.04, P26.05, P26.09, P26.10, P27.03, P28.06, P30.04, P30.09, EP01.03, EP02.12, EP04.03, EP04.06, EP04.09, EP04.37, EP06.05, EP08.01, EP09.01, EP10.11, EP12.32, EP12.37, EP13.01, EP14.09, EP14.10, EP14.15, EP14.20, EP15.13, EP16.01, EP16.02, EP16.07, EP16.08, EP16.15, EP16.17, EP16.19, EP17.03, EP17.07, EP17.09, EP17.14, EP18.11, EP25.08, EP26.04, EP27.02, EP27.03, EP27.04, EP27.07, EP27.11, EP28.07

Award winners



Greg DeVore

Winner of the Ian Donald Gold Medal

Dr. DeVore is an expert in fetal ultrasound who has pioneered work in the identification of congenital heart defects using 2D, 3D, 4D, and color Doppler ultrasound. He has published numerous studies in the peer-reviewed medical literature describing the use of fetal echocardiography to detect fetuses with Down syndrome and other chromosomal defects. Greg DeVore has the highest detection rate reported in medical literature for the detection of Down syndrome using Genetic Ultrasound.

He started his clinical training at Yale University where he received the prestigious Meehan-Miller award and a research grant from the Thrasher Research Fund. This allowed him to do pioneering research in the ultrasound evaluation of the fetal heart. After completing his training, Dr. DeVore joined the faculty at the University of Southern California School of Medicine where he was an Associate Professor for a number of years. After leaving the academic environment, he became a full-time consultant to assist community-based obstetricians with difficult fetal problems. Dr. DeVore was a consultant for the Perinatal Research Branch of the National Institutes of Health, Detroit, Michigan, where he was instrumental in implementing the fetal echocardiography program. Currently, Dr. DeVore is a Clinical Professor of Obstetrics and Gynecology at the David Geffen School of Medicine at UCLA, in Los Angeles, California.

Dr. DeVore has published research findings throughout his career, author over 120 peer-reviewed papers, contributed chapters to over 30 textbooks of medicine, and has been an invited speaker numerous national and international medical meetings.



Gail ter Haar

Winner of the Ian Donald Award for Technical Merit

Gail ter Haar is currently chair of both the British and European committees for medical ultrasound safety and general secretary of the International Society of Therapeutic Ultrasound. She holds an MA(Oxon) and PhD in Physics and has been awarded a DSc(Oxon) in clinical medicine.

Gail ter Haar's PhD research was a study of the interaction of ultrasound with tissue, in an effort to further understanding of both the safety of diagnostic ultrasound and of its potential therapeutic applications. She has continued this interest throughout her research career, initially developing an ultrasound hyperthermia system and looking at synergistic effects of ultrasound on heating tissue. She has also been closely involved in developing safety standards and guidelines for diagnostic ultrasound.

Most recently, she has been investigating the use of high intensity focused ultrasound (HIFU) to rapidly heat and kill malignant tumours, to provide pain relief for bone metastases, and to occlude placental blood vessels. She is also investigating the role of therapeutic ultrasound in stimulating the immune system.

Keynote speakers



Hans Härting

At Austrian Airlines, Captain Härting heads the Human Factors Training department in flight operations as well as being a crew resource management trainer.

Together with Prof. Pateisky, he has been working in medicine and industry since 2002. They apply tools and strategies that improve the safety of employees and patients.

His work with AssekuRisk involves the training of employees in medicine and business, as well as the practical support of projects on the ground. Safety is Captain Härting's passion. During our Congress, Captain Härting will give an interesting talk on the use and importance of Doppler, specifically how it helped you join us Vienna!



Dennis Lo

Dennis Lo is the Director of the Li Ka Shing Institute of Health Sciences, the Li Ka Shing Professor of Medicine and Professor of Chemical Pathology of the Chinese University of Hong Kong (CUHK). He is also the Associate Dean (Research) of the Faculty of Medicine of CUHK. Dennis Lo received his Bachelor of Arts degree from the University of Cambridge and Doctor of Medicine and Doctor of Philosophy degrees from the University of Oxford.

His research interests focus on the biology and diagnostic applications of cell-free nucleic acids in plasma. In particular, he discovered the presence of cell-free fetal DNA in maternal plasma in 1997 and has since then been pioneering non-invasive prenatal diagnosis using this technology.

In recognition of his work, Dennis Lo has received numerous awards and honours, including election as a Fellow of the Royal Society, a Foreign Associate of the US National Academy of Sciences and a Fellow of the World Academy of Sciences. He was awarded the King Faisal International Prize in Medicine in 2014 and the Future Science Prize in Life Science in 2016.



Adrianna Melo

Dr Adriana Melo studied Medicine at the Universidade Federal da Paraíba and has a Master's Degree in Public Health from Universidade Estadual da Paraíba. She gained her PhD in Obstetrics and Gynecology from the Universidade Estadual de Campinas and has a Post-doctoral fellowship in Maternal and Child Health. She is a Professor at the Federal University of Campina Grande as well as being the President of the Research Institute Professor Joaquim Amorim Neto. She was the first researcher to publish cases of Congenital Zika and will be presenting the Stuart Campbell lecture 'Zika virus intrauterine infection causes fetal brain abnormality and microcephaly: tip of the iceberg?' at the ISUOG World Congress this year.

Keynote speakers



Mary Norton

Mary Norton is a perinatologist and geneticist, and is Professor and Interim Chair in the Department of Obstetrics, Gynecology and Reproductive Sciences at the University of California, San Francisco (UCSF). She is Director of the Prenatal Diagnostic Center at UCSF and co-Director of the UCSF Center for Maternal-Fetal Precision Medicine. She is also the President of the Perinatal Quality Foundation, and the Immediate Past President of the Society for Maternal-Fetal Medicine. Her clinical and research interests include genetic testing and its application to prenatal screening and diagnosis. She focuses on the unique aspects of translating new technologies into improved care for pregnant women and their fetuses. Much of her recent research has involved cell-free DNA screening and implementation into prenatal care.



Doron Rabinovici

Born in 1961 in Tel Aviv, Doron Rabinovici has lived in Vienna since 1964. His non-fiction study of the Jewish Council in World War II Vienna, *Instanzen der Ohnmacht* was published by Polity Press in 2011 as *Eichmann's Jews*. His novel, *Andernorts*, was short-listed for the German Book Prize in 2010. From 2013 to 2015 Doron Rabinovici and Matthias Hartmann produced the performance "The Last Witnesses". The production staged the memory of seven survivors and was set on the main stage of the Viennese Burgtheater. Doron Rabinovici's numerous awards include the Anton Wildgans Prize, the Clemens Brentano Prize, the Jean-Améry-award and the Austrian Book Trade Honorary Award for Tolerance in Thought and Action. As an ISUOG keynote speaker, his talk promises to illuminate Viennese history which was pivotal in the shaping of modern Europe.



Tim Spector

Tim Spector is a Professor of Genetic Epidemiology and Director of the TwinsUK Registry at Kings College, London. He trained originally in rheumatology and epidemiology. In 1992 he moved into genetic epidemiology and founded the UK Twins Registry, of 13,000 twins, which is the richest collection of genotypic and phenotypic information worldwide. He is past President of the International Society of Twin Studies, directs the European Twin Registry Consortium (Discotwin) and collaborates with over 120 centres worldwide. He has demonstrated the genetic basis of a wide range of common complex traits, many previously thought to be mainly due to ageing and environment. Through genetic association studies (GWAS), his group have found over 500 novel gene loci in over 50 disease areas. He has published over 800 research articles and is ranked as being in the top 1% of the world's most cited scientists by Thomson-Reuters as well as the most cited scientist at King's College London. He held a prestigious European Research Council senior investigator award in epigenetics and is a NIHR Senior Investigator and is a Fellow of the UK Academy of Medical Sciences. His current work focuses on omics and the microbiome and directs the crowdfunded British Gut microbiome project. He is a prolific writer with several popular science books and a regular blog, focusing on genetics, epigenetics and most recently microbiome and diet (The Diet Myth). He is in demand as a public speaker and features regularly in the media.

**Jim Thornton**

Jim Thornton qualified from Leeds University in 1977. Between 1979 and 1983 he worked at the Chogoria Mission Hospital in Kenya. Since 2001 he has been working as a Professor of Obstetrics and Gynecology at Nottingham University where he has been undertaking research in clinical trials including, most recently, a clinical trial into the induction of labour at 39 weeks for women aged over 35 (35–39 trial).

He has previously worked as the editor for the European Journal of Obstetrics and Gynecology and British Journal of Obstetrics and Gynecology. He is currently the chair for the Swedish Research Council, Vetenskapsrådet, Clinical Therapy Research Board. In 2005 he stood for Parliament (Conservative Party) in Nottingham East.

**Dirk Timmerman**

Dirk Timmerman is Professor in Obstetrics and Gynecology at KU Leuven, Belgium, and Clinical Head of Benign Gynecology and Early Pregnancy UZ Leuven, Vice-chair of the Medical Council at the University Hospitals Leuven and Senior Clinical Investigator of the Scientific Research Fund (FWO) Flanders.

He is coordinator of the International Ovarian Tumor Analysis (IOTA) collaborative group including more than 50 centers for ovarian cancer diagnosis throughout the world. The IOTA group aims to develop new algorithms and liquid biopsies to diagnose and detect ovarian cancer and for optimal care of adnexal tumours (included patients $n > 22,500$). Dirk Timmerman has received the InBev Baillet-Latour Prize for Clinical Research 2014 at the Royal Academy of Medicine, Belgium, Fellowship ad eundem from the Royal College of Obstetricians and Gynaecologists (RCOG, London, 2014) and the William J. Fry Memorial Lecture Award from the American Institute of Ultrasound in Medicine 2016 at AIUM Annual Convention, New York.



CFEF Hands-on training

Learn how to get the right view, the right measurement, in just a few minutes

The French College of Fetal Ultrasound (CFEF) will again be running their highly successful hands-on training at the World Congress in Vienna. The CFEF workshops* give participants the opportunity to take part in intimate training sessions on a specific difficult topic such as 3D surface, corpus callosum, and cerebral Doppler. Pregnant models will be in each room to assist seeing the normal view.

Saturday 16 September 2017					ROOM 0.84
GE 1	GE 2	Samsung 3	Philips 4	Hitachi 5	
08:30 - 09:00	Biometry	3D surface	Uterine & umbilical dopplers	Corpus callosum	Cerebral Doppler & ductus venosus
09:15 - 09:45	Corpus callosum	Hard palate	3 Vessels & trachea	Cerebral Doppler & ductus venosus	Posterior fossa
10:00 - 10:30	Hard palate	3 Vessels and trachea	4 Chambers	Uterine & umbilical dopplers	Great vessels
10:30 - 11:00	Coffee break				
11:00 - 11:30	Posterior fossa	Oesophagus	Corpus callosum	Great vessels	Kidneys Spleen Liver Thyroid
11:45 - 12:15	Great vessels	4 Chambers	Hard palate	Posterior fossa	Biometry
12:15 - 13:45	Lunch				
13:45 - 14:15	4 Chambers	Great vessels	Cerebral Doppler & ductus venosus	3 Vessels & trachea	Uterine & umbilical dopplers
14:30 - 15:00	3D Surface	Cerebral Doppler & ductus venosus	Biometry	Hard palate	4 Chambers
15:00 - 15:30	Coffee break				
15:30 - 16:00	3 Vessels & trachea	Biometry	Posterior fossa	4 Chambers	Hard palate
16:15 - 16:45	Cerebral Doppler & ductus venosus	Posterior fossa	Great vessels	Kidneys Spleen Liver Thyroid	Corpus callosum

* Maximum 3 workshops per delegate

Fee: €39.99 per workshop



GE Healthcare

HITACHI
Inspire the Next

SAMSUNG

PHILIPS

Trice

How to participate: All participants should pre-register to attend these workshops. Please ask at Registration to see if there is any availability.



Certificate in Fetal MRI



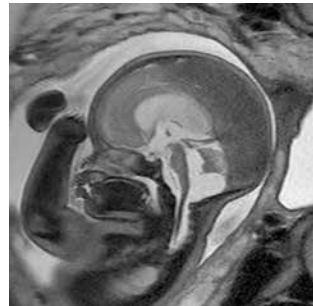
There is an exciting opportunity this year to acquire a basic certificate in Fetal MRI at the World Congress in Vienna. For the first time, delegates attending the PCC in Fetal MRI will be able to follow a program convened by Prof Daniela Prayer and Prof Laurent Salomon. There will be a test at the end of the Congress where successful candidates will receive a certificate.

Conditions for successful completion of the course:

1. Attendance of the Pre Congress Course on Fetal MRI on *Friday 15 September 2017*
2. Attendance of five specifically marked Scientific sessions
3. Passing of an examination on *Tuesday 19 September 2017, Hub 2 : 12:20-13:20*

Sessions: Examples of the specified sessions are below. These will be clearly marked in the program with the symbol ★. Certificate attendees should ensure they are scanned in to each session.

- ★ Brain anomalies: challenges in diagnosis and counselling
- ★ Fetal brain: form and function
- ★ Ultrasound meets MRI: form and function
- ★ Fetal anomalies: from diaphragm up
- ★ Fetal brain and CNS anomalies
- ★ Fetal growth and the brain
- ★ Fetal brain novel applications of ultrasound and MRI
- ★ New tools to evaluate the fetal brain and CNS
- ★ The challenge of evaluating the fetal brain



How to participate: If you have not already contacted congress@isuog.org, you will have the opportunity to sign up on the day of the Pre-Congress Course, *Friday 15 September*

Fee: Participants will need to pay for both the Pre-Congress Course and the Congress itself to achieve the certificate requirements. However, there is no additional charge for the certificate.

What's next: The certificate can be used as the basis of knowledge to attend onsite training as suggested by the ISUOG guidelines for Fetal MRI at a Fetal MRI centre.

Please note that this course is not officially accredited.

Session types explained

Masterclasses

ISUOG invites individual experts to create, present and chair an entire session's content. These popular sessions give attendees the opportunity to hear longer in-depth analysis on a particular subject from a world renowned speaker.

Workshops

Our workshops are created by members of ISUOG's international faculty, who ask leading experts in their field to deliver didactic state-of-the-art talks on a particular topic.

Oral Communications (OC)

Oral Communications (OC) are presentations of abstracts from our submission process that are given 5 minutes to present and 3 minutes for discussion. These take place in the main session halls and are identified by the OC next to the title of the session.

Short Oral Presentations (OP)

Short Oral Presentations (OP) are single slide summaries of abstracts from our submission process that are given 2 minutes to summarise the research and 2 minutes for discussion. These succinct presentations give a quick insight into research happening on a particular topic.

Poster discussions (P)

Poster discussions (P) put together posters by topic for discussions in our Hub space. Chaired by an expert in the field, these are intimate, informal and friendly spaces designed to offer the author the opportunity to meet delegates interested in their research, discuss any comments and answer questions on their work.

Electronic Posters (EP)

Available on our app and On Demand stations, electronic posters give access to submitted research that is not being presented orally as PowerPoint slides. Delegates can contact authors through the integrated email facility On Demand.

Hubs

The Hubs are informal interactive sessions which provide excellent opportunities to communicate and network with fellow attendees. The Hubs cover various formats and topics such as: 'Meet the professors', poster discussions, ISUOG guidelines, Special Interest Group (SIGs) and Outreach, partnership and trainee sessions.

ISUOG AGM - Saturday 16.09.2017

Hall A: 9:50-10:35

Hear what your society has been doing this year and have your say to change the future.



have
your!
say.

Download the official Congress app



Create your
personalised
agenda

Stay up-to-date
with what's going on



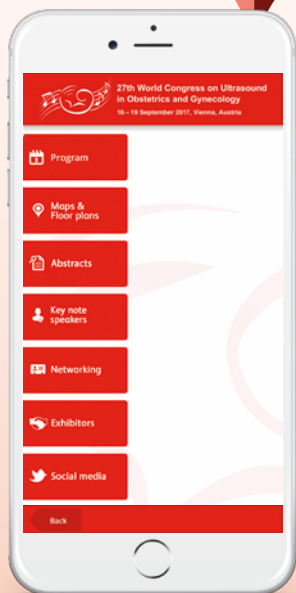
Engage
with other
attendees

Stay social
on our Twitter
and Facebook



Have your say
by voting, rating and
completing our surveys

Read all
abstracts



Search for
'ISUOG 2017'



Available on the iPhone

App Store



GET IT ON

Google play

Join the Congress conversation

#ISUOG2017



 **isuog**.org

Friday 15.09.2017

	Hall B	Hall N	L2
07:00	Registration open		
08:00-17:45	Essentials in fetal MRI: methods and brain imaging (09:00-17:15)	Modern obstetric management: the latest updates (08:00-17:55)	Fetal anatomy: normal or abnormal? The Basic Training approach (08:30-16:15)
	 ispd  Society for Maternal-Fetal Medicine		

Saturday 16.09.2017

	Hall A	Hall E	Hall F	Hall B
07:00	Registration open			
08:30-09:50	Plenary Keynote lectures: Beyond ultrasound			
09:50-10:35	AGM			
10:35-11:00	Coffee and electronic poster viewing			
11:00-12:15	Keynote lecture and top abstracts			
12:15-13:45	Lunch and electronic poster viewing / Satellite Symposia (12:30-13:30)			
13:45-15:05	WS: How to systematically describe adenomyosis and endometriosis and how this helps the surgeon [LIVE SCAN]	WS: Safe ultrasound assisted vaginal deliveries	WS: New approaches to fetal growth: which should I use?	WS: MRI: it's not just for heads anymore
15:05-15:30	Coffee and electronic poster viewing			
15:30-17:30	Awards and keynotes			
17:30-19:30	Opening ceremony and Welcome reception			

Sunday 17.09.2017

	Hall A	Hall E	Hall F	Hall B
07:00	Registration open			
07:30-08:10	Masterclass: Screening and prevention of stillbirth: possibilities and pitfalls	Masterclass: The heart of the matter	Masterclass: Evaluating the endometrium from fertility to menopause	Masterclass: What RCT's can and can't tell us
08:15-09:15	OC: Fetal growth: consequences of being too big or too small [LIVE SCAN]	OC: Fetal heart: what's new	OC: Imaging, reproductive medicine and IVF	
09:20-10:00	OP: Placental and maternal factors in IUGR	OP: Fetal cardiac function	OP: Using ultrasound to solve old and diagnose new problems in reproductive medicine	OP: Fetal anomalies: from the diaphragm up
09:50-10:20	Coffee and electronic poster viewing			
10:20-11:20	OC: Fetal structural abnormalities [LIVE SCAN]	OC: Brain anomalies: challenges in diagnosis and counselling	WS: Using ultrasound to help manage oncology patients (10:20-12:00)	OP: Ultrasound meets MRI: form and function (10:20-11:00)
11:25-12:05	OP: Fetal growth anatomy and measurements	OP: Hot topics around the fetal brain		OP: Ultrasound and genetics
12:00-13:30	Lunch and electronic poster viewing / Satellite Symposia (12:15-13:15)			
13:30-14:30	WS: Fetal echocardiography: complexity made simple [LIVE SCAN]	OC: From poor placentation to pre-eclampsia	OC: Miscarriage, ectopic pregnancy, PUL and other complications in early pregnancy	
14:35-15:15	OP: Detection of fetal heart anomalies I	OP: Babies born too early or too small	OP: Complications in early pregnancy: using imaging and biomarkers to provide new insights	OP: Screening
15:10-15:40	Coffee and electronic poster viewing			
15:40-17:00	WS: IUGR management after the TRUFFLE trial: key messages	WS: Abnormally invasive placenta	WS: The future of ultrasound for the detection of CNS anomalies after the MERIDIAN trial	WS: Difficult problems in early pregnancy: PUL, enhanced myometrial vascularity, diagnosing and managing Caesarean scar pregnancy
19:00-00:30	Congress party at the Rathaus			

Monday 18.09.2017

	Hall A	Hall E	Hall F	Hall B
07:00	Registration open			
07:30-08:10	Masterclass: Fetal neurosonography: tips and tricks	Masterclass: New frontiers in preterm labour	Masterclass: Management of fetal growth restriction in practice	Masterclass: Revising IOTA terms and definitions: case examples of how to classify ovarian masses
08:15-09:15	OC: Abnormal fetal growth: causation, detection and long-term effects	OC: Fetal brain exposed to Zika and CMV virus	OC: Using ultrasound to characterise and help manage ovarian masses	
09:20-10:00	OP: Small-for-gestational age	OP: Fetal brain and CNS anomalies	OP: Using ultrasound to characterise and guide the management of ovarian masses: do IOTA models work in practice?	OP: Detection of fetal heart anomalies II
09:50-10:20	Coffee and electronic poster viewing			
10:20-11:20	OC: Fetal brain: form and function [LIVE SCAN]	OC: Can ultrasound guide delivery?	OC: Using imaging to help in the management of oncology patients	OP: Hypertensive disease in pregnancy: screening to diagnosis
11:25-12:05	OP: Fetal growth and the brain	OP: Ultrasound in the labour ward	OP: How using ultrasound can inform the management of patients with gynecological malignancy	OP: Fetal development in maternal conditions
12:00-13:30	Lunch and electronic poster viewing / Satellite Symposia (12:15-13:15)			
13:30-14:30	WS: Big mothers, big babies: getting the most from your scan [LIVE SCAN]	OC: CfDNA tests: where are we now?	OC: Advances in fetal surgery	OC: Uterine and endometrial problems: from asymptomatic polyps to repairing Caesarean section scars
14:35-15:15	OP: NIPT: issues and implementation	OP: Invasive procedures: new data	OP: Uterine and endometrial problems: from elastography to using ultrasound to monitor treatment response	OP: Clinical challenges in chorionicity
15:10-15:40	Coffee and electronic poster viewing			
15:40-17:00	WS: Understanding outflow tract abnormalities [LIVE SCAN]	WS: Complications of twins: how to image, how to manage	WS: Update from IOTA group: how to use the IOTA rules and models	WS: Late fetal growth restriction
17:15-18:15	Company sponsored symposia			

Tuesday 19.09.2017

	Hall A	Hall E	Hall F	Hall B
07:00	Registration open			
07:30-08:10	Masterclass: The first trimester anomaly scan	Masterclass: Screening for chromosomal anomalies; cfDNA for all, cfTS for all, microarray for all?	Masterclass: Examining women with pelvic pain: how I do it (case examples)	Masterclass: Computerised fetal heart rate analysis in high-risk pregnancy
08:15-09:15	OC: State-of-the-art techniques to image the fetus	OC: Is this placenta abnormally invasive?	OC: Solving problems in urogynecology including data from the OASIS trial	WS: Working in the field: ISUOG Outreach trainers workshop (08:30-10:30)
09:20-10:00	OP: Managing TTTS	OP: How to diagnose and manage abnormal placentation	OP: Solving problems in urogynecology using ultrasound	
09:50-10:20	Coffee and electronic poster viewing			
10:20-11:20	OC: Advanced cytogenetic techniques: impact on ultrasound practice	WS: 3D/4D ultrasound: is it living up to its promise?	OC: How ultrasound is used to assess women with pelvic pain and diagnose endometriosis	
11:25-12:05	OP: Education, simulation and safety	OP: Fetal brain novel applications of ultrasound and MRI (11:30-12:10)	OP: Using ultrasound to assess pelvic pain and diagnose endometriosis	
12:00-13:30	Lunch and electronic poster viewing / Satellite Symposia (12:15-13:15)			
13:30-14:50	WS: Ultrasound and genetic diagnostics at 12 weeks [LIVE SCAN]	WS: Pre-eclampsia in 2017	WS: Managing ovarian masses – what is the evidence base and which approach should we use to classify ovarian masses?	
14:50-16:20	Closing plenary: Show us the power of ultrasound			
16:20-17:30	Leaving drinks and welcome to Singapore 2018!			

Masterclasses

	Session	Presenter	Room
Sunday 07:30-08:10	Screening and prevention of stillbirth: possibilities and pitfalls	<i>G. Smith (UK)</i>	Hall A
		<i>G.R. DeVore (USA)</i>	Hall E
	The heart of the matter (Ian Donald Gold Medal lecture)	<i>T. Van den Bosch (Belgium)</i>	Hall F
	Evaluating the endometrium from fertility to menopause	<i>J. Thornton (UK)</i>	Hall B
	What RCT's can and can't tell us		
Monday 07:30-08:10	Fetal neurosonography: tips and tricks	<i>R. Chaoui (Germany)</i>	Hall A
	New frontiers in preterm labour	<i>R. Romero (USA)</i>	Hall E
	Management of fetal growth restriction in practice	<i>E. Gratacós (Spain)</i>	Hall F
	Revising IOTA terms and definitions: case examples of how to classify ovarian masses – how I manage non-tubal ectopic pregnancies?	<i>L. Valentin (Sweden)</i>	Hall B
Tuesday 07:30-08:10	The first trimester anomaly scan	<i>C.M. Bilardo (Netherlands)</i>	Hall A
	Screening for chromosomal anomalies: cfDNA for all, cFTS for all, microarray for all?	<i>L.J. Salomon (France)</i>	Hall E
	Examining women with pelvic pain: how I do it (case examples)	<i>B. Benacerraf (USA)</i>	Hall F
	Computerised fetal heart rate analysis in high-risk pregnancy	<i>C. Redman (UK)</i>	Hall B

ISUOG Awards

At the Closing ceremony we will be announcing the winners of the:

- **Top Abstract**
- **Young Investigator prize**
- **Austrian Society for Gynaecology and Obstetrics award**
- **Best presentations in each topic**



All OC and OP presentations will be judged within their subject categories by the session chairpersons and the ISUOG Scientific Committee. Winners will be formally acknowledged in our journal, *Ultrasound in Obstetrics and Gynecology*.

Short oral presentations

	Session	Room
Sunday 09:20-10:00	OP01 Placental and maternal factors in IUGR	Hall A
	OP02 Fetal cardiac function	Hall E
	OP03 Using ultrasound to solve old and diagnose new problems in reproductive medicine	Hall F
	OP04 Fetal anomalies: from the diaphragm up	Hall B
10:20-11:00	OP05 Ultrasound meets MRI: form and function	Hall B
11:25-12:05	OP06 Fetal growth: anatomy and measurements	Hall A
	OP07 Hot topics around the fetal brain	Hall E
	OP08 Ultrasound and genetics	Hall B
14:35-15:15	OP09 Detection of fetal heart anomalies I	Hall A
	OP10 Babies born too early or too small	Hall E
	OP11 Complications in early pregnancy: using imaging and biomarkers to provide new insights	Hall F
	OP12 Screening	Hall B
Monday 09:20-10:00	OP13 Small-for-gestational age	Hall A
	OP14 Fetal brain and CNS anomalies	Hall E
	OP15 Using ultrasound to accurately characterise and guide the management of ovarian masses: do IOTA models work in practice?	Hall F
	OP16 Detection of fetal heart anomalies II	Hall B
10:20-11:20	OP17 Hypertensive disease in pregnancy: screening to diagnosis	Hall B
11:25-12:05	OP18 Fetal growth and the brain	Hall A
	OP19 Ultrasound in the labour ward	Hall E
	OP20 How using ultrasound can inform the management of patients with gynecological malignancy	Hall F
	OP21 Fetal development in maternal conditions	Hall B
14:35-15:15	OP22 NIPT: issues and implementation	Hall A
	OP23 Invasive procedures: new data	Hall E
	OP24 Uterine and endometrial problems: from elastography to using ultrasound to monitor treatment response	Hall F
	OP25 Clinical challenges in chorionicity	Hall B
Tuesday 09:20-10:00	OP26 Managing TTTS	Hall A
	OP27 How to diagnose and manage abnormal placentation	Hall E
	OP28 Solving problems in urogynecology using ultrasound	Hall F
11:25-12:05	OP29 Education, simulation and safety	Hall A
	OP30 Fetal brain novel applications of ultrasound and MRI (11:30-12:10)	Hall E
	OP31 Using ultrasound to assess pelvic pain and diagnose endometriosis	Hall F

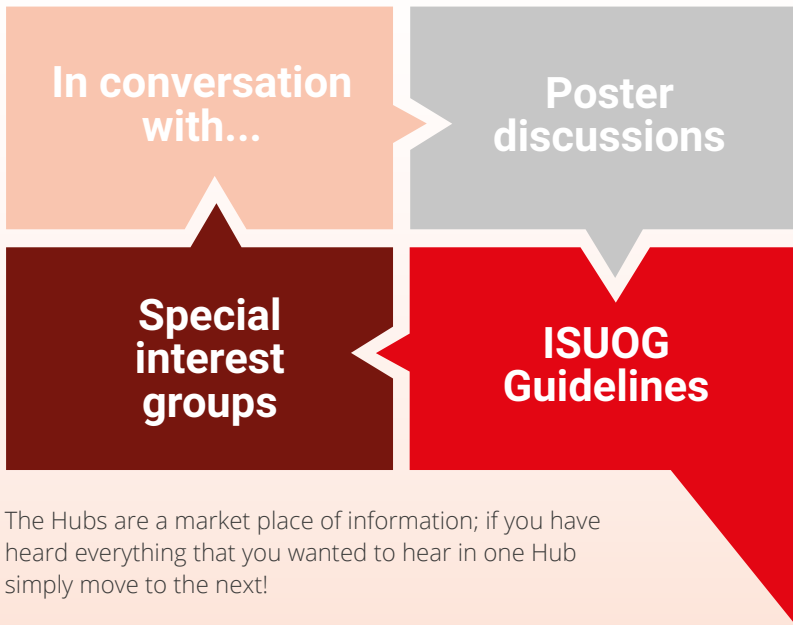Poster discussions

	Session	Room L3 / L6
Sunday 09:20-10:00	P01 Preterm birth: maternal and fetal assessment	Hub 1
	P02 New tools to evaluate the fetal brain and CNS	Hub 2
	P03 Clinical consequences of abnormal placentation	Hub 3
11:25-12:05	P04 Ultrasound in the labour ward I	Hub 1
	P05 Pre-eclampsia	Hub 2
	P06 Fetal echocardiography I	Hub 3
	P07 Using ultrasound in urogynecology patients	Hub 4
14:35-15:15	P08 Fetal growth	Hub 1
	P09 Head, neck and bones	Hub 2
	P10 Placenta, umbilical cord and amniotic fluid	Hub 3
	P11 Using ultrasound to characterise and help manage ovarian masses: experience of using the IOTA ADNEX model and simple rules	Hub 4
Monday 09:20-10:00	P12 Cysts and other abdominal features	Hub 1
	P13 Ultrasound in the labour ward II	Hub 2
	P14 Uterine and endometrial problems: from elastography to using ultrasound to monitor treatment response	Hub 3
	P15 Improving the outcome of fetal procedures	Hub 4
11:25-12:05	P16 Screening for fetal anomalies	Hub 1
	P17 Maternal and fetal assessment in complicated pregnancies	Hub 3
	P18 Techniques related to using ultrasound to assess pelvic pain and diagnose superficial endometriosis and DIE	Hub 4
	P19 Fetal echocardiography II	Hub 2
14:35-15:15	P20 The prognostic value of growth parameters	Hub 1
	P21 Predicting pregnancies at risk	Hub 2
	P22 Fetal echocardiography III	Hub 3
	P23 Managing early pregnancy complications	Hub 4
Tuesday 09:20-10:00	P24 The challenge of evaluating the fetal brain	Hub 1
	P25 Fetal growth Doppler and hemodynamics	Hub 2
	P26 Ultrasound, reproductive medicine and IVF	Hub 3
11:25-12:05	P27 Techniques for fetal cardiac diagnosis	Hub 1
	P28 References, standards and markers	Hub 2
	P29 Improving our management of twin pregnancies	Hub 3
	P30 How to use imaging to manage oncology patients	Hub 4

Hubs - join the buzz!

The Hubs are informal interactive sessions which provide excellent opportunities to communicate and network with fellow attendees.

These intimate Hubs cover various formats and topics such as: 'Meet the professors', poster discussions, ISUOG guidelines, Special Interest Group (SIGs), and Outreach, partnership and trainee sessions.



The Hubs are a market place of information; if you have heard everything that you wanted to hear in one Hub simply move to the next!

Location: Room L3 and L6, first floor

Date: Sunday 17 - Tuesday 19 September

Program: Please see the Programs at a glance

Attending the Hubs: The Hubs are part of the Congress and there are no additional fees to attend.

Join the Congress conversation

#ISUOG2017    

 **isuog**.org

Hubs at a glance

	HUB 1	HUB 2
Sunday		
08:15-09:15	In conversation with <i>B. Benacerraf</i>	
09:20-10:00	Preterm birth: maternal and fetal assessment	New tools to evaluate the fetal brain and CNS
10:20-11:20	In conversation with <i>M. Blanchette Porter</i>	WATOG: In conversation with trainees
11:25-12:05	Ultrasound in the labour ward I	Pre-eclampsia
12:20-13:20	In conversation with <i>A. Testa</i>	Join the conversation: ISUOG and FIGO
13:30-14:30	In conversation with <i>H.P Dietz</i>	In conversation with FIGO
14:35-15:15	Fetal growth	Head, neck and bones
15:40-16:40		Patientenselbsthilfegruppen und gynaekologischer Ultraschall – ein Austausch




Monday		
09:20-10:00	Cysts and other abdominal features	Ultrasound in the labour ward II
10:20-11:20		In conversation with <i>T. Van den Bosch</i> and <i>D. Van Schoubroeck</i>
11:25-12:05	Screening for fetal anomalies	Fetal echocardiography II
12:20-13:20	Join the conversation: Are you practicing safe sonography?	In conversation with <i>G. Condous</i> and <i>S. Guerriero</i>
13:30-14:30		In conversation with <i>N.J. Raine-Fenning</i> .
14:35-15:15	The prognostic value of growth parameters	Predicting pregnancies at risk
15:40-17:00	Guidelines Chinese	Guidelines Spanish

Tuesday		
08:15-09:15	In conversation with <i>E. Kirk</i>	
09:20-10:00	The challenge of evaluating the fetal brain	Fetal growth Doppler and hemodynamics
10:20-11:20	In conversation with <i>D. Fischerová</i> and <i>E. Epstein</i>	
11:25-12:05	Techniques for fetal cardiac diagnosis	References, standards and markers
12:30-13:20		★ MRI certificate exam
13:30-14:30		

HUB 3

SIG: Doppler
Clinical consequences of abnormal placentation
SIG: MRI
Fetal echocardiography I
SIG: 3D
Join the conversation: Aspirin in pre-eclampsia
Placenta, umbilical cord and amniotic fluid

HUB 4

 The principles of ultrasound imaging
Gynecology oncology case discussion
 The principles of ultrasound imaging
Using ultrasound in urogynecology patients
In conversation with *B. Van Calster* and *J. Stirnemann*
Join the conversation: How to properly design a study
Using ultrasound to characterise and manage ovarian masses
 The principles of ultrasound imaging

Uterine and endometrial problems

SIG: Heart

Maternal and fetal assessment in complicated pregnancies

In conversation with the CFEF

Join the conversation: UOG - Your Journal

Fetal echocardiography III

Guidelines French

Improving the outcome of fetal procedure

Join the conversation: how do I avoid medico legal issues

Techniques related to using ultrasound to assess pelvic pain and diagnose superficial endometriosis and DIE

In conversation with *L. Sentilhes* and *R. Romero*

 Join the conversation: Live reporting – fetal MRI

Managing early pregnancy complications

Guidelines Russian

Ultrasound, reproductive medicine and IVF

Improving our management of twin pregnancies

The highlights of the meeting in Chinese

In conversation with *D. Jurkovic*

How to use imaging to manage oncology patients

WATOG: Join the conversation on issues for trainees worldwide

In conversation with *M. Herrera* and *G. Malinger*

Electronic posters


Electronic posters (EP) are available for viewing throughout the Congress on the ISUOG On Demand terminals. You can also send questions or comments to authors using our integrated email facility. Electronic posters are subject-categorised in the following pages.

- EP01 Fetal brain and CNS anomalies: cavum septum pellucidum, corpus callosum, choroid plexus and intracranial cysts
- EP02 Fetal brain and CNS anomalies: ventriculomegaly, posterior fossa and neural tube defects
- EP03 Improving the prenatal diagnosis of fetal brain and CNS anomalies
- EP04 Fetal echocardiography
- EP05 Fetal heart
- EP06 Issues in prenatal screening
- EP07 Bones and spine
- EP08 Fetal structural abnormalities I
- EP09 Fetal structural abnormalities II
- EP10 Head and neck
- EP11 Placenta, umbilical cord and amniotic fluid
- EP12 Thorax and abdomen
- EP13 Ultrasound of chromosomal anomalies
- EP14 Normal and abnormal fetal growth
- EP15 Case presentations of abnormal placentas
- EP16 Doppler and pre-eclampsia
- EP17 Maternal and fetal assessment
- EP18 Preterm birth
- EP19 Ultrasound in the labour ward
- EP20 New data in multiple pregnancies
- EP21 Fetal interventions
- EP22 Innovations in obstetric imaging
- EP23 Education, simulation and safety
- EP24 Ultrasound and management of early pregnancy complications
- EP25 Classifying and managing ovarian masses
- EP26 Diagnosing a cause for pelvic pain and classifying endometriosis
- EP27 Imaging and reproductive medicine
- EP28 Bleeding, endometrial and myometrial pathology
- EP29 Imaging in oncology patients
- EP30 Imaging and the urogynecology patient
- EP31 Innovations in gynecologic imaging

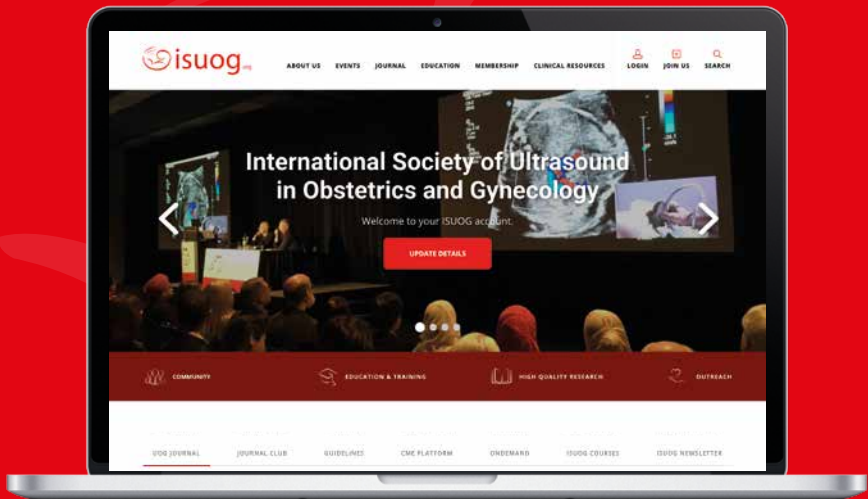PRE-CONGRESS COURSES

Friday 15 September 2017

FRIDAY



Launching your ISUOG: **www.isuog.org**



Find the highest quality educational content with the most up-to-date research and news from the field on our new, easy-to-navigate online platform with fewer clicks.

Login as a member to My ISUOG for a customisable experience. Save your favourite pages, interests and news to your personalised page.

Login to My ISUOG at www.isuog.org/login.htm

Friday 15.09.2017

HALL N

Modern obstetric management: the latest updates

Chairs: A. Tabor (Denmark); M. Norton (United States)

08:00

Introduction

A. Tabor (Denmark)

08:15

Adverse obstetric outcomes: does prediction really matter?

M. Norton (United States)

09:00

Early prediction and prevention of pre-eclampsia

L. Poon (Hong Kong)

09:30

Point of care testing in hypertensive disease of pregnancy

S. Verlohren (Germany)

10:00

Can we improve on prediction of preterm birth?

H. Feltovich (United States)

10:30

Coffee

Chairs: M. Norton (United States); H. Feltovich (United States)

11:00

Evidence-based prevention of preterm birth in high-risk women (including twins)

R. Romero (United States)

11:45

How ultrasound and biomarkers can work together to predict adverse pregnancy outcomes

G. Smith (United Kingdom)

12:15

Future biomarker discovery: distinguishing cause, consequence and pathway

B. Thilaganathan (United Kingdom)

12:45

Lunch

Chairs: R. Romero; L. Wilkins-Haug (United States)

13:55

Fetal DNA in maternal blood to predict complications: the ultimate biomarker?

M. Norton (United States)

14:40

Screening for chromosomal abnormalities using cell-free DNA: latest updates

A. Tabor (Denmark)

15:25

Coffee

Chairs: A. Tabor (Denmark); L. Wilkins-Haug (United States)

15:55

First trimester scan is still useful in the era of cfDNA

R. Chaoui (Germany)

16:25

Expanding the reach of genetic carrier screening: sequencing for single gene disorders and exome testing – who benefits, what are the cautions?

L. Wilkins-Haug (United States)

16:55

Understanding NIPT in practice: interpreting difficult clinical situations through case-based discussions

B. Thilaganathan (United Kingdom)

17:25

Genetic disease in twins: unique aspects and management

L. Wilkins-Haug (United States)

17:55

Closing comments

A. Tabor (Denmark)

In partnership with:



ROOM L2

Fetal anatomy: normal or abnormal? The Basic Training approach

Chairs: T. Chudleigh (United Kingdom); T. Cohen-Overbeek (Netherlands)

08:30 Introduction to ISUOG's 4-day Basic Training programme
R. Abu-Rustum (Lebanon)

08:45 Pre-course test
T. Cohen-Overbeek (Netherlands)

From the long axis of the fetus to the TCD

09:00 The 20 planes approach to the routine mid-trimester scan
T. Chudleigh (United Kingdom)

09:30 Evaluating fetal anatomy from longitudinal sections
T. Cohen-Overbeek (Netherlands)

10:00 Distinguishing between normal and abnormal appearances of the skull and brain
S. Seshadri (India)

10:30 Coffee

From the TCD to the AC

11:00 Obtaining and interpreting heart views correctly
A. Abuhamad (United States)

11:45 Assessing the neck and chest
G. Chalouhi (France)

12:15 Lunch

From the AC to the FL

13:15 Examining the abdomen and anterior abdominal wall
A. Johnson (United States)

13:45 Distinguishing between N and Ab appearances of the urinary tract
S. Seshadri (India)

From the FL to the extremities and finally the face

14:15 Distinguishing between normal and abnormal appearances of the long bones and extremities
G. Chalouhi (France)

14:45 Coffee

15:15 Examining the upper lip, face and profile
T. Chudleigh (United Kingdom)

Evaluating the scan findings

15:45 Making a decision: normal or not? Interactive discussion (including delegate cases)
T. Cohen-Overbeek (Netherlands)

16:15 Post-course test and speaker discussion

HALL B

★ Essentials in fetal MRI: methods and brain imaging

Chairs: D. Prayer; P.C. Brugger (Austria)

- 09:00** Introduction to the course and the fetal MRI certification
D. Prayer (Austria)
- 09:15** Basic methods of fetal MRI: tips and tricks
P.C. Brugger; F. Stuhr (Austria)
- 09:45** Advanced application of fetal MRI including application of contrast media
A.E. Millischer (France)
- 10:15** 3T or 1.5T: which field strength is more appropriate for fetal MRI?
P.C. Brugger; D. Prayer (Austria)
- 10:45** **Coffee**
- Chair: D. Pugash (Canada)*
- 11:15** Normal supratentorial fetal brain development: ultrasound and MRI
D. Pugash (Canada); L. Guibaud (France)
- 12:00** Abnormal development of cerebral commissures: ultrasound and MRI
D. Paladini (Italy); G. Kasprjan (Austria)
- 12:45** **Lunch**
- Chair: G. Kasprjan (Austria)*
- 13:45** The fetal normal and pathological posterior fossa: ultrasound and MRI
L. Guibaud (France); G. Kasprjan (Austria)
- 14:30** Lissencephalies ultrasound and MRI
D. Paladini (Italy); C. Mitter (Austria)
- 15:00** Ventriculomegaly and the FLAIR sequence: is it helpful?
M. Cardoso Diogo (Portugal)
- 15:15** Acquired brain anomaly: ultrasound and MRI
D. Pugash (Canada); D. Prayer (Austria)
- 15:45** **Coffee**
- Chair: L. Guibaud (France)*
- 16:15** Postmortem MRI: when, why and how?
G.M. Gruber (Austria)
- 16:45** Brain malformation: ultrasound and MRI of complex syndromes
All speakers
- 17:15** What would you have done? Interactive case session
All speakers



14th ISUOG INTERNATIONAL SYMPOSIUM

20-22 April 2018
Athens, Greece

Register now

Venue

Royal Olympic, Athens
royalolympic.com

Convenors

N. Vrachnis (Greece) *A.T. Papageorgiou (UK)*

Speakers

C. Bilardo (Netherlands) *A.T. Papageorgiou (UK)*
T. Bourne (UK) *B. Thilaganathan (UK)*
J. Carvalho (UK) *D. Timmerman (Belgium)*
G. Malinger (Israel) *L. Valentin (Sweden)*
D. Paladini (Italy) *N. Vrachnis (Greece)*
L. Salomon (France)

Why attend?

Join colleagues from around the world to hear from leading experts in the fields of obstetrics and gynecology in ultrasound.

Attend cutting-edge lectures, workshops, live scans, hands-on training sessions and lively debates, whilst immersed in the historic surroundings of Athens; just a few minutes' walk from the ancient Acropolis.

Critical dates

Registration & abstract submission opens	01.07.17
Early bird deadline	20.02.18
Exhibition/sponsorship deadline	20.02.18
Abstract deadline	28.02.18
Pre-Congress courses	20.04.18

Incorporating

- The ISUOG fetal anomalies course
- The IOTA Course on diagnosing ovarian cancer

Pre-Congress courses

- ISUOG Basic Training
- 3D/4D Hands-on in obstetrics

Official language: English

In partnership with:



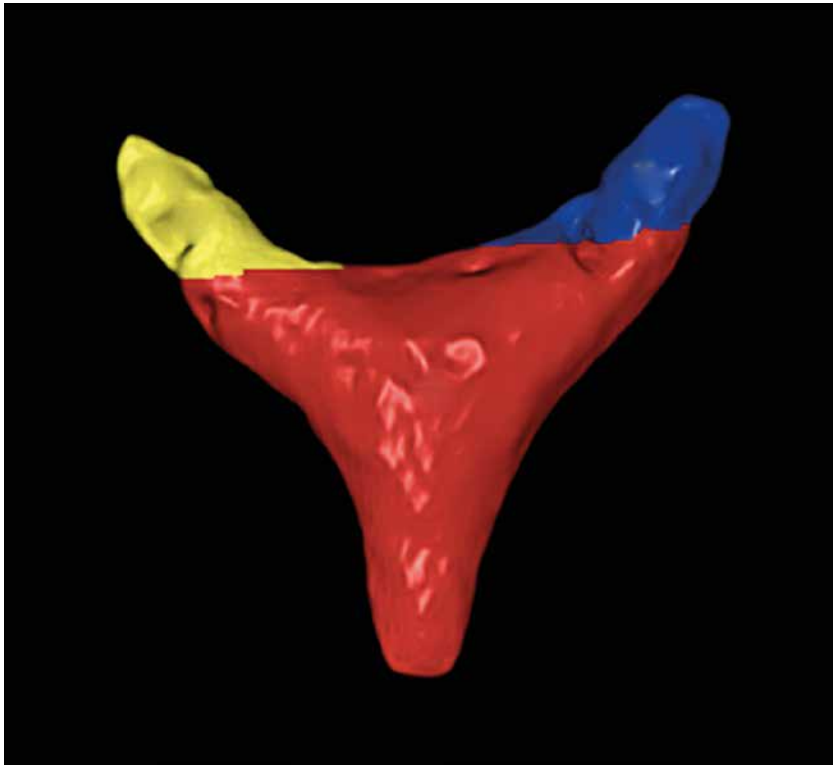
For more information and to register, please visit:
www.isuogsymposium2018.com



SCIENTIFIC PROGRAM

Saturday 16 September 2017

SATURDAY



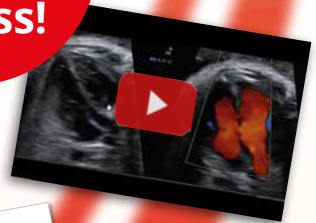Uterus with hysterosonoAVC - Ludwin A, Martins WP, Ludwin I. Uterine cavity imaging, volume estimation and quantification of degree of deformity using automatic volume calculation: description of technique. *Ultrasound Obstet Gynecol* 2017; 50: 138–140.

Earn CME any time from anywhere in the world



Supplement your learning and gain CME* through ISUOG's latest educational resource

Join ISUOG to have access!



Learning activities include:

- ISUOG's Practice Guidelines
- Web lectures from ISUOG education courses and congresses
- Journal Club articles from *Ultrasound in Obstetrics and Gynecology*

91% of CME users said the learning activities have improved their professional effectiveness

"I feel more confident answering questions and counselling."

93% of CME users reported being satisfied with ISUOG's educational content

Start exploring at **isuog.org**

info@isuog.org
+44 (0)20 7471 9955

* 1 AMA PRA category credit = 1 EACCME credit



1
credit per hour

90+
online CME activities now available



#LoveUltrasound



isuog.org

Saturday 16.09.2017

HALL A

- 08:30-09:50** **Keynote lectures: Beyond ultrasound**
Chairs: C. Brezinka; D. Prayer (Austria)
- 08:30 Welcome from the ISUOG President
J.A. Copel (United States)
- 08:35 How you got to Vienna using the Doppler effect
H. Härtling (Austria)
- 09:00 Small babies, large babies and older mothers: when shall we induce?
J. Thornton (United Kingdom)
- 09:25 Twins, microbiomes and personalised health
T. Spector (United Kingdom)
- 09:50-10:35** **ISUOG AGM**
- 10:35-11:00** **Coffee and e-poster viewing**
- 11:00-12:15** **Keynote lecture and top abstracts**
Chairs: D. Timmerman (Belgium); A.T. Papageorgiou (United Kingdom)
- 11:00 **Stuart Campbell lecture:** Zika virus intrauterine infection causes fetal brain abnormality and microcephaly: tip of the iceberg?
A. Melo (Brazil)
- 11:25 **OC01.01** Risk of complications in conservatively managed adnexal masses initially thought to be benign at subjective impression by the ultrasound examiner
W. Froyman (Belgium)
- 11:35 **OC01.02** How to estimate the degree of bowel stenosis in patients with colorectal endometriosis?
S. Ferrero (Italy)
- 11:45 **OC01.03** Incidence of stillbirth is increased in familial LQTS: a retrospective study from eight international centres
B. Cuneo (United States)
- 11:55 **OC01.04** Aspirin versus placebo in pregnancies at high-risk of preterm pre-eclampsia: a multicentre, double-blind, placebo-controlled trial
D.L. Rolnik (United Kingdom)
- 12:05 **OC01.05** STRIDER UK: a randomised controlled trial of sildenafil therapy in dismal prognosis early-onset intrauterine growth restriction
A. Sharp (United Kingdom)
- 12:15-13:45** **Lunch and e-poster viewing**
- 12:30-13:30** **Industry sponsored satellite symposia****

**Lunchtime satellite symposia are brought to you by our sponsors and are not part of the ISUOG CME program. ISUOG takes no responsibility for scientific or clinical content. Please see page 158 for our satellite program.

HALL A

13:45-15:05

Workshop How to systematically describe adenomyosis and endometriosis and how this helps the surgeon

Chairs: G. Hudelist (Austria); G. Condous (Australia)

- 13:45 How accurate is ultrasound for the diagnosis of bowel endometriosis
G. Hudelist (Austria)
- 14:00 How to predict the level of complexity of laparoscopic surgery for endometriosis using ultrasound
G. Condous (Australia)
- 14:15 A systematic approach to examining women with suspected endometriosis: the IDEA consensus
L. Valentin (Sweden)
- 14:30 How do you diagnose adenomyosis and how does it relate to symptoms?
D. Jurkovic (United Kingdom)
- 14:45 **LIVE SCAN:** how to scan deep infiltrating endometriosis – the surgeon and the sonographer view [industry supported*]
G. Hudelist (Austria)

15:05-15:30

Coffee and e-poster viewing

15:30-17:30

Awards and keynotes

Chairs: T. Bourne (United Kingdom); J.A. Copel (United States)

- 15:30 Cell-free DNA: from prenatal screening to molecular diagnosis of cancer
D. Lo (Hong Kong)
- 15:55 Big multicentre trials and gynecology ultrasound: how research can change clinical practice
D. Timmerman (Belgium)
- 16:20 The brave new world of therapies: gene editing and beyond
M. Norton (United States)
- 16:45 Presentation and acceptance of the Ian Donald Gold Medal 2017 to G.R. DeVore
J.A. Copel (United States)
- 16:55 Presentation and acceptance of the Ian Donald Technical Development Award 2017 to G. Ter Haar
K. Marsál (Sweden)
- 17:05 Eichmann's Jews: the Jewish administration of holocaust Vienna
D. Rabinovici (Austria); introduced by D. Prayer (Austria)

17:30-18:00

Opening ceremony

18:00-19:30

Welcome reception

HALL E

Workshop Safe ultrasound-assisted vaginal deliveries

Chairs: G. Visser (Netherlands); T.M. Eggebo (Norway)

- 13:45 Consequences of vaginal delivery
H.P. Dietz (Australia)
- 14:00 Women are designed to deliver vaginally and not by Caesarean section
G. Visser (Netherlands)
- 14:15 Assisted vaginal delivery in middle and low resource countries
T.M. Eggebo (Norway)
- 14:30 Is it important to know fetal position?
T. Ghi (Italy)
- 14:45 Ultrasound-assessed fetal station before vacuum extraction
T.M. Eggebo (Norway)
- 15:00 Discussion

HALL F

Workshop

New approaches to fetal growth: which charts should I use?

*Chairs: S. Campbell;
J. Thornton (United Kingdom)*

- 13:45 International standards ensuring continuity of care from conception to infancy
A.T. Papageorghiou (United Kingdom)
- 14:00 The World Health Organization fetal growth charts: a multinational longitudinal study
T. Kiserud (Norway)
- 14:15 The rationale for a customised approach for assessment of fetal growth and birthweight
J. Gardosi (United Kingdom)
- 14:30 Size charts versus growth velocity versus functional parameters: understanding limitations of our tests
G. Smith (United Kingdom)
- 14:45 Discussion

HALL B

Workshop

MRI: it's not just for heads anymore!

*Chairs: D. Prayer (Austria);
S. Lajfer-Narin (United States)*

- 13:45 Fetal body MRI
D. Prayer (Austria)
- 14:05 Spectrum of fetal teratomas head to toe
S. Lajfer-Narin (United States)
- 14:25 Congenital heart disease: where to look with MRI
G. Kasprjan (Austria)
- 14:45 MRI in genitourinary malformations
A.E. Millischer (France)

ROOM L3 / L6

Workshop (13:00-16:30)

World Association for Trainees in Obstetrics and Gynecology (WATOG)



Chairs: P. Gabor (France)

- 13:00 Gynecological ultrasound in the ER: what to look for?
O. Ami (France)
- 13:30 Biometry, biophysical profile and Doppler: for everyday needs
O. Ami (France)
- 14:00 Basic plans of the first trimester scan: how to get a correct plan for the CRL and the NT
P. Gabor (France)
- 14:30 Basic plans of the second trimester scan: explanation of anatomical references and the position of plans compared to each other
P. Gabor (France)
- 15:00 Coffee break
- 15:30 Twins: how not to get lost between them
K. Dimassi (Tunisia)
- 16:00 Ultrasound in the delivery room: how can it be useful?
K. Dimassi (Tunisia)

ULTRASOUND

in Obstetrics & Gynecology

Upgrade your membership for an annual subscription to ***Ultrasound in Obstetrics and Gynecology (UOG)***, the Society's official Journal and the leading peer reviewed Journal in its field.



Collect your **FREE** printed journal!

How to upgrade:

- During the Congress at the registration desk
- Online at www.isuog.org by logging into your membership account

Upgrade for only £60 for online access and £140 for both an online and print subscription.

UOG includes a stimulating mixture of original research articles, opinions and reviews on a broad range of subjects related to imaging in maternal-fetal medicine and gynecology.

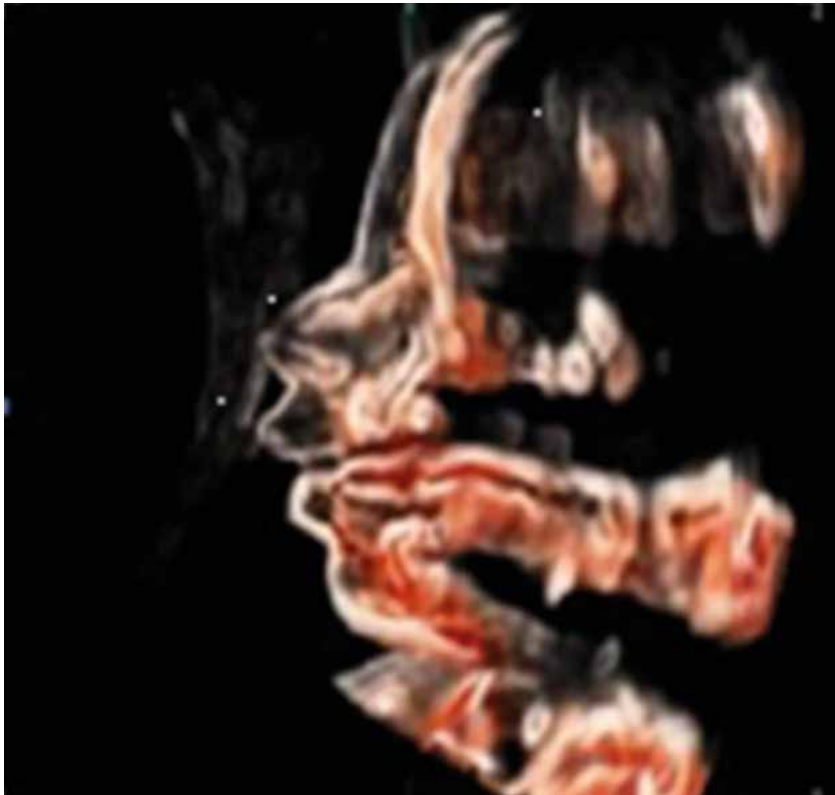

Visit the **ISUOG lounge** to receive a **FREE** print copy, download the app and learn more about UOG.

 **isuog**.org

SCIENTIFIC PROGRAM

Sunday 17 September 2017



SUNDAY

Fetal facial profile with Crystal Vue - Dall'Asta A, Paramasivam G, Lees CC. Qualitative evaluation of Crystal Vue rendering technology in assessment of fetal lip and palate. *Ultrasound Obstet Gynecol* 2017; 49: 549–552.

Sunday 17.09.2017

HALL A

07:30-08:10

Masterclass

Screening and prevention of stillbirth: possibilities and pitfalls
G. Smith (United Kingdom)

08:15-09:15

Fetal growth: consequences of being too big or too small

Chairs: A.T. Papageorghiou (United Kingdom); E. Krampfl-Bettelheim (Austria)

- 08:15 **LIVE SCAN:** updates – optimal evaluation of fetal growth and size [industry supported*]
W. Lee (United States)
- 08:35 **OC02.01** Short-term fetal cardiovascular effects of maternal betamethasone versus dexamethasone: nested study from the blinded, randomised A*STEROID trial
A. Henry (Australia)
- 08:43 **OC02.03** Distal right coronary arterial flow in growth-restricted fetuses: a feasible sign of heart-sparing effect with reserved heart function?
S. Miyashita (Japan)
- 08:51 **OC02.04** Small head circumference at the 2nd trimester anomaly scan following a normal 1st trimester screening: association to chromosomal anomalies and adverse outcome
N. Lund (Denmark)
- 08:59 **OC02.05** MR-based brain volumetry in fetuses with congenital diaphragmatic hernia
F. Prayer (Austria)
- 09:07 **OC02.02** Cardiometabolic biomarkers are associated with fetal overgrowth and adiposity
C.M. O'Brien (Australia)

HALL E

Masterclass

The heart of the matter (Ian Donald Gold Medal lecture)
G.R. DeVore (United States)



Fetal heart: what's new

Chairs: J.A. Copel (United States); K. Marsál (Sweden)

- 08:15 **INVITED:** Fetal heart: just images
R. Chaoui (Germany)
- 08:35 **OC03.01** Abnormal cardiovascular 24-segment sphericity index of the right and left ventricles in fetuses with growth restriction
G.R. DeVore (United States)
- 08:43 **OC03.02** Prenatal detected isolated right aortic arch: insignificant or significant knowledge?
V. Gjørup (Denmark)
- 08:51 **OC03.03** Annular plane systolic excursion z-score in evaluation of heart systolic function of fetus with heart failure
X. Guo (China)
- 08:59 **OC03.04** Fetal cardiac tumour: genomic sequencing, echocardiography characteristics, clinical manifestations and outcomes
S. Ge (United States)
- 09:07 **OC03.05** Mitochondrial toxicity and fetal cardiac remodelling in HIV-infected pregnancies
F. Crispi (Spain)

HALL F

Masterclass

Evaluating the endometrium from fertility to menopause

T. Van den Bosch (Belgium)

Imaging, reproductive medicine and IVF

*Chairs: C. Brezinka (Austria);
N.J. Raine-Fenning (United Kingdom)*

- 08:15 **INVITED:** What is the prevalence and clinical relevance of adhesions and other focal intrauterine pathology?
D. Jurkovic (United Kingdom)
- 08:35 **OC04.01** Endometrial biopsy prior to IVF impacts on the ultrasound appearance of the endometrium at oocyte retrieval
L. Polanski (United Kingdom)
- 08:43 **OC04.02** Follicular flushing does not improve pregnancy rates in women undergoing oocyte retrieval for IVF: a systematic review and meta-analysis
W.P. Martins (Brazil)
- 08:51 **OC04.03** The effect of melatonin on ultrasound markers of follicular development: a double-blind placebo-controlled randomised trial
F. da Silva Costa (Australia)
- 08:59 **OC04.04** Septate uterus by ESHRE-ESGE and ASRM classification: association with infertility and previous miscarriage
A. Ludwin (Poland)
- 09:07 **OC04.05** Pelvic ultrasonography of patients awaiting uterine transplantation: the UK cohort
S. Saso (United Kingdom)

HALL B

Masterclass

What RCT's can and can't tell us

J. Thornton (United Kingdom)

HALL A

09:20-10:00

Short oral presentation (OP)

OP01 Placental and maternal factors in IUGR
*Chairs: F. Figueras (Spain);
L. Impey (United Kingdom)*

09:50-10:20

Coffee and e-poster viewing

10:20-11:20

Fetal structural abnormalities

Chairs: G. Yeo (Singapore); H. Steiner (Austria)

- 10:20 **LIVE SCAN:** how I perform a mid-trimester scan [industry supported*]
K.O. Kagan (Germany)
- 10:40 **OC05.01** Malformation or acquired lesion?
D. Covini (Argentina)
- 10:48 **OC05.02** Fetal urine biochemistry in prediction of long-term (10–30 years of age) postnatal renal function in posterior urethral valves
Y. Ville (France)
- 10:56 **OC05.03** Comparison of biochemistry analysis in fetal serum and fetal urine in the prediction of postnatal renal outcome in low urinary tract obstruction
J. Stirnemann (France)
- 11:04 **OC05.04** Phenotypical spectrum of four antenatal diagnosed cases of MOPD type 1
S. Wavrant (Canada)
- 11:12 **OC05.05** Prenatal diagnosis by ultrasound and amniocentesis in a single centre cohort of 1065 pregnancies complicated by maternal toxoplasma infection
L. Masini (Italy)

HALL E

Short oral presentation (OP)

OP02 Fetal cardiac function
Chairs: P. Acharya (India); S. Yagel (Israel)

Coffee and e-poster viewing

★ Brain anomalies: challenges in diagnosis and counselling

Chairs: A. Toi (Canada); E. Hafner (Austria)

- 10:20 **ROLE PLAY:** counselling of corpus callosum agenesis in practice
*Counsellor: L.D. Platt (United States)
Father & Mother: A. Toi; D. Pugash (Canada)*
- 10:40 **OC06.01** Development of normal fetal brain structures: international standards based on ultrasound measurements from the INTERGROWTH-21st Project
Y. Donadono (United Kingdom)
- 10:48 **OC06.02** Prenatal diagnosis of brainstem anomalies: phenotypic spectrum and neuroimaging features
K.K. Haratz (Israel)
- 10:56 **OC06.03** Reduced hippocampal volume in human fetal brains with agenesis of the corpus callosum revealed by magnetic resonance imaging
G. Kasprjan (Austria)
- 11:04 **OC06.04** MRI appearances of fetal temporal lobe abnormalities in skeletal dysplasias
C. Mitter (Austria)
- 11:12 **OC06.05** Termination of pregnancy for central nervous system (CNS) anomalies
W. Dendas (Belgium)

HALL F

Short oral presentation (OP)

OP03 Using ultrasound to solve old and diagnose new problems in reproductive medicine

*Chairs: C. Brezinka (Austria);
N.J. Raine-Fenning (United Kingdom)*

Coffee and e-poster viewing

Workshop (10:20-12:00)

Using ultrasound to help manage oncology patients

*Chairs: C. Fotopoulou (United Kingdom);
A.C. Testa (Italy)*

- 10:20 Ultrasound as a key imaging modality in the management of all gynecologic cancers
A.C. Testa (Italy)
- 10:40 To what extent does imaging make a difference to the oncology surgeon?
C. Fotopoulou (United Kingdom)
- 11:00 Imaging cervical and endometrial cancer – which modality and how imaging informs management
E. Epstein (Sweden)
- 11:20 How I use ultrasound to manage patients with ovarian cancer?
D. Fischerová (Czech Republic)
- 11:40 Discussion around two cases selected by Epstein and Fischerová
E. Epstein (Sweden)

HALL B

Short oral presentation (OP)

- ★ **OP04** Fetal anomalies: from the diaphragm up
*Chairs: A. Odibo (United States);
P. Sladkevicius (Sweden)*

Coffee and e-poster viewing

Short oral presentation (10:20-11:00)

- ★ **OP05** Ultrasound meets MRI: form and function
*Chairs: R. Abu-Rustum (Lebanon);
W. Lee (United States)*

HALL A

11:25-12:05 Short oral presentation (OP)

OP06 Fetal growth: anatomy and measurements

*Chairs: E.A. Hernandez-Andrade;
A. Odibo (United States)*

12:00-13:30 Lunch and e-poster viewing

12:15-13:15 Industry sponsored satellite symposia**

13:30-14:30

Workshop

Fetal echocardiography: complexity made simple

Chairs: R. Romero; L. Yeo (United States)

13:30 **LIVE SCAN:** FINE: novel features with value in clinical practice [industry supported*]
L. Yeo (United States)

13:45 Interactive case examples
Y. Ville (France)

13:55 Tips and tricks of acquiring a good STIC of the fetal heart
L. Yeo (United States)

14:05 Clinical implementation of the FINE method
J. Weichert (Germany)

14:15 Cases of congenital heart disease using colour Doppler FINE
R. Romero (United States)

HALL E

Short oral presentation (OP)

OP07 Hot topics around the fetal brain

Chairs: R. Chaoui (Germany); C. Mitter (Austria)

Lunch and e-poster viewing

From poor placentation to pre-eclampsia

Chairs: W. Arzt (Austria); A. Khalil (United Kingdom)

DEBATE: early screening for pre-eclampsia is a waste of money in the era of the sphygmomanometer

13:30 *For: M. Norton (United States)*

13:37 *Against: L. Hyett (Australia)*

13:44 Speaker rebuttals and voting

13:50 **OC07.01** Pre-conception maternal hemodynamics is associated with subsequent development of pre-eclampsia (PE) or intrauterine growth restriction (IUGR)
L. Foo (United Kingdom)

13:58 **OC07.02** Multicentre screening for pre-eclampsia by maternal factors and biomarkers at 11–13 weeks' gestation: comparison to NICE guidelines and ACOG recommendations
N. O'Gorman (United Kingdom)

14:06 **OC07.03** Identification of women remaining at high risk of pre-eclampsia after aspirin initiation in the first trimester of pregnancy
C. Gasse (Canada)

14:14 **OC07.04** Pregnancy outcome in women with raised uterine artery Doppler in the second trimester
A. Kaelin Agten (United Kingdom)

14:22 **OC07.05** Maternal cardiac function in patients with mild and severe pre-eclampsia compared with normal pregnant women
T. Yamada (Japan)

* Scientific content of sessions is defined by the Scientific Committee; ultrasound systems and technical support are provided by sponsors.

**Lunchtime satellite symposia are brought to you by our sponsors and are not part of the ISUOG CME program. ISUOG takes no responsibility for scientific or clinical content. Please see page 158 for our satellite program.

HALL F

Lunch and e-poster viewing

Miscarriage, ectopic pregnancy, PUL and other complications in early pregnancy

*Chairs: B. Van Calster (Belgium);
T. Bourne (United Kingdom)*

- 13:30 **INVITED:** How do we advise women with pain and bleeding in early pregnancy regarding the immediate and long-term outcome of the pregnancy?
M. Al-Memar (United Kingdom)
- 13:42 **OC08.01** Evaluating the ultrasound diagnostic criteria for non-viable first trimester pregnancies
M. Atri (Canada)
- 13:50 **OC08.02** Ultrasound diagnosis of molar pregnancy
A.M. Unipan (United Kingdom)
- 13:58 **OC08.03** A randomised controlled trial comparing misoprostol to expectant care in early pregnancy failure
A. Fernlund (Sweden)
- 14:06 **OC08.04** Local versus systemic methotrexate in uterine ectopic pregnancies
S. Schwab (Austria)
- 14:14 **OC08.05** Rates of spontaneous pregnancy loss and ovulation-implantation interval within a prospective pre-conception cohort
L. Foo (United Kingdom)
- 14:22 ^{YI}**OC08.06** Association of vaginal microbiota composition and outcomes in women found to have a pregnancy of unknown location (PUL) on an initial early pregnancy ultrasound scan
S. Bobdiwala (United Kingdom)

HALL B

Short oral presentation (OP)

OP08 Ultrasound and genetics
*Chairs: L. Hui (Australia);
L. Wilkins-Haug (United States)*

Lunch and e-poster viewing

^{YI} This presentation is eligible for the Young Investigator award (to be presented in the closing plenary).

HALL A

14:35-15:15

Short oral presentation (OP)

OP09 Detection of fetal heart anomalies I
Chairs: *J.S. Carvalho (United Kingdom);
E. Mlczoch (Austria)*

15:10-15:40

Coffee and e-poster viewing

15:40-17:00

Workshop

IUGR management after the TRUFFLE trial: key messages

Chairs: *G. Visser (Netherlands); T. Frusca (Italy)*

- 15:40 Overview
G. Visser (Netherlands)
- 15:55 Is MCA useful in severe early onset FGR?
E.A. Hernandez-Andrade (United States)
- 16:05 How is monitoring best achieved before 32 weeks?
K. Hecher (Germany)
- 16:15 Fetal heart monitoring: STV versus PRSA
S. Lobmaier (Germany)
- 16:25 Do steroids affect Dopplers and CTG?
C. Lees (United Kingdom)
- 16:35 Putting TRUFFLE in perspective
C. Lees (United Kingdom)
- 16:50 Discussion

HALL E

Short oral presentation (OP)

OP10 Babies born too early or too small
Chairs: *H. Feltovich (United States);
C. Wohlmutz (Austria)*

Coffee and e-poster viewing

Workshop

Abnormally invasive placenta

Chairs: *L.J. Salomon (France);
F. Chantraine (Belgium)*

- 15:40 Optimal utilisation of ultrasound: when and which signs?
S. Collins (United Kingdom)
- 15:55 Improving detection using MRI: does contrast add benefit?
A.E. Millischer (France)
- 16:10 A "centre of excellence" approach: how to set it up and what are the hurdles?
A. Bhide (United Kingdom)
- 16:25 I just opened this patient and found an unsuspected accreta: what shall I do?
A. Abuhamad (United States)
- My answer in 5 minutes:**
- 16:40 Planned Caesarean hysterectomy in these women
I. Timor-Tritsch (United States)
- 16:45 How to manage placenta accreta: just leave it all in
L. Sentilhes (France)
- 16:50 How to manage placenta accreta: take the placenta out but leave the uterus in
A. Bhide (United Kingdom)
- 16:55 Audience Q&A

HALL F

Short oral presentation (OP)

OP11 Complications in early pregnancy: using imaging and biomarkers to provide new insights

*Chairs: E. Kirk (United Kingdom);
I. Timor-Tritsch (United States)*

Coffee and e-poster viewing

Workshop

The future of ultrasound for the detection of CNS anomalies after the MERIDIAN trial

*Chairs: G. Malinge (Israel);
M. Sanz Cortes (United States)*

- 15:40 The MERIDIAN study in the eyes of the radiologist
Speaker to be confirmed
- 16:00 The MERIDIAN study in the eyes of the ultrasonologist
D. Paladini (Italy)
- 16:20 Why I don't need MRI in my practice
G. Malinge (Israel)
- 16:40 The additional value of MRI in current clinical practice
M. Sanz Cortes (Spain)

HALL B

Short oral presentation (OP)

OP12 Screening
*Chairs: M. Herrera (Colombia);
J. Miller (United States)*

Coffee and e-poster viewing

Workshop

Difficult problems in early pregnancy: PUL, enhanced myometrial vascularity, diagnosing and managing Caesarean scar pregnancy

*Chairs: G. Condous (Australia);
T. Bourne (United Kingdom)*

- 15:40 Do we scan too many women too early? A practical validated approach to managing women with pregnancy of unknown location
S. Bobdiwala (United Kingdom)
- 15:55 What should we do when we find enhanced myometrial vascularity?
T. Van den Bosch (Belgium)
- 16:10 Diagnosing Caesarean scar pregnancy: over the scar; into the scar? Can we link ultrasound features to prognosis yet?
I. Timor-Tritsch (United States)
- 16:25 Managing Caesarean scar pregnancy: is this a surgical problem in all cases?
D. Jurkovic (United Kingdom)
- 16:40 Case discussions
All speakers

Hubs

HUB 1

08:15-09:15

Interactive

In conversation with *B. Benacerraf*:
Gynecology cases: tips and tricks

09:20-10:00

Poster discussion (P)

P01: Preterm birth: maternal and fetal assessment
Chair: H. Feltovich (United States)

10:20-11:20

Interactive

In conversation with *M. Blanchette Porter*:
How do I use ultrasound to assess women with abnormal uterine bleeding?

11:25-12:05

Poster discussion (P)

P04: Ultrasound in the labour ward I
Chair: A. Gagnon (Canada)

12:20-13:20

Interactive

In conversation with *A. Testa*:
Diagnosing less common types of ovarian tumour

13:30-14:30

Interactive

In conversation with *H.P. Dietz*:
How to examine the pelvic floor with ultrasound

14:35-15:15

Poster discussion (P)

P08: Fetal growth
Chair: G. Rizzo (Italy)

15:40-16:40

HUB 2

Poster discussion (P)

★ P02: New tools to evaluate the fetal brain and CNS
Chair: J. Deng (United Kingdom)

Interactive

WATOG: In conversation with trainees:
Exploring the doctor patient relationship
Moderator: P. Gabor (France)
Opinion leaders: A. Gagnon (Canada); N. Vrachnis (Greece); O. Ami (France); Y. Copado Mendoza (Mexico); K. Dimassi (Tunisia)

Poster discussion (P)

P05: Pre-eclampsia
Chair: L. Poon (Hong Kong)

Interactive

Join the conversation: ISUOG and FIGO—what is the trouble with established techniques and technologies in underserved regions?
Moderators: T.M. Eggebo (Norway); G. Visser (Netherlands)
Opinion leaders: H. Feltovich (United States); A. Abuhamad (United States); S. Eik-Nes (Norway)

Interactive

In conversation with FIGO: Can we improve political will in Outreach?
Moderator: G. Di Renzo (Italy); A. Johnson (United States)
Opinion leaders: G. Visser (Netherlands); Y. Ville (France); R. Abu-Rustum (Lebanon); T. Eggebo (Norway); T. Pepera-Hibbert (United Kingdom)

Poster discussion (P)

P09: Head, neck and bones
Chair: P. Acharya (India)

Interactive

Patientenselbsthilfegruppen und gynaekologischer Ultraschall – ein Austausch
Moderator: C. Brezinka (Austria)



HUB 3**Interactive**

Special interest group (SIG): Doppler
Chair: C. Lees (United Kingdom)

Poster discussion (P)

P03: Clinical consequences of abnormal placentation
Chair: B. Tutschek (Switzerland)

Interactive

Special interest group (SIG): MRI
Chair: G. Maligner (Israel)

Poster discussion (P)

P06: Fetal echocardiography I
Chair: J.S. Carvalho (United Kingdom)

Interactive

Special interest group (SIG) 3D
Chair: J. Deng (United Kingdom)

Interactive

Join the conversation: Aspirin in pre-eclampsia
Moderator: F. da Silva Costa (Australia)
Opinion leaders: L. Poon (Hong Kong); E. Bujold (Canada)

Poster discussion (P)

P10: Placenta, umbilical cord and amniotic fluid
Chair: T. Cohen-Overbeek (Netherlands)

HUB 4**Flim launch**

The principles of ultrasound imaging

Interactive

The gynecology oncology case discussion meeting: oncology surgeons and ultrasound specialists discuss cases where imaging impacts management decisions
Moderators: A.C. Testa (Italy); E. Epstein (Sweden)

Flim launch

The principles of ultrasound imaging

Poster discussion (P)

P07: Using ultrasound in urogynecology patients
Chair: A. Youssef (Italy)

Interactive

In conversation with *B. Van Calster* and
J. Stirnemann: Statistics for clinical fellows

Interactive

Join the conversation: How to properly design a study
*Moderators: G. Smith (United Kingdom);
 J. Thornton (United Kingdom);
 A. Odibo (United States)*

Poster discussion (P)

P11: Using ultrasound to characterise and help manage ovarian masses: experience of using the IOTA ADNEX model and simple rules
Chairs: T. Bourne (United Kingdom); D. Timmerman (Belgium)

Flim launch

The principles of ultrasound imaging
 (collaboration of MAF & ISUOG)

OP - Sunday 17.09.2017

OP01: Placental and maternal factors in IUGR

Hall A

Chairs: F. Figueras (Spain); L. Impey (United Kingdom)

- Abnormal cerebroplacental (CPR) and cerebrenal (CRR) Doppler indices in fetuses with small abdominal circumference OP01.01
S. Contag (United States)
- Placenta-derived exosomes in pregnancies complicated with fetal growth restriction at term OP01.02
J. Miranda (Spain)
- Placental histology and sFlt-1/PIGF ratio in intrauterine growth restriction OP01.03
F. Fuse (Italy)
- Birthweight differences at term are explained by the gender, gestational age and placental dysfunction, but not by ethnicity OP01.04
J. Morales-Roselló (Spain)
- Reduced third trimester growth velocity in appropriate-for-gestational-age fetuses is associated with multiple indicators of placental insufficiency OP01.05
T.M. MacDonald (Australia)
- Prediction value of cerebral placental ratio for mode of delivery can be changed and improved using different classification criteria methods OP01.06
E. Zohav (Israel)
- Maternal hemodynamic in hypertensive disorders and different fetoplacental growth patterns, in pregnancy and postpartum OP01.07
F. Fuse (Italy)
- Prenatal stress modifies RNA expression of HSD11 β 2 and the hypothalamic-pituitary-adrenocortical axis in fetal growth restriction OP01.08
J. Miranda (Spain)
- Prediction of birthweight in SGA at 11–13+6 weeks using maternal history, LMP, ultrasound and biochemistry OP01.09
J. Stirnemann (France)
- WITHDRAWN OP01.10
- Maternal hemodynamic in pregnancies complicated by intrauterine growth restriction and hypertensive disorders OP01.11
T. Izzo (Italy)

OP02: Fetal cardiac function

Hall E

Chairs: P. Acharya (India); S. Yagel (Israel)

- Evaluation of ventricular function in fetus with Ebstein's anomaly by velocity vector imaging OP02.01
M. Xie (China)
- 24-segment transverse ventricular fractional shortening: a new technique to evaluate fetal cardiac function OP02.02
- G.R. DeVore (United States)*
- Quantile score: a new reference system for fetal echocardiography from a large multicentre study OP02.03
S. Ge (United States)
- Aortic coarctation: biventricular functional pattern in the third trimester of pregnancy OP02.04
F. Crispi (Spain)
- Ventricular remodelling in fetuses with aortic coarctation OP02.05
F. Crispi (Spain)

Evaluation of multi-modality, global fetal cardiac function assessment in pregnancies complicated with IUGR, TTTS and sIUGR <i>H. Avnet (Australia)</i>	OP02.06
Myocardial ventricular performance in normal fetuses at 11–38 weeks of gestation: comparison between speckle-tracking and traditional echocardiography <i>M. Bellotti (Italy)</i>	OP02.07
WITHDRAWN	OP02.08
Fetal cardiac function and exercise during pregnancy <i>M. Brik (Spain)</i>	OP02.09
Factor analysis on reverse flow phenomenon in aortic isthmus by fetal echocardiography <i>S. Ge (United States)</i>	OP02.10
Congenital heart disease and the placenta: is hypoxia affecting the placenta? <i>E. Mlczoch (Austria)</i>	OP02.11

OP03: Using ultrasound to solve old and diagnose new problems in reproductive medicine

Hall F

Chairs: C. Brezinka (Austria); N.J. Raine-Fenning (United Kingdom)

09:20-09:36 What ultrasound tells us about a women's reproductive function

N. Raine-Fenning (United Kingdom)

INVITED

Time-lapse embryo incubation and/or selection for improving the reproductive outcomes: a systematic review and meta-analysis

W.P. Martins (Brazil)

OP03.01

Ultrasonographic findings related to insulin resistance in patients with polycystic ovarian syndrome

S. Guerriero (Italy)

OP03.02

3D-TVS criteria to diagnose t-shaped uterus

E. Leone (Italy)

OP03.03

A randomised control trial on the retention of intrauterine copper contraceptive device following postplacental and interval insertion

T. Dias (Sri Lanka)

OP03.04

Ovarian response to the gonadotropins during IVF or ICSI cycles in patients with presence of deep infiltrating endometriosis based on ultrasonography

S. Guerriero (Italy)

OP03.05

HyoSy by using the new ultrasound contrast agent lignosal (mixture of 2% lignocaine jelly and saline) for the evaluation of tubal patency

N. Chegondi (India)

OP03.06

OP04: OP: Fetal anomalies: from the diaphragm up

Hall B

Chairs: A. Odibo (United States); P. Sladkevicius (Sweden)

Interobserver variability of sonographic lung size measurement in congenital diaphragmatic hernia (CDH) across the NAFTA* FETO Consortium

N. Abbasi (Canada)

OP04.01

Congenital diaphragmatic hernia and diaphragmatic eventration: separate entities or two sides of the same coin?

L. De Catte (Belgium)

OP04.02

Prenatal prediction of extracorporeal membrane oxygenation requirement in patients with congenital diaphragmatic hernia

J.L. Miller (United States)

OP04.03

Prenatally diagnosed fetal congenital cystic adenomatoid malformation (CCAM) and bronchopulmonary sequestration (BPS) showed excellent survival and prognosis: a 10-year review in a tertiary hospital <i>H. Yi (Republic of Korea)</i>	OP04.04
Variation of fetal lung size in congenital diaphragmatic hernia (CDH): biology or measurement error? <i>J.L. Miller (United States)</i>	OP04.06
Congenital lobar emphysema: how colour Doppler can help to reach the diagnosis <i>M. Brasseur-Daudray (France)</i>	OP04.07
Charts of fetal brain structures: a systematic review of methodological quality <i>V. Donadono (United Kingdom)</i>	OP04.08
4D ultrasound assessment of facial expressions and their reproducibility in the third trimester <i>M.A. AboEllail (Japan)</i>	OP04.09
WITHDRAWN	OP04.10
Prenatal diagnosis of a congenital lung deformity: horseshoe lung <i>M. Xie (China)</i>	OP04.11

OP05: Ultrasound meets MRI: form and function

Chairs: R. Abu-Rustum (Lebanon); W. Lee (United States)

Measurement of fetal urine production using three dimensional ultrasonography rotational technique (VOCALTM) in normal pregnancy <i>A. Rossi (Italy)</i>	OP05.01
Reproducibility of virtual reality and three-dimensional power Doppler ultrasound measurements for non-invasive assessment of periconceptual utero(placental) vascularisation <i>I.F. Reijnders (Netherlands)</i>	OP05.02
Sonographic assessment of normal fetal uterus using three-dimensional imaging: a new technique <i>F. Grosjean (France)</i>	OP05.03
Cross-sectional comparison of two techniques for the non-invasive measurement of cardiac output in and outside pregnancy <i>G. Masini (United Kingdom)</i>	OP05.04
New advances in fetal cardiovascular magnetic resonance imaging <i>L. Sun (China)</i>	OP05.05
Ultrasonic fetal and placental tissue characterisation in lung maturity in pre-eclamptic and diabetic patients <i>M. Podobnik (Croatia)</i>	OP05.06
Prediction and utility of neonatal respiratory morbidity by quantitative lung texture analysis in pregnancies at risk for preterm/early term delivery <i>A. Khurana (India)</i>	OP05.07
Novel placental evaluation using multimodal MRI <i>R. Pratt (United Kingdom)</i>	OP05.08
Grading the fetal echogenic bowel (EB): correlation between quantitative computerised gray-scale analysis and subjective qualitative evaluation <i>L. Maggia (Netherlands)</i>	OP05.09
Fetal magnetic resonance imaging (MRI) versus 3D ultrasonography (3D-US) in assessment of fetal lung volumes in cases at risk of pulmonary hypoplasia <i>M.R. Louis (Egypt)</i>	OP05.10
Artefacts: reality in 3D/4D ultrasound examination of the fetus <i>D. Miric Tesanic (Croatia)</i>	OP05.11

Hall B

OP06: Fetal growth: anatomy and measurements**Hall A**

Chairs: E.A. Hernandez-Andrade; A. Odibo (United States)

- Fetal longitudinal growth assessment and perinatal outcome after suspected preterm labour
L. Gabasa (Spain) OP06.01
- Three-dimensional automated measure of the fetal thigh in high-risk pregnancies to predict fetal weight
T. Izzo (Italy) OP06.02
- Distribution of highly oxygenated umbilical flow in normal human fetuses through the ductus venosus (DV) between 11 and 14+6 weeks of gestation
M. Bellotti (Italy) OP06.03
- US anatomy of the middle and inner ear with high frequency probe: a pictorial essay
M. Brasseur-Daudruy (France) OP06.04
- Clinical impact of using different normal ranges for amniotic fluid index
S. Vannuccini (United Kingdom) OP06.05
- Fetal liver portal venous perfusion in severe growth-restricted fetuses
N. Gilad (Israel) OP06.06
- WITHDRAWN OP06.07
- Investigation of fetal growth restriction genetic cause with SNP array
E. Yang (China) OP06.08
- First trimester fetal anatomy assessment from a single 3D volume
E. Pavlova (Bulgaria) OP06.09
- The association between suboptimal fetal abdominal circumference growth velocity and adverse neonatal outcome in appropriate-for-gestational-age neonates
M. Hendrix (Netherlands) OP06.10
- External genitalia exploration: feasibility study of a second trimester systematic ultrasound based on the exploration of the labioscrotal folds fusion
M. Massoud (France) OP06.11

OP07: Hot topics around the fetal brain**Hall E**

Chairs: R. Chaoui (Germany); C. Mitter (Austria)

- Fetal neurosonography vs magnetic resonance imaging: comparing their accuracy in diagnosing brain anomalies with respect to neuropsychiatric outcome
C. Casato (Italy) OP07.01
- The relationship between the posterior fossa structures and foramen magnum using the occipitum-dens line (ODL) in following fetal surgery for myelomeningocele
E.Q. Barreto (Brazil) OP07.02
- Fetuses with congenital heart disease display normal cerebral volume growth
E.A. Jansen (Netherlands) OP07.03
- Functional ultrasound evaluation in fetuses with myelomeningocele: a preliminary study
L. De Catte (Belgium) OP07.04
- Bilateral periventricular nodular heterotopia (BPNH) as detected on fetal and maternal MRI, caused by a previously undescribed Filamin A mutation
S. Stoecklein (Germany) OP07.05
- Role of prenatal MRI in the prediction of long-term outcome of fetuses with isolated agenesis of the septum pellucidum
L.J. Salomon (France) OP07.06
- Fetal cerebral hemorrhage: a multicentre case series and update of classification and counselling
E. Carrea (Spain) OP07.07
- Preoperative neurosonography in neonates with prenatally detected congenital heart defects
E.A. Jansen (Netherlands) OP07.08

Fetal akinesia deformation sequence: is motor assessment of additional value for <i>in utero</i> diagnosis? A ten-year cohort study <i>J. Tjon (Netherlands)</i>	OP07.09
Neurosonographic evaluation of corpus callosum and cortical development in small-for-gestational age and growth-restricted fetuses <i>J. Miranda (Spain)</i>	OP07.10
CSP dilation in mid-trimester fetuses with DiGeorge syndrome: a case-control study <i>C. Pylypjuk (Canada)</i>	OP07.11

OP08: Ultrasound and genetics**Hall B**

Chairs: L. Hui (Australia); L. Wilkins-Haug (United States)

Cytogenetic analysis in fetuses with late onset abnormal sonographic findings <i>R. Bardin (Israel)</i>	OP08.01
The value of genetic testing and morphological examination in children with gastroschisis <i>C.C. Lap (Netherlands)</i>	OP08.02
The prenatal diagnosis of volvulus in a fetus with congenital diarrhoea (CD) probably associated with a GUCY2C gene variant <i>I. Clemens (Norway)</i>	OP08.03
Pregnancy outcome for fetuses with increased nuchal translucency ≥ 3.5 mm but normal karyotype and CMA <i>C. Votino (Italy)</i>	OP08.04
Prenatal diagnosis of Smith–Magenis syndrome in fetus with mild unilateral borderline ventriculomegaly: a case report <i>A. Yulia (United Kingdom)</i>	OP08.05
Is aberrant right subclavian artery in fetuses a risk factor for microscopic and submicroscopic chromosomal aberrations? <i>S. Ran (Israel)</i>	OP08.06
Chromosomal disorders in congenital anomalies of the kidney and the urinary tract <i>V. Borobio (Spain)</i>	OP08.07

OP09: Detection of fetal heart anomalies I**Hall A**

Chairs: J.S. Carvalho (United Kingdom); E. Mlczoch (Austria)

<i>In utero</i> therapy for fetal heart block: UCLH, London experience <i>A. Yulia (United Kingdom)</i>	OP09.01
Prenatal detection of congenital heart defects by sonographers on routine ultrasound examination in second trimester of pregnancy <i>P. Sladkevicius (Sweden)</i>	OP09.02
CASSEAL: fetal cardiovascular system sonographic evaluation algorithm – multicentric study on its feasibility for prenatal diagnosis <i>C. Bravo (Spain)</i>	OP09.03
Diagnostic options for detailed examination of the fetal heart in the first trimester: what we have learned so far – critical view on conventional and volumetric approaches in >170 cases <i>J. Weichert (Germany)</i>	OP09.04
Detection of isolated major congenital heart defects at 11–13 weeks' scan in fetuses with normal anatomy and normal nuchal translucency <i>E.S. Nekrasova (Russian Federation)</i>	OP09.05
Residual diagnoses of major congenital heart defects by routine 30–34+6 weeks' ultrasound <i>J. Stirnemann (France)</i>	OP09.06
Improving fetal cardiac assessment using 5DHeart™ technique: from beginner to expert <i>M. A. Gembicki (Germany)</i>	OP09.07

Characterisation of subtypes of isolated ventricular septal defects demonstrated by fetal echocardiography and their postnatal outcome <i>L. Gindes (Israel)</i>	OP09.08
Isolated aberrant right subclavian artery at 14–16 weeks of gestation, association with Down's syndrome <i>A. Shrim (Israel)</i>	OP09.09
The value of echocardiography in the diagnosis and postnatal outcome of fetal pure ventricular septal defect <i>Y. Guo (China)</i>	OP09.10
The added value of f-TAPSE in the surveillance of pregnancies complicated by fetal and placental tumours <i>S. Perlman (Israel)</i>	OP09.11

OP10: Babies born too early or too small

Chairs: H. Feltovich (United States); C. Wohlmuth (Austria)

Subclinical placental inflammation as a risk factor for impaired cognitive development in early childhood after suspected preterm labour <i>D. Oros (Spain)</i>	OP10.01
Longitudinal transvaginal ultrasound of cervical length in pregnant women with prior conisation <i>C.B. Wulff (Denmark)</i>	OP10.02
Gestational age-related changes in uterine cervical elasticity in normal pregnancy at 12–35 weeks' gestation evaluated using shear wave elastography <i>T. Horinouchi (Japan)</i>	OP10.03
Assessment of cervical elastography strain pattern and its association with preterm birth <i>R. Schmitz (Germany)</i>	OP10.04
Pulmonary artery acceleration/ejection time as a predictor of neonatal respiratory complications in patients with preterm premature rupture of membranes <i>J.R. Duncan (United States)</i>	OP10.05
Prediction of preterm birth and small-for-gestational-age neonates by fetal biometry at 19–24 gestational weeks <i>M. Kim (Republic of Korea)</i>	OP10.06
Worsening of the uterine artery Doppler is independently associated with fetal redistribution <i>C.A. Monaghan (United Kingdom)</i>	OP10.07
How good are we in predicting low birthweight with third trimester ultrasound scan? <i>K.M. Maksym (United Kingdom)</i>	OP10.08
Ischemia-modified albumin in pregnancy <i>A. Rossi (Italy)</i>	OP10.09
Longitudinal change in the cerebroplacental ratio in pregnancies with small-for-gestational-age fetuses complicated by stillbirth and perinatal death <i>A. Khalil (United Kingdom)</i>	OP10.10

OP11: Complications in early pregnancy: using imaging and biomarkers to provide new insights

Chairs: E. Kirk (United Kingdom); I. Timor-Trisch (United States)

Outcome of ectopic uterine pregnancy (EUP) treated with methotrexate (MTX) associated with uterine artery embolisation (UAE) <i>D.G. Iliescu (Romania)</i>	OP11.01
Endometrial thickness and its value in triaging women with a pregnancy of unknown location <i>S. Bobdiwala (United Kingdom)</i>	OP11.02

Hall E

Hall F

Smaller than expected early Crown–rump length: does it predict the occurrence of early miscarriage in singleton pregnancies conceived by IVF? <i>L. Martins (Portugal)</i>	OP11.03
Should the beta hCG threshold level for ultrasound in the diagnosis of tubal ectopic pregnancies be abolished? <i>L. Polanski (United Kingdom)</i>	OP11.04
Predictors of the successful expectant management of tubal ectopic pregnancy <i>H. Fourie (United Kingdom)</i>	OP11.05
Diagnostic protocols for the management of pregnancy of unknown location (PUL): a systematic review and meta-analysis <i>S. Bobdiwala (United Kingdom)</i>	OP11.06
The natural history of pregnancy-related enhanced myometrial vascularity (EMV) <i>K. Grewal (United Kingdom)</i>	OP11.07
The management of recurrent ectopic pregnancy: a multi-centre observational study <i>H. Fourie (United Kingdom)</i>	OP11.08
Treatment strategies of fetal heart beat (FHB)-positive Caesarean scar pregnancy (CSP) <i>T. Hoshino (Japan)</i>	OP11.09

OP12: Screening

Chairs: M. Herrera (Colombia); J. Miller (United States)

Ultrasonographic detection of fetal malformation and parental longitudinal psychological stress responses <i>A. Kaasen (Norway)</i>	OP12.01
Absent nasal bone without other features of Trisomy 21 in pregnant Caucasian women: check the clavicles for cleidocranial dysplasia <i>F. Rypens (Canada)</i>	OP12.02
To see or not to see anomalies: the nuchal translucency as a magnifying glass? <i>M. Bakker (Netherlands)</i>	OP12.03
Prenatal detection of major congenital malformations in a high-uptake population <i>A.W. Olesen (Denmark)</i>	OP12.04
Combination of early transvaginal and late second trimester ultrasound improves fetal anatomy screening in obese women <i>B. Råman (Sweden)</i>	OP12.05
Audit of gastroschisis and omphalocele in an Australian maternal-fetal medicine centre <i>D. Di Filippo (Australia)</i>	OP12.06
The prenatal diagnosis of disorders of sex development using 2D/3D ultrasonography: a 10-case experience <i>Y. Kozuma (Japan)</i>	OP12.07
Prenatal diagnosis of urinary tract anomalies: a cohort study in the northern Netherlands <i>M. Bakker (Netherlands)</i>	OP12.08
Ultrasound markers predicting complex gastroschisis and adverse outcome: a longitudinal prospective nationwide cohort study <i>C.C. Lap (Netherlands)</i>	OP12.09
Accuracy of prenatal diagnosis in infants with omphalocele <i>P. Conner (Sweden)</i>	OP12.10
Prediction of cervical changes and premature birth by cervical image pattern analysis using real-time tissue elastography <i>R. Nagai (Japan)</i>	OP12.11
Performance and errors of the first trimester (FT) extended anomaly scan: key points for the management of the scan protocol <i>D.G. Iliescu (Romania)</i>	OP12.12

Hall B

P - Sunday 17.09.2017

P01: Preterm birth: maternal and fetal assessment

L3 / L6 Hub 1

Chair: *H. Feltovich (United States)*

- Transabdominal cervical length measurements above 35mm exclude short cervix in both twin and singleton pregnancies P01.01
A. Shrim (Israel)
- WITHDRAWN P01.02
- Ultrasound assessment of cervical length and volume: comparison of transabdominal and transvaginal approach P01.03
J. Wie (Republic of Korea)
- Longitudinal assessments of the fetal adrenal gland indicates preterm birth P01.04
A. Diemert (Germany)
- Relationship between fetal thymus size and cervical length in the second trimester of pregnancy and the risk of preterm birth P01.05
A.F. Moron (Brazil)
- Effectiveness of the contemporary treatment of preterm labour: a comparison with a historical cohort P01.06
K.O. Kagan (Germany)
- Vaginal progesterone and cervical pessary for the prevention of SPB in patients with CCI \leq 5th percentile at routine ultrasound 11–13.6 weeks P01.07
M.A. Parra-Saavedra (Colombia)
- Comparison of preventive measures for preterm deliveries in twin pregnancies between pessary-progesterone and cerclage alone P01.08
C. Gulumser (Turkey)
- Uterine artery pulsatility index in pregnancies complicated by preterm premature rupture of membranes as predictor of placental vascular complications P01.09
J.R. Duncan (United States)
- The cerebroplacental ratio does not appear to predict severe neonatal outcomes in preterm premature rupture of membranes P01.10
J.R. Duncan (United States)
- Comparison between first and third trimester evaluation of uterine scar: a prospective study P01.11
K. Paquette (Canada)

P02: New tools to evaluate the fetal brain and CNS

L3 / L6 Hub 2

Chair: *J. Deng (United Kingdom)*

- Automatic evaluation of cortical folding pattern in isolated ventriculomegaly by magnetic resonance imaging P02.01
N.M. Hahner (Spain)
- Multiplane and skeletal mode of 3D ultrasound for prenatal diagnosis of vertebral deformation and closed spina bifida P02.02
L. Xie (China)
- Volumetric approach for detailed neurosonogram: diagnostic advantage or disadvantage? P02.03
J. Weichert (Germany)
- Axial and coronal views of the vermian primary fissure assist in the diagnosis of vermian dysgenesis P02.04
D. Pugash (Canada)
- Expert neurosonography versus magnetic resonance imaging in the antenatal diagnosis of cortical abnormalities: a prospective study in a high-risk population P02.05
N. Volpe (Italy)
- Feasibility of fetal 2D and 3D neurosonography in a tertiary centre P02.06
S.M. Everwijn (Netherlands)

Termination of pregnancy for midline cerebral anomalies <i>W. Dendas (Belgium)</i>	P02.07
Regression and improvement of Chiari II signs in repair of prenatal myelomeningocele <i>P.M. Gonzalez (Chile)</i>	P02.08

P03: Clinical consequences of abnormal placentation**L3 / L6 Hub 3***Chair: B. Tutschek (Switzerland)*

Validation of a clinical and sonographic-based scoring system for prenatal prediction of morbidly adherent placenta in high risk population <i>A.S. Al Sadah (Canada)</i>	P03.01
The role of ultrasound in diagnosis of placenta previa and accreta in cases after previous surgical intervention <i>S. Babloyan (Armenia)</i>	P03.02
Analysis of the antenatal ultrasonic diagnosis of placenta accreta <i>L. Wang (China)</i>	P03.03
Velamentous and marginal cord insertion and the risk of adverse pregnancy outcomes in singleton pregnancies <i>E. Cosmi (Italy)</i>	P03.04
Characteristics of fetal heart beat (FHB)-positive Caesarean scar pregnancy (CSP) and adverse effects of transarterial embolisation (TAE) therapy <i>T. Hoshino (Japan)</i>	P03.05
Pregnancy outcome and patients' characteristics with low PAPP-A <i>F. Ajibade (United Kingdom)</i>	P03.06

P04: Ultrasound in the labour ward I**L3 / L6 Hub 1***Chair: A. Gagnon (Canada)*

Intrapartum PRSA: a new method to predict fetal acidosis? <i>J. Weyrich (Germany)</i>	P04.01
Umbilical cord index in prediction of short and long umbilical cord in term pregnancy: a new ultrasonographic method <i>M. Basbug (Turkey)</i>	P04.02
What is the relationship between the cerebroumbilical ratio, operative delivery for fetal distress and time to delivery in nulliparous women? <i>S. Usman (United Kingdom)</i>	P04.03
The subpubic arch angle in nulliparous women at term of pregnancy with fetuses in breech presentation <i>N.A. Eltaweel (Egypt)</i>	P04.04
Measurement of retropubic tissue thickness using intrapartum transperineal ultrasound to assess cephalopelvic disproportion (CPD) <i>C. Chor (China)</i>	P04.05
Fetal rotation during vacuum extraction <i>B.H. Kahrs (Norway)</i>	P04.06
Sonographic assessment of fetal shoulder orientation after head delivery <i>N. Volpe (Italy)</i>	P04.07
Neonatal head circumference is not a risk factor for levator ani avulsion <i>I. Cataneo (Italy)</i>	P04.08
Intrapartum ultrasound and mode of delivery in prolonged second stage of labour <i>A. Dall'Asta (Italy)</i>	P04.09
Intrapartum measurement of the lower uterine segment thickness (LUST): defining the normal <i>R. Bardin (Israel)</i>	P04.10

P05: Pre-eclampsia**L3 / L6 Hub 2***Chair: L. Poon (Hong Kong)*

- Associations of "endothelial dysfunction" genes polymorphism in pregnancy-induced hypertension among Uzbek women: a case-control study P05.01
U. Ashurova (Uzbekistan)
- Changes in BOLD MRI in a STOX1 pre-eclamptic mouse model P05.02
H. Collinot de Chanau (France)
- Correlation between placental vascularisation indices and histological findings of placentas in pregnancy hypertension P05.03
A. Suranyi (Hungary)
- Placental histology and sFlt-1/PLGF in pregnancies complicated by hypertensive disorders P05.04
E. Fuse (Italy)
- SFlt-1/PLGF ratio in clinical practice: reassessment of cut-off values for predicting pre-eclampsia in our cohort of patients P05.05
K. Mackova (Czech Republic)
- The assessment of the role of (sFlt-1 / PLGF) ratio in pregnancy complicated by early severe pre-eclampsia P05.06
M.A. Parra-Saavedra (Spain)
- Three-dimensional power Doppler of uteroplacental vascularisation in third trimester: comparison between normal and placental insufficiency pregnancies (EVUPA study) P05.07
A. Chabot-Lecoanet (France)
- Differences in pre-pregnancy stress response between healthy and PE/FGR pregnancies P05.08
J. Man (United Kingdom)
- Uterine artery diastolic notch as risk factor for pre-eclampsia and differences of adiponectin between early onset and late onset pre-eclampsia P05.09
Y. Wati (Indonesia)
- Assessment of maternal cerebrovascular Doppler indices in pregnancies complicated by pre-eclampsia P05.10
S. Han (Republic of Korea)
- Cardiovascular function in women after experiencing a hypertensive disorder in pregnancy P05.11
Z.N. Saumtally (United Kingdom)
- The prognostic value of highly sensitive cardiac troponin I in pregnancies with pre-eclampsia: bicentric prospective study P05.12
A. Ayachi (Tunisia)

P06: Fetal echocardiography I**L3 / L6 Hub 3***Chair: J.S. Carvalho (United Kingdom)*

- WITHDRAWN P06.01
- Perinatal outcome of tetralogy of Fallot depending on time of diagnosis P06.02
C. Enzensberger (Germany)
- Measurement of the aortic outlet angle by ultrasound in fetuses with and without congenital heart malformations involving the left ventricular outflow tract P06.03
L. Gindes (Israel)
- First trimester screening for major congenital heart diseases: the septal-truncus angle P06.04
S. Tudorache (Romania)
- Automation of the fetal right myocardial performance index (RMPI) to optimise repeatability P06.05
H. Avnet (Australia)
- CASSEAL: fetal cardiovascular system sonographic evaluation algorithm – multicentric study on its clinical application for prenatal diagnosis P06.06
C. Bravo (Spain)
- Multicentric study for prenatal diagnosis of congenital cardiovascular anomalies in second trimester using CASSEAL (Cardiovascular System Sonographic Evaluation Algorithm) P06.07

C. Bravo (Spain)

Monitoring of sacrococcygeal teratoma: clinical evaluation of a computerised model P06.08

C. Wohlmuth (Austria)

Performance of TAPSE, MAPSE and TAPSE/MAPSE values in normal fetuses throughout gestation and in newborns by M-mode echocardiography P06.09

M. Rodríguez (Spain)

The application of z-scores in diagnosis of fetal pulmonary artery stenosis in Chinese patients P06.10

Y. Peng (China)

Comparison of M-mode and 2D-echocardiography in the assessment of fetal ventricular systolic function P06.11

E. Crispi (Spain)

Prenatal echocardiographic evaluation in pulmonary stenosis correlated with postnatal intervention P06.12

*A. Takamizu (Japan)***P07: Using ultrasound in urogynecology patients****L3 / L6 Hub 4***Chair: A. Youssef (Italy)*

Correlation and reliability of translabial B-mode and 3D ultrasonographic scan in evaluating transobturator adjustable tape (TOA) surgery success: preliminary results P07.01

M. Rolla (Italy)

Anal sphincter trauma and parity P07.02

Y. Li (China)

Transvaginal two-dimensional sonography: its role in observing the puborectalis in postpartum women P07.03

H. Wang (China)

Quantitative evaluation of a semi-automated measurement system for levator hiatus P07.04

H. Wang (China)

Prevalence of levator trauma and delivery mode P07.05

H.P. Dietz (Australia)

Does a pelvic floor contraction change the appearance of EAS defects? P07.06

H.P. Dietz (Australia)

Ultrasound imaging of transobturator suburethral tape and its association with surgical outcome P07.07

I. Ortega Cárdenes (Spain)

What is the best cut-off value for the levator-urethra gap (LUG) measurement in the diagnosis of avulsion defects? P07.08

V.H. Eisenberg (Israel)

Ultrasound assessment of changes in the pelvic floor before and after childbirth P07.09

B. Graupera (Spain)

Transperineal 3D pelvic ultrasound in the assessment of complex voiding dysfunction following failed suburethral sling division surgery P07.10

S. The (Australia)

WITHDRAWN P07.11

P08: Fetal growth**L3 / L6 Hub 1***Chair: G. Rizzo (Italy)*

Cerebroplacental ratio (CPR) in fetuses with different estimated weight P08.01

R.S. Bataeva (Russian Federation)

The correlation between parental biometric parameters and neonatal head circumference: a prospective study P08.02

S. Porat (Israel)

Low-dose aspirin for prevention of fetal growth restriction and pre-eclampsia in twins: the GAP pilot randomised trial P08.03

E. Bujold (Canada)

The relationship between cardiomegaly and global strain in fetuses with intrauterine growth restriction (IUGR) <i>G.R. DeVore (United States)</i>	P08.04
Secondary ossification centres of fetal femur, humerus and tibia assessed by 3D ultrasound in third trimester: correlation with gestational age <i>G. Cohen (Israel)</i>	P08.05
Low molecular-weight heparin for prevention of placental insufficiency in women with history of a first pregnancy with early onset IUGR <i>O. Tica (Romania)</i>	P08.06
Which fetal growth chart detects the small baby? A comparison of abdominal circumference and estimated fetal weight on the Hadlock charts compared to the Gardosi customised chart in a London University Hospital <i>E.E. Bredaki (United Kingdom)</i>	P08.07
Pitfalls in interpretation of fetal growth curves in pregnancies complicated with maternal obesity and gestational diabetes <i>L. Ceausu (Romania)</i>	P08.08
The influence of cigarette smoking and dietary habits on first trimester growth rate and embryonic heart rate <i>B. Shakeri (Australia)</i>	P08.09
Embryonic growth and birthweight: a correlation study <i>M. Yamamoto (Chile)</i>	P08.10
Evaluation of an automated tool for fetal biometry <i>L. Salim (United Kingdom)</i>	P08.11

P09: Head, neck and bones

L3 / L6 Hub 2

<i>Chair: P. Acharya (India)</i>	
Otocephaly-agnathia, proboscis and holoprosencephaly diagnosed in a fetus with Trisomy 18 using three-dimensional ultrasound and postmortem magnetic resonance imaging <i>A. Alhousseini (United States)</i>	P09.01
Typical and atypical dural sinus malformation imaging in the fetus: based on 4 cases <i>X. Chen (China)</i>	P09.02
MR of fetal neck and face masses: prediction of high morbidity neonatal outcome, including ex utero intrapartum therapy (EXIT) <i>D.M. Twickler (United States)</i>	P09.03
Prenatal diagnosis of diastematomyelia: case series of 9 patients <i>H.P. Tamhankar (India)</i>	P09.04
Evaluation of ossification timing of sacral vertebrae by transabdominal sonography in the second trimester of pregnancy <i>B. Moradi (Islamic Republic of Iran)</i>	P09.05
Pregnancy complicated with maternal and fetal osteogenesis imperfecta type III <i>R. Gerychova (Czech Republic)</i>	P09.06
Three-dimensional imaging of the fetal skeletal system at 9 weeks' gestation <i>H. Shah (United Kingdom)</i>	P09.07
Rare case of unilateral tibial hemimelia in the first trimester <i>D. Singh (India)</i>	P09.08
Ultrasonographic clues for prenatal diagnosis of FGFR3-related skeletal dysplasia <i>B. Jeong (Republic of Korea)</i>	P09.09
Prenatal diagnosis of achondroplasia in the second trimester of pregnancy using the biparietal diameter/femur length ratio <i>J. Stirnemann (France)</i>	P09.10
Maxillo-occipital line: a sonographic marker for the screening of open spina bifida in the first trimester <i>E. Da Silva Costa (Australia)</i>	P09.11

The fetal thymus: morphology and volumetry in 3 Tesla postmortem MRI – a retrospective analysis <i>G.M. Gruber (Austria)</i>	P09.12
Repetitive non-persistent protrusion of the tongue on prenatal ultrasound <i>A.K. Kesrouani (Lebanon)</i>	P09.13
Hemivertebra: diagnosis at 11–14 weeks of pregnancy <i>A. Yulia (United Kingdom)</i>	P09.14

P10: Placenta, umbilical cord and amniotic fluid

L3 / L6 Hub 3

Chair: T. Cohen-Overbeek (Netherlands)

Bartter syndrome: a rare cause of refractory severe polyhydramnios <i>A. Fatma (United Kingdom)</i>	P10.01
Idiopathic polyhydramnios and antenatal Bartter syndrome: diagnostic criteria? <i>J. Thomas (Australia)</i>	P10.02
Prenatal diagnosis of multiple umbilical vein varices associated with massive thrombosis and velamentous cord insertion <i>H. Kang (Republic of Korea)</i>	P10.03
Amniotic band syndrome: first trimester diagnosis and classification <i>C. Lia (United Kingdom)</i>	P10.04
Prenatal diagnosis of an umbilical artery aneurysm in a dichorionic-diamniotic twin gestation with fetal growth discordance <i>E. Pschirrer (United States)</i>	P10.05
Congenital fetal anomalies are associated with placental pathologic change <i>X. Chen (China)</i>	P10.06

P11: Using ultrasound to characterise and help manage ovarian masses: experience of using the IOTA ADNEX model and simple rules

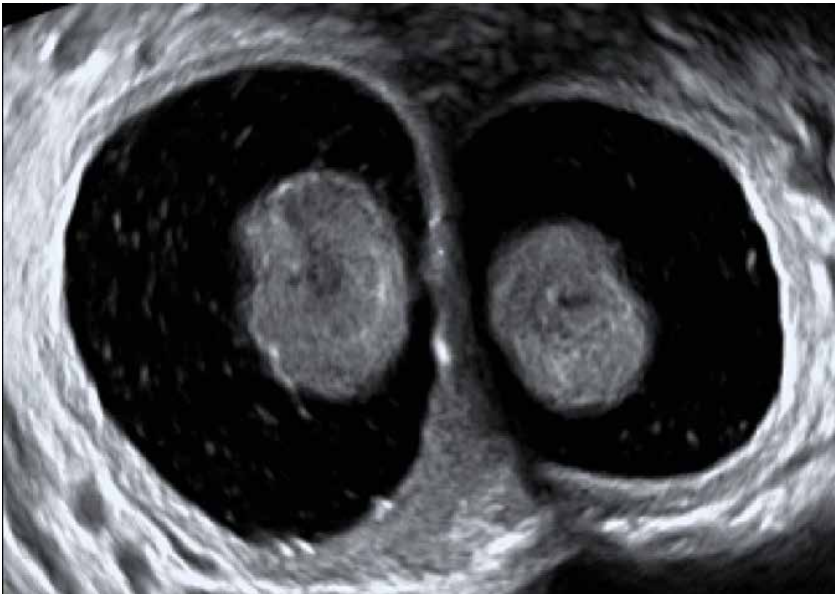L3 / L6 Hub 4

Chairs: T. Bourne (United Kingdom); D. Timmerman (Belgium)

Diagnostic accuracy of IOTA ADNEX and IOTA LR2 model compared with subjective assessment (SA) in differentiating benign and malignant ovarian masses <i>M. Pietryga (Poland)</i>	P11.01
Performance of IOTA ADNEX model in differentiating histological subtypes of borderline ovarian tumours <i>A. Gaurilcikis (Lithuania)</i>	P11.02
Ultrasound features of ovarian carcinoma in patients with BRCA 1 or BRCA 2 mutation <i>S. Giunchi (Italy)</i>	P11.03
Ultrasound evaluation of adnexal masses during pregnancy <i>E. Rabiej (Poland)</i>	P11.04
Subjective ultrasound assessment and the ADNEX model to differentiate between benign and malignant ovarian tumours <i>S. Ferrero (Italy)</i>	P11.05
Could LARP1 be a driving force in ovarian cancer transformation? <i>A. Coosemans (Belgium)</i>	P11.06
Applying IOTA simple rules and ADNEX model in daily routine <i>D.R. Hartge (Germany)</i>	P11.07
AOUI Verona gynecology oncology centre ultrasound experience using IOTA model to study adnexal masses: management and outcome prediction <i>F. Presti (Italy)</i>	P11.08
A case of mature teratoma with strumal foci mimicking borderline ovarian cancer in pregnancy <i>R. Heremans (Belgium)</i>	P11.09
Primary retroperitoneal mucinous tumours diagnosed in pregnancy: a case report and literature review <i>F. Tahmasebi (United Kingdom)</i>	P11.10

SCIENTIFIC PROGRAM

Monday 18 September 2017



MONDAY

Double cervix - Ludwin A, Martins WP, Ludwin I. Volumetric sonovaginocervicography with tomography ultrasound imaging and virtual speculscopy at HD-live: perspective diagnostic for virgins and women with utero-vagino-cervical complex malformations. *Ultrasound Obstet Gynecol* 2016 Aug 25. doi: 10.1002/uog.17285.

Monday 18.09.2017

HALL A

07:30-08:10

Masterclass

Fetal neurosonography: tips and tricks
R. Chaoui (Germany)

08:15-09:15

Abnormal fetal growth: causation, detection and long-term effects

Chairs: *C.M. Bilardo (Netherlands); G. Tulzer (Austria)*

08:15 **INVITED:** Physiological effects of IUGR
F. Figueras (Spain)

08:25 **OC09.01** Transgenerational effect of fetal growth restriction
A. Sepúlveda-Martínez (Spain)

08:33 **OC09.02** Maternal hemodynamics in SGA fetuses that turn to IUGR and the potential efficacy of treatment
G. Tiralongo (Italy)

08:41 **OC09.03** Pattern of placental stromal-vascular lesions in small fetuses with and without pre-eclampsia
L. Youssef (Spain)

08:49 **OC09.04** Ductus venosus waveforms in expectant management of early IUGR fetuses and risk of adverse neonatal outcome: a survival analysis
E. Cosmi (Italy)

08:57 **OC09.05** The effect of introducing umbilical artery Doppler examination on the management of fetal growth restriction in a low-income country
B.K. Parmar (Nepal)

09:05 **OC09.06** Placental ageing in term small-for-gestational age and growth-restricted fetuses
F. Crispi (Spain)

HALL E

Masterclass

New frontiers in preterm labour
R. Romero (United States)

The fetal brain exposed to Zika and CMV virus

Chairs: *M. Herrera (Colombia); G. Kaspiran (Austria)*

08:15 **INVITED:** From maternal infection to fetal brain lesion: the natural history of congenital infection
Y. Ville (France)

08:35 **OC10.01** The Zika virus epidemic in French Guiana: proposition of an ultrasound-based score for the diagnosis of fetal congenital Zika virus syndrome
L. Pomar (French Guiana)

08:43 **OC10.02** Prevalent and incident cases of CNS anomalies in fetuses of pregnant women with symptoms of ZIKV infection: ZEN Initiative, Bucaramanga, Colombia
L.A. Gutierrez Rojas (Colombia)

08:51 **OC10.03** Additional prognostic value of third trimester MRI following reassuring mid-trimester assessment of congenital CMV infection
Y. Ville (France)

08:59 **OC10.04** The echogenic caudate nucleus: a sign for the identification of brain involvement in fetuses with CMV infection?
J. Har-Toooy (Israel)

09:07 **OC10.05** Middle cerebral artery pulsatility index may predict fetal cerebral injury in pregnancy complicated by cytomegalovirus infection
E. Cosmi (Italy)

HALL F

Masterclass

Management of fetal growth restriction in practice

E. Gratacós (Spain)

Using ultrasound to characterise and help manage ovarian masses

Chairs: T. Bourne (United Kingdom);

H. Koelbl (Austria)

- 08:15 **OC11.01** Clinical utility of IOTA models, RMI and ROMA to refer patients with adnexal masses to specialised oncology care
L. Wynants (Belgium)
- 08:23 **OC11.02** IOTA benign easy descriptors and ADNEX model integrated in a 'traffic light system' to guide the clinical management of adnexal pathology
C. Landolfo (Belgium)
- 08:31 **OC11.03** Prospective validation of IOTA methods in the differentiation between benign and malignant adnexal masses
W. Froyman (Belgium)
- 08:39 **OC11.04** Ovarian masses in pregnancy
T. Eichenberger-Gautschi (United Kingdom)
- 08:47 **OC11.05** Transvaginal colour Doppler ultrasound in early diagnosis of ovarian cancer: our experience since 1999
M. Pascual (Spain)
- 08:55 **OC11.06** Ultrasonographic differences of papillations in benign and malignant adnexal unilocular-solid cysts with papillations and no other solid components: a retrospective multicentre study
C. Landolfo (Belgium)
- 09:03 **OC11.07** Ultrasound-guided laparoscopic ovarian wedge resection in recurrent serous borderline ovarian tumours
S. Saso (United Kingdom)

HALL B

Masterclass

Revising IOTA terms and definitions: case examples of how to classify ovarian masses – how I manage non-tubal ectopic pregnancies?

L. Valentin (Sweden)

HALL A

09:20-10:00

Short oral presentation (OP)

OP13 Small-for-gestational age
*Chairs: G. Rizzo (Italy);
B. Thilaganathan (United Kingdom)*

09:50-10:20

Coffee and e-poster viewing

10:20-11:20

★ Fetal brain: form and function

Chairs: D. Paladini (Italy); A. Ngu (Australia)

- 10:20 **LIVE SCAN**: how I look at the fetal brain
[industry supported*]
L. Guibaud (France)
- 10:40 **OC12.01** Early maturation of the sensory-motor cortex assessed by fetal MRI
S. Stoecklein (Germany)
- 10:48 **OC12.02** The accuracy of fetal fiber tracking: a postnatal MRI correlation
J. Song (United States)
- 10:56 ^{VI}**OC12.03** Thicknesses of transient fetal layers in brains of 19–24 gestational weeks' fetuses on 3-T MRI
L. Pogledic (Austria)
- 11:04 **OC12.04** Cortical development is correlated with neurodevelopmental outcome at 6 months in fetuses with isolated non-severe ventriculomegaly
E. Eixarch (Spain)
- 11:12 ^{VI}**OC12.05** Cortical age in fetuses with heart defects using automated age-prediction software
S.M. Everwijn (Netherlands)

HALL E

Short oral presentation (OP)

★ **OP14** Fetal brain and CNS anomalies
*Chairs: L.J. Salomon (France);
M. Sanz Cortes (United States)*

Coffee and e-poster viewing

Can ultrasound guide delivery?

*Chairs: T.M. Eggebø (Norway);
P. Husslein (Austria)*

- 10:20 **ISUOG GUIDELINES**: guidelines on ultrasound in labour
T. Ghi (Italy)
- 10:40 **OC13.01** Managing “big” babies: the impact of fetal head circumference
S. Yagel (Israel)
- 10:48 **OC13.02** Fetal head circumference to predict delivery mode: a pilot study
S. Yagel (Israel)
- 10:56 **OC13.03** Sonographic prediction of mode of delivery: a multicentre, prospective cohort study
B.H. Kahrs (Norway)
- 11:04 **OC13.04, OC13.05, OC13.06**
Dynamic changes of the angle of progression at term and labour outcome
A. Youssef (Italy)
- 11:12 **OC13.07** Visual biofeedback using transperineal ultrasound during the second stage of labour
Y. Gilboa (Israel)

* Scientific content of sessions is defined by the Scientific Committee; ultrasound systems and technical support are provided by sponsors.

^{VI} This presentation is eligible for the Young Investigator award (to be presented in the closing plenary).

HALL F**Short oral presentation (OP)**

OP15 Using ultrasound to accurately characterise and guide the management of ovarian masses: do IOTA models work in practice?

Chairs: S. Helmy (Austria); L. Valentin (Sweden)

Coffee and e-poster viewing**Using imaging to help in the management of oncology patients**

Chairs: S. Helmy (United Kingdom); E. Epstein (Sweden)

- 10:20 **OC14.01** Ultrasound characteristics of endometrial cancer as defined by the International Endometrial Tumor Analysis (IETA) consensus nomenclature: a prospective multicentre study
E. Epstein (Sweden)
- 10:40 **OC14.02** Ultrasound-based mathematical model for predicting persistent trophoblastic neoplasia from a large cohort of women with hydatidiform mole: the update of testing model
J. Qin (China)
- 10:48 **OC14.03** Preoperative assessment of the extent of disease in ovarian cancer: comparative study of ultrasound and CT scan
J.L. Alcázar (Spain)
- 10:56 **OC14.04** Role of intraoperative ultrasound to extend minimally invasive surgery for treatment of recurrent gynecological cancer
A.C. Testa (Italy)
- 11:04 **OC14.05** Contrast enhanced ultrasonography (CEUS) of cervical carcinoma: a pilot study on contrast distribution patterns and qualitative CEUS parameters in cervical cancer patients and in women with normal cervixes
K. Palsdotir (Sweden)
- 11:12 **OC14.06** Preoperative staging of advanced ovarian cancer: comparison between ultrasound, CT and WB-DWI/MRI
D. Fischerová (Czech Republic)

HALL B**Short oral presentation (OP)**

OP16 Detection of fetal heart anomalies II

Chairs: A. Abuhamad (United States); G. Tulzer (Austria)

Coffee and e-poster viewing**Short oral presentation (OP)**

OP17 Hypertensive disease in pregnancy: screening to diagnosis

Chairs: F. Crispi (Spain); G. Di Renzo (Italy)

HALL A

- 11:25-12:05 **Short oral presentation (OP)**
★ **OP18** Fetal growth and the brain
Chairs: A. Ngu (Australia); D. Prayer (Austria)

12:00-13:30 **Lunch and e-poster viewing**

12:15-13:15 **Industry sponsored satellite symposia****

Workshop
**Big mothers, big babies:
getting the most from your
scan**

Chair: H. Gardiner; J. Miller (United States)

- 13:30 Effective fetal monitoring in diabetic mothers: physiology to practice
J. Miller (United States)
- 13:50 The heart of the problem: optimising screening for heart defects on a technically challenging scan
H. Gardiner (United States)
- 14:10 **LIVE SCAN:** optimising imaging in the overweight patient [industry supported*]
P. Glanc (Canada)

HALL E

- Short oral presentation (OP)**
OP19 Ultrasound in the labour ward
Chairs: T. Ghi (Italy); C. Lees (United Kingdom)

Lunch and e-poster viewing

**CfDNA tests: where are we
now?**

Chairs: L.D. Platt (United States); U. Lang (Austria)

- 13:30 **INVITED:** ISUOG consensus statement
L.J. Salomon (France)
- 13:50 **OC15.01** Analysis of cell-free DNA in maternal blood in screening for aneuploidies: updated meta-analysis
M. Gil (Spain)
- 13:58 **OC15.02** Evolving role of ultrasound in the NIPT era: population-based trends in screening and diagnostic testing for fetal aneuploidy
L. Hui (Australia)
- 14:06 **OC15.03** Comparison between first trimester combined screening and a combination between ultrasound and cell-free DNA
K.O. Kagan (Germany)
- 14:14 **OC15.04** Chromosomal abnormalities detected by cell-free DNA testing as a contingent approach versus direct invasive prenatal diagnosis
K.Y. Leung (Hong Kong)
- 14:22 **OC15.05** Socioeconomic status and clinical variation in prenatal testing in the NIPT era
L. Hui (Australia)

* Scientific content of sessions is defined by the Scientific Committee; ultrasound systems and technical support are provided by sponsors.

**Lunchtime satellite symposia are brought to you by our sponsors and are not part of the ISUOG CME program. ISUOG takes no responsibility for scientific or clinical content. Please see page 158 for our satellite program.

HALL F

Short oral presentation (OP)

OP20 How using ultrasound can inform the management of patients with gynecological malignancy

*Chairs: D. Fischerová (Czech Republic);
M. Blanchette Porter (United States)*

Lunch and e-poster viewing

Advances in fetal surgery

*Chairs: A. Johnson (United States);
P. Klaritsch (Austria)*

- 13:30 **INVITED:** Fetal surgery for spina bifida in the 21st century
A. Johnson (United States)
- 13:50 **OC16.01** Fetoscopic repair of spina bifida also improves postnatal motor outcomes
D.A. Pedreira (Brazil)
- 13:58 **OC16.02** Percutaneous fetoscopic 3-layer closure of large open spina bifida defects using a bilaminar skin substitute
R. Quintero (United States)
- 14:06 **OC16.03** Effects of carbon dioxide gas (CO₂) insufflation for fetoscopy on the amniotic fluid and fetal membranes
R. Papanna (United States)
- 14:14 **OC16.04** Intrauterine open fetal surgery for correction of isolated occipital encephalocele
H.J. Milani (Brazil)
- 14:22 **OC16.05** Open fetal surgery for congenital malformations: feasibility and perinatal outcomes
A.F. Moron (Brazil)

HALL B

Short oral presentation (OP)

OP21 Fetal development in maternal conditions

*Chairs: C.M. Billardo (Netherlands);
E. Krampfl-Bettelheim (Austria)*

Lunch and e-poster viewing

Uterine and endometrial problems: from asymptomatic polyps to repairing Caesarean section scars

Chairs: T. Van den Bosch (Belgium); F. Leone (Italy)

- 13:30 ^{YI}**OC17.01** Routine ultrasound monitoring of asymptomatic endometrial polyps offers no benefit in clinical practice
M. Wong (United Kingdom)
- 13:50 **OC17.02:** Non-atypical endometrial hyperplasia: clinical and sonographic characteristics and long-term outcome
Q. Rotenberg (United States)
- 13:58 **OC17.03** Risk of endometrial cancer in asymptomatic postmenopausal women with endometrial thickness >11mm: systematic review and meta-analysis
J.L. Alcázar (Spain)
- 14:06 **OC17.04** Intra- and interobserver agreement using the MUSA terminology for ultrasonographic features associated with ill-defined lesions
C. Kjaergaard (Denmark)
- 14:14 **OC17.05** New sonographic and hysteroscopic combined classification for surgical repair of isthmoceles in an out-patient setting to ensure maximum safety in minimal invasive surgery
A.M. Dueckelmann (Germany)
- 14:22 **OC17.06** 2D-TVU is a more accurate modality than 3D-VCI in staging endometrial cancer
R.W. Green (Sweden)

^{YI} This presentation is eligible for the Young Investigator award (to be presented in the closing plenary).

HALL A

14:35-15:15

Short oral presentation (OP)

OP22 NIPT: issues and implementation
*Chairs: J. Stirnemann (France);
B. Tutschek (Switzerland)*

15:10-15:40

Coffee and e-poster viewing

15:40-17:00

Workshop Understanding outflow tract abnormalities

*Chairs: A. Abuhamad (United States);
J.S. Carvalho (United Kingdom)*

15:40

LIVE SCAN: effective screening for
outflow tract abnormalities – tips and
tricks
[industry supported*]
J.S. Carvalho (United Kingdom)

16:00

Tetralogy of Fallot: from anatomy to
ultrasound
G. Rizzo (Italy)

16:20

Transposition of the great arteries: from
anatomy to ultrasound
G.R. DeVore (United States)

16:40

Image quiz
A. Abuhamad (United States)

17:15-18:15

Industry sponsored satellite symposia**

HALL E

Short oral presentation (OP)

OP23 Invasive procedures: new data
*Chairs: A. Gagnon (Canada);
M. Yamamoto (Chile)*

Coffee and e-poster viewing

Workshop Complications of twins: how to image, how to manage

*Chairs: A. Khalil (United Kingdom);
E. Gratacós (Spain)*

15:40

Twin–twin transfusion syndrome
Y. Ville (France)

16:00

Selective fetal growth restriction
E. Gratacós (Spain)

16:20

Twin reversed arterial perfusion
K. Hecher (Germany)

16:40

How to avoid stillbirth in twins
A. Khalil (United Kingdom)

* Scientific content of sessions is defined by the Scientific Committee; ultrasound systems and technical support are provided by sponsors.

**Lunchtime satellite symposia are brought to you by our sponsors and are not part of the ISUOG CME program. ISUOG takes no responsibility for scientific or clinical content. Please see page 158 for our satellite program.

HALL F

Short oral presentation (OP)

OP24 Uterine and endometrial problems: from elastography to using ultrasound to monitor treatment response
Chairs: P Schw rtzler (Austria); L. Valentin (Sweden)

Coffee and e-poster viewing

Workshop

Update from the IOTA group: how to use IOTA rules and models

Chairs: D. Timmerman (Belgium); D. Fischerov  (Czech Republic)

- 15:40 How we approach scanning? Easy descriptors
T. Bourne (United Kingdom)
- 15:53 Using IOTA simple rules and simple rules risks
L. Valentin (Sweden)
- 16:06 The IOTA ADNEX model: variable required and how to interpret the results
A.C. Testa (Italy)
- 16:19 The optimum approach to evaluating masses: easy descriptors and the ADNEX model: data and case examples
D. Timmerman (Belgium)
- 16:29 Case examples
C. Landolfo (Italy)
- 16:44 Case examples
M. Al-Memar (United Kingdom)

HALL B

Short oral presentation (OP)

OP25 Clinical challenges in chorionicity
Chairs: K. Hecher (Germany); Y. Ville (France)

Coffee and e-poster viewing

Workshop

Late fetal growth restriction

Chairs: F. Figueras (Spain); J. Thornton (United Kingdom)

- 15:40 Late fetal compromise: scale of the problem
J. Thornton (United Kingdom)
- 16:00 Monitoring parameters and stillbirth
B. Thilaganathan (United Kingdom)
- 16:15 Neonatal morbidity in late gestation
F. Figueras (Spain)
- 16:30 Is late uterine Doppler useful?
K. Mars l (Sweden)
- 16:45 Why a third trimester randomised controlled trial is needed
C. Lees (United Kingdom)

Hubs

HUB 1

09:20-10:00 **Poster discussion (P)**
P12: Cysts and other abdominal features
Chair: S. Seshadri (India)

10:20-11:20

11:25-12:05 **Poster discussion (P)**
P16: Screening for fetal anomalies
Chair: K.O. Kagan (Germany)

12:20-13:20 **Interactive**
Join the conversation:
Are you practicing safe sonography?
Moderator: S. Westerway (Australia)
Opinion leaders: E. Merz (Germany);
G. Ter Haar (United Kingdom); C. Brezinka (Austria)

13:30-14:30

14:35-15:15 **Poster discussion (P)**
P20: The prognostic value of growth parameters
Chair: C. Brezinka (Austria)

15:40-17:00 **Guidelines**
Chinese
Moderator: Q. Wu (China)

HUB 2

Poster discussion (P)
P13: Ultrasound in the labour ward II
Chair: L.D. Platt (United States)

Interactive
In conversation with *T. Van den Bosch* and
D. Van Schoubroeck.
How to carry out a one-stop fertility scan:
using contrast in the uterus and tubes

Poster discussion (P)
P19: Fetal echocardiography II
Chair: W. Lee (United States)

Interactive
In conversation with *G. Condous* and
S. Guerriero: Practical approach to ultrasound
diagnosis of endometriosis

Interactive
In conversation with *N.J. Raine-Fenning*:
How do I diagnose polycystic ovaries and
perform cycle monitoring?

Poster discussion (P)
P21: Predicting pregnancies at risk
Chair: B. Thilaganathan (United Kingdom)

Guidelines
Spanish
Moderator: M. Herrera (Columbia)

HUB 3

Poster discussion (P)

P14: Uterine and endometrial problems: from elastography to using ultrasound to monitor treatment response

Chair: E. Epstein (Sweden)

Interactive

Special interest group (SIG): Heart

Chair: J.S. Carvalho (United Kingdom)

Poster discussion (P)

P17: Maternal and fetal assessment in complicated pregnancies

Chair: M. Herrera (Colombia)

Interactive

In conversation with the CFEF

Moderators: P. Boukobza (France);

G. Haddad (France)

Interactive

Join the conversation:

UOG - Your Journal

Moderators: B. Thilaganathan;

R. Hutchinson (United Kingdom)

Poster discussion (P)

P22: Fetal echocardiography III

Chair: F. Crispi (Spain)

Guidelines

French

Moderator: G. Haddad (France)

HUB 4

Poster discussion (P)

P15: Improving the outcome of fetal procedures

Chair: A. Johnson (United States)

Interactive

Join the conversation:

How do I avoid medico legal issues?

Moderator: C. Brezinka (Austria)

Opinion leaders: C. Lees (United Kingdom);

N. Raine-Fenning (United Kingdom);

J. Copel (United States)

Poster discussion (P)

P18: Techniques related to using ultrasound to assess pelvic pain and diagnose superficial endometriosis and DIE

Chairs: G. Condous (Australia);

G. Hudelist (Austria)

Interactive

In conversation with *L. Sentilhes* and *R. Romero*:

Consensus on preventing preterm birth in high-risk situations

Interactive

Join the conversation:

Live reporting – fetal MRI

Moderators: D. Prayer (Austria);

D. Pugash (Canada);

D.M. Twickler (United States)

Poster discussion (P)

P23: Managing early pregnancy complications

Chairs: S. Bobdiwala; D. Jurkovic (United Kingdom)

Guidelines

Russian

Moderators: F. Ushakov (United Kingdom);

E. Andreeva (Russian Federation)

OP - Monday 18.09.2017

OP13: Small-for-gestational age

Chairs: G. Rizzo (Italy); B. Thilaganathan (United Kingdom)

Operative delivery due to fetal compromise in small-for-gestational-age fetuses at term: a prediction model and internal validation

Hall A

OP13.01

E. Kalafat (Turkey)

Different expression of placental nutrient transporters among term small-for-gestational-age and growth-restricted fetuses

OP13.02

E. Crispi (Spain)

Prediction of delivery of small-for-gestational age neonates and adverse perinatal outcomes by angiogenic factors at 37 weeks' gestation

OP13.03

S. Triunfo (Spain)

Mode of delivery and neonatal mortality among very low birthweight infants

OP13.04

A. Londero (Italy)

Echocardiographic differences between SGA and AGA fetuses

OP13.05

E. Cosmi (Italy)

Mechanical versus chemical labour induction in suspected IUGR/SGA: systematic review and meta-analysis

OP13.06

A. Henry (Australia)

Targeted lipidomics of maternal and cord blood in term gestations with suboptimal fetal growth

OP13.07

J. Miranda (Spain)

Placental three-dimensional power Doppler indices in pregnancies complicated by gestational diabetes mellitus

OP13.08

C. Chen (Taiwan)

Birthweight and intrauterine growth patterns of fetuses of pregnant women post-bariatric surgery

OP13.09

T. Maric (United Kingdom)

Prediction of birthweight in SGA at 11–13+6 weeks using maternal history, LMP, ultrasound and biochemistry

OP13.10

J. Stirnemann (France)

Placental mesenchymal dysplasia: four cases

OP13.11

Y. Copado Mendoza (Mexico)

OP14: Fetal brain and CNS anomalies

Chairs: L.J. Salomon (France); M. Sanz Cortes (United States)

Termination of pregnancy for central nervous system (CNS) anomalies: correlation of prenatal with postmortem diagnosis

OP14.01

W. Dendas (Belgium)

Cystic abnormalities of fetal posterior fossa at 11–13+6 weeks scan

OP14.02

E. Andreeva (Russian Federation)

Evaluation of fetal ventriculomegaly at 11–14 weeks of gestation

OP14.03

H. Gülmez (Switzerland)

Neurodevelopmental outcome of isolated fetal ventriculomegaly

OP14.04

E. Barzilay (Israel)

"Ganglionic eminence fingers": MR evidence of disruptive migration in fetal hydrocephalus

OP14.05

G. Kasprjan (Austria)

Finding the hippocampus: challenge accepted

OP14.06

C. Comanescu (Romania)

Hall E

Outcomes of fetuses with small cerebellum on second and third trimester ultrasonography <i>M. Massoud (France)</i>	OP14.07
Prenatal diagnosis of a new cobblestone malformation complex disorder: Walker-Warburg syndrome associated with tectocerebellar dysraphia <i>H. Bakry (Israel)</i>	OP14.08
Pericallosal lipomas may escape detection during a second trimester scan <i>J. Har-Toov (Israel)</i>	OP14.09
Normal ganglionic eminence and blighted ganglionic eminence in neuronal migration disorder cases detected by transvaginal neuroscan <i>R.K. Paah (Japan)</i>	OP14.10
Prenatal diagnosis of medullary tegmental cap dysplasia: a rare disorder of axonal guidance <i>K.K. Haratz (Israel)</i>	OP14.11

OP15: Using ultrasound to accurately characterise and guide the management of ovarian masses: do IOTA models work in practice?

Hall F

Chairs: S. Helmy (Austria); L. Valentin (Sweden)

09:20-09:32 Classifying solid ovarian masses
L. Valentin (Sweden)

INVITED

Evaluating the ADNEX model in preoperatively predicting malignancy risks of ovarian masses: a prospective study in a tertiary hospital in the Philippines <i>J. Gabaldon-Las (Philippines)</i>	OP15.01
Use of Crystal Vue technique for imaging of adnexal masses: a pilot study <i>S. Saso (United Kingdom)</i>	OP15.02
Evaluation of the STIC technology with high-definition colour Doppler for preoperative differential diagnosis of ovarian tumours: a prospective study <i>J.L. Alcázar (Spain)</i>	OP15.03
Diagnostic performance of IOTA models in adnexal masses: a retrospective assessment <i>S. Schwab (Austria)</i>	OP15.04
Opposite behaviour of CD8+ T cells in blood and tumour tissue of ovarian cancer patients <i>A. Coosemans (Belgium)</i>	OP15.05
Performance of RMI, IOTA ADNEX and simple rules risk model in the assessment of adnexal masses not classifiable using the revised benign easy descriptors as first step: a novel two-step strategy <i>C. Landolfo (Belgium)</i>	OP15.06
Prospective validation of International Ovarian Tumour Analysis (IOTA) malignancy indicators for adnexal masses: a 4-year study from a single centre <i>S. Johnson (United Kingdom)</i>	OP15.07

OP16: Detection of fetal heart anomalies II

Hall B

Chairs: A. Abuhamad (United States); G. Tulzer (Austria)

Absent pulmonary valve syndrome: diagnosis, associations and outcome in 71 prenatally diagnosed cases <i>R. Axt-Fliedner (Germany)</i>	OP16.01
Pulmonary atresia-critical stenosis with intact ventricular septum: prospective validation of a prenatal score for prediction of postnatal outcome <i>E. Gómez Montes (Spain)</i>	OP16.02
Perinatal and perioperative cardiac changes in fetuses with simple transposition of the great arteries <i>O. Patey (United Kingdom)</i>	OP16.03
The prevalence of pathogenic copy number variation in tetralogy of Fallot and associated congenital heart defect diagnosed prenatally <i>S. Ge (United States)</i>	OP16.04

Prenatal diagnosis of tuberous sclerosis complex using high-throughput DNA sequencing combined with fetal echocardiography <i>S. Ge (United States)</i>	OP16.05
Quality assessment of (semi-) automated evaluation of the fetal heart using fetal intelligent navigation echocardiography (FINE) in 700 cases <i>D.R. Hartge (Germany)</i>	OP16.06
Fetal intelligent navigation echocardiography (FINE) detects congenital heart disease with a sensitivity of 98%, specificity of 93% and accuracy of 95% <i>L. Yeo (United States)</i>	OP16.07
Feasibility and comparison of high definition flow and B flow in assessing fetal heart during first trimester screening <i>S. Piri (Islamic Republic of Iran)</i>	OP16.08
A study on the application value of STIC technology for the prenatal diagnosis of abdominal vascular malformations <i>Q. Pei (China)</i>	OP16.09
Prenatal diagnosis of aberrant right subclavian artery (ARSA) in unselected population: our own experience <i>R.S. Bataeva (Russian Federation)</i>	OP16.10
Identification of fetal great arteries and their main branches by four-dimensional sonography with high-definition flow imaging <i>Y. Zhang (China)</i>	OP04.11

OP17: Hypertensive disease in pregnancy: screening to diagnosis

Hall B

<i>Chairs: F. Crispi (Spain); G. Di Renzo (Italy)</i>	
Risk assessment for pre-eclampsia in nulliparous women in the first trimester <i>L.J. Salomon (France)</i>	OP17.01
First trimester data to predict pregnancy outcomes: the GOS study <i>E. Bujold (Canada)</i>	OP17.02, OP17.03
Predictive value of serial sFlt-1, PlGF and sFlt-1/PlGF ratio measurement in predicting the development of placental syndrome in women at high risk: a pilot study <i>J. Kolenburg (Netherlands)</i>	OP17.04
Diagnostic accuracy of different sFlt-1 and PlGF cut-off values in the assessment of preterm and term pre-eclampsia <i>A. Schoetzu (Switzerland)</i>	OP17.05
Quality assessment of biomarkers measurement in the first trimester combined screening for pre-eclampsia in 26,543 cases <i>F. da Silva Costa (Australia)</i>	OP17.06
Worsening of the uterine artery Doppler is associated with the development of hypertensive disorders of pregnancy <i>J. Binder (United Kingdom)</i>	OP17.07
Echocardiography and heart rate variability in pregnant women with essential arterial hypertension and pre-eclampsia <i>V. Makukhina (Russian Federation)</i>	OP17.08
Flow mediated dilation and peripheral arterial tonometry are disturbed in pre-eclampsia and reflect different aspects of endothelial function <i>D. Mannaerts (Belgium)</i>	OP17.09
Possible new approach in the prediction of late gestational hypertension: the role of the fetal aortic intima-media thickness <i>E. Cosmi (Italy)</i>	OP17.10
Does the presence of ascites among women with severe pre-eclampsia correlate with the severity and poor maternal and neonatal outcomes? <i>C. Mbonyizina (Rwanda)</i>	OP17.11

OP18: Fetal growth and the brain**Hall A**

Chairs: A. Ngu (Australia); D. Prayer (Austria)

Assessment of fetal brain vascularisation in fetuses affected by late onset fetal growth restriction using three dimensional power Doppler angiography 0P18.01

A. Rossi (Italy)

Cerebroplacental ratio in recurrent reduced fetal movements: evidence for worsening fetal hypoxemia 0P18.02

J. Binder (United Kingdom)

Development of a rabbit neurosphere model to study the neurodevelopmental damage induced by intrauterine growth restriction 0P18.03

M. Illa (Spain)

Reference values for fetal cerebrorenal and cerebroplacental ratios 0P18.04

S. Contag (United States)

The study of cranial ultrasound to diagnostic value of neonatal hypoxic-ischemic encephalopathy 0P18.05

C. Wu (China)

Comparison of fetal brain weight determined by fetal magnetic resonance imaging with autopsy brain weight 0P18.06

P.C. Brugger (Austria)

Growth of the fetal subarachnoid space: a volumetric fetal MRI study 0P18.07

P.C. Brugger (Austria)

FGR fetuses have less facial expressions than AGA counterparts with the assessment by 0P18.08

four-dimensional high-definition live (4D HDlive) ultrasound

H. Chida (Japan)

Impact of maternal anxiety on intrauterine growth and fetoplacental circulation in late third trimester 0P18.09

S. Triunfo (Spain)

Association of fetal cardiac indices with cerebroplacental ratio in normal, diabetic and fetal growth-restricted pregnancies at term 0P18.10

O. Patey (United Kingdom)

Assessment of correlation between fetal middle cerebral artery peak systolic velocity and brain apparent diffusion coefficient in IUGR 0P18.11

M.S. Kutuk (Turkey)

OP19: Ultrasound in the labour ward**Hall E**

Chairs: T. Ghi (Italy); C. Lees (United Kingdom)

MRI at station 0 in a small series: how well performs the ultrasound estimations? 0P19.01

D.G. Iliescu (Romania)

Maternal-fetal Doppler assessment in early labour and perinatal and delivery outcomes: a multicentre study 0P19.02

A. Dall'Asta (Italy)

Sonographic prediction of length of vacuum deliveries: a multicentre, prospective cohort study 0P19.03

B.H. Kahrs (Norway)

Vacuum extraction failure is associated with a large head circumference rather than high birth weight 0P19.04

S. Yagel (Israel)

Does McRoberts' manoeuvre affect fetal head angle of progression in active second stage of labour? 0P19.05

A.L. Zimerman (Israel)

Longitudinal changes of subpubic arch angle during pregnancy 0P19.06

A. Youssef (Italy)

Transabdominal ultrasound to assess fetal position in labour: a gold standard? 0P19.07

S. Usman (United Kingdom)

Higher rates of interventional delivery and maternal and neonatal complications in persistent occiput posterior position with a large head circumference OP19.08

S. Yagel (Israel)

The value of transperineal ultrasound OP19.09, OP19.10

S. Usman (United Kingdom)

OP20: How using ultrasound can inform the management of patients with gynecological malignancy

Hall F

Chairs: D. Fischerová (Czech Republic); M. Blanchette Porter (United States)

★ 11:25-11:37 MRI of ultrasound to delineate cervical carcinoma

INVITED

E. Epstein (Sweden)

An independent predictor for methotrexate resistance in low-risk gestational trophoblastic neoplasia with myometrial invasion: a prospective study OP20.01

J. Qin (China)

Sonographic features of inguinal lymph nodes in vulvar cancer OP20.02

P. Pinto (Portugal)

Ultrasound features of endometrial stromal sarcomas OP20.03

M. Ludovisi (Italy)

Imaging in gynecological disease: clinical and ultrasound features of ovarian clear cell carcinoma OP20.04

E. Mora (Italy)

Ultrasound features of uterine leiomyosarcomas OP20.05

M. Ludovisi (Italy)

Preoperative prediction of uterine sarcoma using signal intensity at T2 weighted imaging and apparent diffusion coefficient (ADC) on MRI OP20.06

Y. Oka (Japan)

Transvaginal ultrasound (TVS) versus MRI for diagnosing myometrial infiltration in endometrial carcinoma: a systematic review and meta-analysis OP20.07

J.L. Alcázar (Spain)

OP21: Fetal development in maternal conditions

Hall B

Chairs: C.M. Bilardo (Netherlands); E. Krampfl-Bettelheim (Austria)

Pre-pregnancy exercise stress testing is related to normal physiological adaptation from pre-pregnancy to mid-pregnancy OP21.01

J. Man (United Kingdom)

Assessment of relationship between fetal middle cerebral artery peak systolic velocity and umbilical vein blood gas values in diabetic pregnancies OP21.02

M.S. Kutuk (Turkey)

Incidence of pregnancy induced hypertension (PIH) and small-for-gestational age-(SGA) infants in egg donation pregnancies: a prospective study OP21.03

C. Scala (Italy)

The impact of pre-eclampsia for mothers and infants: analysis of outcomes from the PREDICT study OP21.04

K. Eastwood (United Kingdom)

The cerebroplacental ratio as a prognostic factor of fetal outcome in pregnancies complicated by maternal sickle cell disease OP21.05

A. Swarray-Deen (Ghana)

Gestational diabetes mellitus: could hemodynamic assessment identify patients with poor glycemic control at higher risk of labour complications? OP21.06

D. Lo Presti (Italy)

From when can we detect an alteration in fetal weight to placental volume ratio in pregnancy complicated by diabetes mellitus? <i>A. Suranyi (Hungary)</i>	OP21.07
Fetal thymus size in pregnant women with diabetic disease <i>K. Oelmeier de Murcia (Germany)</i>	OP21.08
Fetal Dopplers for prediction of perinatal outcomes in pregnancies complicated by gestational diabetes mellitus <i>A. Familiari (Italy)</i>	OP21.09

OP22: NIPT: issues and implementation

Chairs: J. Stirnemann (France); B. Tutschek (Switzerland)

Prenatal diagnosis of sex chromosome aneuploidies before and after NIPT: an analysis of 30 years of population-based data <i>L. Hui (Australia)</i>	OP22.01
The determination of fetal sex using cell-free DNA testing <i>M. Hynek (Czech Republic)</i>	OP22.02
Should pre-NIPT genetic counselling for sex chromosome aneuploidies be obligatory? A clinical audit of 5409 mixed risk pregnancies <i>F. da Silva Costa (Australia)</i>	OP22.03
Non-invasive prenatal testing (NIPT) for 22q11.2 deletion syndrome using a targeted microarray-based cell-free DNA (cfDNA) test <i>M. Schmid (United States)</i>	OP22.04
Changes in the utilisation of prenatal screening and diagnosis of chromosomal abnormalities in the era of cell-free DNA <i>K.Y. Leung (Hong Kong)</i>	OP22.05
Changing trend in common chromosomal aneuploidy management in the United Kingdom <i>H. Gandhi (United Kingdom)</i>	OP22.06
Validation of NIPT as a screening test for Trisomy 21, 18, 13 and fetal sex performed at Hvidovre Hospitals NIPT Centre, Copenhagen, Denmark <i>T.S. Hartwig (Denmark)</i>	OP22.07
Integrating ultrasound findings with chromosomal microarray stretches of homozygosity and principles in founder populations <i>S. Yagel (Israel)</i>	OP22.08
Does NIPS change the spectrum of detected major chromosomal aberrations (CHA)? Population-based data <i>P. Calda (Czech Republic)</i>	OP22.09
Characteristics of 'no-calls' from non-invasive prenatal testing (NIPT) performed at Hvidovre Hospitals NIPT Centre, Copenhagen, Denmark <i>T.S. Hartwig (Denmark)</i>	OP22.10

OP23: Invasive procedures: new data

Chairs: A. Gagnon (Canada); M. Yamamoto (Chile)

Amniocentesis and cerclage: an invasive strategy to exclude patients with intra-amniotic infection before treatment <i>J. Vojtech (Czech Republic)</i>	OP23.01
Percutaneous transvenous chorionic villus sampling: an alternative method for difficult procedures <i>P.I. Cavoretto (Italy)</i>	OP23.02
Factors associated with the risk of intrauterine demise in Twin-twin transfusion syndrome cases treated with laser ablation <i>A. Khalil (United Kingdom)</i>	OP23.03

Hall A

Hall E

Selective reduction in complex triplet pregnancy by radio frequency ablation: single centre experience <i>E. Sanna (United Kingdom)</i>	OP23.04
Procedure outcomes of embryo reduction and selective feticide with multifetal pregnancy to twin or singleton pregnancy: a retrospective study <i>M. Kim (Republic of Korea)</i>	OP23.05
Time and temperature dependence of radiofrequency ablation in human placenta <i>P. Makarasen (Thailand)</i>	OP23.06
Comparison between neodymium-doped yttrium aluminium garnet (Nd: YAG) and Diode lasers in different power and duration of interstitial laser ablation in human placental model <i>D. Hunsawongsakul (Thailand)</i>	OP23.07
Longitudinal growth evaluation in fetuses with neural tube defect with and without prenatal-fetoscopic and open-repair <i>M. Sanz Cortes (United States)</i>	OP23.08
Perinatal outcome in fetuses with dislodged pleuro-amniotic shunts (PAS) <i>N. Abbasi (Canada)</i>	OP23.09
Best timing for sequential intrauterine transfusion in fetal alloimmune anemia <i>J. Rodriguez Calvo (Spain)</i>	OP23.10

OP24: Uterine and endometrial problems: from elastography to using ultrasound to monitor treatment response

Hall F

Chairs: P. Schwärzler (Austria); L. Valentin (Sweden)

Ultrasound features of atypical endometrial hyperplasia <i>L. Jokubkiene (Sweden)</i>	OP24.01
Combination of use of dienogest with LNG IUD Mirena <i>K. Tokhunts (Armenia)</i>	OP24.02
Sonography before and after hysteroscopic management of isthmocoele: is the myometrial wall reconstructed? <i>P. Capmas (France)</i>	OP24.03
Value of "elasto strain ratio" ultrasound elastography in the diagnosis of intramural uterine fibroids: preliminary study <i>P.R. Szkodziak (Poland)</i>	OP24.04
Highly vascularised uterine myomas at ultrasound and correlation to histopathology <i>S. Camilli (Italy)</i>	OP24.05
Comparison of 2D and 3D-transvaginal sonography to assess endometrial thickness <i>F. Leone (Italy)</i>	OP24.06
Proliferative endometrium in postmenopausal bleeding: clinical and sonographic characteristics and long-term outcome <i>O. Rotenberg (United States)</i>	OP24.07
Combined treatment with the levonorgestrel-releasing intrauterine device and ulipristal acetate in patients with uterine adenomyosis <i>S. Ferrero (Italy)</i>	OP24.08
Ulipristal acetate (UPA) therapy increased ultrasound features of adenomyosis: a good treatment given in an erroneous diagnosis of uterine fibroids <i>F. Conway (Italy)</i>	OP24.09

OP25: Clinical challenges in chorionicity**Hall B***Chairs: K. Hecher (Germany); Y. Ville (France)*

Natural history of early selective intrauterine growth restriction in monochorionic diamniotic pregnancies <i>C. Colmant (France)</i>	OP25.01
Experience of selective reduction by radiofrequency ablation in complicated monochorionic twin pregnancy between 2007 and 2016 <i>S. Wavrant (Canada)</i>	OP25.02
Iatrogenic preterm prelabour rupture of membranes after umbilical cord occlusion in monochorionic diamniotic pregnancies <i>T. Micheletti (Spain)</i>	OP25.03
Perinatal outcomes of fetoscopic laser photocoagulation for monochorionic twin gestation with selective intrauterine growth restriction accompanied by oligohydramnios <i>K. Ishii (Japan)</i>	OP25.04
Selective intrauterine growth restriction monochorionic diamniotic twin pregnancies: outcomes from a tertiary centre in Western Australia <i>W. Almeida (Australia)</i>	OP25.05
Selective feticide in monochorionic dizygotic twins discordant for heart anomaly and sIUGR with prenatally confirmed blood chimerism <i>Y. Sciaky Tamir (Israel)</i>	OP25.06
First trimester inter- and intrafetal size discrepancies in bichorionic twins conceived by <i>in vitro</i> fertilisation: can it predict pregnancy outcome? <i>R. Bardin (Israel)</i>	OP25.07
Prognostic value of intra-amniotic interleukin-6 and cervical length in monochorionic twins after fetal surgery <i>J. Vojtech (Czech Republic)</i>	OP25.08
Cervical length <i>F. Moretti (Canada)</i>	OP25.09
Outcomes of emergency cerclage placement in twin pregnancy <i>H. Boo (Republic of Korea)</i>	OP25.10

P - Monday 18.09.2017

P12: Cysts and other abdominal features

L3 / L6 Hub 1

Chair: *S. Seshadri (India)*

Fetal cystic mass which was found out as fetus in fetu	P12.01
<i>W. Kim (Republic of Korea)</i>	
Morgagni diaphragmatic hernia presenting with massive pericardial effusion	P12.02
<i>J. Miguez (Brazil)</i>	
Fetal congenital imperforate hymen	P12.03
<i>L. Ortega Cárdenes (Spain)</i>	
Congenital megalourethra: a rare form of obstructive uropathy	P12.04
<i>D. Atanassova (Bulgaria)</i>	
Sacrococcygeal fetiform teratoma in a male fetus	P12.05
<i>L. Wang (China)</i>	
Prenatal diagnosis of a warfarin-associated fetal hemoperitoneum: a case report	P12.06
<i>S. Wavrant (Canada)</i>	
Prenatal diagnosis of an extensive congenital lymphatic malformation as a starting point for sirolimus therapy after birth: a case report	P12.07
<i>M. Hynek (Czech Republic)</i>	
Isolated fetal ascites: diagnostic algorithm and management protocol	P12.08
<i>M. Eldarawi (Egypt)</i>	
Fetal intra-abdominal umbilical vein varix: a retrospective cohort study, systematic review of the literature and meta-analysis	P12.09
<i>L.J. Salomon (France)</i>	
Prenatal and postnatal evolution of 14 cases of fetal splenic cysts	P12.10
<i>F. Fuchs (France)</i>	
Prenatal severe hydronephrosis: the added value of CAKUT in the prediction of postnatal outcome	P12.11
<i>S. Perlman (Israel)</i>	

P13: Ultrasound in the labour ward II

L3 / L6 Hub 2

Chair: *L.D. Platt (United States)*

The role of caput in accuracy of assessing fetal position in labour	P13.01
<i>J. Goldkamp (United States)</i>	
The role of prior vaginal delivery and fetal station in assessing fetal position in labor	P13.02
<i>J. Goldkamp (United States)</i>	
Correlations of the sonopartogram with classic clinical partogram and key points from a pilot study	P13.03
<i>D.G. Iliescu (Romania)</i>	
The role of ultrasound in prediction of successful induction of labour	P13.04
<i>V. Marsoosi (Islamic Republic of Iran)</i>	
Can the "dynamic" assessment of intrapartum ultrasound parameters serve a better predictor for mode of delivery?	P13.05
<i>N.A. Elbarbary (Egypt)</i>	
Ultrasound evaluation of safely of postpartum hemorrhage (PPH) compression belt in reduction of uterine, internal iliac and femoral artery blood flow in healthy postpartum women	P13.06
<i>T. Dias (Sri Lanka)</i>	
Acceptability of transabdominal and transperineal ultrasound compared to vaginal examinations prior to delivery	P13.07
<i>S. Usman (United Kingdom)</i>	

Intrapartum sonographic diagnosis of malpositions and cephalic malpresentations P13.08

F. Bellussi (Italy)

Is a prolonged second stage of labour too long? P13.09

S. Yagel (Israel)

P14: Uterine and endometrial problems: from elastography to using ultrasound to monitor treatment response **L3 / L6 Hub 3**

Chair: E. Epstein (Sweden)

Evaluation of intramural fibroid vascularisation after uterine artery embolisation by 3D power Doppler ultrasound P14.01

P. Czuczwar (Poland)

Ultrasonographic evaluation of possible endometrial pathology in symptomatic women via IETA and MUSA rules P14.02

E. Domali (Greece)

Inter- and intrarater reproducibility in detecting deep myometrial invasion and cervical stromal invasion using 2D-TVU and 3D-VCI P14.03

R.W. Green (Sweden)

Atypical glandular cells and ultrasound changes: is there a relationship? P14.04

M.D. Bernardo (Portugal)

Macroscopic endometrial findings in patients with myomas treated with ulipristal acetate: ultrasonographic and hysteroscopic correlations with histologic analysis P14.05

C. Ros (Spain)

Ulipristal acetate in the treatment of fibroids: report of the initial experience of a tertiary centre in Portugal P14.06

J. Pereira (Portugal)

Thickened endometrium secondary to continuous ulipristal acetate treatment P14.07

M. Munmany (Spain)

Focal endometrial pathology, ultrasound, hysteroscopy and histology: what is the correlation between them? P14.08

A. Galvão (Portugal)

Ultrasound markers of impending intrauterine adhesions: new data about natural history and prevention P14.09

T. Amin (United Kingdom)

Factors associated with inconsistency in visibility of the endometrial echo on transvaginal ultrasound of postmenopausal women P14.10

P. Dar (United States)

Review of current evidence on investigations for postmenopausal bleeding by transvaginal scan followed by hysteroscopy: gap in clinical effectiveness P14.11

E. Zielinski (United Kingdom)

3D parameters via Render Mode during transvaginal ultrasonography and endometrial malignancy P14.12

E. Domali (Greece)

Ultrasound-guided transvaginal thrombin injection to treat uterine arteries pseudoaneurysms P14.13

C. Ros (Spain)

Acquired uterine arteriovenous malformation (AVM): case series P14.14

A.E. Dominguez (Philippines)

P15: Improving the outcome of fetal procedures **L3 / L6 Hub 4**

Chair: A. Johnson (United States)

Procedure-to-delivery interval after late amniocentesis (28 and 33 weeks): is there a rationale in giving glucocorticoids prior to the procedure? P15.01

K.K. Haratz (Israel)

Amniotic band syndrome: literature review of prenatal therapy <i>M. Yamamoto (Chile)</i>	P15.02
Antenatal diagnosis of lower urinary tract obstructions (LUTO): a prediction model to improve the diagnostic accuracy <i>F. Fontanella (Netherlands)</i>	P15.03
Non-invasive <i>in utero</i> treatment of twin reversed arterial perfusion sequence by improved high-intensity focused ultrasound systems <i>K. Ichizuka (Japan)</i>	P15.04
Predicting intrauterine transfusion interval in isoimmunised pregnancies that undergo fetal therapy <i>J. Snelgrove (Canada)</i>	P15.05
The relationship between perioperative cervical dynamics and the interval to delivery after fetoscopy <i>J.L. Miller (United States)</i>	P15.06
Fetoscopic tracheal occlusion for congenital diaphragmatic hernia in Japan: the feasibility and preliminary results of lung volume analyses <i>H. Saga (Japan)</i>	P15.07
Preliminary application of biplane mode using real time electronic 4D technology for fetal intervention <i>Y. Takahashi (Japan)</i>	P15.08
The impact of operative fetoscopy on the cervical length <i>J.L. Miller (United States)</i>	P15.09
Embryo reduction in trichorionic triplets: effect on time to delivery and birthweight discordance <i>E. Kalafat (Turkey)</i>	P15.10

P16: Screening for fetal anomalies

L3 / L6 Hub 1

Chair: K.O. Kagan (Germany)

The value of prenatal chromosomal microarray analysis in fetuses with structural ultrasound abnormalities and a normal karyotype in China <i>Q. Wu (China)</i>	P16.01
Detecting aneuploidies and subchromosomal abnormalities by use of circulating fetal trophoblast cells in maternal blood <i>O.B. Petersen (Denmark)</i>	P16.02
Alterations in placental development in Down's syndrome fetuses mirror differences of miRNA profiles <i>P. Calda (Czech Republic)</i>	P16.03
Prevalence of submicroscopic chromosome aberrations in pregnancies without increased risk for structural chromosome aberrations: a systematic review of the literature <i>M. Joosten (Netherlands)</i>	P16.04
The influence of chromosomal microarray and NIPT on the diagnostic yield in 6,811 high-risk pregnancies without ultrasound anomalies <i>M.I. Srebniak (Netherlands)</i>	P16.05
First trimester ultrasound screening for Trisomy 21 based on maternal age, fetal nuchal translucency and different methods of ductus venosus assessment <i>K.O. Kagan (Germany)</i>	P16.06
Screening for fetal aneuploidy and major abnormalities at 11–13 weeks' gestation, local particularities <i>D. Nemescu (Romania)</i>	P16.07
Non-mosaic Trisomy 21 from CVS and subsequent normal karyotype from amniocentesis: a rare case of fetoplacental discordance <i>E. Thia (Singapore)</i>	P16.08
Optimal genetic testing for failed cell-free DNA results: a tricky task <i>J. Miguez (Brazil)</i>	P16.09
False-negative NIPT and the role of placental mosaicism <i>A.M. Adna (Australia)</i>	P16.10

P17: Maternal and fetal assessment in complicated pregnancies L3 / L6 Hub 3*Chair: M. Herrera (Colombia)*

- The maternal hepatic and uteroplacental blood flow in pregnant women with hepatic dysfunction during pregnancy P17.01
I.V. Ignatko (Russian Federation)
- Hepatic steatosis: a prenatal process? P17.02
V. Berger-Kulemann (Austria)
- Risk factor survey for intrauterine deaths among mothers who attend Teaching Hospital Peradeniya over last five years P17.03
J.P. Jayasinghe (Sri Lanka)
- Perinatal risk scale: detection of perinatal risk degree based on the results of antenatal ultrasonographic monitoring P17.04
I. Safonova (Ukraine)
- Relationship between uterine artery Doppler and the risk of stillbirth in our population P17.05
N. Caner (Spain)
- Updating amniotic fluid index nomogram according to perinatal outcome P17.06
R. Bardin (Israel)
- WITHDRAWN P17.07
- Differences in three-dimensional power Doppler vascularisation indices in placenta syndrome compared to healthy pregnancies: a pilot study P17.08
V. Schiffer (Netherlands)
- Assessment and validation of a novel three-dimensional power Doppler VOCAL sonobiopsy technique P17.09
D. Pellaers (Netherlands)
- Pre-pregnancy exercise test hemodynamic responses are related to birthweight in subsequent pregnancy P17.11
J. Man (United Kingdom)

P18: Techniques related to using ultrasound to assess pelvic pain and diagnose superficial endometriosis and DIE L3 / L6 Hub 4*Chairs: G. Condous (Australia); G. Hudelist (Austria)*

- Transvaginal diagnosis of endometrioma: how often are there other endometriosis pelvic lesions? P18.01
C. Exacoustos (Italy)
- Prevalence of negative 'sliding sign' in low-risk population: a feasibility study P18.02
B. Shakeri (Australia)
- Learning curve for the ultrasonographic diagnosis of deep endometriosis using an intensive training program P18.03
S. Guerriero (Italy)
- Transvaginal ultrasound (TVS) combined evaluation of pelvic sites of implants and the "sliding sign" to predict likelihood of rectal/rectosigmoid deep infiltrating endometriosis (DIE) at laparoscopy P18.04
M. Espada (Australia)
- Many faces of whirlpool in patients with adnexal torsion P18.05
A.N. Joshi (India)
- Bowel preparation prior to transvaginal ultrasound improves the diagnosis of rectosigmoid deep infiltrating endometriosis: a prospective study P18.06
C. Ros (Spain)
- Caesarean scar endometriosis: case series – ultrasound and Doppler characteristics P18.07
K. Rathod (India)
- Bowel resection for DIE: 2D and 3D transvaginal sonographic evaluation of residual disease and associated symptoms P18.08
F.G. Martire (Italy)
- Retzius' retroperitoneal bladder endometriosis: a new entity of an enigmatic disease P18.09
F. Leone (Italy)

Correlation between laparoscopic macroscopic appearance of superficial endometriosis and histopathological confirmation P18.10
B. Nadim (Australia)

P19: Fetal echocardiography II

L3 / L6 Hub 2

Chair: W. Lee (United States)

Application of different frame rates in two-dimensional speckle-tracking in fetal echocardiography and their influence on strain analysis P19.01

C. Enzensberger (Germany)

The effects of maternal diabetes on fetal heart function: a systematic review P19.02

A.L. Depla (Netherlands)

Evaluation of emerging modalities for fetal global cardiac function assessment in normal pregnancies P19.03

H. Avnet (Australia)

Fetal atrioventricular time intervals assessed by three different pulsed-wave Doppler methods P19.04

S. Anuwutnavin (Thailand)

Speckle-tracking echocardiography and myocardial ventricular performance in fetuses with left ventricular obstruction P19.05

M. Bellotti (Italy)

Gestational diabetes (GDM) and fetal myocardial function: evaluation using speckle-tracking echocardiography (STE) and traditional echocardiography P19.06

M. Bellotti (Italy)

High incidence of abnormal Tei index in the fetuses with maternal anti SS-A antibody P19.07

Y. Maeno (Japan)

Growth and arterial Doppler in fetuses with congenital heart disease P19.08

V. Jowett (United Kingdom)

Preoperative cardiac time intervals in recipient twin in Twin-twin transfusion syndrome in relation to Quintero stage P19.09

M. Gijtenbeek (Netherlands)

Cardiac dysfunction in TTTS donor and recipient twins: same effect on myocardial performance index time intervals? P19.10

J.U. Ortiz (Spain)

Novel technique to assess fetal fractional shortening by two-dimensional tracking P19.11

S. Nagasaki (Japan)

Ultrasonic screening of fetal cardiac structure in the first trimester P19.12

Y. Wu (China)

P20: The prognostic value of growth parameters

L3 / L6 Hub 1

Chair: C. Brezinka (Austria)

Third-trimester prediction of late fetal growth restriction by longitudinal versus cross-sectional assessment P20.01

S. Triunfo (Spain)

Prediction of adverse perinatal outcomes using fetal biometric parameters in women with gestational diabetes mellitus: a Korean multicentre study P20.02

H. Kim (Republic of Korea)

Long-term prognosis of fetal growth restriction and association with autistic spectrum disorder P20.03

T. Shiga (Japan)

Longitudinal growth assessment for the prediction of adverse perinatal outcome among SGA-suspected fetuses P20.04

J. Caradeux (Spain)

Prediction of large-for-gestational-age neonates in *in vitro* fertilisation pregnancies and Crown-rump length at 11–13+6 weeks' gestation P20.05

D. Kwak (Republic of Korea)

The accuracy of prenatal ultrasound in predicting fetal birthweight in diabetic singleton pregnancies <i>C. Nash (Canada)</i>	P20.06
Abdominal circumference growth velocity and cerebroplacental ratio as predictors of perinatal outcome in small-for-gestational-age fetuses <i>A. Cavallaro (United Kingdom)</i>	P20.07
Prediction of small-for-gestational-age neonate in a cohort of estimated normal weight fetuses at term <i>A. Laoreti (United Kingdom)</i>	P20.08
The probability of cephalic presentation across pregnancy in the INTERGROWTH-21st fetal growth longitudinal study <i>L. Salim (United Kingdom)</i>	P20.09
Prediction of large-for-gestational-age neonate in a cohort of estimated normal weight fetuses at term <i>A. Laoreti (United Kingdom)</i>	P20.10
Small-for-gestational-age (SGA) fetuses are at higher risk of neonatal unit (NNU) admission: we aimed to develop and validate a predictive model for the risk of NNU admission in SGA fetuses at term <i>E. Kalafat (Turkey)</i>	P20.11

P21: Predicting pregnancies at risk

L3 / L6 Hub 2

Chair: B. Thilaganathan (United Kingdom)

Perinatal outcomes of pregnancies conceived by assisted reproductive technologies in an 11+0–13+6 weeks' screening program <i>A. Sepúlveda-Martínez (Chile)</i>	P21.01
In high-risk women, first trimester blood pressure elevation below current treatment thresholds leads to pre-eclampsia <i>J.L. Miller (United States)</i>	P21.02
First trimester pre-eclampsia screening in low-risk nulliparous women: the great obstetrical syndrome (GOS) study <i>A. Boutin (Canada)</i>	P21.03
First trimester prediction of pre-eclampsia in high-risk women using 3D power Doppler placental vascularisation indices <i>K. Eastwood (United Kingdom)</i>	P21.04
Prediction of pre-eclampsia by biochemical and biophysical markers at first trimester among Mongolian pregnant women <i>U. Tserensambuu (Mongolia)</i>	P21.05
Perinatal risk degree determination: the role of ductus venosus flow, cerebroplacental ratio and cardiothoracic ratio <i>L. Safonova (Ukraine)</i>	P21.06
Association between uterine artery blood flow volume and fetal weight gain <i>H. Arneberg (Norway)</i>	P21.07
Diagnosis of metabolic risk during pregnancy by body mass index (BMI): does a better method exist? Preliminary results <i>A. Rocha (Brazil)</i>	P21.08
Incorporation of vasa previa screening into a routine anomaly scan <i>D. Nyberg (United Kingdom)</i>	P21.09
Development of vasa previa with advancing gestation from placental and umbilical cord vessels in the lower uterine segment <i>J. Hasegawa (Japan)</i>	P21.10
Third-trimester sonographic evaluation of intra-abdominal adhesions in patients with previous Caesarean section <i>J. Baron (Israel)</i>	P21.11

P22: Fetal echocardiography III**L3 / L6 Hub 3***Chair: F. Crispi (Spain)*

- Fetal echocardiography and pregnancy outcome in Serbia
S. Vrzic Petronijevic (Serbia) P22.01
- Polish National Registry for fetal cardiac anomalies in 2016
M. Respondek-Liberska (Poland) P22.02
- Electronic STIC improves four-dimensional fetal echocardiography
E. Bellussi (Italy) P22.03
- Clinical value of chromosomal microarray analysis in prenatally diagnosed transposition of the great arteries
M. Lee (Republic of Korea) P22.04
- Outcome of pregnancy after the prenatal diagnosis of isolated major congenital heart diseases
S. Tudorache (Romania) P22.05
- HDliveFlow with spatiotemporal image correlation for diagnosing congenital heart diseases
M.A. AboEllail (Japan) P22.06
- Clinical significance of prenatal ultrasound diagnosis on fetal with congenital conotruncal defects and category from northwest China: a single centre experience
T. Zhu (China) P22.07
- Characteristics of interventricular shunt flow in fetuses with isolated ventricular septal defect assessed by dual Doppler imaging
T. Kaji (Japan) P22.08
- Prenatal ultrasonic diagnosis of isolated left subclavian artery and left brachiocephalic trunk malformation
Q. Pei (China) P22.09
- Prenatal diagnosis of fetal aberrant subclavian artery: associated anomalies and perinatal outcome in 104 cases
M. Xie (China) P22.10
- Systematic evaluation of the fetal hepatic venous system in mid-trimester scan (CASSEAL protocol in a multicentric study)
C. Bravo (Spain) P22.11

P23: Managing early pregnancy complications**L3 / L6 Hub 4***Chairs: S. Bobdiwala; D. Jurkovic (United Kingdom)*

- Doppler colour scoring system using offline video analysis in women with an incomplete miscarriage: inter- and intraobserver reproducibility study
G.T. Leong (Australia) P23.01
- Ectopic pregnancies and treatment: surgery is not the only choice
E. Domali (Greece) P23.02
- Comparison of risk factors and diagnostic term of tubal pregnancy and low-lying implantation ectopic pregnancy
V. Makukhina (Russian Federation) P23.03
- The value of 3D Doppler indices in prediction of successful medical treatment in missed abortion
M. Odeh (Israel) P23.04
- Medical termination of pregnancy in a tertiary centre in Greece: a case series of a diverse population including refugees and travellers
E. Domali (Greece) P23.05
- Hemoperitoneum and ectopic pregnancy does not always mean surgery
B. Nadim (Australia) P23.06
- Ultrasound markers prior to 8 weeks' gestational age for the prediction of fetal demise prior to 12 weeks gestation
T.J. Taylor (Australia) P23.07

ISUOG Outreach trainers workshop

ISUOG will be hosting its first Outreach trainers workshop during the World Congress.

During this two hour session, attendees will gain an understanding of ISUOG's outreach mission and vision, the cultural preparation needed, what to expect once you're there and the continuation of the relationships once the trip has finished. Expert trainers will share best practice, provide real life examples, answer questions and allow others to share their experiences.



Date: : Tuesday 19 September 2017

Time: 08.30-10.30

Location: Hall B

Program: Please see page 101

Course Chairs:

Anthony Johnson (USA)

Gesù Antonio Báez (ISUOG International Development Coordinator, UK/Italy)

Speakers:

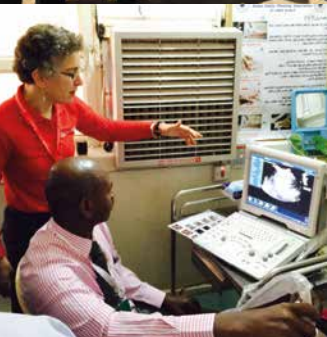Ann Tabor (Denmark)

Reem Abu-Rustum (Lebanon)

Lisbet Hanson (USA)

Theodora Pepera-Hibbert (UK/Ghana)

Eleni Xilakis (ISUOG Education Officer, UK)



Discover more about volunteering:
outreach@isuog.org

 **isuog**.org

13000+

ISUOG members in 127 countries

4468 trainees

100 international partnerships

UOG

1,881,467

downloads (+94,300)

120,000

App page views



Impact Factor:

4.71



26th WORLD CONGRESS - Rome

2700 DELEGATES

over 96% would recommend the Congress

1211 abstract submissions | 5 travel grants


BASIC TRAINING

281

delegates

from 29 countries
6.1/7 satisfaction

ISUOG Education



2016

INTENSIVE COURSES

185 live delegates

510

livestream

71 countries

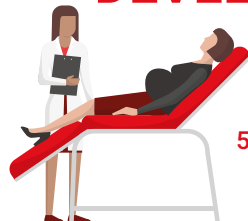ONLINE LEARNING

+500 online lectures



90658 On Demand views
832 users of CME activities

INTERNATIONAL DEVELOPMENT



Outreach Sudan

30 trainees

155 patients

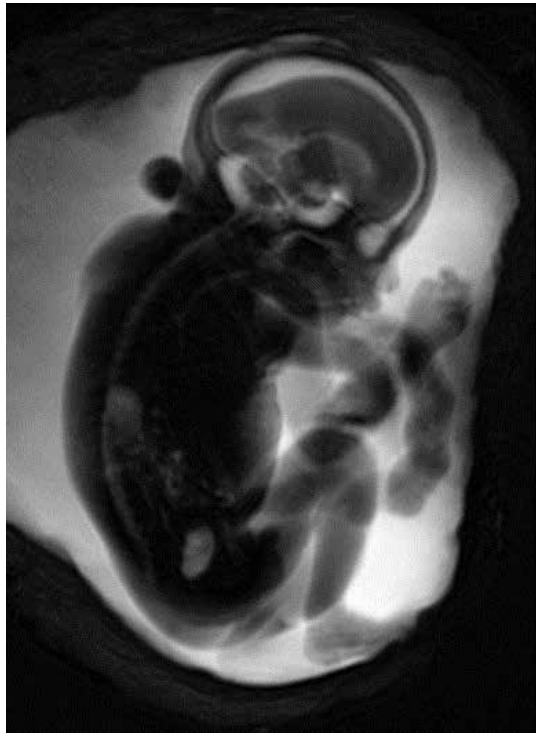
58 Approved courses

7,864 delegates

Guidelines in 17 languages

SCIENTIFIC PROGRAM

Tuesday 19 September 2017



MRI fetus - Prayer D, Malinge G, Brugger PC, Cassidy C, De Catte L, De Keersmaecker B, Fernandes GL, Glanc P, Gonçalves LF, Gruber GM, Laifer-Narin S, Lee W, Millischer AE, Molho M, Neelavalli J, Platt L, Pugash D, Ramaekers P, Salomon LJ, Sanz M, Timor-Tritsch IE, Tutschek B, Twickler D, Weber M, Ximenes R, Raine-Fenning N. ISUOG Practice Guidelines: performance of fetal magnetic resonance imaging. *Ultrasound Obstet Gynecol* 2017; 49: 671–680.

Tuesday 19.09.2017

HALL A

07:30-08:10

Masterclass

The first trimester anomaly scan
C.M. Bilardo (Netherlands)

08:15-09:15

State-of-the-art techniques to image the fetus

*Chairs: K.O. Kagan (Germany);
F. da Silva Costa (Australia)*

08:15 **INVITED:** What you can do with ultrasound in 2017

B. Benoit (France)

08:35 **OC18.01** Fetal enhanced tridimensional and translational anatomical landscape: FETAL Project

A. Lamouroux (France)

08:43 **OC18.02** Magnetic resonance imaging (MRI) T1 relaxation properties of fetal blood in normal and in suspected anemic fetuses

D. Jørgense (Denmark)

08:51 ^{YI}**OC18.03** Superb microvascular imaging of the fetus, placenta and umbilical cord

K. Yamamoto (Japan)

08:59 **OC18.04** Ultrasound-based computer-aided tracking technique of fetal breathing movement analysis for intrauterine growth restriction

I. Mendilcioglu (Turkey)

09:07 **OC18.05** Echogenicity of the fetal bowel using histogram gray-scale analyser: a comparison between normal fetuses and fetuses with echogenic bowel (EB)

L. Maggio (Netherlands)

09:20-10:00

Short oral presentation (OP)

OP26 Managing TTTS
Chair: K. Hecher (Germany)

HALL E

Masterclass

Screening for chromosomal anomalies: cfDNA for all, cFTS for all, microarray for all!
L.J. Salomon (France)

Is this placenta abnormally invasive?

*Chairs: A. Bhide (United Kingdom);
I. Timor-Tritsch (United States)*

08:15 **INVITED:** Placenta accreta: screening, diagnostic and management options

A. Bhide (United Kingdom)

08:35 **OC19.01** Comparison of ultrasound descriptors of abnormally invasive placenta (AIP) in second versus third trimester: is an increase verifiable?

M.E. Gorczyca (Austria)

08:43 **OC19.02** The natural development of low-lying placentas diagnosed in the second trimester

A. Kaelin Agten (United Kingdom)

08:51 **OC19.03** Evaluating the accuracy of ultrasonography in predicting morbidly adherent placenta using a scoring system

B.S. Albagawi (Saudi Arabia)

08:59 **OC19.04** Validation of the placenta accreta index by ultrasound to predict morbidly adherent placenta

D.M. Twickler (United States)

09:07 **OC19.05** The tramline sign for abnormally invasive placenta using Crystal Vue with flow

A. Dall'Asta (Italy)

Short oral presentation (OP)

OP27 How to diagnose and manage abnormal placentation
Chairs: P. Calda (Czech Republic); D.M. Twickler (United States)

^{YI} This presentation is eligible for the Young Investigator award (to be presented in the closing plenary).

HALL F

Masterclass

Examining women with pelvic pain: how I do it (case examples)

B. Benacerraf (United States)

Solving problems in urogynecology including data from the OASIS trial

Chairs: S. Yagel (Israel); I. Geiss (Austria)

08:15 **OC20.01, OC20.02, OC20.03** Pelvic ultrasound examination to predict labour outcome

A. Youssef (Italy)

08:38 **OC20.04** The effect of a repeat delivery on long-term outcome in women with obstetric anal sphincter injury (OASIS): a prospective longitudinal ultrasound study

V.H. Eisenberg (Israel)

08:46 **OC20.05** Changes in urethral mobility and kinking after prolapse repair

H.P. Dietz (Australia)

08:54 **OC20.06** Are we getting better at diagnosing, treating and managing obstetric anal sphincter injuries (OASIS)?

V.H. Eisenberg (Israel)

09:02 **OC20.07** Is there an association between imaging and urodynamic findings after suburethral sling?

H.P. Dietz (Australia)

Short oral presentation (OP)

OP28 Solving problems in urogynecology using ultrasound

Chairs: A. Youssef (Italy); I. Geiss (Austria)

HALL B

Masterclass

Computerised fetal heart rate analysis in high-risk pregnancy

C. Redman (United Kingdom)

Workshop

08:30-10:30

Working in the field: ISUOG Outreach trainers workshop

Chairs: A. Johnson (United States); G.A. Báez (United Kingdom)

Introduction

08:30 Understanding ISUOG vision and Outreach mission

A. Johnson (United States)

08:40 Anatomy of the Outreach program

A. Johnson (United States)

08:45 The role of the Outreach volunteer

R. Abu-Rustum (Lebanon)

Cultural preparation

08:55 Understanding the dynamics of your destination

G.A. Báez (United Kingdom)

09:05 Understanding culture shock and how to prepare

G.A. Báez (United Kingdom)

On the ground

09:10 Pedagogical approach: how to interact and teach knowledge and skills

E. Xilakis (United Kingdom)

09:15 Outreach training: how to comprehend the trainees educational needs and how to attune your content and teach accordingly

A. Tabor (Denmark)

09:20 How to work with ISUOG templates

A. Tabor (Denmark)

09:30 How to assess learning: pre and post tests

R. Abu-Rustum (Lebanon)

09:35 Hands-on training: what to expect and how to manage

T. Pepera-Hibbert (United Kingdom)

09:40 Empowering trainees for ownership

T. Pepera-Hibbert (United Kingdom)

After the trip

09:50 Continuing the relationship post training: mentoring

L. Hanson (United States)

10:00 Assessing feedback and evaluating

L. Hanson (United States)

10:05 Trainers share their experience

10:15 Q&A with speakers

HALL A

09:50-10:20 Coffee and e-poster viewing

10:20-11:20

Advanced cytogenetic techniques: impact on ultrasound practice

Chairs: L. Hui (Australia); D. Bettelheim (Austria)

DEBATE: is it still worth measuring nuchal translucency in 2017?

For: D. Bettelheim (Austria)

10:30 *Against: J. Hyett (Australia)*

10:40 Speaker rebuttals and voting

10:48 **OC21.01** Whole-genome array as a first-tier cytogenetic test in routine prenatal diagnosis
M. Hynek (Czech Republic)

10:56 **OC21.02** Fetal abnormalities associated with increased nuchal translucency versus cell-free fetal DNA
F. Bardi (Netherlands)

11:04 **OC21.04** Chromosomal microarray as a primary diagnostic genomic tool for pregnancies defined as being at increased risk within a population-based combined first trimester screening program
L. Vogel (Denmark)

11:12 **OC21.05** Implications of inconclusive results in prenatal maternal serum cell-free DNA testing
M. Smet (Australia)

11:25-12:05

Short oral presentation (OP)

OP29 Education, simulation and safety

Chair: S. Eik-Nes (Norway)

12:00-13:30

Lunch and e-poster viewing

12:15-13:15

Industry sponsored satellite symposia**

HALL E

Coffee and e-poster viewing

Workshop

3D/4D ultrasound: is it living up to its promise?

Chairs: J. Deng (United Kingdom); L. Gindes (Israel)

DEBATE: 3D/4D has proven its clinical utility

For: R. Chaoui (Germany)

10:20 *Against: A. Abuhamad (United States)*

10:27 Rebuttal (speaker 1)

10:34 Rebuttal (speaker 2)

10:37 Audience vote and results

10:40 3D/4D specific artefacts: how to recognise, minimise and avoid them
J. Deng (United Kingdom)

10:45 3D uterine malformations: clinical classifications old and new
B. Benacerraf (United States)

10:55 3D and 4D pelvic floor exploration
A. Youssef (Italy)

Short oral presentation (OP)

★ **OP30** Fetal brain novel applications of ultrasound and MRI (11:30-12:10)

Chairs: J. Hyett (Australia); A. Toi (Canada)

Lunch and e-poster viewing

**Lunchtime satellite symposia are brought to you by our sponsors and are not part of the ISUOG CME program. ISUOG takes no responsibility for scientific or clinical content. Please see page 158 for our satellite program.

HALL F

Coffee and e-poster viewing

How ultrasound is used to assess women with pelvic pain and diagnose endometriosis

Chairs: G. Condous (Australia); S. Guerriero (Italy)

- 10:20 **INVITED:** Establishing a uniform approach to the reporting of DIE using ultrasound
G. Condous (Australia)
- 10:40 **OC22.01** Transvaginal sonography-based minimal invasive surgery for urinary tract endometriosis: test accuracy and outcomes
G. Hudelist (Austria)
- 10:48 **OC22.02** Diagnostic accuracy of the transvaginal ultrasound “sliding sign”, direct visualisation and combination of both for the prediction of deep infiltrating endometriosis of the rectum and the rectosigmoid
M. Espada (Australia)
- 10:56 **OC22.03** The relationship between gastrointestinal symptoms and ultrasound findings in women with suspected endometriosis: a prospective pilot study
V.H. Eisenberg (Israel)
- 11:04 **OC22.04** Transvaginal ultrasonography combined with computed tomographic colonography in the diagnosis of bowel endometriosis
S. Ferrero (Italy)
- 11:12 ^{YI}**OC22.05** 3D transvaginal ultrasound in adenomyosis: are we looking at all there is?
T. Tellum (Norway)

Short oral presentation (OP)

OP31 Using ultrasound to assess pelvic pain and diagnose endometriosis

Chairs: S. Ferrero (Italy); G. Hudelist (Austria)

Lunch and e-poster viewing

^{YI} This presentation is eligible for the Young Investigator award (to be presented in the closing plenary).

HALL A

13:30-14:50

Workshop Ultrasound and genetic diagnostics at 12 weeks

*Chairs: A. Tabor (Denmark);
E. Krampfl-Bettelheim (Austria)*

- 13:30 The scope of sonographic screening and of a detailed anatomical survey at 12 weeks
B. Tutschek (Switzerland)
- 13:50 **LIVE SCAN:** how I optimise detection of anomalies at 12 weeks [industry supported*]
C.M. Bilardo (Netherlands)
- 14:10 The potential of the biochemical component of combined screening in the era of NIPT: beyond T21/18/13
A. Tabor (Denmark)
- 14:30 Non-invasive screening for genetic conditions: where will we be by Berlin 2019?
S. Yagel (Israel)

14:50-16:20

Closing plenary: show us the power of ultrasound

*Chairs: G. Condous (Australia);
L.J. Salomon (France); G. Yeo (Singapore)*

- 14:50 Awards presentation: Top abstract, Young Investigator and best in category
D. Timmerman (Belgium)
Austrian Society of Gynaecology and Obstetrics for best contribution from Austria
P. Kohlberger (Austria)
- 15:05 The power of ultrasound: top images from top experts
*B. Benoit (France), R. Chaoui (Germany);
G.R. DeVore (United States);
B. Benacerraf (United States); C. Brezinka (Austria)*
- 15:35 Discussion and voting

16:20

Congress leaving drinks Join us in Singapore in 2018!

HALL E

Workshop Pre-eclampsia in 2017

*Chairs: J. Hyett (Australia);
E. Gratacós (Spain)*

- 13:30 It's all in the heart
B. Thilaganathan (United Kingdom)
- 13:40 No way, it's the placental!
S. Verlohren (Germany)
- 13:50 Nature's transplant placentation and the complex pre-eclampsia tango
C. Redman (United Kingdom)
- 14:10 The state of prevention
F. da Silva Costa (Australia)
- 14:30 Practical assessment of maternal cardiovascular risk in pregnancy
A. Khalil (United Kingdom)

HALL F

Workshop

Managing ovarian masses – what is the evidence base and which approach should we use to classify ovarian masses?

Chairs: T. Bourne (United Kingdom); J.L. Alcázar (Spain)

- 13:30 A systematic review of the evidence and meta-analysis
B. Van Calster (Belgium)
- 13:50 A randomised trial of the use of the IOTA simple rules and the risk of malignancy index (to include OC23.01)
N.P. Nunes (United Kingdom)
- OC23.01** Comparison of two protocols for the management of pain-free postmenopausal women with adnexal tumours: an RCT of RMI/RCOG versus simple rules
N.P. Nunes (United Kingdom)
- 14:10 Based on the data from the IOTA study: what do we think is the best approach to classifying ovarian masses in 2017?
W. Froyman (Belgium)
- 14:30 Discussion of case examples
D. Timmerman (Belgium); J.L. Alcázar (Spain); D. Jurkovic (United Kingdom)

Hubs

HUB 1

08:15-09:15

Interactive

In conversation with *E. Kirk*.
Diagnosing and managing ectopic pregnancy:
expectant, medical or surgical

09:20-10:00

Poster discussion (P)

★ P24: The challenge of evaluating the fetal brain
Chair: E.A. Hernandez-Andrade (United States)

10:20-11:20

Interactive

In conversation with *D. Fischerová* and *E. Epstein*.
Using ultrasound to assess the oncology patient
including staging

11:25-12:05

Poster discussion (P)

P27: Techniques for fetal cardiac diagnosis
Chair: H. Gardiner (United States)

12:20-13:20

HUB 2

Poster discussion (P)

P25: Fetal growth Doppler and
hemodynamics
Chair: F. da Silva Costa (Australia)

Poster discussion (P)

P28: References, standards and markers
Chair: S. Yagel (Israel)

Interactive

★ MRI certificate exam
Moderators: G. Kasprjan; D. Prayer (Austria)

13:30-14:30

HUB 3**Poster discussion (P)**

P26: Ultrasound, reproductive medicine and IVF
 Chair: *W. Froyman (Belgium)*

HUB 4**Interactive**

In conversation with *D. Jurkovic*:
 How do I manage non-tubal ectopic pregnancies?

Poster discussion (P)

P29: Improving our management of twin pregnancies
 Chair: *K. Hecher (Germany)*

Poster discussion (P)

P30: How to use imaging to manage oncology patients
 Chair: *I. Timor-Tritsch (United States)*

Interactive

WATOG: Join the conversation on issues for trainees worldwide
 Moderator: *K. Dimassi (Tunisia)*
 Opinion leaders: *N. Vrachnis (Greece); G. Szabo (Hungary); Y. Mendoza Copado (Mexico); P. Gabor (France); O. Ami (France)*

Interactive

The highlights of the meeting in Chinese
 Moderator: *Q. Wu (China)*

Interactive

In conversation with *M. Herrera* and *G. Malinge*:
 The status of the Zika crisis

OP - Tuesday 19.09.2017

OP26: Managing TTTS

Hall A

Chair: K. Hecher (Germany)

TTTS before 18 weeks: what you need to know

OP26.01, OP26.02

B. Mylrea-Lowndes (United Kingdom)

Short cervix in Twin–twin transfusion syndrome and pregnancy outcome

OP26.03

J.U. Ortiz (Spain)

Low cerebroplacental ratio can predict subsequent fetal demise of donor or smaller twin with abnormal umbilical artery flow after fetoscopic laser surgery

OP26.04

M. Nakata (Japan)

Differences in prognostic factors of single fetal demise after laser therapy for Twin–twin transfusion syndrome between early and late fetal demise

OP26.05

A. Yamashita (Japan)

Outcome of surviving twins underwent intrauterine transfusion for severe anemia subsequent to single fetal death in monochorionic twin gestations

OP26.06

M. Kanda (Japan)

Perinatal outcome of fetoscopic laser surgery for severe Twin–twin transfusion syndrome in early gestation.

OP26.07

E. Tiblad (Sweden)

25% of fetal interposition (FI) in the placental equator in TTTS placentas: the fetoscopic approach

OP26.08

M. Yamamoto (Chile)

Fetal E/e' by dual gate Doppler method in Twin–twin transfusion syndrome and relationship with amniotic fluid brain-type natriuretic peptide

OP26.09

M. Takano (Japan)

Assessment of fetal cardiac function and structure in monochorionic diamniotic twins with Twin–twin transfusion syndrome before and after fetal therapy

OP26.10

X. Torres (Spain)

OP27: How to diagnose and manage abnormal placentation

Hall E

Chairs: P. Calda (Czech Republic); D.M. Twickler (United States)

The jellyfish sign: a new sonographic marker for morbidly adherent placenta previa diagnosis

OP27.01

E. Bertucci (Italy)

“Rail” sign for prediction of advanced AIP (abnormally invasive placenta)

OP27.02

J. Shih (Taiwan)

Ultrasound: a valuable tool to face the epidemic of placenta accreta in Tunisia

OP27.03

D. Chelli (Tunisia)

Comparison of transabdominal ultrasound (US) versus transvaginal US in the accurate prenatal assessment of abnormally invasive placenta (AIP)

OP27.04

M. Aboulghar (Egypt)

Variants of abnormal placentation: retrospective analysis of selected cases and possible clinical implications

OP27.05

P. Pateisky (Austria)

An audit on the management of suspected cases of morbidly adherent placenta at the Heart of England Foundation Trust: a pathway to enhance patient care

OP27.06

A. Fatma (United Kingdom)

- Does imaging correlate with clinical findings for morbidly adherent placenta? An audit from University Hospitals Coventry and Warwickshire
L.J. Ewington (United Kingdom) OP27.07
- The risk factors for antenatal bleeding in pregnancy with placenta previa
H. Cho (Republic of Korea) OP27.08
- The utility of a routine screening for abnormal invasive placentation in women with previous Caesarean sections according to placental insertion site
E. Bertucci (Italy) OP27.09
- Is leaving placenta in situ all we need in the treatment of morbidly adherent placenta? Comparison of three different treatment approaches
M.S. Kutuk (Turkey) OP27.10
- HDlive, HDliveFlow and HDliveFlow silhouette mode for the diagnosis of gestational trophoblastic disease
K. Yamamoto (Japan) OP27.11

OP28: Solving problems in urogynecology using ultrasound

Hall F

Chairs: A. Youssef (Italy); I. Geiss (Austria)

- Levator avulsion and parity
C.E. Walsh (Australia) OP28.01
- Levator ani muscle avulsion and risk of recurrence after facial surgery for pelvic organ prolapse: preliminary results
F. Leone (Italy) OP28.02
- The prevalence of pelvic organ prolapse in a Nepali gynecology clinic
H.P. Dietz (Australia) OP28.03
- The prevalence of major birth trauma in Nepali women
H.P. Dietz (Australia) OP28.04
- Association of uterine leiomyoma and overactive bladder syndrome: a cohort study
S. Schwab (Austria) OP28.05
- Pelvic organ descent and hiatal dimensions in Asian and Caucasian women with symptomatic pelvic organ prolapse
H.P. Dietz (Australia) OP28.06
- WITHDRAWN OP28.07
- Is abnormal posterior compartment anatomy associated with anal incontinence?
H.P. Dietz (Australia) OP28.08
- The levator-urethral gap measurement: tomographic ultrasound imaging (TUI) versus Omniview-volume contrast imaging (VCI)
E. Montaguti (Italy) OP28.09
- The effect of Kristeller manoeuvre on postpartum pelvic organ prolapse: prospective case-control study
M. Paganotto (Italy) OP28.10

OP29: Education, simulation and safety

Hall A

Chair: S. Eik-Nes (Norway)

- B-mode fetal echocardiography perception analysis with the use of eye tracking technology and voice recordings
M. Wiechec (Poland) OP29.01
- Thermal and mechanical index for obstetric scans: an analysis
C. Lees (United Kingdom) OP29.02
- Measurement of temperature during transvaginal scans
C. Lees (United Kingdom) OP29.03

Establishing infection prevention flowcharts for obstetric and gynecological ultrasound practitioners <i>S.C. Westerway (Australia)</i>	OP29.04
WATOG satisfaction survey on the ultrasound training of trainees in obstetrics and gynecology <i>P. Gabor (France)</i>	OP29.05
Evaluation of Canadian obstetrics and gynecology ultrasound curriculum and self-reported competency of final-year residents <i>M. Leonardi (Canada)</i>	OP29.06
ISUOG Basic Training live streaming: evaluation of Nigerian attendees training and practice of obstetric ultrasound <i>H.O. Raji (Nigeria)</i>	OP29.07
Impact of image orientation during transvaginal ultrasound training <i>E. Dreisler (Denmark)</i>	OP29.08
Development of an obstetrics ultrasound Doppler simulator <i>F.A. Guerra (Chile)</i>	OP29.09
Simulation in amniocentesis using a training model in a Latin American setting <i>E. Gil Guevara (United States)</i>	OP29.10

OP30: Fetal brain novel applications of ultrasound and MRI

Chairs: J. Hyett (Australia); A. Toi (Canada)

Photoacoustics as a new imaging technique for <i>in utero</i> assessment of fetal cerebellar tissue oxygenation <i>E. Gil Guevara (United States)</i>	OP30.01
Ultrasound and MRI abnormalities of fetal cortical plate morphology correlate with development of cerebral malformations <i>D. Pugash (Canada)</i>	OP30.02
Segmentation of prenatal cerebellar vermian pathologies in fetal MRI <i>G. Kaspran (Austria)</i>	OP30.03
Fusion imaging (FI) in brain structure measurements on a fetus phantom when combining real-time ultrasound (US) with magnetic resonance imaging (MRI) <i>A. Arechva (Sweden)</i>	OP30.04
Volumetric MRI study of the intrauterine growth restriction fetal brain <i>E. Katorza (Israel)</i>	OP30.05
Imaging the optic chiasm and nerves using Crystal Vue and Crystal Vue flow <i>A. Dall'Asta (United Kingdom)</i>	OP30.06
A new semi-automated method for measuring volume of structures in the fetal brain <i>E. Katorza (Israel)</i>	OP30.07
Reproducibility of a new three-dimensional ultrasound method for the measurement of fetal frontal lobe volume <i>M.E. Albers (Netherlands)</i>	OP30.08
Postmortem MRI and histological correlation of the rostral migratory stream in the human fetal brain <i>C. Mitter (Austria)</i>	OP30.09
Automated measurements of cephalic fetal biometry by three-dimensional ultrasound: feasibility and reproducibility <i>A. Chabot-Lecoanet (France)</i>	OP30.10
The first trimester fetal central nervous system: a novel ultrasonographic perspective <i>H. Shah (United Kingdom)</i>	OP30.11

Hall E

OP31: Using ultrasound to assess pelvic pain and diagnose endometriosis**Hall F***Chairs: S. Ferrero (Italy); G. Hudelist (Austria)*

- New sonographic score of adenomyosis: classification of type and degree of the myometrial involvement and correlation to symptoms OP31.01
C. Exacoustos (Italy)
- Changes in endometriomas and rectovaginal endometriotic nodules during treatment with norethindrone acetate or extended-cycle oral contraceptive OP31.02
C. Scala (Italy)
- Pelvic floor morphometry at three- and four-dimensional transperineal ultrasound in women with ovarian endometriosis or deep infiltrating endometriosis OP31.03
A. Benfenati (Italy)
- Evidence of adenomyosis on transvaginal ultrasound and infertility management of patients with endometriosis selected for surgical intervention OP31.04
V.H. Eisenberg (Israel)
- Ultrasound appearance of decidualised deep endometriosis during pregnancy OP31.05
L. De Blasis (Italy)
- Decidualisation of endometriotic lesions in pregnancy OP31.06
E. Bean (United Kingdom)
- Papillary bladder carcinoma of low-malignant potential during pregnancy: 2D and 3D ultrasonography OP31.07
A. Mulic-Lutvica (Sweden)
- New sonographic score of adenomyosis: interobserver reproducibility in the evaluation of type and degree of the myometrial involvement OP31.08
L. Lazzeri (Italy)
- Influence of endometriomas and deep infiltrating endometriosis on pregnancy outcome and first and second trimester markers of impaired placentation OP31.09
C. Scala (Italy)
- Performance of the transvaginal sonographic 'sliding sign' in prediction of pouch of Douglas obliteration: does this improve over time? OP31.10
B. Shakeri (Australia)
- Follow-up of MRI deep infiltrative endometriotic lesions before and after pregnancy: does it change something? OP31.11
A.E. Millischer (France)

P - Tuesday 19.09.2017

P24: The challenge of evaluating the fetal brain

L3 / L6 Hub 1

Chair: E.A. Hernandez-Andrade (United States)

- Fetal brain anomalies detection during the first trimester: expanding the scope of antenatal sonography P24.01
E. Katorza (Israel)
- Prenatal detection of central nervous system defects at 11–13+6 weeks' ultrasound scan P24.02
E. Andreeva (Russian Federation)
- Outcome of fetuses with prenatal diagnosis of isolated severe ventriculomegaly P24.03
S. Carta (United Kingdom)
- The many faces of prenatal imaging diagnosis of ventriculomegaly related to aqueduct obstruction P24.04
L. Guibaud (France)
- Differential cortical development in fetuses with isolated non-severe ventriculomegaly assessed by magnetic resonance imaging P24.05
N.M. Hahner (Spain)
- Isolated complete short corpus callosum in fetuses: prevalence and pregnancy short-term outcome P24.06
F. Fuchs (France)
- Posterior fossa imaging features enabling diagnosis of PHACE syndrome *in utero* P24.07
H. Bakry (Israel)
- Prenatal sonographic diagnosis of congenital arachnoid cyst: clinical outcomes in a tertiary care centre P24.08
Y. Jung (Republic of Korea)
- Neurosonographic findings in fetal tuberous sclerosis complex P24.09
E. Correa (Portugal)
- The first case of Zika virus related microcephaly in the Netherlands P24.10
R. de Heus (Netherlands)
- Fetal neurosonographic aspects of the Zika virus infection P24.11
H.J. Milani (Brazil)

P25: Fetal growth Doppler and hemodynamics

L3 / L6 Hub 2

Chair: F. da Silva Costa (Australia)

- Assessment of placental vascularisation using three-dimensional power Doppler angiography (3D PDA) in normal fetuses and fetuses affected by fetal growth restriction (FGR) P25.01
A. Rossi (Italy)
- An objective system to evaluate the quality of middle cerebral artery Doppler images P25.02
S. Ruiz-Martinez (United Kingdom)
- Fetal umbilical/middle cerebral artery pulsatility indices and the cerebroplacental ratio (CPR) normograms at 16–40 weeks of gestation by polynomial regression analysis P25.03
T. Dias (Sri Lanka)
- Stillbirth and fetal growth restriction from umbilical artery and ductus venosus diastolic waveform assessment: a systematic review and meta-analysis P25.04
R.J. Martinez-Portilla (Spain)
- Uterine Doppler, cerebroplacental ratio and fetal growth in the late third trimester: association with adverse outcome P25.05
G. Albaiges Baiget (Spain)
- Clinical impact of the Doppler reference charts used for the management of fetal growth restriction: the need for standardisation P25.06
S. Ruiz-Martinez (Spain)
- Three-dimensional power Doppler ultrasound examination in pregnancies complicated by intrauterine growth restriction P25.07
A. Molnár (Hungary)

Maternal hemodynamic profile in pregnancies complicated by intrauterine growth restriction <i>T. Izzo (Italy)</i>	P25.08
CPR 2 as a new Doppler parameter to assess the well-being in fetal growth-restricted fetuses <i>A. Rossi (Italy)</i>	P25.09
Maternal hemodynamics in pregnancies complicated by hypertensive disorders <i>E. Fuse (Italy)</i>	P25.10
Usefulness of computerised cardiocography-based short-term variation in late-onset fetal growth-restricted (FGR) fetuses <i>O. Graupner (Germany)</i>	P25.11

P26: Ultrasound, reproductive medicine and IVF

L3 / L6 Hub 3

Chair: W. Froyman (Belgium)

Interobserver variability of uterine measurements in congenital uterine anomalies with three-dimensional ultrasound <i>B. Graupera (Spain)</i>	P26.01
Objective assessment of uterine peristalsis outside pregnancy by high-order texture analysis of ultrasound images <i>C. Caresio (Italy)</i>	P26.02
Perinatal outcomes in singleton pregnancies conceived by natural cycle as compared with conventional IVF and spontaneously conceived pregnancies <i>H. Ayuso (Spain)</i>	P26.03
To appraise the current evidence comparing double and single intrauterine insemination (IUI) on the reproductive outcomes in subfertile couples <i>C.O. Nasti (Brazil)</i>	P26.04
The possible effect of HPV infection on IVF outcomes: a systematic review and meta-analysis <i>W.P. Martins (Brazil)</i>	P26.05
Evaluating tubal patency using three different ultrasound techniques: interobserver reliability agreement and diagnostic accuracy <i>L. Ludwin (Poland)</i>	P26.06
Androgen levels in female offspring of PCOS and non-PCOS women <i>M. Kollmann (Austria)</i>	P26.07
Screening for congenital uterine anomalies by three-dimensional transvaginal ultrasound in premenopausal women: the online added information <i>S. Tudorache (Romania)</i>	P26.08
Image quality of the coronal plane of the uterus by 3D ultrasound: comparison of four techniques based on the opinion of several experts <i>W.P. Martins (Brazil)</i>	P26.09
Normal/arcuate vs septate uterus: agreement among experts' subjective impression evaluating the coronal plane of the uterus on 3D ultrasound <i>A. Ludwin (Poland)</i>	P26.10

P27: Techniques for fetal cardiac diagnosis

L3 / L6 Hub 1

Chair: H. Gardiner (United States)

Additional cardiac views for 76811 billing do not increase detection of congenital heart disease, despite increased number of ultrasound exams <i>V. Fratto (United States)</i>	P27.01
Accuracy of early fetal echocardiography within 16 weeks of gestation in the diagnosis of outflow tracts anomalies in a high-risk population <i>V. De Robertis (Italy)</i>	P27.02
Improving detection of severe fetal pulmonary stenosis <i>V. Jowett (United Kingdom)</i>	P27.03

Evaluation of PLAS index (post LA space index) in normal fetus <i>Y. Kawazu (Japan)</i>	P27.04
Prenatal diagnosis of total anomalous pulmonary venous connections (TAPVC): multicentre cohort study and meta-analysis <i>D. Paladini (Italy)</i>	P27.05
Use of 'coumadin ridge': an easy sign to rule out TAPVC <i>U. Singh (India)</i>	P27.06
Feasibility of basic fetal heart imaging during first trimester <i>A. Gerede (Greece)</i>	P27.07
First trimester cardiac screening for major CV anomalies performance using transabdominal simplified fetal echocardiography protocol <i>M. Calomfirescu (Romania)</i>	P27.08
Diagnostic accuracy of basic fetal heart examination at 11–13 weeks' gestation of pregnancy <i>T. Loureiro (Portugal)</i>	P27.09
Barriers to prenatal detection of critical congenital heart disease: lessons learned from review of false-negative anatomy ultrasounds <i>D. Goff (United States)</i>	P27.10
Perinatal outcome of pulmonary atresia with intact ventricular septum (PAIVS) depending on time of diagnosis <i>R. Axt-Fliedner (Germany)</i>	P27.11

P28: References, standards and markers

L3 / L6 Hub 2

<i>Chair: S. Yagel (Israel)</i>	
Congenital lung malformations: correlation between pre- and postnatal imaging <i>A.E. Millischer (France)</i>	P28.01
Establishment of ultrasound references value for fetal anogenital distance and perineal muscular complex measurements: could it be a future prospect in our antenatal anorectal malformation ultrasound diagnosis? <i>A. Ayachi (Tunisia)</i>	P28.02
Reference curves for fetal urinary bladder and renal pelvis volumes in the second and third trimester of pregnancy <i>E. Fontanella (Netherlands)</i>	P28.03
Antenatal renal pelvic dilatation: is it a wee problem? Long-term outcome in male and female children <i>S. Sankaran (United Kingdom)</i>	P28.04
The prenatal diagnosis and outcomes of fetal lung cystic lesions: 100 cases at a single centre <i>R. Sugibayashi (Japan)</i>	P28.05
Perinatal management in cases of fetal abdominal wall defects (fAWD): retrospective survey on predictors of final outcome <i>U. Schneider (Germany)</i>	P28.06
Ultrasound markers in fetal hydronephrosis to predict postnatal surgery <i>D. Wertaschnigg (Austria)</i>	P28.07
Thorax-to-head ratio and defect diameter-to-head ratio in giant omphaloceles as predictor for fetal outcome <i>J. Braun (Germany)</i>	P28.08

P29: Improving our management of twin pregnancies

L3 / L6 Hub 3

<i>Chair: K. Hecher (Germany)</i>	
Maternal hemodynamic changes and complications following intrauterine interventions for monochorionic twin pregnancies <i>P. Greimel (Austria)</i>	P29.01

Maternal hemodynamics in monochorionic twin pregnancy: hypodynamic circulation and reduced cardiac power <i>D. Farsetti (Italy)</i>	P29.02
Assessment of fetal myocardial performance index in routine follow-up of twin pregnancy: feasibility study <i>M. Massoud (France)</i>	P29.03
The roles of superficial anastomoses with Twin–twin transfusion syndrome <i>H. Kanno (Japan)</i>	P29.04
Placental cord insertion site and adverse pregnancy outcome in twin pregnancy <i>E. Kalafat (Turkey)</i>	P29.05
Outcomes of monochorionic diamniotic twin pregnancies in tertiary fetal medicine centre with new access to invasive fetal therapy <i>K. Behavkova (Czech Republic)</i>	P29.06
Short-term and long-term outcome of spontaneous twin anemia-polycythemia sequence <i>S. Han (Republic of Korea)</i>	P29.07
Acute fetto-fetal transfusion simulation in monochorionic diamniotic twins <i>L. Haslik (Czech Republic)</i>	P29.08
The use of long-term indomethacin stabilises cervical length in twin pregnancies <i>O.M. Turan (United States)</i>	P29.09

P30: How to use imaging to manage oncology patients

L3 / L6 Hub 4

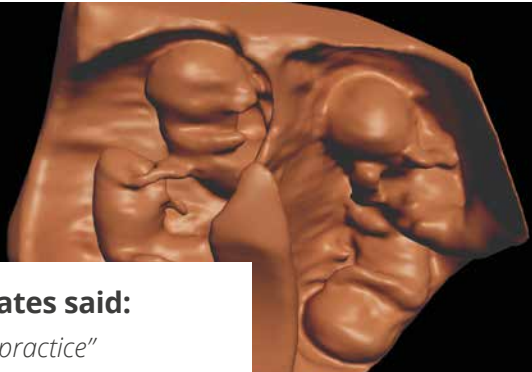Chair: I. Timor-Tritsch (United States)

Neuroendocrine tumours of the female genital tract: a small case series <i>H. Mehra (United Kingdom)</i>	P30.01
Accuracy of different risk prediction models and subjective ultrasound assessment to diagnose extraovarian primary peritoneal cancer <i>M. Stukan (Poland)</i>	P30.02
Imaging in gynecological disease: clinical and ultrasound features of ovarian endometrioid carcinoma <i>E. Moro (Italy)</i>	P30.03
Does rectal enema improve the accuracy of ultrasonography in predicting rectosigmoid infiltration in patients with ovarian cancer? <i>S. Ferrero (Italy)</i>	P30.04
MRI and ultrasound fusion imaging for endometrial cancer <i>M. Allanche (France)</i>	P30.05
Accuracy of different risk prediction models and subjective ultrasound assessment to diagnose colon cancer metastases in the ovaries <i>M. Stukan (Poland)</i>	P30.06
Prospective evaluation of ultrasound implementation into preoperative evaluation of cervical cancer patients <i>M. Zikan (Czech Republic)</i>	P30.07
Imaging in gynecological disease: clinical and ultrasound characteristics of ovarian metastasis from low-grade appendiceal mucinous neoplasms (LAMNs) <i>A.C. Testa (Italy)</i>	P30.08
MRI and ultrasound fusion imaging for cervical cancer <i>C. Theodore (France)</i>	P30.09
Ultrasound and clinical features of uterine carcinosarcoma <i>S. Giunchi (Italy)</i>	P30.10
Gastrointestinal stromal tumours: can they be correctly diagnosed by ultrasound during gynecologic evaluation? A report of five cases <i>N. Rams (Spain)</i>	P30.11



ISUOG Education

ISUOG delivers regular, high quality education courses in ultrasound in obstetrics and gynecology, providing up-to-date knowledge and clinical guidance in a range of topics. Our courses present dynamic, interactive clinical updates and are now available face to face and live online.

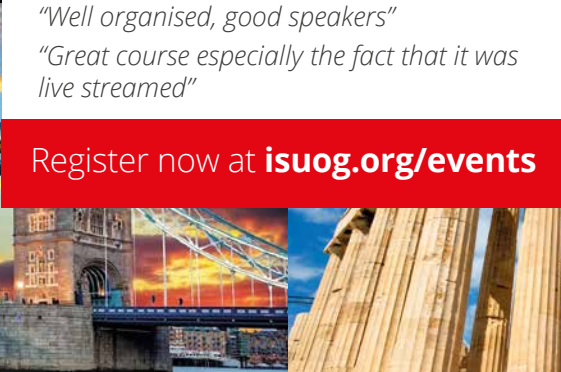

Our previous delegates said:

"Very relevant to clinical practice"

"Well organised, good speakers"

"Great course especially the fact that it was live streamed"



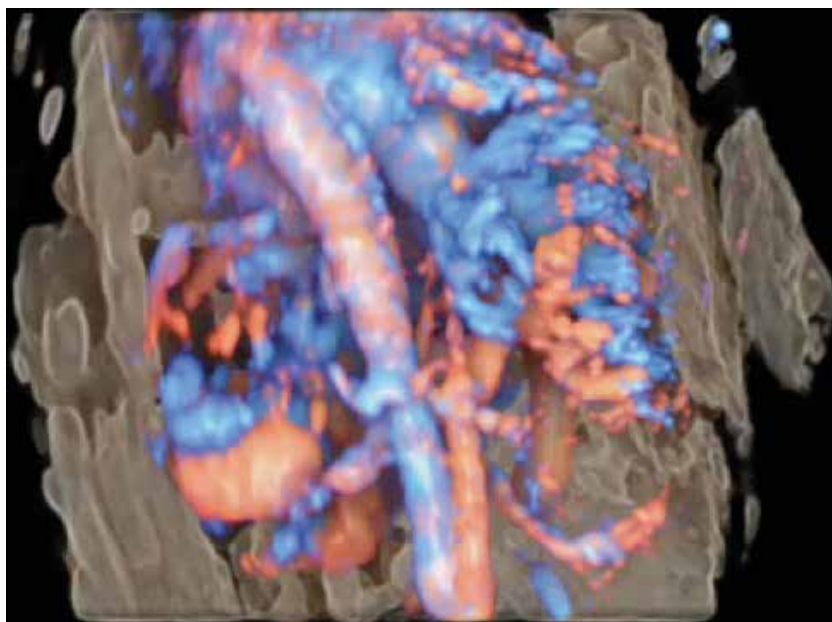
Register now at [isuog.org/events](https://www.isuog.org/events)

Full list of courses at:
www.isuog.org/events



ELECTRONIC POSTERS

ISUOG 2017



Fetal hepatic hemangioma - Tenkumo C, Hanaoka U, AboEllail MA, Ishimura M, Morine M, Maeda K, Hata T. HDlive Flow with HDlive silhouette mode in diagnosis of fetal hepatic hemangioma. *Ultrasound Obstet Gynecol* 2017; 49: 541–542.

EP - Electronic posters

EP01: Fetal brain and CNS anomalies: cavum septum pellucidum, corpus callosum, choroid plexus and intracranial cysts

- Reliability of cavum septum pellucidum volume measurements during second trimester ultrasonography in structurally normal fetuses EP01.01
M. Sezik (Turkey)
- Abnormal cavum septi pellucidi (CSP): experience of a tertiary centre EP01.02
D.G. Iliescu (Romania)
- Fetal cavum septum pellucidum: tentorium angle measured with three-dimensional ultrasonography and its clinical value EP01.03
G. Lyu (China)
- Prenatal diagnosis and postnatal outcome of agenesis of the corpus callosum: a retrospective multicentre study EP01.04
K. Yusupov (Russian Federation)
- OmniView: a useful tool for early evaluation of fetal cortex abnormal sulcation associated with dysgenesis of corpus callosum – a case report EP01.05
E.Q. Barreto (Brazil)
- Isolated absence of septum pellucidum: a report of two cases EP01.06
H. Boo (Republic of Korea)
- Fetal intracranial space occupying lesions: MRI versus ultrasound EP01.07
X. Chen (China)
- Fetal choroid plexus at 11–13 weeks: a predictor of handedness? EP01.08
R.S. Abu-Rustum (Lebanon)
- Fetal choroid plexus cysts and aneuploidy EP01.09
S. Pashaj (Albania)
- Prenatal diagnosis and prognosis of fetal arachnoid cysts EP01.10
L. Yin (China)
- A case of large prenatally-diagnosed arachnoid cyst EP01.11
S. Wavrant (Canada)
- Magnetic resonance imaging of fetal brain in confirming the diagnosis of supra- and infratentorial arachnoid cysts seen in routine antenatal ultrasound EP01.12
M.R. Louis (Egypt)
- Prenatal diagnosis of Aicardi syndrome: a case report EP01.13
C.T. Hsieh (Taiwan)

EP02: Fetal brain and CNS anomalies: ventriculomegaly, posterior fossa and neural tube defects

- Fetal mild ventriculomegaly: the correlation between the degree of dilatation and other fetal biometric parameters EP02.01
E. Katorza (Israel)
- Ventricular wall morphology in cases with mild/moderate ventriculomegaly at 18–21 weeks EP02.02
R.K. Pooh (Japan)
- Isolated non-severe ventriculomegaly is associated with poorer early neurodevelopment EP02.03
N.M. Hahner (Spain)
- WITHDRAWN EP02.04

Spontaneous resolution of a ventriculomegaly <i>A.K. Kesrouani (Lebanon)</i>	EP02.05
Ventriculomegaly related to genetic disorders of differentiation <i>Y. Nieto Jimenez (Spain)</i>	EP02.06
Differential diagnosis of hydrocephalus caused by intracranial hemorrhage and congenital brain tumours: a study of three cases <i>E. Soga (Japan)</i>	EP02.07
WITHDRAWN	EP02.08
Occipital cephalocele: diagnosis, obstetric and postnatal management <i>R. Radulescu-Botica (Romania)</i>	EP02.09
WITHDRAWN	EP02.10
Posterior encephalocele with cerebellar displacement and hypoplasia <i>A.K. Kesrouani (Lebanon)</i>	EP02.11
Hypoplasia of the cerebellar vermis in fetuses from 45 to 84 mm Crown–rump length <i>R. Altmann (Austria)</i>	EP02.12
Neurosonography and Doppler analysis of the brain and cerebellum in fetal rats with spina bifida: a novel marker for Arnold-Chiari type II malformation <i>E. Gil Guevara (United States)</i>	EP02.13
Correlation between ultrasound and MRI measurements of the fetal cerebellum performed on the same day <i>R.E. Parad (United States)</i>	EP02.14
First trimester imaging in Dandy-Walker syndrome with vermian agenesis <i>A.K. Kesrouani (Lebanon)</i>	EP02.15
Case of hypoplasia cerebellar vermis with dynamic ventriculomegaly change <i>R. Matsuoka (Japan)</i>	EP02.16

EP03: Improving the prenatal diagnosis of fetal brain and CNS anomalies

Reproducibility of the intracranial anatomy assessment during second trimester sonographic scan <i>E. Kalafat (Turkey)</i>	EP03.01
Impact of fetal magnetic resonance imaging of the brain in assessment of fetal CNS anomalies <i>M.R. Louis (Egypt)</i>	EP03.02
Fetal neurosonography: experience and correlation with magnetic resonance images (MRI) in T2 weighted images (WI) at Hospital Italiano of Buenos Aires <i>D. Covini (Argentina)</i>	EP03.03
The cerebral third ventricle in fetuses with normal anatomy and CNS malformations: a high-resolution 3D ultrasound (3DUS) study of the mid-sagittal view <i>D. Paladini (Italy)</i>	EP03.04
Central nervous system ultrasound characterisation in triploid fetuses in the first trimester <i>T. Loureiro (Portugal)</i>	EP03.05
12 weeks' ultrasound diagnostic of hemivertebrae <i>R.E. Bahiltea (Romania)</i>	EP03.06
Prenatal diagnosis of 22q11.2 microdeletion: minor cardiac finding detected in mid-trimester scan associated with severe bilateral perisylvian polymicrogyria in late gestation <i>H. Bakry (Israel)</i>	EP03.07
Fetal neuronal migration disorder with megalencephaly at 18 weeks related to paternal UPD mosaicism with PTEN mutation <i>R.K. Paah (Japan)</i>	EP03.08
Prenatal diagnosis of ultrasound and MRI in the Vein of Galen aneurysmal malformation <i>X. Chen (China)</i>	EP03.09
A very rare case of fetal brainstem disconnect <i>N. Jackson (United Kingdom)</i>	EP03.10

- Dichorionic diamniotic twin pregnancy with central nervous system anomalies in both fetuses
M.W. Serafin (Poland) EP03.11
- A comparison between prenatal and postnatal radiologic findings of prenatally diagnosed lissencephaly cases
H. Cho (Republic of Korea) EP03.12

EP04: Fetal echocardiography

- Systematic evaluation of the fetal subclavian arteries in mid-trimester scan (CASSEAL protocol in a multicentric study)
C. Bravo (Spain) EP04.01
- Outcomes with fetal immune mediated congenital atrioventricular block (CAVB)
K.M. Liong (Singapore) EP04.02
- Ultrasonic diagnosis to pathological types of fetal complete transposition of the great arteries (CTGA) and combined malformations
J. Li (China) EP04.03
- Detection of congenital heart defects at 11–13+6 weeks' scan using only 4 chamber view and combination of 4 chamber and 3 vessel views of the heart
E.S. Nekrasova (Russian Federation) EP04.04
- Applicability of ISUOG practice guidelines on second trimester sonographic screening examination of fetal heart
A. Gerede (Greece) EP04.05
- High SVC/Ao ratio in 3 vessel view can be one of the indicators for the placental insufficiency
J. Matsumoto-Runser (Japan) EP04.06
- Comparative study between early fetal echocardiography performed at 13–13+6 weeks' and at 16 weeks' gestation
L. Ortega Cárdenes (Spain) EP04.07
- Quantification of mechanical dyssynchrony in growth-restricted fetuses and normal controls using speckle-tracking echocardiography (STE)
R. Schmitz (Germany) EP04.08
- Prenatal ultrasound diagnosis on fetal absent pulmonary valves
T. Zhu (China) EP04.09
- Absent pulmonary valve syndrome: the earlier the operation, the better the results?
K. Zych Krekora (Poland) EP04.10
- M-mode vs 2D echocardiography for measuring of fetal myocardial wall thickness
A. Sepúlveda-Martínez (Spain) EP04.11
- Parameters affecting imaging accuracy on sonographic screening examination of fetal heart during second trimester according to ISUOG practice guidelines
A. Gerede (Greece) EP04.12
- Fetal right aortic arch can be screened with three vessel view in the second or third trimester ultrasound screening
E. Inoue (Japan) EP04.13
- Does the fetal echosonographic index of infection have an impact on the newborn's condition?
J. Murlawska (Poland) EP04.14
- Postnatal clinical course of the fetal vascular ring
N. Imaoka (Japan) EP04.15
- Perinatal outcome in fetuses with heterotaxy syndrome
A. Mabuchi (Japan) EP04.16
- The use of early fetal echocardiography in fetuses with ultrasound soft markers
Q. Pan (China) EP04.17
- Major aortopulmonary collaterals (MAPCA): prenatal diagnosis and prognosis
R. Gasnier (Israel) EP04.18

The estimation of the prognosis for fetal critical aortic stenosis with the left atrium area and the Doppler pattern in pulmonary veins <i>S. Sukegawa (Japan)</i>	EP04.19
Prenatal subtyping of ventriculocoronary connections in hypoplastic left heart syndrome: review of the literature and a case report <i>K. Oelmeier de Murcia (Germany)</i>	EP04.20
Tetralogy of Fallot: a series of cases – associations and evolution <i>C. Marginean (Romania)</i>	EP04.21
The fetal case of right isomerism with infracardiac total anomalous pulmonary venous drainage and agenesis of the ductus venosus <i>K. Kim (Japan)</i>	EP04.22
The role of ultrasound in fetal Graves' disease: a case report <i>M. Theodora (Greece)</i>	EP04.23
Prenatal diagnosis of arterial tortuosity syndrome <i>J. Park (Republic of Korea)</i>	EP04.24
Prenatal/preoperative/postoperative cases presentation: pulmonary artery sling associated with compression of the airway <i>Y. Peng (China)</i>	EP04.25
A case of Long QT syndrome screened by 2:1 AV block and confirmed by fetal ECG <i>M. Kawataki (Japan)</i>	EP04.26
Fetal cardiomegaly caused by massive hemangioma <i>H. Moczulska (Poland)</i>	EP04.27
Fetal echocardiography in the third trimester a new obligation to save fetal/neonatal life? A new approach based on 4 cases from a tertiary centre <i>M. Respondek-Liberska (Poland)</i>	EP04.28
Prenatal diagnosis of Turner syndrome in a case of isolated aberrant right subclavian artery <i>A. Corbacioglu Esmer (Turkey)</i>	EP04.29
Fetal dilated cardiomyopathy: genetic susceptibility? <i>K. Kuo (United States)</i>	EP04.30
Case report: isolated absent pulmonary valve syndrome (APVS) <i>A. Idelson (Israel)</i>	EP04.31
Left atrial isomerism (LAI) without serious heart defect: first trimester diagnosis and delayed postnatal development of the heart block at the age of 11 months <i>S. Milovanova (United Kingdom)</i>	EP04.32
Idiopathic intermittent dilated cardiomyopathy: in the fetal and the postnatal periods <i>K. Kuo (United States)</i>	EP04.33
Significance of an abnormal venous return on the prenatal morphology scan <i>A.K. Kesrouani (Lebanon)</i>	EP04.34
Prenatal diagnosis of fetal idiopathic ventricular tachycardia treated with maternal intravenous magnesium: a case report <i>J. Park (Republic of Korea)</i>	EP04.35
Fetal sinus bradycardia as the symptom of previously undiagnosed familial form of Long QT syndrome type 1 caused by mutation of KCNQ1 gene (c.926C>T) <i>M. Lubusky (Czech Republic)</i>	EP04.36
Fetal persistent left superior vena cava: a case report and review of the literature <i>L.J. Ewington (United Kingdom)</i>	EP04.37
Prenatal diagnosis of a fetal Uhl anomaly <i>S.S. Kabra (India)</i>	EP04.38
Hypoplastic left heart syndrome: early ultrasound diagnosis of fetal congenital heart defects <i>D. Ilic (Serbia)</i>	EP04.39

Case report of Ebstein's anomaly which dynamic slow-motion display was useful for a diagnosis of the functional pulmonary atresia <i>N. Inamura (Japan)</i>	EP04.40
Intrathymic course of the left brachiocephalic vein <i>A. Corbacioglu Esmer (Turkey)</i>	EP04.41
Fetal diagnosis of total pulmonary venous connection with the persistent left superior vena cava <i>N. Inamura (Japan)</i>	EP04.42
Semi quantitative analysis of ductus venosus blood flow for a-wave characterisation <i>D. Nemescu (Romania)</i>	EP04.43
Accuracy of early fetal echocardiography within 16 weeks of gestation in the diagnosis of aortic arch anomalies in a high-risk population <i>V. De Robertis (Italy)</i>	EP04.44
First trimester learning curve and feasibility of MCA assessment in an unselected Lebanese population <i>R.S. Abu-Rustum (Lebanon)</i>	EP04.45
First trimester CPR assessment and normogram in an unselected Lebanese population <i>R.S. Abu-Rustum (Lebanon)</i>	EP04.46

EP05: Fetal heart

Non-immune hydrops fetalis caused by restrictive foramen ovale without congenital heart defect <i>A. Parzynska (Poland)</i>	EP05.01
Difficulties in right CDH survival prediction <i>M. Yamamoto (Chile)</i>	EP05.02
WITHDRAWN	EP05.03
WITHDRAWN	EP05.04
First trimester sonographic diagnosis of situs anomaly <i>Y. Nakamura (Japan)</i>	EP05.05
The analysis of misdiagnosis and missed diagnosis by fetal echocardiography combined with cardiovascular cast <i>S. Ge (United States)</i>	EP05.06
Cerebral hemodynamics in fetuses with transposition of great arteries: a multicentre study <i>S. Ge (United States)</i>	EP05.07
The added value of 3D/4DUS high definition power Doppler, TUI and B-flow to the evaluation of the fetal precordial venous system <i>S. Yagel (Israel)</i>	EP05.08

EP06: Issues in prenatal screening

WITHDRAWN	EP06.01
The landscape of pathogenic copy number variants in fetuses with congenital heart defects <i>X. Chen (China)</i>	EP06.02
Be aware of a diagnostic delay: Rotterdam's experience with NIPT in 1071 high-risk pregnancies <i>K.E. Diderich (Netherlands)</i>	EP06.03
Fetal homozygous α 0-thalassemia prediction using three-dimensional sonographic placental volume in first trimester <i>E. Yang (China)</i>	EP06.04
Did women's hepatitis B status affect their uptake of invasive prenatal diagnosis after a positive conventional aneuploidy screening? <i>K.Y. Leung (Hong Kong)</i>	EP06.05
The assessment of diagnosis of fetal neural tube defects by ultrasound in the first trimester <i>Q. Wu (China)</i>	EP06.06

Sonographic features of Trisomy 13 at 11–13 weeks of gestation <i>Y. Nakamura (Japan)</i>	EP06.07
First trimester prenatal diagnosis of aberrant right subclavian artery <i>D. Markov (Bulgaria)</i>	EP06.08
Impact of “no call result” in NIPT in a single centre <i>G. Albaiges Bajget (Spain)</i>	EP06.09
Performance of the 13-week gross-anatomy survey in a primary care centre in the Netherlands <i>F. Bardi (Netherlands)</i>	EP06.10
Why do patients refuse invasive prenatal testing? <i>P. Sadlecki (Poland)</i>	EP06.11
Fetal situs evaluation at the first trimester screening scan <i>N. Feldman Leidner (Israel)</i>	EP06.12
International trends in patient samples submitted for non-invasive prenatal testing (NIPT) <i>M. Schmid (United States)</i>	EP06.13
WITHDRAWN	EP06.14
Early and late chorionic villus sampling in Zagreb: experience with 13,300 cases <i>M. Podobnik (Croatia)</i>	EP06.15
Preliminary study on the consequences of the implementation of the DNAf technique for the screening of Trisomy 21 in a hospital of the public network of Madrid, Spain <i>C. Martínez-Payo (Spain)</i>	EP06.16
First trimester diagnosis of cystic hygroma by transvaginal ultrasound and cytogenetic evaluation <i>M. Podobnik (Croatia)</i>	EP06.17
Current prenatal screening efficacy of Trisomy 21, 18 13 in the Taiwan: a 6-year national registry study <i>C. Hsiao (Taiwan)</i>	EP06.18
Discordant NIPT in a pregnant women with breast cancer <i>P. Moore (Chile)</i>	EP06.19
Choroid plexus morphology and size anomalies: a Trisomy 22 feature? <i>M.M. Martins (Portugal)</i>	EP06.20
First trimester growth delay: an early marker of triploidy <i>K. Kuo (United States)</i>	EP06.21
Little sonographic findings and numeric chromosome aberrations <i>Y. Nieto Jimenez (Spain)</i>	EP06.22

EP07: Bones and spine

Non-lethal skeletal dysplasia: a 25 year-old with isolated fetal femoral fracture <i>T.F. Oluoyomi-Obi (Canada)</i>	EP07.01
Recurrent clubfoot in one family <i>A.K. Kesrouani (Lebanon)</i>	EP07.02
A case of chondrodysplasia punctata in a lupic mother <i>S. Wavrant (Canada)</i>	EP07.03
Prenatal diagnosis of arthrogryposis multiplex congenital <i>Y. Nagayasu (Japan)</i>	EP07.04
A fetus with isolated unilateral lower limb hypertrophy: a case report <i>A. Yulia (United Kingdom)</i>	EP07.05
Prenatal radial malformation with cleft lip and palate, tetralogy of Fallot <i>J. Park (Republic of Korea)</i>	EP07.06
The value of prenatally quantitative evaluation the severity of clubfoot by sonography <i>G. Lyu (China)</i>	EP07.07
WITHDRAWN	EP07.08

Real-time VCI-A with a 4D electronic probe facilitates the evaluation of fetal extremities in mid-trimester sonograms EP07.09

F. Bellussi (Italy)

Talipes equinovarus: prenatal diagnosis and outcome in the centre Gennet 2007–2016, Czech Republic EP07.10

D. Smetanova (Czech Republic)

EP08: Fetal structural abnormalities I

Hemodynamic indices of mother-placenta-fetus system in pregnant at high risk of intrauterine infection EP08.01

L. Vygivska (Ukraine)

Overview of the role of urological fetal MRI in Evelina Children's Hospital EP08.02

C.E. Lovegrove (United Kingdom)

Prevalence of major congenital anomalies in a tertiary care hospital in Oman (5 years' retrospective study) EP08.03

T.R. Al-Dughaihi (Sultanate of Oman)

Contribution of ultrasound in the diagnosis and management of twin pregnancies with single fetal malformation EP08.04

D. Chelli (Tunisia)

Fetal anomalies detected in Sri Lankan tertiary fetal medicine referral centre EP08.05

T. Dias (Sri Lanka)

EP09: Fetal structural abnormalities II

The fetal zygoma detection : an important landmark in the differential diagnosis of mandibular anomalies EP09.01

Y. Gilboa (Israel)

Subependymal heterotopia in fetuses with Chiari II malformation EP09.02

P.C. Brugger (Austria)

Prenatal diagnosis of a voluminous facial rapidly involuting congenital hemangioma (RICH): a case report EP09.03

S. Wavrant (Canada)

Solitary median maxillary central incisor syndrome (SMMCI) in association with agenesis of the corpus callosum EP09.04

I. Ortega Cárdenes (Spain)

Familial aplasia cutis congenita on the scalp complicated with unexplained persistent mild hydrocephalus and polyhydramnios on prenatal ultrasonography: "like father, like daughter" EP09.05

K. Lee (Republic of Korea)

Sagging renal artery: clue to prenatal diagnosis of horseshoe kidney EP09.06

D. Singh (India)

Perinatal features of restrictive dermopathy in one dizygotic twin EP09.07

E. Sluijsmans (Netherlands)

EP10: Head and neck

Asymmetry of the lateral ventricles and choroid plexus at the time of first trimester screening as a possible early sign of hemimegalencephaly EP10.01

A. Weichert (Germany)

Laryngeal atresia associated with esophageal fistula EP10.02

I. Ortega Cárdenes (Spain)

A case of unilateral choanal atresia EP10.03

S. Brezinova (Czech Republic)

Agenesis of peroné: a case report EP10.04

L. Javier (Chile)

Relationship between absent or hypoplastic fetal nasal bone at 20–23+6 weeks of gestation and chromosomal defects in an unselected Chinese population <i>L. Cao (China)</i>	EP10.05
HD-flow use in the study of the posterior palate defects: pilot study <i>A. Comanescu (Romania)</i>	EP10.06
WITHDRAWN	EP10.07
Look at the fetal nose 1: the nasofrontal angle <i>E. de Jong-Pleij (Netherlands)</i>	EP10.08
Added value of prenatal MR in the evaluation of fetal cleft lip, cleft palate and micrognathia <i>S.L. Lajfer-Narin (United States)</i>	EP10.09
Look at the fetal nose 2: the nasal height <i>E. de Jong-Pleij (Netherlands)</i>	EP10.10
The frontal fetal facial (FFF) angle in the second trimester measured by 3D ultrasound in normal fetuses and fetuses with Trisomy 18 <i>E. Merz (Germany)</i>	EP10.11
Sonographic evaluation of the fetal thymus using the thy-box technique between 18 and 22 weeks' gestation in a multicentric study <i>C. Bravo (Spain)</i>	EP10.12
Clinical management of fetal goiter: case series and review of the literature <i>M.A. Gembicki (Germany)</i>	EP10.13
Fetal cleft lip and palate: improved diagnostic accuracy by combined sonography (US) and magnetic resonance imaging (MRI) <i>J.A. Estroff (United States)</i>	EP10.14
A new sign to demonstrate the presence of a cleft palate: the rolling stone sign! <i>J. Develay-Morice (France)</i>	EP10.15

EP11: Placenta, umbilical cord and amniotic fluid

Preterm intrauterine growth restriction and amniotic band syndrome <i>C. Martínez-Payo (Spain)</i>	EP11.01
A rare tumour of umbilical cord: umbilical cord hemangioma and pregnancy outcome <i>T. Sarac Sivriköz (Turkey)</i>	EP11.02
WITHDRAWN	EP11.03
Umbilical cord cyst as an incidental finding on ultrasound <i>C. De Bruyn (Belgium)</i>	EP11.04
Streeter syndrome 3D observation of amnion dysmorphism <i>Y. Nieto Jimenez (Spain)</i>	EP11.05
A case with non-reassuring fetal status due to obstruction of unilateral umbilical artery <i>M. Goto (Japan)</i>	EP11.06
The ultrasonographic features of multivesicular placental disorders with fetus: partial hydatidiform mole, complete hydatidiform mole coexistent with a fetus and placental mesenchymal dysplasia <i>A. Omoto (Japan)</i>	EP11.07

EP12: Thorax and abdomen

Fetal cervical lymphangioma: prenatal diagnosis and treatment <i>L. Javier (Chile)</i>	EP12.01
WITHDRAWN	EP12.02
Bicornuate uterus on prenatal three-dimensional ultrasound <i>E. Mousty (France)</i>	EP12.03
Bronchopulmonary sequestration with hydrops in monochorionic twins treated with multiple courses of Betamethasone <i>P. Hanulíková (Czech Republic)</i>	EP12.04

Ultrasound appearance of fetal giant thymus <i>R.E. Bohiltea (Romania)</i>	EP12.05
Cyst of the seminal vesicle as a rare cause of a prenatal diagnosed Douglas cyst by male fetus <i>R. Gatina (Germany)</i>	EP12.06
Meconium peritonitis from the first trimester <i>Y. Nieto Jimenez (Spain)</i>	EP12.07
Herlyn–Werner–Wunderlich syndrome: performance of MRI findings compared to ultrasound imaging and intraoperative assessment during Caesarean section <i>F. Presti (Italy)</i>	EP12.08
An unusual localisation of lymphangioma <i>Y. Nieto Jimenez (Spain)</i>	EP12.09
Cantrell's Pentalogy: gestational ultrasound imaging <i>C. Martínez-Payo (Spain)</i>	EP12.10
Prenatal ultrasound diagnosis of megalourethra associated with enterolithiasis <i>N. Sabry (Egypt)</i>	EP12.11
Two cases of prenatally diagnosed autosomal recessive polycystic kidney disease treated with intensive respiratory management <i>A. Kanai (Japan)</i>	EP12.12
A case of partial urorectal septum malformation sequence with a very small lower abdominal cyst and review of literature <i>F. Liu (China)</i>	EP12.13
Discordant monochorionic monoamniotic twin malformation: omphalocele-extrophy-imperforate anus-spinal (OEIS) defect complex <i>R.A. Moreira de Sa (Brazil)</i>	EP12.14
Prenatal diagnosis and outcome of congenital aortic aneurysm: a case report <i>E.S. Nekrasova (Russian Federation)</i>	EP12.15
Fetal ascites: when the mesentery beckons <i>D. Singh (India)</i>	EP12.16
Fetal adrenal gland enlargement: prenatal and postnatal management <i>A. Cunderlik (Slovakia)</i>	EP12.17
WITHDRAWN	EP12.18
Diagnosis by ultrasound of omphalocele during first trimester of pregnancy <i>C. Martínez-Payo (Spain)</i>	EP12.19
Evaluation, natural history and fetal outcome in renal pelvis dilatation <i>R.E. Bohiltea (Romania)</i>	EP12.20
Fetal small bowel volvulus: ultrasound and MRI findings – which is the best? <i>J. Faure (France)</i>	EP12.21
WITHDRAWN	EP12.22
Application of 3D multislice ultrasound in analysis of fetal urinary tract abnormalities <i>Z. Jurisic (Serbia)</i>	EP12.23
Fetal abdominal cystic masses: three-year experience of a tertiary centre <i>D.G. Iliescu (Romania)</i>	EP12.24
Fetal spontaneous resolution of small bowel volvulus: prenatal ultrasound and MRI diagnosis and neonate issue <i>J. Faure (France)</i>	EP12.25
The prenatal sonographic diagnosis and value assessment of fetal abdominal cystic echo <i>Q. Wu (China)</i>	EP12.26
WITHDRAWN	EP12.27
WITHDRAWN	EP12.28
Antenatally diagnosed abdominal cysts: 11 years' experience <i>E. Sanna (Italy)</i>	EP12.29

Significance and outcome of simple renal cysts detected antenatally <i>E. Sanna (Italy)</i>	EP12.30
Prenatal prognosis markers in congenital diaphragmatic hernia <i>E. Gómez Montes (Spain)</i>	EP12.31
Fetal megacystis: prenatal detection, neonatal outcome and follow-up in 25 consecutive cases observed in a tertiary referral centre <i>L. Masini (Italy)</i>	EP12.32
Acidosis predictive factors in fetal gastroschisis <i>P. Moore (Chile)</i>	EP12.33
Postnatal outcomes of antenatally diagnosed abdominal cysts <i>E. Sanna (Italy)</i>	EP12.34
Reliability of prenatal diagnosis on neonatal outcome in isolated left-sided congenital diaphragmatic hernia: the results of the perinatal centre in the years 2003–2015 <i>P. Hanulíková (Czech Republic)</i>	EP12.35
Prenatal diagnosis of anterior urethral valve: a rare cause for fetal hydronephrosis <i>S. Perlman (Israel)</i>	EP12.36
The value of 2D and 3D bladder volume measurement in the prediction of spontaneous resolution of prenatal hydronephrosis <i>M.S. Daly (United Kingdom)</i>	EP12.37

EP13: Ultrasound of chromosomal anomalies

HDlive Studio for antenatal diagnosis of Apert syndrome <i>K. Yamamoto (Japan)</i>	EP13.01
Prenatal diagnosis of Emanuel syndrome: a case report <i>D. Kilijanová (Czech Republic)</i>	EP13.02
Pierre Robin sequence resulting from 1q21.1 deletion in a neonate <i>S. Kim (Republic of Korea)</i>	EP13.03
Prenatal diagnosis of Pallister–Killian syndrome by 2D/3D ultrasound in second trimester <i>V. Frisova (Czech Republic)</i>	EP13.04
Upper limbs malformation and mutation in RECQL4 gene first trimester prenatal diagnosis <i>C. Martínez-Payo (Spain)</i>	EP13.05
Prenatal diagnosis of Ellis-van Creveld syndrome (EVCS): a case report <i>K. Tsurane (Japan)</i>	EP13.06
Pathological findings in the study of prenatal arrays by structural ultrasound anomalies <i>B. Herrera (Spain)</i>	EP13.07
Prenatal diagnosis of Holt–Oram syndrome <i>K. Maeda (Japan)</i>	EP13.08
Conradi–Hünemann–Happle syndrome, prenatal diagnosis and family generational report <i>L. Javier (Chile)</i>	EP13.09

EP14: Normal and abnormal fetal growth

Gestational age estimator based on MRI data: a user-friendly graphical user interface <i>S. Sejidbakti (Islamic Republic of Iran)</i>	EP14.01
The prediction study of fetal growth restriction with universal third trimester ultrasonic measurements and Doppler parameters <i>C. Zhu (China)</i>	EP14.02
Fetal renal artery Doppler in a healthy population <i>S. Contag (United States)</i>	EP14.03
Prediction of small-for-gestational-age neonates at term by second and third trimester fetal biometry using INTERGROWTH-21st and high altitude charts at 3,400m above sea level <i>W. Villamonte Calanche (Peru)</i>	EP14.04

Intra- and interobserver reproducibility of fetal measurements in third trimester ultrasound: does maternal weight matter? <i>C. Policiano (Portugal)</i>	EP14.05
Correlation of 3D fractional limb volumes with birth weight in fetuses with gastroschisis <i>S. Tuburan (United States)</i>	EP14.06
3D ultrasound measurement of volume and blood flow in normal fetal kidney <i>J. Wang (China)</i>	EP14.07
An unfavourable intrauterine environment may determine renal functional capacity in adulthood: systematic review and meta-analysis <i>M.A. Carvalho (Brazil)</i>	EP14.08
A hypercoiled cord can cause an atypical ductus venosus Doppler in cases of fetal growth restriction <i>S. Iwagaki (Japan)</i>	EP14.09
The impact of recurrent genital herpes on the state of fetus <i>L. Vygviska (Ukraine)</i>	EP14.10
The normal range of fetal abdominal circumference velocity between 20 and 36 weeks of gestation <i>S. Vannuccini (United Kingdom)</i>	EP14.11
Echographic morphometry of the pancreas of the fetus in uncomplicated pregnancy and IUGR <i>I.V. Ignatko (Russian Federation)</i>	EP14.12
The association between fetal abdominal circumference growth velocity and placental biomarkers in appropriate-for-gestational-age neonates <i>M. Hendrix (Netherlands)</i>	EP14.13
Application of the fetal ultrasound imaging for fetal malformation detection in early and mid-pregnancy <i>M. Liu (China)</i>	EP14.14
Which Doppler parameter during the second trimester ultrasound should be assessed as predictor for small-for-gestational-age fetus? <i>E. Cosmi (Italy)</i>	EP14.15
Doppler changes and management in late onset IUGR <i>T.F. Oluoyami-Obi (Canada)</i>	EP14.16
Fetal abdominal circumference in the second trimester and prediction of small-for-gestational age at birth <i>G. Doulaveris (United States)</i>	EP14.17
WITHDRAWN	EP14.18
Comparison of fetal liver length of diabetic and non-diabetic Filipino mothers at 14– 40 weeks' gestational age <i>N.C. Dimaano (Philippines)</i>	EP14.19
Pentaerithrityl tetranitrate (PETN) for secondary prevention of intrauterine growth restriction (PETN-Trial-DFG GR 1955 4-1) <i>U. Schneider (Germany)</i>	EP14.20
Longitudinal comparison of two techniques for non-invasive measurement of cardiac output from pre-conception to postpartum <i>G. Masini (United Kingdom)</i>	EP14.21
WITHDRAWN	EP14.22
Human long bone development in intrauterine growth restriction: <i>in vivo</i> analysis of the distal femoral epimetaphysis on prenatal MR imaging <i>U. Nemer (Austria)</i>	EP14.23
Early and late fetal growth restriction: changes in fetal Doppler flow and correlation with pregnancy outcome in China <i>L. Sun (China)</i>	EP14.24
Placental weight and volume related to birthweight and third trimester maternal blood sample in normal and IUGR pregnancies <i>A. Suranyi (Hungary)</i>	EP14.25

- Ketanserin can reduce vascular resistance in umbilical and placental veins but not in arteries both in IUGR and control pregnancies EP14.26
A. Suranyi (Hungary)
- Outcome comparison of the pregnancies with undetected macrosomia with known macrosomia EP14.27
S. Farrakh (United Kingdom)
- Correlation of various fetal sonographic parameters to the gestational age in early pregnancy EP14.28
H. Wong (Australia)
- Assessment of normal renal function in second trimester ultrasound screening EP14.29
M. Ditte (Slovakia)
- Monitoring of fetuses with intrauterine growth restriction: sonographic biometric assessment – abdominal circumference vs EFW EP14.30
E. Pirnareva (Bulgaria)
- Does clinical and ultrasonography estimation of fetal weight predict fetal birthweight at term? EP14.31
E. Zohav (Israel)
- Analysis of fetal respiratory movement EP14.32
F.M. Andrade (Brazil)
- Assessment of the blood flow of kidney in growth-restricted fetuses using quantitative three-dimensional power Doppler ultrasound EP14.33
P. Tsai (Taiwan)
- Psychosocial stress and placenta vascular malperfusion across pregnancy EP14.34
S. Kim (Republic of Korea)
- The influence of fetal gender on the antenatal detection of small-for-gestational-age fetuses EP14.35
G. Volpe (United Kingdom)
- Correlation between ultrasound images and pathological findings of placenta with early-onset severe fetal growth restriction EP14.36
M. Ohashi (Japan)
- Cerebroplacental ratio for the prediction of placental vascular malperfusion in normally grown fetuses EP14.37
J. Yim (Republic of Korea)
- Three-dimensional prenatal diagnosis of true knots of the umbilical cord: a five-year experience EP14.38
L. Markova (Bulgaria)
- Should we consider prenatal diagnosis of Silver–Russell syndrome? EP14.39
S. Wavrant (Canada)
- Abnormal chromosomes 18 on microarray: SNP-array analysis with normal band G karyotype in a severe growth-restricted fetus EP14.40
F.M. Andrade (Brazil)
- Right ventricle diastolic function assessment improved diagnosis of a high risk IUGR fetus with normal umbilical artery Doppler and without a wave reversal in ductus venosus EP14.41
P. Moore (Chile)
- Fetal cerebrorenal ratio and cerebroplacental ratio to evaluate the small fetus EP14.42
S. Contag (United States)
- Accuracy of fetal weight estimated on scan at 40 weeks and beyond: a retrospective cohort study EP14.43
V. White (United Kingdom)

EP15: Case presentations of abnormal placentas

- Placenta vascular malperfusion and their relationship with fetal Doppler in overweight/obese pregnant women EP15.01
J. Shin (Republic of Korea)
- Prenatal diagnosis of abnormally invasive placenta EP15.02
M. Tsankova (Bulgaria)
- Does a short cervix predict antepartum massive hemorrhage in patients with placenta previa? EP15.03
A. Togo (Japan)

Developing expertise in diagnosis of abnormally invasive placenta: a comparison of MRI and ultrasound assessment with surgery or histology findings <i>K. Rademan (South Africa)</i>	EP15.04
Velamentous placenta with separation the vessels umbilical cord and vasa previa <i>L. Gotovtseva (Russian Federation)</i>	EP15.05
A case of abnormally invasive placentation in a nulliparous woman following uterine artery embolisation for uterine fibroids <i>W. Almeida (Australia)</i>	EP15.06
Positive result of first trimester combined screening as a first sign of coexistence of normal and molar pregnancy: case report <i>M. Szubert (Poland)</i>	EP15.07
Reducing the risk of bleeding in hypervascular malformations of the uterus <i>B. Csapo (Austria)</i>	EP15.08
True umbilical cord hemangioma with significant hemodynamic alterations: case report <i>A.S. Castellanos Gutierrez (Germany)</i>	EP15.09
Observation of a uterine septum and hammock-like placenta: a case report <i>V. Schiffer (Netherlands)</i>	EP15.10
Partial hydatiform mole: a case report <i>F. Presti (Italy)</i>	EP15.11
Diagnosis and management of abnormal placentation in tertiary care centre in Sri Lanka <i>J.P. Jayasinghe (Sri Lanka)</i>	EP15.12
A suspected case of placental adhesive disorder in the first trimester <i>S.L. Malone (Australia)</i>	EP15.13
An optimal timing of Caesarean delivery in placenta previa <i>S. Hong (Republic of Korea)</i>	EP15.14
Amniotic band constriction of umbilical cord in third trimester causing stillbirth: a case report <i>E.Q. Barreto (Brazil)</i>	EP15.15

EP16: Doppler and pre-eclampsia

Effect of a new method of assessment and onsite training on the reproducibility of the measurement of uterine artery Doppler <i>L. Poon (Hong Kong)</i>	EP16.01
A novel approach for first trimester uterine artery Doppler assessment: the transverse technique <i>J.M. Johnson (Canada)</i>	EP16.02
The role of middle cerebral artery Doppler in the detection of fetal anemia in pregnancy with decreased perception of fetal movements <i>F. Bellussi (Italy)</i>	EP16.03
The value of uterine artery Doppler at 18–24 weeks' gestation in predicting adverse pregnancy outcomes among pregnant women with chronic hypertension <i>S.L. Suplido (Philippines)</i>	EP16.04
Effect of curcumin in decreasing MDA level in pre-eclampsia-induced human umbilical vein endothelial cell (HUVEC) <i>C. Yeni (Indonesia)</i>	EP16.05
Pravastatin improves placental perfusion and decreases umbilical artery vascular resistance in singleton pregnancies <i>A. Jurisic (Serbia)</i>	EP16.06
The study for the effect of different diameter in bilateral umbilical arteries on the formation of umbilical twist <i>M. Nakamura (Japan)</i>	EP16.07

WITHDRAWN	EP16.08
Cerebroplacental ratio at term and risk of adverse perinatal outcome <i>G. Albaiges Bajget (Spain)</i>	EP16.09
Prediction of adverse outcomes in women with hypertensive disorders of pregnancy near term utilising the uterine artery pulsatility index <i>J.R. Duncan (United States)</i>	EP16.10
Umbilical artery notch: appearance and timing may be explained by pulse wave reflection and propagation <i>M. Gonser (Germany)</i>	EP16.11
WITHDRAWN	EP16.12
The correlation of nuchal translucency and maternal serum aneuploidy markers with placental dysfunction <i>H. Lee (Republic of Korea)</i>	EP16.13
First trimester screening of circulating C19MC microRNAs and the evaluation of their potential to predict the onset of pre-eclampsia and IUGR <i>L. Hromadnikova (Czech Republic)</i>	EP16.14
Correlation between different methods for mean arterial pressure measurement and possible bias effects on early pre-eclampsia screening risks model <i>H. Oviedo-Cruz (Mexico)</i>	EP16.15
Does the first trimester screening of A.uterina flow changes correlate with a genetic predisposition to pre-eclampsia development? <i>N. Vedmedovska (Latvia)</i>	EP16.16
Contribution of uterine artery Doppler in the prediction of uteroplacental insufficiency <i>D. Chelli (Tunisia)</i>	EP16.17
Pregnancy association of abnormal Doppler indices with inherited thrombophilia <i>R.E. Bohiltea (Romania)</i>	EP16.18
Transient angiogenic improvement after nitric oxide precursor intake as endothelial therapy for pre-clinical pre-eclampsia <i>H. Oviedo-Cruz (Mexico)</i>	EP16.19

EP17: Maternal and fetal assessment

Perinatal management and pregnancy outcome in pregnant women with congenital heart disease <i>S. Ge (United States)</i>	EP17.01
Third trimester non-invasive evaluation of maternal cardiac function in gestational diabetes <i>C. Migliavacca (Italy)</i>	EP17.02
Effectiveness of a 2-weekly HIG protocol in first trimester CMV infection <i>K.O. Kagan (Germany)</i>	EP17.03
The impact of placental cord insertion on pregnancy outcome <i>C. Rouse (United States)</i>	EP17.04
WITHDRAWN	EP17.05
Ultrasound evaluation of maternal visceral adiposity tissue (VAT) during pregnancy and the impact in maternal glycemic levels (preliminary results) <i>A.D. Rocha (Brazil)</i>	EP17.06
First trimester maternal visceral adipose tissue thickness is independently associated with postpartum maternal adiposity <i>H. Berger (Canada)</i>	EP17.07
The association between maternal vitamin B12 insufficiency and obesity: a systematic review <i>N. Khan (United Kingdom)</i>	EP17.08
WITHDRAWN	EP17.09
Pregnancy outcome of presentation with reduced fetal movements (RFM) to day assessment unit <i>F. Ajibade (United Kingdom)</i>	EP17.10

Evaluation of self-testing of urine by patient during pregnancy <i>F. Ajjade (United Kingdom)</i>	EP17.11
WITHDRAWN	EP17.12
Increased incidence of obstetric complications in women carrying mitochondrial DNA mutations <i>L.J. Salomon (France)</i>	EP17.13
WITHDRAWN	EP17.14
Obstetric ultrasound of patients in prison. <i>F.M. Andrade (Brazil)</i>	EP17.15
Fetomaternal transfusion: a case with antenatal diagnosis <i>M. Yamamoto (Chile)</i>	EP17.16
Risks factors for congenital CMV infection following primary and non-primary maternal infection: a prospective neonatal screening study using PCR in saliva <i>Y. Ville (France)</i>	EP17.17

EP18: Preterm birth

Role of cervical length and birthweight in women with history of previous Caesarean section: prediction of early onset of labour before 39 weeks of gestation <i>J. Wie (Republic of Korea)</i>	EP18.01
The association between elastogram of the cervix and preterm delivery among parturients at risk for preterm delivery: a prospective study <i>R. Baldes (Israel)</i>	EP18.02
The evolution of cervical length during pregnancy in singletons and twins and analysis of influencing factors <i>V. Serra (Spain)</i>	EP18.03
Spontaneous preterm birth and cervical length in a pregnant Asian population <i>S. Thain (Singapore)</i>	EP18.04
Cervical elastography in high-risk pregnancy for preterm birth treated with cervical cerclage <i>T. Dias (Sri Lanka)</i>	EP18.05
Maternal interleucin-6 as a predictor of histological chorioamnionitis in patients with premature rupture of membranes <i>R.J. Martinez-Portilla (Spain)</i>	EP18.06
At which gestational period is cervical length most predictive of spontaneous preterm delivery in singleton and twin pregnancies? <i>V. Serra (Spain)</i>	EP18.07
Predicting preterm birth by sonographic analysis of the texture of uterine cervix <i>H. Joern (Germany)</i>	EP18.08
Expression profile of C19MC microRNAs in placental tissue of patients with preterm prelabour rupture of membranes and spontaneous preterm birth <i>I. Hromadnikova (Czech Republic)</i>	EP18.09
First trimester screening maternal and biochemical factors affecting preterm delivery <i>M. Li (Singapore)</i>	EP18.10
Addition of cervical elastography may increase preterm delivery prediction performance in pregnancies with short cervix: a prospective study <i>S. Oh (Republic of Korea)</i>	EP18.11
Uterine polyp and pregnancy outcome <i>J. Bae (Republic of Korea)</i>	EP18.12
Transvaginal 3D ultrasonography and quantitative elastography of the uterine cervix as a predictor of cervical incompetency and preterm delivery <i>M. Podobnik (Croatia)</i>	EP18.13
Influence of previous vaginal delivery on cervical length <i>J. Kwon (Republic of Korea)</i>	EP18.14

Efficacy of emergency cervical cerclage using absorbable monofilament suture <i>Y. Sato (Japan)</i>	EP18.15
Second trimester sludge as a marker for preterm birth <i>A.K. Kesrouani (Lebanon)</i>	EP18.16
Amniotic sheets and pregnancy outcomes: a case series <i>W. Sim (Singapore)</i>	EP18.17

EP19: Ultrasound in the labour ward

WITHDRAWN	EP19.01
Induction of labour at 39 or more weeks in uncomplicated gestations: maternal and neonatal risks <i>E. Kim (Republic of Korea)</i>	EP19.02
Accuracy of ultrasound in fetal weight estimation in case of clinical suspected macrosomia <i>D. Chelli (Tunisia)</i>	EP19.03
Sonographic appearance of the uterus in the early puerperium in vaginal vs Caesarean deliveries: a prospective study <i>R. Bardin (Israel)</i>	EP19.04
The dynamic changes in upper and lower uterine segment in 3rd stage of labour and blood loss during 3rd stage of labour <i>L. Eslamian (Islamic Republic of Iran)</i>	EP19.05
Clinical factors and ultrasound parameters to predict successful vaginal delivery following labour induction <i>E. Kim (Republic of Korea)</i>	EP19.06
Transperineal ultrasound to assess caput succedaneum in labour: a more objective assessment compared to digital vaginal examinations? <i>S. Usman (United Kingdom)</i>	EP19.07
Prolonging the second stage of labour increases risks of complications <i>S. Yagel (Israel)</i>	EP19.08
WITHDRAWN	EP19.09
WITHDRAWN	EP19.10
Mesenteric venous thrombosis and uterine synechiae after uterine arterial embolisation for postpartum bleeding due to placenta accreta <i>H. Kang (Republic of Korea)</i>	EP19.11
Sonographic demonstration of a third degree perineal tear after delivery <i>F. Bellussi (Italy)</i>	EP19.12
The use of transperineal ultrasound as a complementary tool for the management of vaginal hematomas and in the detection of the bleeding vessel: a case report <i>A. Yousef (Italy)</i>	EP19.13

EP20: New data in multiple pregnancies

<i>In utero</i> partial exchange transfusion (iPET) combined with <i>in utero</i> blood transfusion (IT) for treatment of twin anemia polycythemia sequence <i>J.A. Copel (United States)</i>	EP20.01
Diagnostic performance of middle cerebral artery peak systolic velocity for fetal severe anemia in advanced gestational age of monochorionic diamniotic twin pregnancy <i>J. Oh (Republic of Korea)</i>	EP20.02
Cervical length measurement as a screening tool for spontaneous preterm delivery in twins <i>L. Markova (Bulgaria)</i>	EP20.03
Diagnostic indices of MCA PSV for fetal severe anemia in MCDA twin pregnancy <i>J. Oh (Republic of Korea)</i>	EP20.04

A case of twin reversed arterial perfusion (TRAP) sequence misdiagnosed as discordant twin in first trimester <i>J. Kim (Republic of Korea)</i>	EP20.05
Initial experience of a fetal medicine service in the accomplishment of fetoscopy for the treatment of feto-fetal transfusion syndrome <i>H.J. Milani (Brazil)</i>	EP20.06
111 TTTS cases treated in Talca and Santiago with classical selective technique: towards a Chilean perinatal network <i>M. Yamamoto (Chile)</i>	EP20.07
Neurodevelopment outcome after intrauterine transfusion for monochorionic twin pregnancies focusing fetal life-threatening status <i>Y. Takahashi (Japan)</i>	EP20.08
Fetal growth in South Indian dichorionic twin pregnancies <i>L. Shanmugasundaram (India)</i>	EP20.09
Maternal cardiac function in twin pregnancy with pre-eclampsia <i>K. Shimizu (Japan)</i>	EP20.10
Ultrasound labelling of twins: could the placental cord insertion be useful? <i>N. Volpe (Italy)</i>	EP20.11
The heartless triplet: acardius anceps complicating monochorionic pregnancy <i>K.B. Gajewska-Knapik (United Kingdom)</i>	EP20.12
Vasa previa due to communicating distant dichorionic placentas <i>A. Alhousseini (United States)</i>	EP20.13
Natural history of a monochorionic triamniotic triplet pregnancy complicated with TRAP sequence: prenatal ultrasonographic and postnatal placental findings – “a pump, an indirect pump and an acardiac triplets’ destiny” <i>K. Lee (Republic of Korea)</i>	EP20.14
WITHDRAWN	EP20.15
Not-Quintero sequence TTTS or TAPS with polyhydramnion/oligohidramnion: sometimes they are difficult to classify <i>I. Safonova (Ukraine)</i>	EP20.16
Ultrasound description and histopathologic-genetic confirmation of a vanishing twin phenomenon <i>A.J. Sigue (Philippines)</i>	EP20.17
Monochorionic twin pregnancy with proximate umbilical cord insertion (PCI): case study <i>P.S. Bataeva (Russian Federation)</i>	EP20.18
Discordant anomalies in monochorionic monoamniotic (MCMA) twin pregnancy <i>N. Al Riyami (Sultanate of Oman)</i>	EP20.19
“Two weeks’ younger sister”: a case of monopaternal superfecundation after clomifene citrate ovulation induction <i>M. Ciebiera (Poland)</i>	EP20.20
Assessment of third trimester fetal cardiac morphometry and function in monochorionic diamniotic twins with Twin–twin transfusion syndrome after fetal surgery <i>X. Torres (Spain)</i>	EP20.21

EP21: Fetal interventions

Management of pregnancies at risk of hemolytic disease of the fetus and newborn in the Czech Republic <i>M. Lubusky (Czech Republic)</i>	EP21.01
Intrauterine open fetal surgery for cervical spina bifida correction: case report <i>S. Sarmento (Brazil)</i>	EP21.02
Contact laser for severe CCAM with hydrops: not only good news <i>M. Yamamoto (Chile)</i>	EP21.03

Radiofrequency ablation of a giant fetal sacrococcygeal teratoma
A. Corbacioglu-Esmer (Turkey) EP21.04

EP22: Innovations in obstetric imaging

An application of ultrasound elastography for uterine cervix assessment during pregnancy EP22.01

A. Idelson (Israel)

Role of emergency magnetic resonance imaging in the workup of suspected appendicitis in pregnant women EP22.02

E. Katarza (Israel)

Cervical elastography for predicting the time to delivery EP22.03

S. Choi (Republic of Korea)

Assessment of Caesarean section scar stiffness by ultrasound elastography EP22.04

A. Dall'Asta (Italy)

WITHDRAWN EP22.05

Morphology of maternal structures in fetal MRI: a retrospective, clinical-anatomical data analysis EP22.06

G.M. Gruber (Austria)

Blood flow calculated in the uterine arteries based on the PixelFlux technique EP22.07

T. Andersen (Norway)

Discrepancy in fetal head biometry between ultrasound and MRI in suspected microcephalic fetuses EP22.08

E. Katarza (Israel)

Handheld ultrasound device: transverse section of uterus as a plane of choice for postpartum period EP22.09

E. Mujezinović (Slovenia)

A novel semi-automated technique for measuring carotid intima-media thickness in pregnant women EP22.10

S. Santhirakumaran (United Kingdom)

Use of "elasto strain ratio" in the assessment of the cervical internal os stiffness in asymptomatic, low-risk pregnant women: preliminary study EP22.11

P.R. Szkodziak (Poland)

A multi-biomarker approach to evaluation of the human pregnant cervix using quantitative ultrasound EP22.12

(QUS) imaging biomarkers

H. Feltovich (United States)

Comparison study: obtaining augmentation index using the Vicorder compared to a novel semi-automated technique EP22.13

S. Santhirakumaran (United Kingdom)

Longitudinal study of ultrasound measures of maternal abdominal subcutaneous fat layers EP22.14

M.J. Peek (Australia)

Feasibility of automated recognition of fetal abdominal circumference on antenatal ultrasound by using convolutional neural network EP22.15

Y. Park (Republic of Korea)

Comparison of a 2D and 3D measurement of the intracranial translucency using post-processing software EP22.16

B.J. Mein (Australia)

Automatic detection and measurement of bi-dimensional fetal head planes from 3D ultrasound EP22.17

volumes using a prototype tool

A. Cavallaro (United Kingdom)

Factors affecting the condition of the fetal brain on postmortem MRI EP22.18

G.M. Gruber (Austria)

Investigating the effect of umbilical cord insertion site on placental perfusion EP22.19

R. Pratt (United Kingdom)

Automated three-dimensional measurements of cephalic fetal biometry: feasibility and reproducibility EP22.20

A. Chabot-Lecoanet (France)

Magnetic resonance in fetal cerebral lesions EP22.21

J.H. Ochoa (Argentina)

- Prenatal diagnosis of fetal lower urinary tract obstruction presenting as an abdominal mass in a twin pregnancy using three-dimensional ultrasound with “fly thru” technology: a case report
N.C. Dimaano (Philippines) EP22.22
- Novel three-dimensional imaging of the fetal kidneys in the first trimester
H. Shah (United Kingdom) EP22.23
- New blood flow imaging technique of Superb Micro-vascular Imaging (SMI) in obstetrics
J. Hasegawa (Japan) EP22.24

EP23: Education, simulation and safety

- The first advanced cardiac life support course in obstetrics in Japan: perinatal critical care course (PC3)
T. Maenaka (Japan) EP23.01
- The impact of simulation-based training in the Lebanese outreach setting
R.S. Abu-Rustum (Lebanon) EP23.02
- Evaluation of knowledge transfer through telemedicine: evaluation of ISUOG live webcast of basic obstetrics and gynecology ultrasound training in Rwanda
D. Nirushwa (Rwanda) EP23.03
- Integration of 3D/4D ultrasound technology into undergraduate medical education: student perception
T. Kondrashova (United States) EP23.04
- Improving obstetrical care in medically underserved communities using modern technology: medical student perception
T. Kondrashova (United States) EP23.05

EP24: Ultrasound and management of early pregnancy complications

- The evolution and significance of enlarged nuchal translucency detected before 11 weeks of pregnancy
M. Hynek (Czech Republic) EP24.01
- Association of embryonic bradycardia with gestational outcomes using first trimester transvaginal ultrasound (TVS)
A.J. Sigue (Philippines) EP24.02
- Pregnancy in a non-communicating rudimentary horn: diagnostic challenges and late sonographic diagnostic criteria
T. Indrielle (United Kingdom) EP24.03
- Robustness of free-Beta-hCG and PAPP-A model matched by median correction factors for Mexican population
H. Oviedo-Cruz (Mexico) EP24.04
- Ultrasound (US) and magnetic resonance imaging (MRI) findings of fetal heart beat (FHB)-positive Caesarean scar pregnancy (CSP) in a developed country
T. Hoshino (Japan) EP24.05
- Early sonography signs of low-lying implantation ectopic pregnancy
V. Makukhina (Russian Federation) EP24.06
- Medical termination of pregnancy up until the 7th week of gestation in the Czech Republic: the role of ultrasound in diagnosis and follow-up
M. Lubusky (Czech Republic) EP24.07
- A case report of uterine cervical pregnancy evaluated by Superb Micro-vascular Imaging (SMI)
H. Nakazawa (Japan) EP24.08
- Recurrent benign pelvic schwannoma in pregnancy: a case report
P. Greimel (Austria) EP24.09
- Audit on anti-D antibody prophylaxis for early pregnancy complications
C. Kandauda (Sri Lanka) EP24.10
- Retrospective study on first trimester miscarriages in Teaching Hospital Peradeniya, Sri Lanka
J.P. Jayasinghe (Sri Lanka) EP24.11

Management of Caesarean scar pregnancy: towards a new protocol <i>D. Chelli (Tunisia)</i>	EP24.12
Cervical ectopic pregnancy: case series of 6 cases <i>S.D. Matang (India)</i>	EP24.13
A curious uterine tumour in pregnancy <i>S. Wavrant (Canada)</i>	EP24.14
Ultrasound characteristics of retained products of conception: could the type of measurement help in the choice of treatment options offered? <i>M. Oniah (United Kingdom)</i>	EP24.15
Risk factor evaluation and management of ectopic pregnancy in a tertiary care institute, Sri Lanka <i>C. Kandauda (Sri Lanka)</i>	EP24.16
WITHDRAWN	EP24.17
Heterotopic pregnancy and interstitial ectopic pregnancy: 6 cases series <i>L. Safonova (Ukraine)</i>	EP24.18
Heterotopic pregnancy in a spontaneous pregnancy <i>P. Moreno Munoz (Spain)</i>	EP24.19
Management of advanced cervical pregnancy <i>L. Nieder (Germany)</i>	EP24.20
Accuracy of ultrasound for the diagnosis and the monitoring of ectopic pregnancy with atypical localisation <i>D. Chelli (Tunisia)</i>	EP24.21
Management of Caesarean scar ectopic pregnancy with infusion of methotrexate into the gestational sac under ultrasound guidance <i>M. Theodora (Greece)</i>	EP24.22
Caesarean scar pregnancy: a case report <i>C.R. Cassis-Phillips (Ecuador)</i>	EP24.23
Cervical ectopic pregnancy: a case report <i>C.R. Cassis-Phillips (Ecuador)</i>	EP24.24

EP25: Classifying and managing ovarian masses

Performance of IOTA ADNEX model in the selected group of patients with borderline ovarian tumours <i>M. Gedgaudaite (Lithuania)</i>	EP25.01
Diagnostic gain of US and MRI imaging in case of an extreme large epithelial ovarian cancer associated with pregnancy <i>G. Vajda (Hungary)</i>	EP25.02
Ultrasound features of a jejunal adenocarcinoma with ovarian metastasis: a case report <i>B. Grandal (Spain)</i>	EP25.03
Unusual pelvic sonographic findings: a case series <i>M. Leonardi (Canada)</i>	EP25.04
Sonographic markers in treatment of hemoperitoneum caused by corpus luteal cyst rupture <i>M. Kim (Republic of Korea)</i>	EP25.05
Coexistence of ovarian and endometrial cancer on the ground of endometriosis <i>M. Szubert (Poland)</i>	EP25.06
Rare adenomatoid tumour of the uterus <i>M.M. Kolodziejcki (Poland)</i>	EP25.07
The value of pattern recognition of ultrasound diagnosis of adnexal masses compared to the histological outcome <i>S. Schwab (Austria)</i>	EP25.08
Comparison of diagnostic value of using GIRADS system and ovarian malignancy marker Ca-125 in the preoperational adnexal tumours assessment <i>M. Migda (Poland)</i>	EP25.09
Intestine tumour presenting as an adnexal mass <i>F. Buonomo (Italy)</i>	EP25.10

Rare virilising granulosa cell tumour in an adolescent: ultrasonographic and MRI diagnostics, clinical features and treatment <i>G. Vajda (Hungary)</i>	EP25.11
Abdominopelvic actinomycosis associated with an intrauterine device: a case report <i>N. Rams (Spain)</i>	EP25.12
Theca lutein cysts in the setting of primary hypothyroidism <i>J. Rukundo (Rwanda)</i>	EP25.13
Utility of GI-RADS classification in diagnosing malignant ovarian masses <i>M. Migda (Poland)</i>	EP25.14
Inversion and borderline ovarian tumours <i>E. Domali (Greece)</i>	EP25.15
Vascularisation of endometriomas: a case series <i>M. Leonardi (Canada)</i>	EP25.16
Images produced by 3D ultrasound scan could war investigator regarding the nature of the ovarian lesion <i>E. Domali (Greece)</i>	EP25.17
Risk of borderline malignancy and ultrasonic assessment <i>E. Domali (Greece)</i>	EP25.18
Cystic ovarian teratoma with intracystic fat balls <i>N. Rams (Spain)</i>	EP25.19
Diagnosis of bilateral ovarian torsion due to a giant dermoid: case report from Rwanda <i>J. Rukundo (Rwanda)</i>	EP25.20
About 13 cases of an unusual entity: the pelvic hydatic cyst <i>D. Chelli (Tunisia)</i>	EP25.21
Ovarian tumour suspect malignant during pregnancy: a case report and discussion on management options <i>C. Yeni (Indonesia)</i>	EP25.22
Small intestine myofibroblastic tumour: ultrasound findings and differential diagnosis <i>Y. Wang (Singapore)</i>	EP25.23
A case of anti-NMDA receptor encephalitis <i>L. Ng (Singapore)</i>	EP25.24

EP26: Diagnosing a cause for pelvic pain and classifying endometriosis

Value of "elasto strain ratio" ultrasound elastography in the diagnosis of adenomyosis: preliminary study <i>S. Wozniak (Poland)</i>	EP26.01
Ultrasound accuracy of transvaginal ultrasound compared with magnetic resonance image in deep infiltrating endometriosis <i>R. Rodriguez (Spain)</i>	EP26.02
Prediction of pouch of Douglas obliteration by analysing offline ultrasound and laparoscopic videosets: a diagnostic accuracy and inter-observer study <i>G. Condous (Australia)</i>	EP26.03
MRI-ultrasound fusion imaging for diagnosis of deep infiltrating endometriosis: a critical appraisal <i>J. Berger (Netherlands)</i>	EP26.04
Accuracy of transvaginal sonography in a series of patients operated of endometriosis <i>P. Español (Spain)</i>	EP26.05
Pelvic pain: looking beyond gynecologic pathology <i>D. Singh (India)</i>	EP26.06
Hydrosalpinx abruptly turned into hematosalpinx immediately after menstruation <i>S. Lee (Republic of Korea)</i>	EP26.07
Endometrioid carcinoma not to be mistaken for deep infiltrating endometriosis on transvaginal ultrasound <i>T. Van den Bosch (Belgium)</i>	EP26.08
Fibroid or endometriosis in the uterine wall? <i>B. Erdodi (Hungary)</i>	EP26.09

EP27: Imaging and reproductive medicine

- Complete septate uterus with double cervix and communication between both cavities: a case report of an uncommon anomaly
M. Hynek (Czech Republic) EP27.01
- Ultra-high magnification (IMSI) vs standard sperm selection (ICSI) for assisted reproduction
W.P. Martins (Brazil) EP27.02
- Longitudinal volumetric analysis of follicular growth
N. Subbarao (India) EP27.03
- Normal/arcuate vs septate uterus: agreement between currently recommended cut-off values for measurements and experts' opinion
A. Ludwin (Poland) EP27.04
- Hysterosalpingo-foam sonography: a 5-year experience of a single operator
M. Hynek (Czech Republic) EP27.05
- Intra- and interobserver agreement of three-dimensional ultrasound in assessing the uterine Mullerian anomalies
S. Tudorache (Romania) EP27.06
- Normal/arcuate vs septate uterus: diagnostic test accuracy and best cut-off values for currently used measurements
A. Ludwin (Poland) EP27.07
- Feasibility study on the use of ultrasound scan for the insertion of postpartum contraceptive device (PPIUD) following vaginal delivery
T. Padeniya (Sri Lanka) EP27.08
- An audit of our experience on the use of hysterosalpingo-contrast-sonography (HyCoSy)
V. Serra (Spain) EP27.09
- WITHDRAWN EP27.10
- Normal/arcuate vs septate uterus: interobserver reliability/agreement of currently used measurements
W.P. Martins (Brazil) EP27.11

EP28: Bleeding, endometrial and myometrial pathology

- Uterine artery pseudoaneurysm with coexisting arteriovenous malformation
F. Buonomo (Italy) EP28.01
- Two cases of growing inwardly uterine cervical carcinoma that were diagnosed by transvaginal ultrasound guided needle biopsy
T. Ichimura (Japan) EP28.02
- Association between ovarian volume and endometrial malignancy in women with postmenopausal bleeding
A.J. Sigue (Philippines) EP28.03
- Diagnosis of uterine arteriovenous malformation by 3D colour Doppler and conservative management with a gonadotropin-releasing hormone agonist
M.O. Tsuzuki (Japan) EP28.04
- Venous thromboembolism secondary to massive uterine leiomyoma
J.P. Jayasinghe (United Kingdom) EP28.05
- Survey on selecting patients with postmenopausal bleeding (PMB) for hysteroscopy: current practice and future clinical effectiveness.
E. Zielinski (United Kingdom) EP28.06
- PALM-COEIN classification of submucosal myomas using 3D saline contrast sonohysterography: intermethod agreement
A. Ludwin (Poland) EP28.07
- Ultrasound preoperative evaluation in the prediction of laparoscopic myomectomy complications
S. Baggio (Italy) EP28.08
- Ultrasonic images might be able to inform regarding the benignity or malignancy of endometrial lesions
E. Domali (Greece) EP28.09

- Thick uterine endometrium with “honeycomb” appearance in transvaginal ultrasonography revealed various gynecologic conditions: presented with flexible hysteroscopic findings EP28.10
S. Lee (Republic of Korea)
 WITHDRAWN EP28.11
 Descriptive study on PMB patients, who referred to RAC (rapid access clinic) in Queen Elizabeth Hospital, Gateshead EP28.12
J.P. Jayasinghe (United Kingdom)
 Gynecological ultrasound of patients in prison EP28.13
F.M. Andrade (Brazil)
 Study on the clinical symptoms of leiomyoma uteri based on diagnostic sonography EP28.14
A. Suranyi (Hungary)

EP29: Imaging in oncology patients

- The value of transvaginal elastography in the diagnosis of uterine fibroids EP29.01
Y. Ren (China)
 Superb Micro-vascular Imaging in cervical carcinoma: monitoring treatment response to neoadjuvant chemotherapy EP29.02
K. Uno (Japan)
 Accuracy of 2D ultrasonography in detecting lymph node metastasis in uterine and cervical malignancies at the Philippine General Hospital: a five-year retrospective study EP29.03
K.N. Reforma (Philippines)
 Feasibility of a transthoracic ultrasound scanning of diaphragm and pleural cavity for staging in patient suspected for advanced ovarian cancer EP29.04
M. Stukan (Poland)
 Importance of an adequate study in patients with primary amenorrhea and pelvic tumour EP29.05
L. Javier (Chile)
 Metabolic syndrome and risk of endometrial carcinoma among asymptomatic, postmenopausal, urban Sri Lankan females: a community cohort follow-up study EP29.06
T. Dias (Sri Lanka)
 The predictive value of advanced transvaginal sonography in patients with endometrial neoplasia EP29.07
E.M. Levine (United States)
 The efficacy of Superb Micro-vascular Imaging on diagnosing endometrial cancer EP29.08
T. Takeda (Japan)
 Preoperative power Doppler score in predicting depth of myometrial invasion in endometrioid type of endometrial carcinoma EP29.09
E. Moretti (Canada)
 Evaluation of myometrial infiltration in endometrial cancer using three different US techniques: expert vs untrained operator – preliminary results EP29.10
M. Rolla (Italy)
 Giant pedunculated leiomyosarcoma of the uterus: case report EP29.11
M.D. Bernarda (Portugal)
 Pelvic pathology diagnosed with transvaginal ultrasound EP29.12
L. Bonino (Italy)
 The role of uterine artery pulsatility index and a new ultrasound-guided approach to uterine biopsy in the pre-operative evaluation of placental site trophoblastic tumour EP29.13
P.I. Cavoretto (Italy)
 Ultrasound appearance of an ovarian metastasis from a primary lung cancer: case report EP29.14
A. Meira (Portugal)
 Uterine sarcomas: clinical presentation and imaging features EP29.15
D. Chelli (Tunisia)

EP30: Imaging and the urogynecology patient

- Ureter stone at the ureterovesical junction diagnosed with three-dimensional transvaginal ultrasonography
S. Lee (Republic of Korea) EP30.01
- Transperineal 3D sonography: how to define a well positioned suburethral sling?
P. Capmas (France) EP30.02
- Pelvic floor biometry ultrasound findings among primiparous women: a cross-sectional study
G.C. Pascual (Philippines) EP30.03

EP31: Innovations in gynecologic imaging

- Comparison between transvaginal ultrasound with water contrast (TVUWC) and computed tomography-based virtual colonoscopy (CTC) in detecting rectosigmoid DIE
M. Rolla (Italy) EP31.01
- Assessment of targeted ultrasound contrast agent on vasculogenic mimicry in ovarian cancer
H. Xiang (China) EP31.02
- Ultrasound-based strain mapping for quantitative characterisation of uterine activity outside pregnancy
Y. Huang (Netherlands) EP31.03
- Dyslipidemia, arteriosclerosis and osteoporosis in primary ovarian insufficiency
S. Igarashi (Japan) EP31.04
- Implementation of gynecological ultrasound examination report (software REGU) based on consensus of international specialised groups
R.E. Bohiltea (Romania) EP31.05
- Role of ultrasound examination for optimisation of young surgeon's learning curve in tertiary health care centre
L. Bonino (Italy) EP31.06

Voluson™

A HEALTHIER FUTURE FOR WOMEN

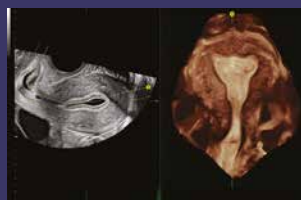
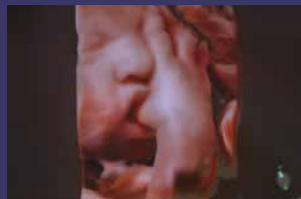
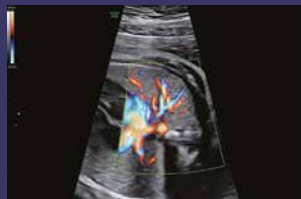
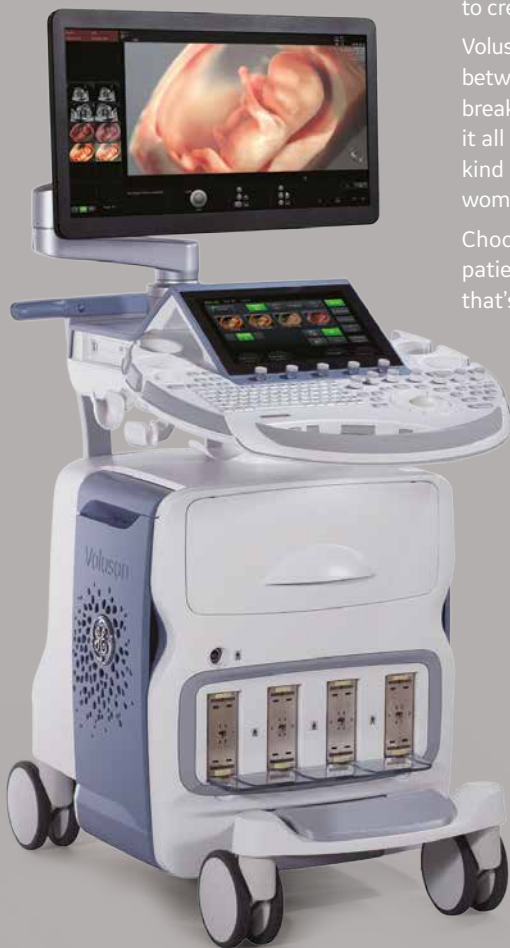Expect the best for your patients.
That's why Voluson is the only choice.

At GE Women's Health Ultrasound, we're committed to creating a healthier future for women.

Voluson's ultrasound solutions enhance the relationship between you and your patients, and work relentlessly to break new ground and advance innovation. And we do it all with the goal of empowering you to provide the kind of exceptional care that will exponentially improve women's lives, and ensure better health for generations.

Choose Voluson and take your practice – and your patients – confidently into the future with the partner that's as committed to Women's Health as you are.

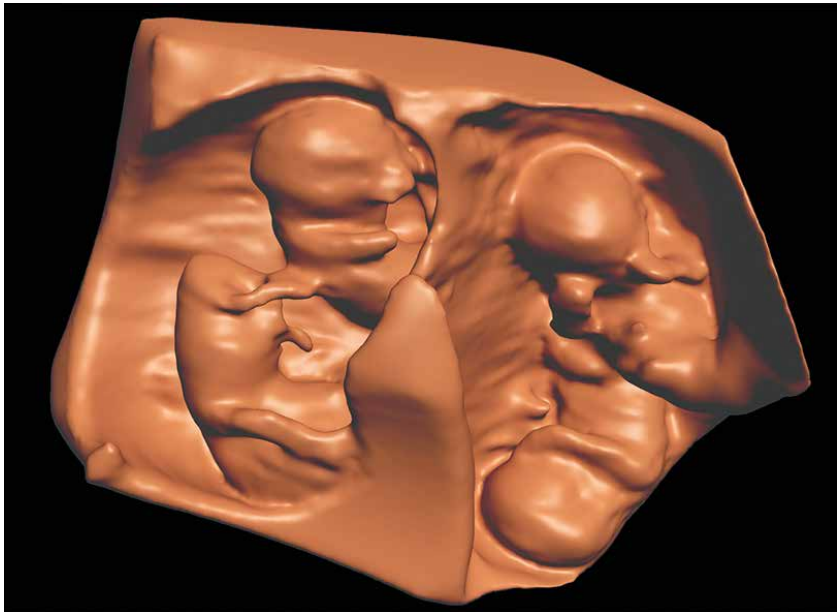


www.voluson.com

Voluson is a trademark of General Electric Company. JB50561XX

EXHIBITION & SPONSORSHIP

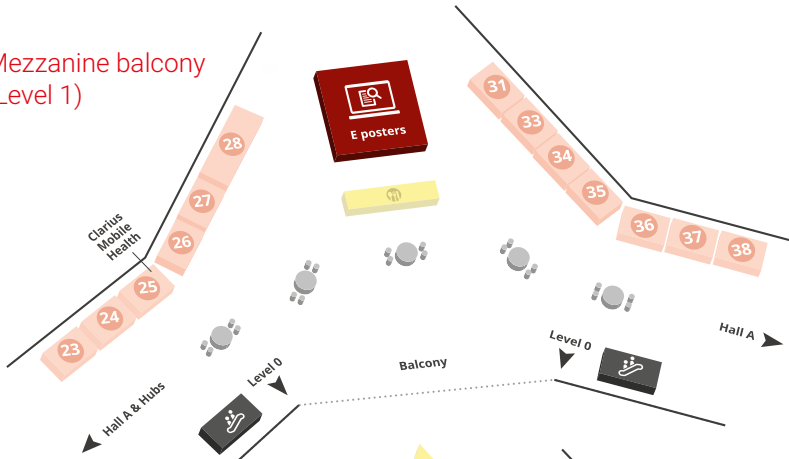
ISUOG 2017



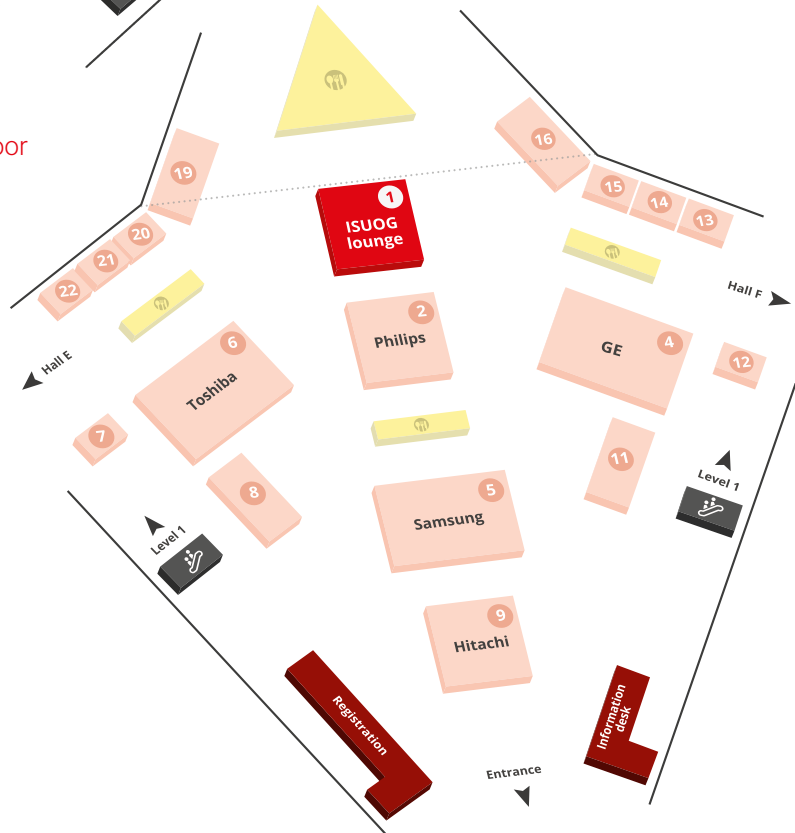Virtual image of quadruplet pregnancy - Werner H, Castro P, Daltro P, Lopes Dos Santos J, Ribeiro G, Tonni G, Campbell S, Araujo Júnior E. Monochorionic diamniotic quadruplet pregnancy: physical models from prenatal three-dimensional ultrasound and magnetic resonance imaging data. *Ultrasound Obstet Gynecol* 2017; 49: 812–814.

Exhibition floor plans

Mezzanine balcony
(Level 1)



Ground floor
(Level 0)



Exhibitor listing

Stand	Company
12	3D Systems Symbionix
23	Anatomy Art
13	astraiia software
14	CAE Healthcare
25	Clarius Mobile Health
35	ContextVision AB
15	ExEm Foam
4	GE Healthcare
9	Hitachi Medical Systems Europe
31	International Society for Prenatal Diagnosis (ISPD)
1	ISUOG lounge
20	Karl Storz GmbH & Co.KG
27	Malopolskie Warsztaty Ultrasonografii SP. Z.o.o
26	MedaPhor Ltd
36	MIDES GmbH
8	Mindray Medical
34	Parker Laboratories
7	Parsagen
22	PerkinElmer
2	Philips
19	Roche Sequencing Solutions
5	Samsung
21	Shenzhen Talecare Technologies
33	Society for Maternal-Fetal Medicine (SMFM)
37	SonoSim Inc.
6	Toshiba Medical Systems
16	Trice Imaging
11	Tristel
38	Versandbuchhandlung Stefan Schuldt
28	Wisepress Medical Bookshop
24	World Association of Trainees in Obstetrics and Gynaecology (WATOG)

3D Systems Simbionix

Booth: 12

5381 South Alkire Circle, Littleton, CO 80127, USA
+1 303 273 5344
Galia Zilbershtein: healthcare@3dsystems.com
www.simbionix.com

Experience the U/S Mentor VR immersive training simulator experience. The U/S Mentor is known for its virtual reality clinical cases and focused clinical scenarios with real ultrasound scans for OB/GYN transabdominal and transvaginal scanning. Designated skill tasks, diverse diagnostic scenarios and captured metrics help promote proficiency by providing residents, fellows, and practicing physicians to acquire and improve their sonography-related skills. These capabilities are now enhanced via VR goggles that help learners gain diagnostic proficiency.

Anatomy Art

Booth: 23

Zurich, 8032 Switzerland
+41 7653 692 06
Fatou Lo: Fatou.lo@hotmail.com
www.anatomy-art.com

Fatou Lo is an artist who creates cast bronze sculptures that combine parts of our anatomy with abstract aspects. Her project "LOOK INSIDE" demonstrates the incredibly rich and diverse relationship between the visual arts and anatomy. At ISUOG 2017 she will be showcasing her first finished cast bronze patinated fetus sculpture.

astraia software

Booth: 13

Occamstraße 20, 80802 Munich, Germany
+49 89 1271 1470
Roland Denk: info@astraia.com
www.astraia.com

astraia software gmbh provides a software solution in obstetrics and gynaecology for structured documentation and reporting, for quality assurance as well as for scientific studies. The company was founded in 2000 and it is based in Munich, Germany. A dedicated team of about 30 employees serves more than 1,500 customers in over 75 countries. In many countries, astraia is also represented by local sales partners. astraia cooperates closely with leading experts around the world.

CAE Healthcare

Booth: 14

50 Robert-Koch-Strasse, Mainz, 55219, Germany
+49 175 94140 39
Karla Kleist: karla.kleist@cae.com
www.caehealthcare.com

CAE Healthcare is a healthcare training partner of choice for hospitals, physicians, nurses, students, EMS responders and the military around the world. With a mission to improve patient safety, CAE Healthcare develops each product in partnership with clinical educators whose aim is to ensure physiological accuracy and educational relevance. Visit the CAE Healthcare booth to learn about our newest patient, imaging and interventional simulators and our audiovisual solutions for center management and debrief.

Clarius Mobile Health

Booth: 25

GF9 Systems House, The Alba Campus,
Rosebank, Livingston, EH54 7EG, UK
+44 (0)203 865 4695 or +1 778 800 9975
sales@clarius.me
www.clarius.me



Clarius is the only Handheld Wireless Ultrasound Scanner that doesn't compromise on image quality. It produces high resolution ultrasound images and transmits them to most iOS or Android smart devices. With automated gain and frequency settings, Clarius is almost as easy to use as the camera on your smart phone. Clarius L7 linear array ultrasound scanners are ideal for guiding procedures. Starting price for a basic Clarius Scanner in the United States is \$6900.

ContextVision AB

Booth: 35

Klara Norra Kyrkogatan 31, Stockholm, 111 22, Sweden
+46 700019355
Markus Norén: Markus.noren@contextvision.se
www.contextvision.com

ContextVision is a medical technology company specializing in image analysis and artificial intelligence. Its technology helps clinicians accurately interpret medical images, a crucial foundation for better diagnosis and treatment. An industry pioneer for more than 30 years, ContextVision is taking a lead position within deep learning, the latest artificial intelligence technology. The present product portfolio includes state-of-the-art image enhancement software for 2D/3D/4D ultrasound, MRI, x-ray and mammography which is used by leading equipment manufacturers worldwide.

GE Healthcare

Booth: 4

Hitachi Medical Systems Europe

Booth: 9



GE Healthcare

Tiefenbach 15, Zipf 4871, Austria
 +43 7682 38000
 Heleen van Weel: heleen.vanweel@ge.com
www.voluson.com

GE Healthcare provides transformational medical technologies and services to meet the demand for increased access, enhanced quality and more affordable healthcare around the world. GE (NYSE:GE) works on things that matter – great people and technologies taking on tough challenges. From medical imaging, software and IT, patient monitoring and diagnostics to drug discovery, biopharmaceutical manufacturing technologies and performance improvement solutions, GE Healthcare helps medical professionals deliver great healthcare to their patients.

HITACHI
 Inspire the Next

Sumpfstrasse 13, CH - 6300 Zug, Switzerland
 +41 41 748 63 33
 Romea Wallnoefer: marcom@hitachi-medical-systems.com
www.hitachi-medical-systems.com

Hitachi Medical Systems Europe is the European headquarters of Hitachi Healthcare Business Unit, which is part of the global Hitachi Ltd., Japan. We support accurate diagnosis throughout pregnancy by a sophisticated range of advanced functions. We provide reassurance to parents by 3D/4D ultrasound, STIC, high-resolution B-mode, eFLOW, specialized tools for examining the early pregnancy, fetal heart and the innovative real-time Image Fusion (RVS) for multimodality imaging. Various transducers facilitate treatment of infertility, gynecological diseases and applications for therapy assistance.

HITACHI
 Inspire the Next

IMAGINE WHAT COMES NEXT IN OB/GYN

JOIN US AS WE **UNVEIL** OUR NEW
PREMIUM ARIETTA FAMILY MEMBER
 SATURDAY, SEPT 16TH, 15.00 AT BOOTH 9

AND JOIN OUR **EDUCATIONAL PROGRAMME**
 SUNDAY, SEPT 17TH AND MONDAY, SEPT 18TH, 12.00 TO 13.30, ROOM L8, 1ST FLOOR
 AS WELL AS OUR **LIVE SCANNING SESSION**
 MONDAY, SEPT 18TH, 15.40 TO 15.55, AUDITORIUM, HALL A

International Society for Prenatal Diagnosis (ISPD)

Booth: 31

ISUOG

ISUOG Lounge

Suite 201, 154 en Road, VA, Charlottesville, 22911, USA
+1 434 979 4773
info@ispdhome.org
www.ispd.org

The International Society for Prenatal Diagnosis (ISPD) brings together a global multidisciplinary group of medical and scientific professionals with interests and expertise in a diverse array of clinical and research aspects of prenatal diagnosis and fetal care. We focus on all relevant topics in this field, with a unique emphasis on reproductive and prenatal genetic screening and testing and their integration with other disciplines of prenatal diagnosis.

ExEm Foam

Booth: 15

Delftechpark 26, 2628 XH Delft, The Netherlands
+31 653140968
Eric Reep: Reep@iq-medicalventures.com
www.iq-medicalventures.com

IQ Medical Ventures is a medical device revolving Incubator Company. We develop bright ideas from physicians into simple, affordable and safe products for the daily practice. Medical Ventures currently markets two products in the field of gynecological ultrasound imaging (hysterosalpingo foam sonography and gel instillation sonohysterography). The basis for these two products is ExEm® gel, of which ExEm foam Kit is the product we present at ISUOG 2017.



122 Freston Road, London, W10 6TR, UK
+44 (0)20 7471 9955
Cora Siebert: info@isuog.org
www.isuog.org

ISUOG is a charity and membership association encouraging exceptional research and education in ultrasound and related imaging within the field of obstetrics and gynecology. ISUOG has been in existence since 1991 and, with over 13,000 members in 127 countries, it is the leading international society representing professionals in ultrasound for obstetrics and gynecology. All fully paid delegates are now enrolled as members of ISUOG for 2018 and can immediately access many member benefits including On Demand (platform to view recordings and lectures from our World Congresses) and over 500 web lectures. Visit the ISUOG Lounge to find out more about membership and browse your benefits.



Karl Storz GmbH & Co. KG**Booth: 20**

Mittelstrasse 8, Tuttlingen, 78532, Germany
 +49 7461 708 0
 info@karlstorz.com
www.karlstorz.com

KARL STORZ is a renowned manufacturer that is well established in all fields of endoscopy. The still family held company has grown to one with a worldwide presence and 7100 employees. KARL STORZ offers a range of both rigid and flexible endoscopes for a broad variety of applications.

**Malopolskie Warsztaty
Ultrasonografii SP. Z o.o.****Booth: 27**

Ul. Felinskiego 20A, 31-236, Malopolska, Poland
 +48 730 740 402
 Piotr Latala: info@malopolskieusg.pl
www.ultrasoundcracow.com

Lesser Poland Workshops in Ultrasound is a unique educational project aimed at medical professionals interested in developing ultrasound skills in terms of theory and practice. We guarantee that our vision for education in ultrasound is unique and we ensure that it is worthwhile to compare it with other experiences. During our courses we use innovative teaching tools like 3D models of Fetal Heart.

MedaPhor Ltd**Booth: 26**

Cardiff Medcentre, Heath Park, Cardiff, CF14 4UJ, UK
 +44 (0)2920 756534
 sales@medaphor.com
www.medaphor.com

ScanTrainer is recognized globally as a leading simulation system for education in transvaginal and transabdominal ultrasound. Developed by leading clinicians at the University Hospital of Wales, it is considered to be the most effective, self-directed simulation solution for realistic training in ultrasound. MedaPhor is proud to work closely with healthcare educators from around the world to develop market-leading educational simulators that will help better prepare and support clinicians in the care of their patients.

MIDES GMBH**Booth: 36**

Weinholdstrasse 33, 8010 Graz, Austria
 +43 31642650010
 Lucijana Manovic: lucijana.manovic@mides.com
www.mides.com

MIDES Healthcare technology - specialist in ultrasound as imaging representation. Sales in 54 countries worldwide
 Ultrasound - probe repairs Certified company (ISO 9001 and ISO13485) the European market leader in the ultrasound probe repair. Service and repair of default -, 3D / 4D probes - and TEE probes. New: Ultrasound - Endoscopy - Repair Leading international supplier of ultrasound devices (New / Demo / Refurbished) and spare parts to B2B and retail.

Mindray Medical**Booth: 8**

Mindray Building, Keji 12th Road South, High-tech Industrial Park, Nanshan, Shenzhen 518057, P.R. China
 +86 755 8188 7663
 Ellen Mok: ellen.hmmo@mindray.com
www.mindray.com/en

Mindray, as one of the leading global providers of medical devices and solutions, dedicates to making better healthcare more accessible to humanity. With over decades of experience, Mindray has worked out a wide range of ultrasound imaging solutions including cart-based and portable systems. With a sound global R&D, the ultrasound solution by Mindray is evolving with the cutting-edge technologies to improve diagnosis confidence and efficiency.

Parker Laboratories**Booth: 34**

Bedrijvenpark Twente 305, Almelo, 7602 KL, The Netherlands
 +31 546 549 107
 Dennis Wessels: europe@parkerlabs.com
www.parkerlabs.com

Parker Laboratories is a leading global medical products company that develops, manufactures and sells ultrasound and electromedical contact media, as well as leading lines of institutional cleaners and disinfectants.

Parsagen

Booth: 7

Louise Dumont Strasse 25, Dusseldorf, 40211, Germany
+49 211 54224949
Derya Bercin: derya.bercin@partosure.com
www.partosure.de

Parsagen Diagnostics, Inc. is the manufacturer of PartoSure™, a novel bedside test to aid in the assessment of preterm delivery in patients with symptoms of preterm labour. Based on the detection of PAMG-1, PartoSure has been shown in published studies to have a higher positive predictive value compared to current methods, while maintaining an equally high negative predictive value. The PartoSure test is CE marked and is currently investigational use only in the United States.

PerkinElmer

Booth: 22

Mustionkatu 6, 20750 Turku, Finland
+358 40 771 1683
Tarja Ahola: tarja.ahola@perkinelmer.com
www.perkinelmer.com/MaternalFetalHealth

PerkinElmer is a global company focused on improving the health and safety of people and their environment. Within the field of fetal and maternal healthcare, PerkinElmer offers complete screening solutions including instrumentation, reagents and risk calculation software for early detection of pregnancy related anomalies.

Maternal fetal products availability and claims may differ from country to country based on regulations and product approvals. Please check availability with your local distributor.

Philips

Booth: 2

PHILIPS

Veenpluis 6, Best, PO Box 80019, Eindhoven,
The Netherlands
+31 6466 37805
Dolores Cantelli: dolores.cantelli@philips.com
www.philips.com

At Philips, we look beyond technology to the experiences of patients, providers and caregivers across the health continuum from healthy living to prevention, diagnosis, treatment, and home care. We unlock insights leading to innovative solutions that help deliver better care at lower costs. It's a unique perspective empowering us all to create a healthier future.

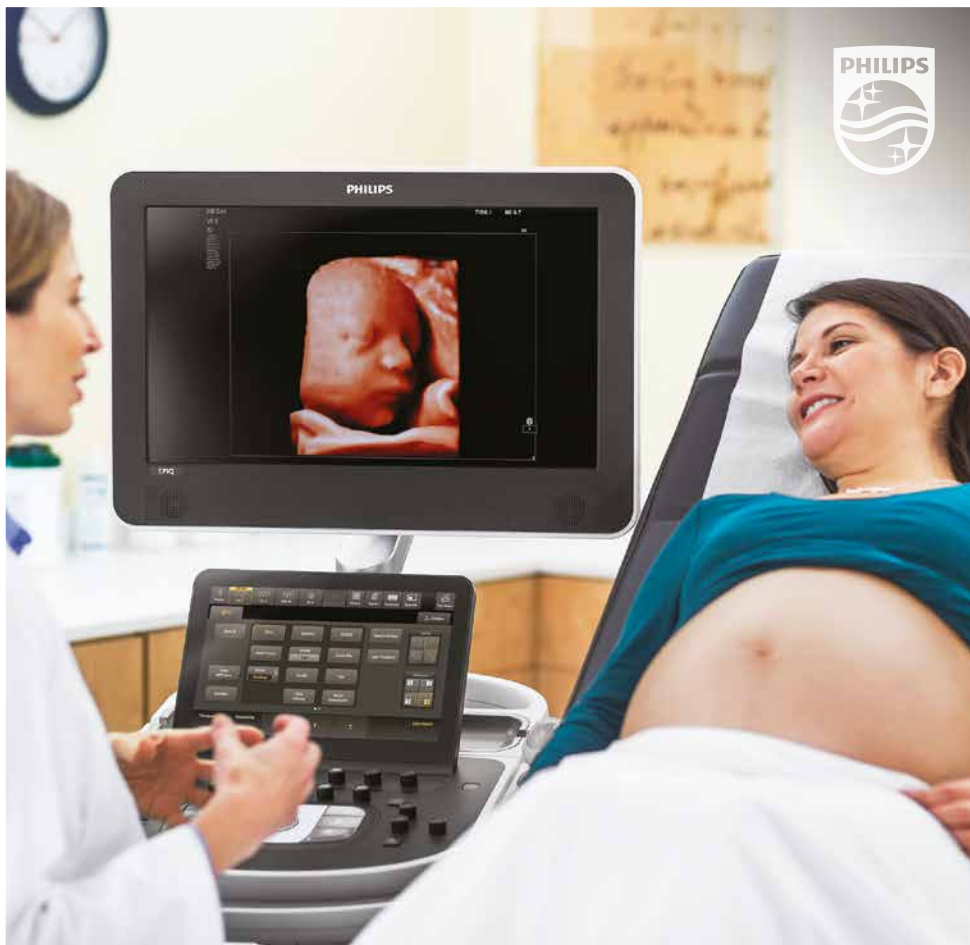Roche Sequencing Solutions

Booth: 19

5945 Optical Court, San Jose CA 95138, USA
+1 408 887 0703
Marissa Pelagio: marissa.pelagio@roche.com
www.harmonytest.com

Headquartered in Pleasanton, California, the Roche Sequencing Unit is focused on developing novel sequencing technologies and products to support innovation in clinical research applications. Our goal is to develop assays for sequencing, and refine sequencing techniques to advance sequencing technologies that will deliver truly differentiated clinical value.





TrueVue with TouchVue

Photorealistic 3D fetal imaging

Provides photorealistic 3D fetal imaging at your fingertips. With the EPIQ and Affiniti, TrueVue adds a new interactive interface called TouchVue. The TouchVue interface utilizes the touch panel to allow fingertip control of both volume rotation and position of the internal light source directly on the TrueVue 3D image.

innovation  you

See more at
www.philips.com/isuog

PHILIPS

SAMSUNG

FAMILY PLANNING

GYNECOLOGY & BREAST HEALTH

HEALTHY PREGNANCY BIOMETRY

Focusing on women's health

HEALTHY BIRTH

HEALTHY PREGNANCY DIAGNOSIS

HEALTHY PREGNANCY VISUALIZATION

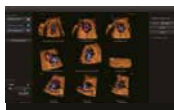

Samsung's Commitment to Life-long Healthcare for Women

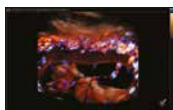CRYSTAL CLEAR CYCLE™ provides ultrasound diagnostics for women's health by life stage, from family planning to healthy birth, and gynecological and breast health.

Please visit the SAMSUNG booth for more information!

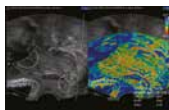
5D Heart Color™



Crystal Vue Flow™



E-Cervix™



IOTA-ADNEX



Visit <http://www.samsunghealthcare.com> to learn more

Samsung**SAMSUNG**

42, Teheran-ro, 108-gil, Gangnam-gu, Seoul,
Republic of Korea, 135-280
+82 2 2194 1131
Pia Park: hm11.park@samsungmedison.com
www.samsunghealthcare.com

Samsung Healthcare : Combining leading technology to improve the quality of people's lives.

Samsung is committed to create a new future for medical professionals and patients with a mission to bring health and well-being to people's lives. Integrating its leading expertise in display, IT, mobile and electronics, our vision is to bring confident diagnosis, cost- effective solutions and improved workflow to customers.

Shenzhen Talecare Technologies**Booth:21**

5th Floor, Building 712 West, Shenzhen, China
+86 755 2399 1200
Anson He: Anson.he@talecare.com
www.talecare.com

Shenzhen Talecare Technologies has researched and developed some total solutions for certain departments in hospitals, for instance,"Ultrasound Total Solutions", "Total Solutions for Obstetrics and Gynecology", and "Total Solutions for Endoscopy Lab" to show our advanced technology and products that have disseminated our service concept of "Health through Care" around the world.

Booth: 5**Society for Maternal-Fetal Medicine Booth: 33**

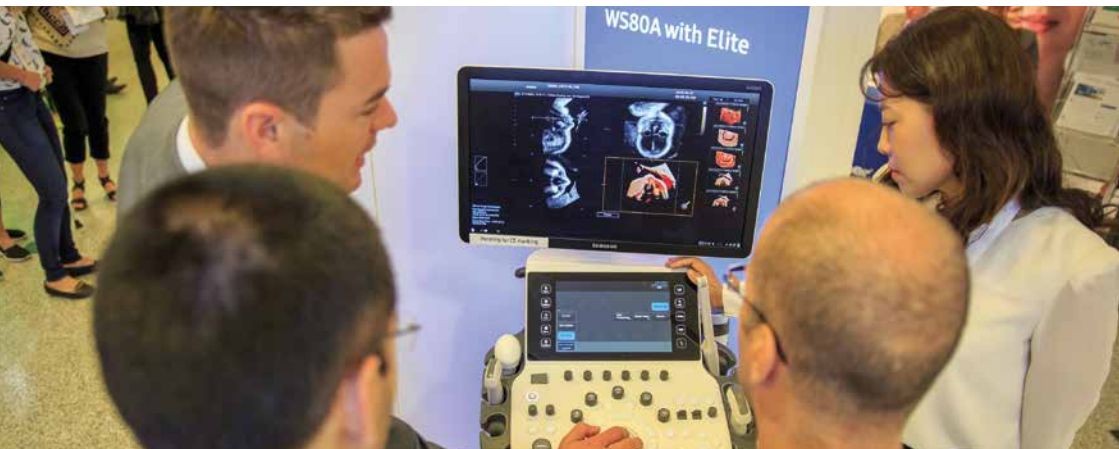409 12th Street, SW, Suite 601, Washington,
DC 20024, USA
+1 202 517 6353
Tim Heinle: theinle@smfm.org
www.smfm.org

The Society for Maternal-Fetal Medicine (SMFM) was established in 1977 to give MFM physicians and scientists a place to share knowledge, research and clinical best practices in order to improve care for pregnant women and babies. We are the high-risk pregnancy experts specializing in the un-routine. To learn more about the Society and the benefits of membership visit www.smfm.org/join.

SonoSim Inc.**Booth:37**

1738 Berkeley St., Santa Monica, 90404, USA
+1 323 473 3800
Lisa lvey: lisa@sonosim.com
www.sonosim.com

SonoSim, Inc. is dedicated to improving and transforming medical care by serving as a global leader in ultrasound education and training. With its staff of leading ultrasound educators, instructional designers, content editors, scientists, and software developers, SonoSim has created the easiest way to learn ultrasonography in over 35 countries globally, The SonoSim® Ultrasound Training Solution.



Toshiba Medical Systems

Booth: 6

**TOSHIBA
MEDICAL**

Canon
CANON GROUP

Yokoso Rainbow Tower 10F, 3-20-20 Kaigan,
Minatoku, Tokyo, Japan
+81 3636 99 673

Jeroen Uijttenhout: Jeroen1.ujttenhout@toshiba.co.jp
www.toshibamedicalsystems.com

Toshiba Medical offers a full range of diagnostic imaging systems. As of December 2016, Toshiba Medical became a member of the Canon Group. In line with our continued Made for Life philosophy, patients are at the heart of everything we do. Our mission is to provide medical professionals with solutions that support their efforts in contributing to the health and wellbeing of patients worldwide so that together our industry-leading solutions deliver an enriched quality of life.

Trice Imaging

Booth: 16

1334 Stratford Court, Del Mar, CA 92014, USA
+49 175 2234 710

Bernd Nuber: info@triceimaging.com
www.triceimaging.com

Trice Imaging offers a web based service called Tricefy™ that enables health care providers to securely store, convert, distribute, and access DICOM medical images and reports anywhere, anytime on any device – in seconds. Images can be shared anonymously with patients and in their original DICOM format with medical professionals, either directly from the modality or from their Tricefy™ account.

Tristel

Booth: 11

Lynx Business Park, Fordham Road,
Snailwell, Cambridgeshire, UK
+44 (0)1638 72 1500
mail@tristel.com
www.tristel.com

Tristel is a manufacturer of of Infection Prevention and contaminating control products. Its lead technology is a chlorine dioxide formulation, which has been a ground breaking innovation in the world of infection control. Visit our stand to find out about Tristel products particularly suitable for Ultrasound.

Versandbuchhandlung Stefan Schuldt Booth: 38

Dorfstrasse 17L, Flintbek, Germany
+49 4347 74706

Stefan Schuldt: info@versandbuchhandlung-schuldt.de

WATOG

Booth: 24

35 Rue Berger, Paris, France
+33 661 143 924

Olivier Ami: executive@watog.org
www.watog.org

The World Association of Trainees in Obstetrics & Gynecology (WATOG) is a non-profit organization that represents the first worldwide network of young obstetricians and gynecologists. It was founded in 2012 under the auspices of the FIGO. WATOG wishes to promote the foundation and sustainment of OB/GYN trainee associations on national and regional level, to improve education and training, and to potentiate trainees' involvement in global women's health issues.

Wisepress Medical Bookshop

Booth: 28

15 Lyon Road, London, SW19 2RL UK
+44 (0)20 8715 1812
marketing@wisepress.com
www.wisepress.com

Wisepress.com, Europe's leading conference bookseller, attend around 200 conferences every year.

We have an extensive range of books and journals relevant to the themes of this conference available at our booth. We also have a comprehensive range of STM titles available on our online bookshop. Follow us on Twitter @WisepressBooks

**Together,
we help you see more.**

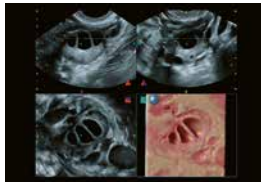
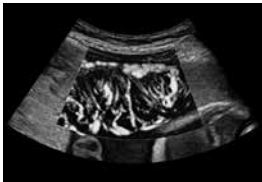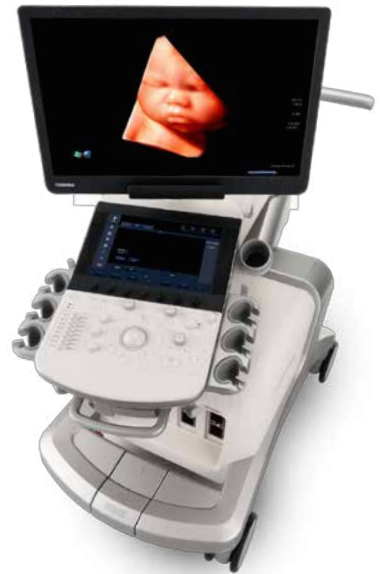Made For life



Delivering superior image quality lies at the heart of everything we do, because we believe that only the best images can give you the confidence to make the most critical decisions during early stage pregnancy and beyond.

From our unique SMI technology that reveals minute microvascular flow never seen before with ultrasound, to advanced 4D applications that add true clinical value to your diagnosis, we equip you with the best tools to help you see more.

Visit our educational sessions at ISUOG 2017 and learn about how our Women's Health solutions can support you in providing the best care for your patients.



Hospitality and education suites

CRYSTAL LOUNGE

Saturday - Tuesday

GE Voluson Club



HALL N

Saturday

13:00-13:45

Secret of the masters I

Sunday

12:45-13:30

Secret of the masters II

Please visit GE Healthcare at Stand 4 for more details

ROOM 0.11-12

Saturday - Tuesday

Samsung lounge

SAMSUNG

ROOM 0.96-98

Saturday

10:30-11:00

Automated fetal weight estimation *L. Mack*

15:00-15:30

Premature Birth (Cervical Elastography)

Sunday

09:50-10:20

The clinical value of Crystal Vue™ in the second trimester *C. Lees (UK)*

Monday

Imaging the first trimester fetus: a novel perspective *H. Shah (UK)*

Tuesday

The ADNEX risk prediction model *M. Al-Memar (UK)*

13:00-13:30

The ADNEX risk prediction model *M. Al-Memar (UK)*

15:10-15:40

“Virtual” cardiac volume acquisition training *L. Yeo (USA)*

ROOM 0.95

Saturday

12:45-13:15

New Insights to right arch, double arch and vascular rings *J. Carvalho (UK)*

15:05-15:30

The use of anatomical landmarks for CNS examination *L. Guibaud (France)*

TOSHIBA MEDICAL

Canon CANON GROUP

Sunday

09:50-10:20

Pre-eclampsia screening in the first trimester *J. Hyett (Australia)*

Monday

CNS anatomy in the first trimester *E. Krampfl-Bettelheim (Austria)*

Tuesday

Ultrasound of the reproductive cycle and early pregnancy assessment *B. Smith (UK)*

12:45-13:15

First trimester structural abnormalities *J. Cruz (Portugal)*

A new practical approach to the assessment of cardiac function *M. Geijtenbeek (Netherlands)*

15:10-15:40

Gynecological quiz: improve your skills for a correct ultrasound diagnosis *F. Moro (Italy)*

CNS pathology: Quiz for experts and advanced learners *L. Guibaud (France)*

ROOM 0.14

PHILIPS

Sunday

12:00:13:30 Quiz, clips and tricks in prenatal diagnosis
M. Hoopman

12:00:13:00 **Monday**
Fetal Echo using advanced techniques
R. Axt-Fliedner

Tuesday

Screening for and prevention of Fetal head-, face- and brain-defects at 11-13 weeks

Screening and prevention of Iatrogenic and Non-Iatrogenic premature birth at 11-13 weeks
R. Lachmann

ROOM L8

HITACHI
Inspire the Next**Sunday**

12:00-13:30 ARIETTA 850 Live Scanning 'Fetal Brain and Heart with new advanced Hitachi techniques'
G. Rizzo, Italy

Sharing Experience with Fusion Imaging in cervical cancer: a new multimodality imaging method *J.M. Levaillant*

Q&A

Sandwich Lunch for attendees

Monday

Fetal Cardiology Workshop

Back to Basics: ISUOG Cardiac Guidelines
J. Carvalho

Going beyond the basics: how to do it – additional structures and ultrasound views and other modalities *J. Carvalho*

Q&A

Light Lunch

ROOM 0.91



ExEm® Foam
Sunday

11:00 HyFoSy Workshops: How to easily test tubal patency with ExEm Foam Gel - presentation and hands on training using UltraSound *Dr Helmy*

12:30
14:00 Hands on session with use of TVUS ultrasound, ExEm Foam and hysterosalpingo phantom, will start after each workshop.

ROOM 0.80

Trice

Monday

Experience the future of connected ultrasound
Tricefy archiving, sharing and collaboration
Tricefy for clinical study management
Tricefy data security and compliance

Please visit Trice imaging at stand 16 for more details

Satellite symposia - HALL F

Saturday

12:30-13:30

Philips ultrasound: Delivering superior technology to the clinician and patient

PHILIPS

"The fetal profile in the first trimester - diagnostic potential beyond nuchal translucency"

M. Hoopman

"Precision made simple: The way to early advanced morphological scans" *G. Gorincour*

Hypoplastic left heart and variants: Prenatal diagnosis and outcomes *R. Axt Fliedner*

Advances in Fetal Imaging: Automation and Enhanced 3D Obstetric Ultrasound *M. Ruma*

Sunday

12:15-12:35

Fetal and Maternal Heart Abnormality Screening

SAMSUNG

Fetal Intelligent Navigation Echocardiography (FINE): complexity made simple

12:35-12:55

FINE/5D Heart™: novel features with value in clinical practice *L. Yeo (United States)*

12:55-13:15

Maternal heart screening *B. Thilaganathan (United Kingdom)*

Monday

12:15-13:15

Please see GE at stand 4 for more details



GE Healthcare

A. Abuhamad

B. Beniot

D. Jurkovic

Monday

17:15-17:35

Ancillary Solution in Predicting Preterm Delivery

SAMSUNG

Cervical elastography in OB: what, why, and how *J.Y. Kwon (Republic of Korea)*

17:35-17:55

E-cervix™: Results from multicenter study by Korean Society of Ultrasound in Obstetrics and Gynecology Research Group *S.Y. Oh (Republic of Korea)*

17:55-18:15

Predicting premature birth in high risk population *P. Bennett (United Kingdom)*

Tuesday

12:15-13:15

Chair: Caterina Bilardo

**TOSHIBA
MEDICAL**

Canon
CANON GROUP

Novel tools for the evaluation of the fetus & placenta in early gestation

A. Abuhamad (United States)

Tips and tricks in screening for fetal heart defects: a problem based approach

M. Haak (The Netherlands)

New approaches in gynecological oncology: the use of ultrasound to guide invasive procedures

A. Testa (Italy)

Industry acknowledgements

ISUOG gratefully acknowledges the following industry support for Basic Training:

Friday 08:30-16:45 Fetal anatomy: normal or abnormal? L2
The Basic Training approach



ISUOG gratefully acknowledges the following industry support for our hands-on workshops:



HITACHI
Inspire the Next

SAMSUNG

PHILIPS

Trice

Saturday 08:30-16:45 CFEF Workshops - hands-on training 0.79-0.84

ISUOG gratefully acknowledges the following industry support for our simulation workshops:



3D SYSTEMS



Saturday 08:30-13:30 Basic Training simulation workshops L7

Live scan ultrasound gel kindly sponsored by:



ISUOG gratefully acknowledges the following industry support for our live scan sessions.*

Sunday 08:15 Updates: optimal evaluation of fetal growth and size Hall A

Sunday 13:30 FINE: novel features with value in clinical practice Hall A

SAMSUNG

Sunday 10:20 How I perform a mid-trimester scan Hall A

Monday 10:20 How I look at the fetal brain Hall A

Tuesday 13:50 How I optimise detection of anomalies at 12 weeks Hall A

**TOSHIBA
MEDICAL**

Canon
CANON GROUP

Saturday 14:45 How to scan deep infiltrating endometriosis - the surgeon and sonographer view Hall A

Monday 14:10 Optimising imaging in the overweight patient Hall A

PHILIPS

Monday 15:40 Effective screening for outflow tract abnormalities: tips and tricks Hall A

HITACHI
Inspire the Next

* Scientific content of sessions is defined by the Scientific Committee; ultrasound systems and technical support are provided by sponsors

ISUOG Board and Committee meetings

Date	Start	End	Meeting	Room
Thursday	12:00	13:30	Executive Committee & Finance Committee	Suite E, 0.61
	14:00	17:00	Bids Committee	Suite E, 0.63
Friday	08:30	17:30	ISUOG Board meeting (1)	Hall M
Saturday	07:30	08:30	Chairpersons briefing	Hall B
	09:50	10:35	AGM and Awards	Hall A
	12:30	13:30	Scientific Committee (1)	Suite E, 0.63
	12:15	13:45	Advisory Members lunch	L2
	14:00	16:00	Journal Editors meeting	Hall M
	14:00	14:45	Patient Information SIG	Suite E, 0.61
Sunday	09:20	10:20	ISUOG-FIGO Collaboration	Suite E, 0.61
	10:20	11:20	Clinical Standards Committee	Suite E, 0.63
	10:45	11:45	Nominations Committee	Suite E, 0.61
	12:00	13:30	Editorial Board meeting	Hall M
	13:00	14:30	IOTA meeting	L2
	13:30	14:30	WATOG-ISUOG meeting	Suite E, 0.61
	14:30	15:30	CME Task Force	Suite E, 0.63
	14:35	15:35	Gold Medal Awards Committee	Hall M
	15:10	15:40	Singapore Local Organising Committee	Suite E, 0.61
16:40	18:10	Online Education Content Task Force	Suite E, 0.61	
Monday	08:00	09:30	Basic Training Task Force	Suite E, 0.63
	08:15	09:15	Safety Committee	Suite E, 0.61
	09:50	10:50	Courses Task Force	Suite E, 0.61
	11:25	12:55	IETA meeting	Hall M
	12:15	13:30	Young Investigators lunch	L2
	13:30	14:30	VISUOG Task Force	Suite E, 0.61
	14:35	15:55	Outreach Committee	Suite E, 0.63
	16:00	17:30	Education Committee	Hall M
	17:00	18:00	IDEA meeting	L2
Tuesday	08:15	10:15	ISUOG Board meeting (2)	Hall M
	11:00	12:00	Exhibitors' Closing meeting	Suite E, 0.61
	12:15	13:15	Ambassadors lunch	L2
	12:30	14:00	Scientific Committee meeting (2)	Suite E, 0.63



28th World Congress on Ultrasound in Obstetrics and Gynecology

20 – 24 October 2018, Singapore

Incorporating ASUM 2018

Join us in Singapore at the leading event
in obstetric and gynecological ultrasound.

Critical dates 2018

January	Registration opens*
9 April	Abstract submission and presenter registration deadline
20 August	Early bird registration deadline
20 October	Pre-Congress courses and Basic Training
21 October	Congress opens

Travel grants available: isuog.org/worldcongress/2018/travelgrant

For full details visit isuog.org/worldcongress/2018
congress@isuog.org | +44 (0)20 7471 9955

* Discounts apply to ISUOG and ASUM members, trainees and sonographers and endorsing partner organisations members.

Organised by the International Society of Ultrasound in Obstetrics and Gynecology.



#ISUOG2018



ISUOG would like to thank the following industry partners for their support of the 27th World Congress:

Diamond



SAMSUNG

**TOSHIBA
MEDICAL**

Canon
CANON GROUP

Platinum

PHILIPS

Gold

HITACHI
Inspire the Next

Bronze



ISUOG

122 Freston Road, London W10 6TR, UK
+44 (0)20 7471 9955 | congress@isuog.org

