

ISUOG Practice Guidelines: role of ultrasound in twin pregnancy

Clinical Standards Committee

The International Society of Ultrasound in Obstetrics and Gynecology (ISUOG) is a scientific organization that encourages sound clinical practice, and high-quality teaching and research related to diagnostic imaging in women's healthcare. The ISUOG Clinical Standards Committee (CSC) has a remit to develop Practice Guidelines and Consensus Statements as educational recommendations that provide healthcare practitioners with a consensus-based approach, from experts, for diagnostic imaging. They are intended to reflect what is considered by ISUOG to be the best practice at the time at which they are issued. Although ISUOG has made every effort to ensure that Guidelines are accurate when issued, neither the Society nor any of its employees or members accepts any liability for the consequences of any inaccurate or misleading data, opinions or statements issued by the CSC. The ISUOG CSC documents are not intended to establish a legal standard of care because interpretation of the evidence that underpins the Guidelines may be influenced by individual circumstances, local protocol and available resources. Approved Guidelines can be distributed freely with the permission of ISUOG (info@isuog.org).

INTRODUCTION

The incidence of multiple pregnancy is rising, mainly due to delayed childbirth and advanced maternal age at conception and the resultant widespread use of assisted reproduction techniques¹. The twin birth rate increased by just under 70% between 1980 (19 per 1000 live births) and 2006 (32 per 1000 live births)².

Twin pregnancy is associated with a high risk of perinatal mortality and morbidity^{3–6}. In 2009, the associated stillbirth rate was 12 per 1000 twin births and 31 per 1000 triplet and higher-order multiple births, compared with five per 1000 singleton births^{7,8}. Preterm birth prior to 37 weeks' gestation occurs in up to 60% of multiple pregnancies, contributing to the increased risk of neonatal mortality (65% of neonatal deaths among multiple births are preterm, compared with 43% of neonatal deaths in singletons) and long-term morbidity^{9–12}. Of course, such complications rise with a reduction in gestational age

at birth. In addition, compared with singletons, twins are at increased risk of iatrogenic preterm delivery due to the greater incidence of maternal and fetal complications. The risk is significantly higher in monochorionic pregnancy compared with dichorionic pregnancy^{3–6}.

Ultrasound assessment of fetal biometry, anatomy, Doppler velocimetry and amniotic fluid volume is used to identify and monitor twin pregnancies at risk of adverse outcomes such as twin-to-twin transfusion syndrome (TTTS) and fetal growth restriction (FGR). As in singletons, impaired fetal growth can be assessed in twins by comparing biometry and Doppler velocimetry parameters against standards for uncomplicated pregnancy.

This guidance will address the role of ultrasound in the care of uncomplicated twin pregnancy and those complicated by TTTS, selective FGR (sFGR), twin anemia–polycythemia sequence (TAPS), twin reversed arterial perfusion (TRAP) sequence, conjoined twins and single intrauterine death (IUD). The document provides guidance on the methods used to determine gestational age and chorionicity, screening for chromosomal and structural abnormalities, and screening for TTTS, TAPS, growth abnormalities and preterm birth. The management of higher-order multiple pregnancy will be covered in a separate document.

OUTLINE/SCOPE

- Dating of the pregnancy (determining gestational age)
- Determining chorionicity and amnionicity
- Twin labeling
- Timing, frequency and content of ultrasound assessment
- Screening for aneuploidy
- Prenatal diagnosis of aneuploidy
- Screening for structural abnormalities
- Diagnosis and management of discordant twin pregnancy
- Fetal reduction/selective termination
- Screening for preterm birth
- Screening, diagnosis and management of FGR
- Management of multiple pregnancy complicated by single IUD

- Complications unique to monochorionic twin pregnancy
 - Screening, diagnosis and management of TTTS
 - Screening, diagnosis and management of TAPS
 - Management of TRAP sequence
 - Management of monochorionic monoamniotic (MCMA) twin pregnancy
 - Diagnosis and management of conjoined twins

IDENTIFICATION AND ASSESSMENT OF EVIDENCE

The Cochrane Library and Cochrane Register of Controlled Trials were searched for relevant randomized controlled trials, systematic reviews and meta-analyses and a search of MEDLINE from 1966 to 2014 was carried out. The date of the last search was 15 November 2014. In addition, relevant conference proceedings and abstracts were searched. Databases were searched using the relevant MeSH terms including all sub-headings. This was combined with a keyword search using 'twin', 'multiple', 'pregnancy', 'ultrasound', 'twin-to-twin transfusion syndrome', 'fetal growth restriction', 'twin anemia polycythemia sequence', 'twin reversed arterial perfusion', 'acardiac twin', 'monochorionic monoamniotic', 'conjoined', 'demise'. The National Library for Health and the National Guidelines Clearing House were also searched for relevant guidelines and reviews. Gray (unpublished) literature was identified through searching the websites of health technology assessment and health technology assessment-related agencies, clinical practice guideline collections and clinical trial registries. The search was limited to the English language. When possible, recommendations are based on, and explicitly linked to, the evidence that supports them, while areas lacking evidence are annotated as 'good practice points'. Details of the grades of recommendations and levels of evidence used in these Guidelines are given in Appendix 1.

RECOMMENDATIONS

Dating of twin pregnancy

- Twin pregnancies should ideally be dated when the crown-rump length (CRL) measurement is between 45 and 84 mm (i.e. 11 + 0 to 13 + 6 weeks of gestation) (GRADE OF RECOMMENDATION: D).
- In pregnancies conceived spontaneously, the larger of the two CRLs should be used to estimate gestational age (GRADE OF RECOMMENDATION: C).

Other studies have recommended the use of the smaller CRL or the mean CRL, which takes into account both fetuses^{13–15}. The disadvantage of using the smaller CRL is the potential of the operator believing that the larger twin is large-for-gestational age, and therefore being falsely reassured that the smaller twin is still growing appropriately. The most common practice is to use the

larger CRL. If the woman presents after 14 weeks' gestation, the larger head circumference should be used¹. Twin pregnancies conceived via *in-vitro* fertilization should be dated using the oocyte retrieval date or the embryonic age from fertilization (EVIDENCE LEVEL: 2+).

Determining chorionicity/amnionicity in twin pregnancy

- Chorionicity should be determined before 13 + 6 weeks of gestation using the membrane thickness at the site of insertion of the amniotic membrane into the placenta, identifying the T sign or lambda sign, and the number of placental masses. An ultrasound image demonstrating the chorionicity should be kept in the records for future reference (GRADE OF RECOMMENDATION: D).
- If it is not possible to determine chorionicity by transabdominal or transvaginal ultrasound in the routine setting, a second opinion should be sought from a tertiary referral center (GOOD PRACTICE POINT).
- At the time at which chorionicity is determined, amnionicity should also be determined and documented. MCMA twin pregnancies should be referred to a tertiary center with expertise in their management (GOOD PRACTICE POINT).

Every attempt should be made to determine the chorionicity of a twin pregnancy. Chorionicity should be determined between 11 + 0 and 13 + 6 weeks of gestation using the membrane thickness at the site of insertion of the amniotic membrane into the placenta, identifying the T-sign or lambda sign (Figure 1), and the number of placental masses visualized using ultrasound¹. It is important to examine the dividing membrane carefully; in dichorionic diamniotic twin pregnancy, the twins are separated by a thick layer of fused chorionic membranes with two thin amniotic layers, one on each side, giving the appearance of a 'full lambda', compared with only two thin amniotic layers separating the two fetuses in monochorionic diamniotic (MCDA) twin pregnancy (the T-sign). In women presenting for the first time after 14 weeks of gestation, chorionicity is best determined using the same ultrasound signs, in particular by counting the membrane layers, and noting discordant fetal sex. The reliability of the number of placental masses is questionable, as dichorionic placentae are commonly adjacent to each other, appearing as a single mass, and 3% of monochorionic twin pregnancies have two placental masses on ultrasound, the presence of which does not preclude the presence of vascular anastomoses¹⁶. It is likely that using a combination of ultrasound features, rather than a single one, would be more accurate¹.

If it is not possible to determine chorionicity by transabdominal ultrasound imaging, this should be attempted using transvaginal sonography. If it is still not possible to determine chorionicity, a second opinion should be sought from a tertiary referral center. If the center is uncertain about the chorionicity, it is safer to classify the pregnancy as monochorionic¹ (EVIDENCE LEVEL: 3).

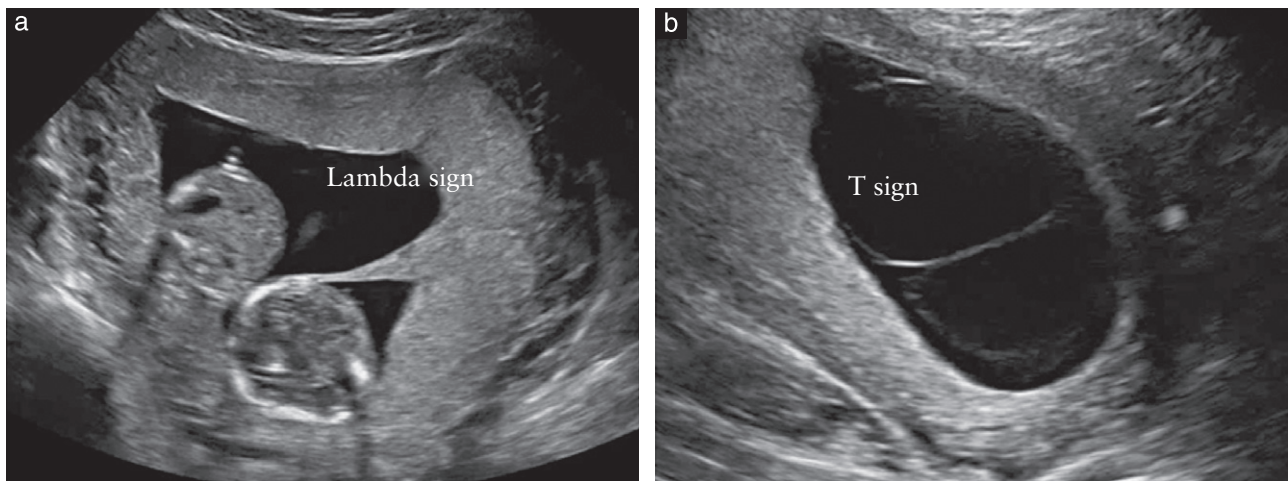


Figure 1 Ultrasound images in the first trimester of: (a) a dichorionic diamniotic twin pregnancy, in which the twins are separated by a thick layer of fused chorionic membranes; (b) a monochorionic diamniotic twin pregnancy, in which the twins are separated by only two thin amniotic layers.

At the time at which chorionicity is determined, amnionicity (i.e. whether or not the twins share the same amniotic sac) should be determined and documented. In case of doubt, absence of the intertwin membrane is best confirmed by transvaginal scan. Another useful finding is demonstration of cord entanglement, which is almost universal in MCMA twin pregnancy, using color and pulsed-wave Doppler ultrasound. Using pulsed-wave Doppler, two distinct arterial waveform patterns with different heart rates are seen within the same sampling gate (EVIDENCE LEVEL: 4).

All MCMA twin pregnancies should be referred to a tertiary center with expertise in their management¹. It is recommended that an ultrasound image demonstrating the chorionicity is stored electronically and that a hard copy is added to the medical records. As determination of chorionicity is most accurate at 11–14 weeks' gestation when the amnion and chorion have not yet fused, the first-trimester scan in twin pregnancy is paramount (EVIDENCE LEVEL: 4).

Labeling of twin fetuses

- The labeling of twin fetuses should follow a reliable and consistent strategy and should be documented clearly in the woman's notes (GOOD PRACTICE POINT).

It is important to follow a reliable, consistent strategy for antenatal twin labeling. Options include: labeling according to their site, either left and right, or upper and lower; or mapping in the first trimester according to the insertion of their cords relative to the placental edges and membrane insertion. In some healthcare settings, Twin A is the fetus on the right side, while Twin B is the one on the left. This information should be documented clearly in the woman's notes in order to ensure consistent labeling during follow-up scans¹⁷. It is advisable to describe each twin using as many features as possible so as to enable others to identify them accurately; e.g. 'Twin A (female) is on the maternal right with a posterior

placenta and marginal cord insertion'. For pregnancies with discordance, the labeling should be accompanied by a description such as 'Twin A, potential recipient'. It is important to acknowledge that labeling is less accurate in MCMA twin pregnancy, particularly in the first trimester.

The perinatal switch phenomenon

It should be borne in mind that the twins labeled as 'Twin A' and 'Twin B' during antenatal ultrasound scans may not necessarily be delivered in that order, in particular if the mode of delivery is Cesarean section¹⁸. It is important to alert parents and healthcare professionals attending the delivery to this fact, particularly in pregnancies in which the twins are discordant for structural abnormalities that are not obvious by external examination, e.g. congenital diaphragmatic hernia or cardiac defects. In such cases, an ultrasound scan should be performed just prior to delivery and also before instigating any specific neonatal intervention.

Routine monitoring of twin pregnancy with ultrasound

- Women with an uncomplicated dichorionic twin pregnancy should have a first-trimester scan, a detailed second-trimester scan, and scans every 4 weeks thereafter. Complicated dichorionic twins should be scanned more frequently, depending on the condition and its severity (GOOD PRACTICE POINT).
- Uncomplicated monochorionic twins should have a first-trimester scan and be scanned every 2 weeks after 16 weeks in order to detect TTTS and TAPS in a timely manner. Complicated monochorionic twins should be scanned more frequently, depending on the condition and its severity (GRADE OF RECOMMENDATION: C).

In uncomplicated dichorionic twin pregnancy, ultrasound imaging should be performed in the first trimester, again at around 20 weeks' gestation (second-trimester

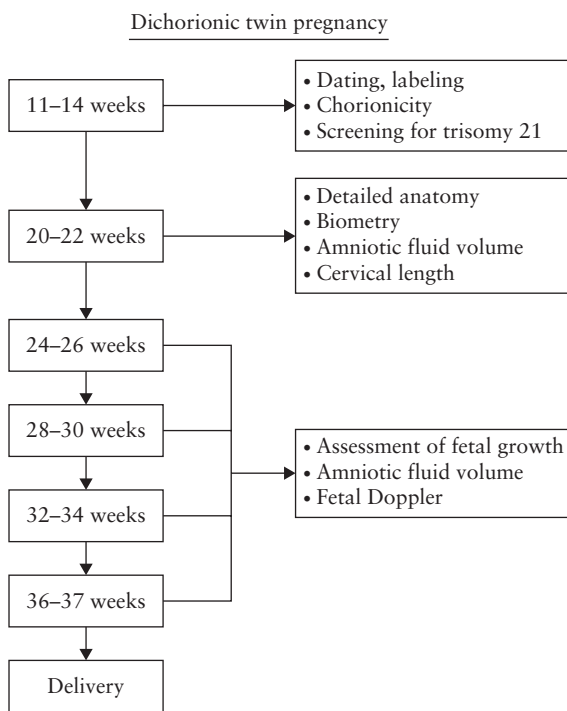


Figure 2 Ultrasound monitoring pathway in uncomplicated dichorionic twin pregnancy.

anomaly scan), and every 4 weeks thereafter (unless a complication is detected which might require more frequent scans) (Figure 2)¹. In uncomplicated monochorionic twins, an ultrasound scan should be performed in the first trimester. There should then be scans every 2 weeks from 16 weeks onwards, as timely detection of TTTS and TAPS has been shown to improve perinatal outcome (Figure 3)^{19,20} (EVIDENCE LEVEL: 4).

At each ultrasound assessment, the following should be assessed: fetal biometry, amniotic fluid volume and umbilical artery Doppler (from 20 weeks' gestation) for both twins. Discordance in estimated fetal weight (EFW) should be calculated and documented at each scan from 20 weeks. In monochorionic twin pregnancy, middle cerebral artery (MCA) peak systolic velocity (PSV) should be recorded from 20 weeks, in order to screen for TAPS. In MCDA twins, the amniotic fluid volume (deepest vertical pocket) should be assessed and documented at each ultrasound scan to screen for TTTS. Cervical length assessment is performed ideally at the same visit as the anomaly scan in the second trimester, in order to identify women at risk of extreme preterm birth (EVIDENCE LEVEL: 2+, 2++).

Screening for chromosomal abnormalities in twin pregnancy

- Screening for trisomy 21 can be performed in the first trimester using the combined test (nuchal translucency thickness (NT), free beta-human chorionic gonadotropin (β -hCG) level and pregnancy-associated plasma protein-A (PAPP-A) level). An alternative is combination of maternal age and NT only (GRADE OF RECOMMENDATION: B).

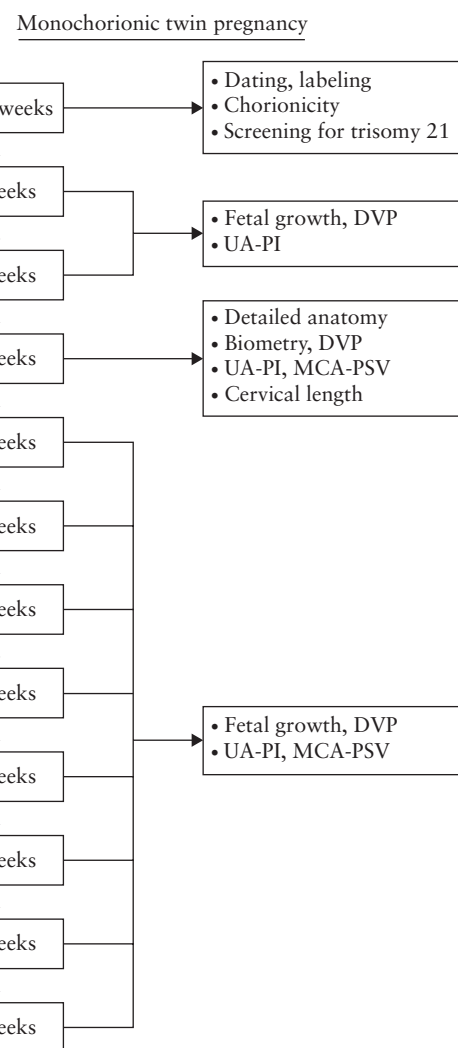


Figure 3 Ultrasound monitoring pathway in uncomplicated monochorionic twin pregnancy. DVP, deepest vertical pocket; MCA, middle cerebral artery; PI, pulsatility index; PSV, peak systolic velocity; UA, umbilical artery.

- In case of a vanished twin, if there is still a measurable fetal pole, NT alone, in combination with maternal age, should be used for risk estimation²¹ (GRADE OF RECOMMENDATION: B).
- The detection rate (DR) of non-invasive prenatal testing for trisomy 21 may be lower in twins than in singletons, but data are still limited (GRADE OF RECOMMENDATION: B).

In twin pregnancy, screening for trisomy 21 can be performed in the first trimester using the combined test, which includes maternal age, NT measurement and serum β -hCG and PAPP-A levels. An alternative is the combination of maternal age and the NT recorded between 11 + 0 and 13 + 6 weeks of gestation¹. In case of a vanished twin, if there is still a measurable fetal pole, β -hCG and PAPP-A measurements are biased and NT alone should be used for risk estimation. The risk of trisomy 21 in monochorionic twin pregnancy is calculated per pregnancy based on the average risk of both fetuses (because the twins share the same karyotype), whereas in dichorionic twin

pregnancy the risk is calculated per *fetus* (as around 90% are dizygotic so have different karyotypes).

The DR for Down syndrome may be lower in twin compared with singleton pregnancy¹. However, a recent meta-analysis reported similar performance (89% for singletons, 86% for dichorionic twins and 87% for monochorionic twins, at a false-positive rate (FPR) of 5%)²² (EVIDENCE LEVEL: 2++).

The likelihood of being offered invasive testing on the basis of a combined screening result is greater in twin compared with singleton pregnancy¹. Moreover, invasive testing carries greater risks in twins^{23–25}. A meta-analysis showed that the overall pregnancy loss rate following chorionic villus sampling (CVS) in twin pregnancy was 3.8%, and following amniocentesis was 3.1%²³. Other research has reported lower loss rates: 2% following CVS and 1.5–2% following amniocentesis²⁶. The risk was found to be similar for transabdominal and transcervical approaches, use of a single-needle or double-needle system, and single or double uterine entry²³ (EVIDENCE LEVEL: 2++).

Screening and diagnostic testing for trisomy is more complex in twin compared with singleton pregnancy. It is important, therefore, that counseling prior to testing is provided by healthcare professionals with expertise in this area¹. It is important to inform women and their partners in advance of the potentially complex decisions that they will need to make on the basis of the results of combined screening, bearing in mind the increased risk of invasive testing in twins, the possible discordance between dichorionic twins for fetal aneuploidy, and the risks of selective fetal reduction¹ (EVIDENCE LEVEL: 2+).

Cell-free DNA (cfDNA) analysis of maternal blood for risk assessment for fetal trisomy 21 is used increasingly in clinical practice. It has the potential to overcome many of these complex issues, because it has a much higher DR and lower FPR than does the combined test²⁷. In a recent meta-analysis, the weighted pooled DR for trisomy 21 in singleton pregnancy was 99% for a FPR of 0.1%²⁸. The corresponding values in twin pregnancy were 94.4% and 0%. However, so far, the reported number of trisomy-21 cases in twin pregnancy diagnosed using cfDNA testing is far smaller than that in singleton pregnancy (EVIDENCE LEVEL: 2++).

Invasive prenatal diagnosis in twin pregnancy

- CVS is preferred in dichorionic twin pregnancy (GRADE OF RECOMMENDATION: D).

Invasive testing for chromosomal or genetic analysis of twins should be carried out by a fetal medicine expert. CVS is preferred in dichorionic twin pregnancy because it can be performed earlier than can amniocentesis. Earlier diagnosis of any aneuploidy is particularly important in twin pregnancy, given the lower risk of selective termination in the first compared with the second trimester (7% risk of loss of the entire pregnancy, and 14% risk of delivery before 32 weeks)²⁹. It is important to map carefully

the position of the twins within the uterus. During amniocentesis in monochorionic twins, if monochorionicity has been confirmed before 14 weeks' gestation and the fetuses appear concordant for growth and anatomy, it is acceptable to sample only one amniotic sac. Otherwise, both amniotic sacs should be sampled because of the possibility of rare discordant chromosomal anomalies in monochorionic pregnancy. CVS in monochorionic pregnancy will sample only the single placenta so will miss these rare discordant chromosomal anomalies. Discordance for most of the common human aneuploidies (trisomies 13, 18 and 21, Turner syndrome and triploidy) has been reported in monochorionic twin pairs³⁰. In the event of heterokaryotypic monochorionic pregnancy, selective reduction by umbilical cord occlusion can be offered from 16 weeks onwards, with a survival rate of more than 80% for the healthy twin^{31,32}. When monochorionic twins are discordant for an abnormality, prior to invasive testing a discussion should take place regarding the complexity of selective termination, should it become necessary³² (EVIDENCE LEVEL: 3).

Implications of discordance in NT or CRL in the first trimester

- The management of twin pregnancy with CRL discordance $\geq 10\%$ or of NT discordance $\geq 20\%$ should be discussed with a fetal medicine expert (GRADE OF RECOMMENDATION: B).

Although some studies have reported an association between first-trimester intertwin discordance in NT or CRL, or reversed a-wave in the ductus venosus (DV), and the development of TTTS, their predictive value is poor^{17,33–35}. NT discordance of $\geq 20\%$ had a sensitivity of 52–64% and a specificity of 78–80%, a positive predictive value of 50% and a negative predictive value of 86% for the development of TTTS^{36,37}. Discordance in NT of $\geq 20\%$ is found in around 25% of monochorionic twins and the risk of early IUD or development of severe TTTS in this group is more than 30%³⁷. The risk of complications is less than 10% if the NT discordance is $< 20\%$ ³⁷. An abnormal DV will pick up only 38% of all pregnancies that subsequently develop TTTS, and, of those predicted to be at high risk, only 30% will ultimately develop TTTS³⁵. Similarly, although intertwin discordance in CRL at 11–13 weeks' gestation is significantly associated with the risk of pregnancy loss (area under the receiver–operating characteristics curve (AUC), 0.5), birth-weight discordance (AUC, 0.6), sFGR (AUC, 0.6) and preterm delivery prior to 34 weeks' gestation (AUC, 0.5), again the predictive value is poor (pooled predictive risk of 52%)^{38,39}. Nevertheless, the management of twin pregnancy with CRL discordance $\geq 10\%$ or NT discordance $\geq 20\%$ should be discussed with a fetal medicine expert and in these pregnancies there should be detailed ultrasound assessment and testing for karyotype abnormalities. The risk of fetal abnormalities was found to be 25% in pregnancies with CRL discordance $\geq 10\%$,

compared with 4% in pregnancies with CRL discordance < 10%⁴⁰. However, CRL discordance at 7 + 0 to 9 + 6 weeks' gestation is a predictor of the risk of single fetal demise in the first trimester (DR of 74% for a FPR of 5%)⁴¹ (EVIDENCE LEVEL: 2++).

Ultrasound screening for structural abnormalities in twin pregnancy

- Twin fetuses should be assessed for the presence of any major anomalies at the first-trimester scan, and a routine second-trimester (anomaly) scan should be performed at around 20 (18–22) weeks' gestation (GOOD PRACTICE POINT).
- Cardiac screening assessment should be performed in monochorionic twins (GOOD PRACTICE POINT).

At the first-trimester scan (between 11 + 0 and 13 + 6 weeks' gestation) the fetuses should be assessed for the presence of any major anomalies⁴². Routine second-trimester ultrasound screening for anomalies in twins should be performed by an experienced operator at around 20 (18–22) weeks' gestation^{1,43}. This scan may be more difficult than usual because of the presence of a second fetus, and it is important to allow adequate time (i.e. in the order of 45 min). The risk of fetal anomaly is greater in twin compared with singleton pregnancy⁴⁴. The rate per fetus in dizygotic twins is probably the same as that in singletons, whereas it is two-to-three times higher in monozygotic twins. In around 1 in 25 dichorionic, 1 in 15 MCDA and 1 in 6 monoamniotic twin pregnancies, there is a major congenital anomaly that typically affects only one twin^{45,46}. Therefore, screening for anomalies should be considered in monochorionic twin pregnancy, bearing in mind that brain and cardiac abnormalities might become more obvious in the third trimester. Abnormalities associated with twins include neural tube defects, anterior abdominal wall defects, facial clefts, brain abnormalities, cardiac defects and gastrointestinal anomalies. Therefore, screening cardiac assessment should be performed according to ISUOG guidance⁴⁷, including laterality, situs and four-chamber, ventricular outflow tract and aortic arch views. It is important to make the woman aware of the limitations of ultrasound screening, which vary according to the type of anomaly. The benefits of screening for fetal anomaly in the second trimester include giving parents the chance to prepare for the birth of a baby with a potential problem, offering them the option of termination, allowing transfer to a specialist center for the birth, and, potentially, facilitating intrauterine therapy¹ (EVIDENCE LEVEL: 3).

Managing twin pregnancy discordant for fetal anomaly

- Twin pregnancies discordant for fetal anomaly should be referred to a regional fetal medicine center (GOOD PRACTICE POINT).

One to two percent of twin pregnancies will have an anomaly affecting only one fetus, leading to the

challenging decision between expectant management and selective termination of the affected twin. Even in monozygotic twins, concordance for a structural anomaly is found in fewer than 20% of cases. Such pregnancies should be referred to a regional fetal medicine center for further management¹. In monochorionic twins discordant for a structural abnormality, discordant aneuploidy is very rare (though not impossible). In these situations, expert ultrasound assessment in a tertiary center, with invasive fetal chromosomal or genetic testing if indicated, and a discussion of the likely prognosis for both the affected and the normal twin, are essential. For conditions that are lethal and carry a high risk of intrauterine demise, conservative management is preferred in dichorionic twins, whereas in monochorionic twin pregnancy this would warrant intervention to protect the healthy cotwin against the adverse effects of spontaneous demise of the other.

Selective feticide in twin pregnancy

- In dichorionic twin pregnancy, selective feticide is performed by ultrasound-guided intracardiac or intrafunicular injection of potassium chloride or lignocaine, preferably in the first trimester (GRADE OF RECOMMENDATION: B).
- When the diagnosis is made in the second trimester, women might opt for late selective termination in the third trimester, if the law permits (GOOD PRACTICE POINT).
- Selective feticide in monochorionic twins is performed by cord occlusion, intrafetal laser ablation or radiofrequency ablation (RFA) (GRADE OF RECOMMENDATION: B).

The timing of selective termination in twin pregnancy influences the risk of miscarriage and/or preterm birth. This is particularly relevant in twin pregnancies discordant for anomalies, in which selective termination in the second trimester is associated with a higher risk of miscarriage and preterm birth, compared with that in the first trimester (7% risk of loss of the entire pregnancy, and 14% risk of delivery before 32 weeks)²⁹. When the diagnosis is made in the second trimester, women might opt for a late selective termination in the third trimester, if the law permits, when the procedure is associated with a risk of preterm birth rather than fetal loss of the unaffected twin. The pros and cons of each option should be considered (prematurity, loss rate, parental stress, availability of a fetal medicine specialist to perform the procedure in the event of preterm labor, and risk of complications associated with the specific anomaly) (EVIDENCE LEVEL: 2++).

Selective feticide in dichorionic twin pregnancy is performed by ultrasound-guided intracardiac or intrafunicular injection of 'strong' potassium chloride or 1% lignocaine. When selective termination of one twin of a monochorionic pair is the choice, injection of potassium chloride is not an option because of the risk to the healthy cotwin. Instead, cord occlusion, intrafetal laser ablation or RFA of the affected twin is necessary^{48,49}. This leads to

demise of the affected twin while protecting the healthy twin against losing part of its circulating blood volume into the terminated twin following its death. The survival rate of the cotwin is approximately 80% and the risk of premature rupture of the membranes and preterm birth prior to 32 weeks is 20%⁴⁹. The risk of adverse neurological sequelae in the surviving cotwin may also be increased compared with that in uncomplicated pregnancy^{49–52} (EVIDENCE LEVEL: 2++).

Screening for risk of preterm birth in twin pregnancy

- Cervical length measurement is the preferred method of screening for preterm birth in twins; 25 mm is the cut-off most commonly used in the second trimester (GRADE OF RECOMMENDATION: B).

Both spontaneous and iatrogenic preterm births are more common in twin than in singleton pregnancy². More than half of twins are born before 37 weeks of gestation (60% and 12% of twin births occur before 37 and 32 weeks of gestation, respectively; these rates are 5.4 and 7.6 times the equivalent rates for singleton pregnancy, respectively)². Asymptomatic women found to have a short cervix at the second-trimester ultrasound scan are known to be at increased risk of spontaneous preterm birth^{53,54}. However, the sensitivity of this finding is low, and the cut-off of the cervical length used to define increased risk of preterm birth is controversial. A cervical length < 25 mm at 18–24 weeks' gestation in twin pregnancy is a moderate predictor of preterm birth before 34 weeks, but not before 37 weeks^{53,54}. In asymptomatic women, a cervical length \leq 20 mm at 20–24 weeks was the most accurate predictor of preterm birth before 32 and before 34 weeks (pooled sensitivities, specificities and positive and negative likelihood ratios were 39% and 29%; 96% and 97%; 10.1 and 9.0; and 0.64 and 0.74, respectively). A cervical length \leq 25 mm at 20–24 weeks had a pooled positive likelihood ratio of 9.6 for the prediction of preterm birth before 28 weeks^{53,54}. The predictive accuracy of cervical length for preterm birth was low in symptomatic women^{53,54} (EVIDENCE LEVEL: 2++).

Moreover, there is no effective strategy to prevent preterm birth in these women. Bed rest, progesterone therapy, Arabin cervical pessary or oral tocolytics do not reduce the risk of preterm delivery in these women^{1,55–60}. However, progesterone therapy might reduce the risk of neonatal morbidity and mortality⁵⁵. Ongoing research may clarify management in this area in due course (EVIDENCE LEVEL: 1+).

Screening, diagnosis and management of fetal growth restriction (FGR)

Diagnostic criteria and investigations for selective FGR (sFGR)

- sFGR, conventionally, is defined as a condition in which one fetus has EFW < 10th centile and the intertwin EFW discordance is > 25% (GOOD PRACTICE POINT).

- A discordance cut-off of 20% seems acceptable to distinguish pregnancies at increased risk of adverse outcome (GRADE OF RECOMMENDATION: B).

The definition, assessment and management of FGR are inconsistent among clinicians. If both twins have an EFW < 10th centile, the fetuses should be termed small-for-gestational age. Conventionally, sFGR is a term applied to twin pregnancies in which one fetus has an EFW < 10th centile and the intertwin EFW discordance is > 25%^{61,62}. The American College of Obstetricians and Gynecologists considers a difference of 15–25% in the EFW to constitute discordant fetal growth⁶³. A cut-off of 18% for discordance in birth weight was found to predict adverse outcome optimally⁶⁴. Some clinicians do not take into account the intertwin EFW discordance (and simply use instead EFW < 10th centile in one twin). Furthermore, the discordance cut-off most predictive of adverse outcome is likely to vary with gestational age⁶⁵. A discordance cut-off of 20% seems a pragmatic choice for distinguishing pregnancies at increased risk of adverse outcome (consensus of Guideline authors). EFW discordance is calculated by the following formula: ((weight of larger twin – weight of smaller twin) \times 100)/weight of larger twin (EVIDENCE LEVEL: 2++).

Once a diagnosis has been made, a cause should be sought⁶². This search should include a detailed anomaly scan and screening for viral infections (cytomegalovirus, rubella and toxoplasmosis). Amniocentesis may also be required to exclude chromosomal abnormalities as a cause of FGR⁶². sFGR in monochorionic twin pregnancy occurs mainly due to unequal sharing of the placental mass and vasculature⁶⁶ (EVIDENCE LEVEL: 3).

Screening for FGR in twin pregnancy

- A combination of head, abdomen and femur measurements performs best in calculating EFW (GRADE OF RECOMMENDATION: B).
- If intertwin discordance is \geq 25%, a referral should be made to a tertiary fetal medicine center (GOOD PRACTICE POINT).

Assessing EFW using ultrasound is less accurate in twin than in singleton pregnancy⁶⁷. EFW charts that include a combination of head, abdomen and femur measurements perform best in both singleton and twin pregnancy⁶⁷. Currently, the charts used to monitor fetal growth in twin pregnancy are the same as those used for singletons. However, there is a reduction in fetal growth in twin compared with singleton pregnancy, particularly in the third trimester⁶⁸. This is particularly marked in MCDA pregnancies. This suggests that specific twin growth charts should be used for documenting and monitoring growth in twin pregnancies. However, the use of specific twin growth charts is controversial due to the concern that the reduced growth in the third trimester observed in most twin pregnancies might be caused by some degree of placental insufficiency, warranting close observation (EVIDENCE LEVEL: 2++).

EFW discordance between twins is significantly associated with the risk of perinatal loss⁶⁹. The hazard ratio for the risk of total perinatal loss in twins with an EFW discordance $\geq 25\%$ was found to be 7.3. According to the National Institute for Health and Care Excellence guidance, EFW discordance should be calculated and documented at every scan from 20 weeks onwards. If this discordance reaches 25% or more, a referral should be made to a tertiary-level fetal medicine unit for assessment, increased fetal surveillance, including fetal Doppler, and planning of delivery when appropriate¹ (EVIDENCE LEVEL: 2++).

Classification of monochorionic twin pregnancy complicated by sFGR

- Classification of sFGR in monochorionic twins depends on the pattern of end-diastolic velocity at umbilical artery Doppler (GOOD PRACTICE POINT).

The classification of sFGR depends on the pattern of end-diastolic velocity in the umbilical artery (Figure 4)⁷⁰. In Type I, the umbilical artery Doppler waveform has positive end-diastolic flow. In Type II, there is absent or reversed end-diastolic flow (AREDF). In Type III, there is a cyclical/intermittent pattern of AREDF. The survival rate in Type-I sFGR is greater than 90% (*in-utero* mortality rates of up to 4%). Type-II sFGR is associated with a high risk of IUD of the growth-restricted twin and/or very preterm delivery with associated risk of neurodevelopmental delay if the other twin survives (IUD of either twin in up to 29% and risk of neurological sequelae in up to 15% of cases born prior to 30 weeks). Type-III sFGR is associated with a 10–20% risk of sudden death of the growth-restricted fetus, which is unpredictable (even in cases in which ultrasound features have been stable). There is also a high (up to 20%) associated rate of

neurological morbidity in the surviving larger twin^{61,71} (EVIDENCE LEVEL: 2++).

Managing twin pregnancy complicated by sFGR

- In dichorionic pregnancies, sFGR should be followed as in growth-restricted singletons (GOOD PRACTICE POINT).
- There is limited evidence to guide the management of monochorionic twins affected by sFGR (GOOD PRACTICE POINT).

In dichorionic twin pregnancy complicated by sFGR, the timing of delivery should be determined based on a risk–benefit assessment and according to the wishes of the parents, guided by obstetric and neonatal counseling. As these twins have separate circulations, the pregnancy can be followed as in growth-restricted singleton pregnancy, monitoring for progressive deterioration of umbilical artery, MCA and DV Doppler, and of biophysical profile scores. These pregnancies should be managed in specialist centers with the relevant expertise. There is limited evidence to guide the management of monochorionic twins affected by sFGR. Options include: conservative management followed by early delivery; laser ablation; or cord occlusion of the growth-restricted twin (in order to protect the cotwin)⁷² (EVIDENCE LEVEL: 2–).

Follow-up of twin pregnancy complicated by sFGR

- In dichorionic twin pregnancy complicated by sFGR, fetal Doppler should be assessed approximately every 2 weeks, depending on the severity. In monochorionic twin pregnancy complicated by sFGR, fetal Doppler should be assessed at least weekly (GOOD PRACTICE POINT).

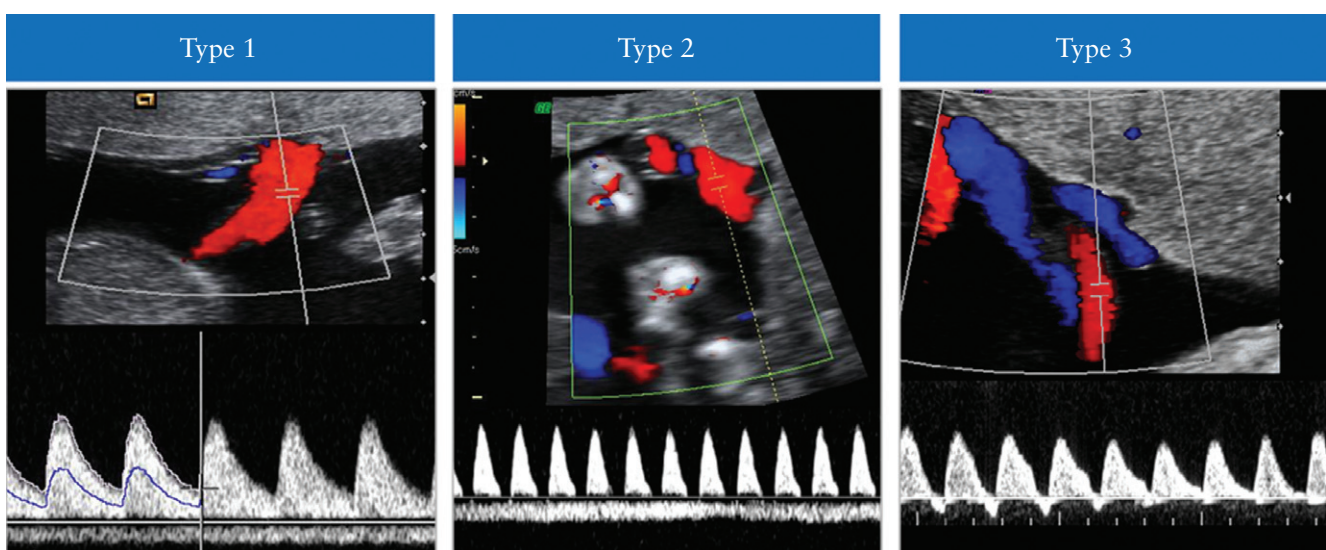


Figure 4 Classification of selective fetal growth restriction in monochorionic twin pregnancy. In Type I, the umbilical artery Doppler waveform has positive end-diastolic flow, while in Type II there is absent or reversed end-diastolic flow (AREDF). In Type III there is a cyclical/intermittent pattern of AREDF.

- If there is a substantial risk of fetal demise of one cotwin before 26 weeks, selective termination may be considered (GRADE OF RECOMMENDATION: D).

In monochorionic twin pregnancy complicated by sFGR, fetal growth should be assessed at least every 2 weeks, and fetal Doppler (umbilical artery and MCA) at least weekly. If the umbilical artery Doppler is abnormal, assessment of the DV blood flow should be undertaken. The aim in managing these pregnancies is to prolong the pregnancy at least until viability is achieved, while at the same time avoiding single IUD with its associated serious consequences for the surviving cotwin. In dichorionic twin pregnancy complicated by sFGR, follow-up visits could be less frequent, as delivery is usually not recommended before 32–34 weeks' gestation.

In cases in which Doppler assessment concludes that there is a real risk of fetal demise of one twin before 26 weeks of gestation, the option of selective termination should be explored in order to protect the normally grown fetus from serious harm should the smaller twin die *in utero*. Management of these cases is complex and should be coordinated by a tertiary-level fetal medicine center⁷² (EVIDENCE LEVEL: 2–).

The timing of delivery should be decided based on assessment of fetal wellbeing, interval growth, biophysical profile, DV waveform and/or computerized cardiotocography (CTG), when available. However, as the risk of IUD in these pregnancies is increased, delivery might be indicated even before abnormalities in the DV Doppler or the computerized CTG become evident. Furthermore, the incidence of severe cerebral injury in monochorionic twins complicated by sFGR is approximately 10% and is associated with abnormal umbilical artery Doppler, single IUD and low gestational age at birth⁷³. Interestingly, the risks of neonatal morbidity (38% *vs* 19%), particularly respiratory distress syndrome (32% *vs* 6%) and cerebral lesions, are higher in the larger than in the smaller cotwin⁷⁴ (EVIDENCE LEVEL: 2++).

Managing the surviving twin after demise of its cotwin

- When single IUD occurs in a twin pregnancy, the woman should be referred to a tertiary-level center with relevant expertise (GOOD PRACTICE POINT).

Following single IUD, the following complications are found in monochorionic and dichorionic pregnancies, respectively^{75–77}:

- Death of the cotwin: 15% and 3%.
- Preterm delivery: 68% and 54%.
- Abnormal postnatal cranial imaging of the surviving cotwin: 34% and 16%.
- Neurodevelopmental impairment of the surviving cotwin: 26% and 2% (EVIDENCE LEVEL: 2++).

When one monochorionic twin dies *in utero*, the surviving twin may then lose part of its circulating volume to the dead twin, leading to potentially severe hypotension

in the survivor. This can lead to hypoperfusion of the brain and other organs, which can cause brain damage or death (EVIDENCE LEVEL: 3).

When single IUD occurs in a monochorionic twin pregnancy, the woman should be managed at a tertiary-level center with relevant expertise. This should include assessment of fetal Doppler, especially MCA-PSV, in order to look for signs of fetal anemia in the surviving twin. Conservative management (i.e. continuing the pregnancy) is often the most appropriate course of action. Swift delivery is usually not indicated, because, if the surviving twin suffers any neurological harm, this has often already happened by the time the death has been diagnosed. If the pregnancy is at term, then it makes sense to deliver without delay, but if it is preterm, prolonging the pregnancy for the benefit of the surviving twin (in terms of increased maturity) is usually recommended. Detailed counseling of the parents is required. This should include an explanation of the risk that there might be significant long-term morbidity (neurological or otherwise) to the surviving twin but that this damage may have taken place already and urgent delivery may be too late to prevent such harm. In the short term, the surviving twin should be assessed for evidence of ongoing fetal compromise using CTG or MCA Doppler to assess for fetal anemia⁷⁸. If conservative management is chosen, fetal biometry and assessment of umbilical and MCA Doppler should be scheduled every 2–4 weeks, and delivery should be considered at 34–36 weeks, after a course of maternal steroids. If the MCA-PSV is normal in the first few days, fetal anemia is unlikely to occur later. The fetal brain should be imaged around 4–6 weeks after the death of the cotwin to search for evidence of cerebral morbidity. In cases in which there is strong evidence that the surviving cotwin may have suffered serious neurological harm, late termination of pregnancy should be considered as an option. Neurodevelopmental assessment of the surviving twin at the age of 2 years should be recommended. There have been some reports of intrauterine transfusion of an anemic surviving cotwin, but whether this prevents long-term neurological morbidity is unknown^{79–81} (EVIDENCE LEVEL: 3).

COMPLICATIONS UNIQUE TO MONOCHORIONIC TWIN PREGNANCY

Complications which occur only in monochorionic twin pregnancy include TTTS, TAPS, TRAP sequence, monoamniotic pregnancy and conjoined twinning.

Screening, diagnosis, staging and management of TTTS

Up to one third of twin pregnancies are monochorionic. In nearly all monochorionic twins, the placenta contains vascular anastomoses connecting the two fetal circulations. It is the angioarchitecture of these vascular anastomoses that determines the risk profile. Monochorionic twins are at risk of developing TTTS when there is unequal hemodynamic and amniotic fluid balance^{82–85}. The diagnosis of TTTS requires the presence of significant amniotic

fluid imbalance. The 'donor' twin has a DVP of < 2 cm (oligohydramnios) and the 'recipient' twin has a DVP > 8 cm (polyhydramnios). In Europe, the diagnosis of polyhydramnios is made when DVP \geq 8 cm at \leq 20 weeks and \geq 10 cm after 20 weeks' gestation. Size discordance is a common finding, but is not essential for the diagnosis. TTTS affects 10–15% of monochorionic twin pregnancies and is associated with increased perinatal mortality and morbidity; if untreated, it leads to fetal demise in up to 90% of cases, with morbidity rates in survivors of over 50%^{84,85}. Early diagnosis, however, may allow intervention with fetoscopic laser ablation, which significantly improves the prognosis. Laser treatment in these pregnancies results in 60–70% double survival and 80–90% survival of at least one twin^{85–87}.

Staging of TTTS

- Although Quintero staging does not always predict accurately outcome or chronological evolution of TTTS, it remains the classification system of choice (GOOD PRACTICE POINT).

TTTS is currently classified using the Quintero staging system (Table 1)^{82,83}. There is some debate about the validity of Quintero staging of TTTS. It has been noted that Stage-I disease is not necessarily associated with the best outcomes. For example, some recipient twins in pregnancies categorized as Quintero stage I TTTS may have a degree of cardiac dysfunction^{88–90}. Another criticism is that it does not represent a chronological order of deterioration, e.g. Stage 1 can become Stage 5 without passing through Stages 2, 3 and 4, and it does not predict survival well after treatment. While incorporation of additional cardiovascular parameters stratifies additional disease features independent of Quintero staging, these do not improve prediction of outcome following treatment. Nevertheless, the Quintero staging system remains the most commonly used for the classification of twin pregnancy complicated by TTTS (EVIDENCE LEVEL: 2+).

Screening for TTTS

- In monochorionic twin pregnancy, screening for TTTS should start at 16 weeks, with scans repeated every 2 weeks thereafter (GOOD PRACTICE POINT).

Table 1 Quintero staging system⁸²

Stage	Classification
I	Polyhydramnios–oligohydramnios sequence: DVP > 8 cm in recipient twin and DVP < 2 cm in donor twin
II	Bladder in donor twin not visible on ultrasound
III	Absent or reversed umbilical artery diastolic flow, reversed ductus venosus a-wave flow, pulsatile umbilical venous flow in either twin
IV	Hydrops in one or both twins
V	Death of one or both twins

DVP, deepest vertical pocket.

Monitoring of monochorionic twin pregnancy for the development of TTTS should start with a scan at 16 weeks' gestation; scans should be repeated every 2 weeks thereafter. At every scan, the operator should note and record evidence of membrane folding and measure the DVP of amniotic fluid for each fetus. If significant inequality in DVP exists or there is membrane infolding, then more frequent ultrasound surveillance may be warranted. TTTS is far less common in MCMA, compared with MCDA, twin pregnancy; the ultrasound diagnostic features include polyhydramnios in the common amniotic sac and discordant bladder sizes.

Prognosis for monochorionic twin pregnancy with amniotic fluid discordance

- Monochorionic twin pregnancies with uncomplicated amniotic fluid discordance can be followed up on a weekly basis to exclude progression to TTTS (GOOD PRACTICE POINT).

Monochorionic twin pregnancies with amniotic fluid discordance between the twins which does not fulfil the 8 cm/2 cm criterion (in other words, it falls within the 'normal' range), and normal umbilical artery Doppler measurements, are associated with a good outcome (93% overall survival) and a low risk (14%) of progression to severe TTTS^{91–93}. However, it is common practice for these pregnancies to be followed on a weekly basis initially, to ensure that there is no progression to TTTS (EVIDENCE LEVEL: 2+).

Treatment of TTTS

- Laser ablation is the treatment of choice for TTTS at Quintero stages II and above (GRADE OF RECOMMENDATION: A).
- Conservative management with close surveillance or laser ablation can be considered for Quintero stage I (GRADE OF RECOMMENDATION: B).
- When laser treatment is not available, serial amnioreduction is an acceptable alternative after 26 weeks' gestation (GRADE OF RECOMMENDATION: A).

TTTS diagnosed before 26 weeks of gestation is best treated by laser ablation, as the evidence suggests that it leads to better outcomes compared with amnioreduction or septostomy⁸⁵ (EVIDENCE LEVEL: 1+). It is generally accepted that Quintero stages II and above will require treatment, and many centers will manage Quintero stage I conservatively. However, if laser ablation expertise is not available, amnioreduction is an acceptable alternative in pregnancies diagnosed after 26 weeks of gestation⁸⁵. There is, in fact, some evidence that laser ablation is still the best form of treatment for TTTS, regardless of whether it is diagnosed early (before 16 weeks) or late (after 26 weeks' gestation)^{93,94}. Both conservative management with close surveillance and laser treatment are considered reasonable options in Stage 1 TTTS, pending

the results of randomized trials comparing conservative management with laser therapy. If conservative management is chosen for Quintero stage I, worsening polyhydramnios, maternal discomfort and shortening of the cervical length are considered 'rescue' criteria signalling a need to proceed with fetoscopic laser treatment. In a systematic review of the management of Stage 1 TTTS pregnancy, overall survival appeared to be similar for those undergoing laser therapy or conservative management (85% and 86%, respectively), but was somewhat lower for those undergoing amnioreduction (77%)⁹⁵ (EVIDENCE LEVEL: 2-).

Following laser treatment, the recurrence rate of TTTS is up to 14%, which is likely to be due to anastomoses missed at the time of the initial laser treatment⁹⁶ (EVIDENCE LEVEL: 2-). The risk of recurrence of TTTS and occurrence of TAPS is reduced by use of the Solomon technique (equatorial laser dichorionization) compared with the highly-selective technique^{86,87} (EVIDENCE LEVEL: 1+).

Another option for the management of severe TTTS is selective termination of pregnancy using bipolar diathermy, laser coagulation or RFA of one of the umbilical cords. This means that this fetus is sacrificed in the hope of protecting the other twin from death or cerebral damage. Rarely, parents may opt for termination of the entire pregnancy.

Follow-up and optimal gestational age for delivery in twin pregnancy with TTTS

- A common practice is weekly ultrasound assessment for the first 2 weeks after treatment, reducing to alternate weeks following clinical evidence of resolution (GOOD PRACTICE POINT).
- In case of demise of one fetus (post-laser), brain imaging of the surviving cotwin should be considered 4–6 weeks later, and neurodevelopmental assessment should take place at 2 years of age (GOOD PRACTICE POINT).

There is no evidence to guide frequency of ultrasound follow-up after treatment of TTTS. However, treatment should result in normalization of amniotic fluid by 14 days⁹⁷. Cardiac dysfunction generally normalizes in the recipient within 1 month, while the donor suffers a temporary impairment of cardiac function⁹⁸ (EVIDENCE LEVEL: 2+). A common practice is weekly ultrasound assessment for the first 2 weeks after treatment, reducing to alternate weeks following clinical evidence of resolution. Each ultrasound scan should assess the DVP, biometry (every 2 weeks), and umbilical artery, MCA (PSV) and DV Doppler in both fetuses. Nevertheless, 8% of all twins, both recipients and donors, will have pulmonary artery stenosis at the age of 10 years⁹⁹ and 4% of survivors suffer antenatal brain damage¹⁰⁰ (EVIDENCE LEVEL: 3). There should be a detailed assessment of the brain, heart and limbs (risk of amputation secondary to thrombi or amniotic bands) during these follow-up scans. Functional heart problems and antenatal cerebral

lesions may become obvious only in the third trimester. Some fetal medicine centers offer fetal brain magnetic resonance imaging (MRI) at 30 weeks to all survivors after laser treatment, in order to detect brain anomalies such as migration and proliferation disorders. However, evidence to support this practice is limited and the specificity of diagnosis and how this translates into long-term neurological morbidity is unknown¹⁰¹. There is limited evidence on the optimal timing and route of delivery for monochorionic twins previously treated for TTTS, but the general consensus is that this should be at 34 weeks of gestation, after a course of steroids¹⁰². However, it is also reasonable to adopt a similar strategy as that for all monochorionic twins, with delivery at 34 weeks of gestation for persisting abnormalities and up to 37 weeks where there is complete resolution. The optimal route of delivery following laser therapy has not been determined.

Twin pregnancies treated by laser for TTTS should be considered as high risk for adverse outcomes, even if normalization of the amniotic fluid occurs (EVIDENCE LEVEL: 2-). In pregnancies complicated by demise of one fetus (post-laser), brain imaging should be considered 4–6 weeks later, and neurodevelopmental assessment should take place at the age of 2–3 years.

Risk of brain abnormalities and neurodevelopmental delay in twin pregnancy with TTTS

Monochorionic twin pregnancies complicated by TTTS, single IUD, sFGR or TAPS are at increased risk of brain abnormalities and neurodevelopmental disability^{73,103–105}. In pregnancies complicated by TTTS, cerebral abnormalities were reported in 5% of those undergoing laser coagulation, 14% following serial amnioreduction and 21% following expectant management¹⁰⁴ (EVIDENCE LEVEL: 2-). Both donors and recipients are at risk of developing either ischemic or hemorrhagic lesions¹⁰⁴. At a median age of 34 months following laser treatment for TTTS, 7% of the children had major neurological abnormalities^{106,107} (EVIDENCE LEVEL: 2-). The neurodevelopmental outcome at 6 years of age was similar to that at the age of 2 years and 10 months, with 9% of the children experiencing major neurodevelopmental delay¹⁰⁸ (EVIDENCE LEVEL: 2-).

Screening, diagnosis and management of twin anemia–polycythemia sequence (TAPS)

- The prenatal diagnosis of TAPS is based on the finding of discordant MCA Doppler abnormalities (GRADE OF RECOMMENDATION: D).
- There is little evidence about the outcome and optimal management of TAPS; therefore treatment options should be individualized and discussed with parents (GOOD PRACTICE POINT).

Understanding of the natural history and fetal and neonatal implications of TAPS in monochorionic pregnancies is still evolving. Moreover, the optimal treatment and

frequency and mode of surveillance have yet to be established. The incidence of TAPS occurring spontaneously in MCDA twins is up to 5%. However, it may complicate up to 13% of cases of TTTS following laser ablation⁹⁶. TAPS is believed to be due to the presence of miniscule arteriovenous anastomoses (< 1 mm) which allow slow transfusion of blood from the donor to the recipient, leading to highly discordant hemoglobin concentrations at birth (EVIDENCE LEVEL: 3). The postnatal diagnosis of TAPS is made based on the finding of chronic anemia (including reticulocytosis) in the donor and polycythemia in the recipient. The criteria for diagnosis include a difference in hemoglobin concentration between the twins of more than 8 g/dL and at least one of either reticulocyte count ratio greater than 1.7 or small vascular anastomoses (< 1 mm in diameter) in the placenta^{109,110}. The prenatal diagnosis of TAPS is based on the finding of discordant MCA Doppler abnormalities, including MCA-PSV > 1.5 multiples of the median (MoM) in the donor, suggesting fetal anemia, and MCA-PSV < 1.0 MoM in the recipient, suggesting polycythemia. Additional ultrasound findings in TAPS include differences in placental echogenicity and thickness, with a bright, thickened section associated with the donor and an echolucent thin section associated with the recipient. The polycythemic twin might have a 'starry sky' appearance of the liver pattern due to diminished echogenicity of the liver parenchyma and increased brightness of the portal venule walls. The antenatal and postnatal severity-based staging classifications are shown in Table 2^{109,110} (EVIDENCE LEVEL: 3).

The outcome of twin pregnancies complicated by TAPS is variable. Severe TAPS may result in IUD of both twins. At the other end of the spectrum, mild TAPS may still allow the birth of two healthy neonates (apart from

having a significant difference in hemoglobin level between the two). It appears that the main neonatal morbidity is anemia (requiring transfusion) and polycythemia (possibly requiring partial exchange transfusion)¹¹¹. However, cases of severe cerebral damage have been reported in TAPS neonates¹¹². Recent evidence suggests that, in monochorionic twins complicated by TAPS, the risk of neurodevelopmental delay is increased (20%)¹¹³. Therefore, brain imaging during the third trimester and neurodevelopmental assessment at the age of 2 years are recommended (EVIDENCE LEVEL: 3).

The management options depend on the gestational age at diagnosis, parental choice, severity of the disease and technical feasibility of intrauterine therapy. Therefore, the management of twin pregnancies complicated by TAPS should be individualized. The commonest options include conservative management, early delivery, laser ablation or intrauterine blood transfusion (IUT) for the anemic twin, combined IUT for the anemic twin and partial exchange transfusion to dilute the blood of the polycythemic twin¹¹⁴. In order to screen for TAPS, the MCA-PSV should be measured from 20 weeks onwards in both fetuses, and during the follow-up of cases treated for TTTS. Prevention of TAPS by modification of the fetoscopic laser ablation technique remains the best way to prevent morbidity^{87,115} (EVIDENCE LEVEL: 3).

Twin reversed arterial perfusion (TRAP) sequence

- The chances of survival of the pump twin are increased by the use of minimally invasive techniques (e.g. cord coagulation, cord ligation and photocoagulation of the anastomoses, as well as intrafetal methods), preferably before 16 weeks of gestation (GRADE OF RECOMMENDATION: D).

TRAP sequence is a rare complication of monochorionic twin pregnancy (1% of monochorionic twin pregnancies and 1 in 35 000 pregnancies overall). It is characterized by the presence of a TRAP or acardiac mass perfused by an apparently normal (pump) twin (Figure 5)¹¹⁶. The perfusion occurs in a retrograde fashion through arterioarterial anastomoses, usually through a common cord insertion site¹¹⁷. This characteristic vascular arrangement predisposes to a hyperdynamic circulation and progressive high-output cardiac failure in the pump twin¹¹⁷. The risk of demise of the pump fetus in TRAP sequence managed conservatively is up to 30% by 18 weeks' gestation¹¹⁸ (EVIDENCE LEVEL: 3).

Different minimally invasive techniques, such as cord coagulation, cord ligation and photocoagulation of the anastomoses, as well as intrafetal methods, such as RFA and intrafetal laser therapy, are performed as a means of preventing the demise of the pump twin (Figure 5)¹¹⁹. The survival rate of the pump twin using these treatment modalities is approximately 80%. TRAP sequence pregnancies are usually monitored serially, with the aim of undertaking intrauterine therapy if cardiac strain becomes

Table 2 Antenatal and postnatal staging of twin anemia–polycythemia sequence (TAPS)^{109,110}

Stage	Antenatal staging	Postnatal staging: intertwin Hb diff (g/dL)
1	Donor MCA-PSV > 1.5 MoM and recipient MCA-PSV < 1.0 MoM, without other signs of fetal compromise	> 8.0
2	Donor MCA-PSV > 1.7 MoM and recipient MCA-PSV < 0.8 MoM, without other signs of fetal compromise	> 11.0
3	Stage 1 or 2 and cardiac compromise in donor (UA-AREDF, UV pulsatile flow, or DV increased or reversed flow)	> 14.0
4	Hydrops of donor twin	> 17.0
5	Death of one or both fetuses, preceded by TAPS	> 20.0

AREDF, absent or reversed end-diastolic flow; DV, ductus venosus; Hb, hemoglobin; MCA, middle cerebral artery; MoM, multiples of median; PI, pulsatility index; PSV, peak systolic velocity; UA, umbilical artery; UV, umbilical vein.

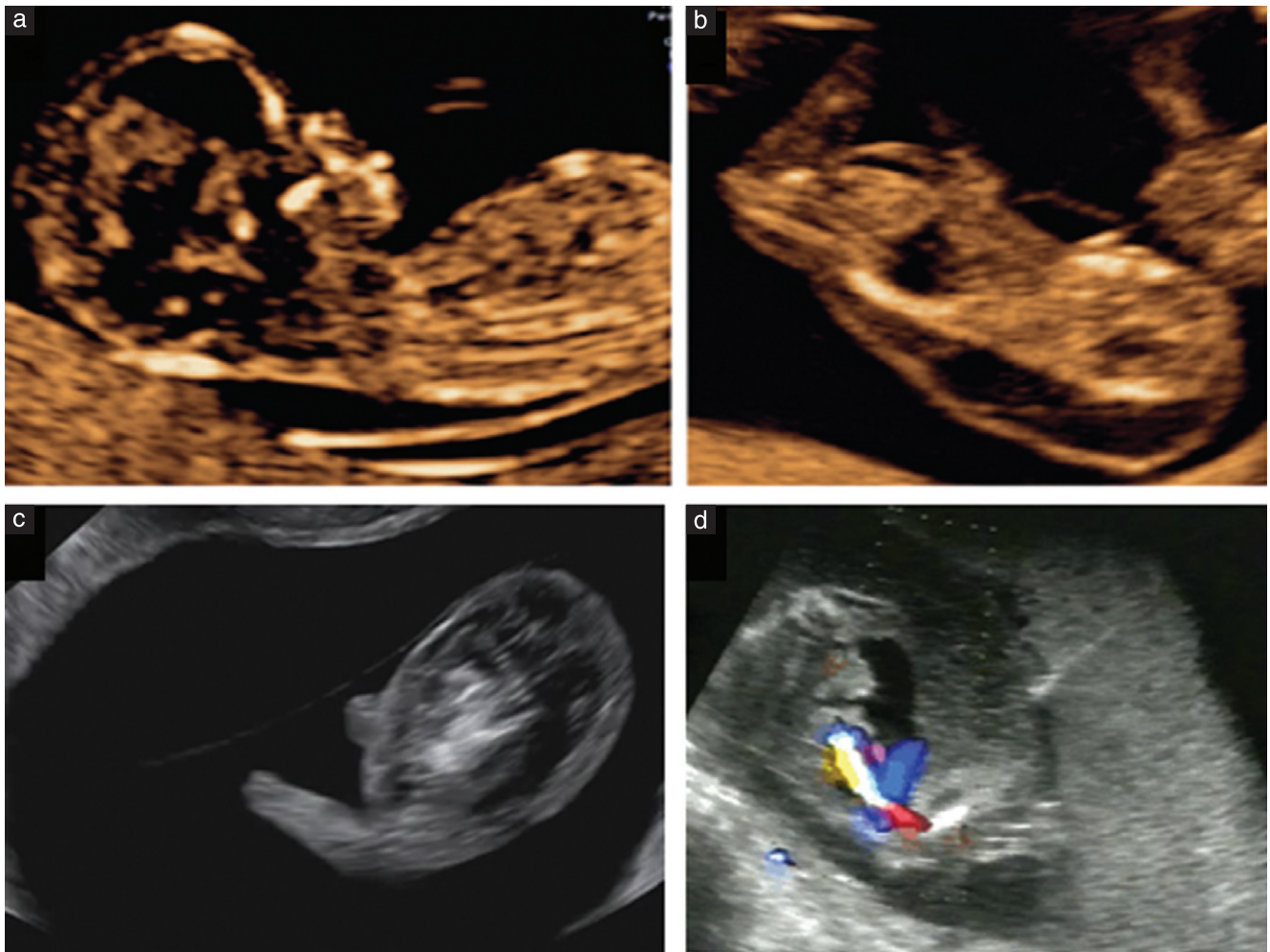


Figure 5 (a) Mid-sagittal ultrasound image of pump twin in a pregnancy affected by twin reversed arterial perfusion (TRAP) sequence. (b,c) Sagittal views of TRAP mass. (d) Intrafetal laser treatment as a means to arrest the flow in the TRAP mass. The needle is positioned, under ultrasound guidance, in the TRAP mass near the cord insertion.

evident in the pump twin or there is increased perfusion (including the occurrence of polyhydramnios) and growth of the TRAP mass¹¹⁹. Therefore, careful monitoring and ultrasound follow-up in a tertiary fetal medicine center is indicated. However, close monitoring with ultrasound and Doppler does not prevent sudden demise. When treatment is necessary, it appears to be preferable before 16 weeks' gestation¹²⁰. The rate of preterm birth before 32 weeks' gestation is approximately 10%¹²⁰. Recent evidence suggests an inverse relationship between gestational age at treatment and gestational age at birth. Therefore, survival might be improved by elective intervention at 12–14 weeks' gestation¹²¹. However, it is important to acknowledge the observational nature of this evidence and the small size of the case series, which does not allow for the assessment of fetal loss rates compared with those following later intervention (EVIDENCE LEVEL: 3).

Monochorionic monoamniotic (MCMA) twins

- Umbilical cord entanglement is almost always present in MCMA twins and does not appear to contribute to

their morbidity and mortality (GRADE OF RECOMMENDATION: D).

- Delivery by Cesarean section is recommended at 32–34 weeks (GRADE OF RECOMMENDATION: D).

MCMA twin pregnancies constitute approximately 5% of monochorionic twin pregnancies¹²². The reported perinatal loss rate before 16 weeks' gestation is as high as 50%¹²³ (EVIDENCE LEVEL: 3). Most losses are attributable to fetal abnormalities and spontaneous miscarriage¹²³ (EVIDENCE LEVEL: 3). The management of these pregnancies may be complex and should take place in centers with the relevant expertise. The loss rate has improved, from 40% in the older literature^{124–126} to 10–15% in recent studies¹²⁷ (EVIDENCE LEVEL: 2–). In a cohort study including 98 MCMA twin pregnancies, the perinatal mortality rate (from 20 weeks of gestation until 28 days of age) was 19%¹²⁸. However, the rate was 17% after exclusion of fetuses with a lethal anomaly. After 32 weeks of gestation, only two pregnancies were complicated by perinatal mortality (4%). The incidence of TTTS and cerebral injury was 6% and

5%, respectively¹²⁸ (EVIDENCE LEVEL: 3). The recommended timing of delivery varies from 32 to 36 weeks' gestation. Recent evidence suggests that MCMA twin pregnancies are at increased risk of IUD compared with other types of twin pregnancy and should be delivered by Cesarean section between 32 and 34 weeks of gestation (EVIDENCE LEVEL: 3). This is based on the finding that, after 32 + 4 weeks' gestation, the risk of IUD is greater in ongoing MCMA pregnancy compared with the risk of non-respiratory neonatal complications when the twins are delivered¹²⁹. Therefore, individualized assessment of these pregnancies should inform the timing of delivery.

It is important to realize that umbilical cord entanglement is present in almost all monoamniotic twins evaluated systematically by ultrasound and color Doppler¹³⁰. A systematic review including a total of 114 monoamniotic twin sets (228 fetuses) with cord entanglement concluded that cord entanglement does not contribute to prenatal morbidity and mortality in monoamniotic twin pregnancy¹²⁷. Moreover, the presence of an umbilical artery notch, without other signs of fetal deterioration, is not indicative of an adverse perinatal outcome¹³¹ (EVIDENCE LEVEL: 2–).

In MCMA twin pregnancies undergoing selective reduction (because of discordant anomaly, TRAP sequence, severe TTTS or sFGR), cord occlusion and transection are recommended to prevent fetal demise of the other twin due to cord accidents^{132–135}. The perinatal outcomes are similar to those of discordant MCDA twins treated with cord occlusion. However, the rate of preterm prelabor rupture of the membranes is higher and gestational age at delivery is lower in MCMA than in MCDA pregnancy (EVIDENCE LEVEL: 3).

Conjoined twins

Conjoined twins are very rare, occurring in approximately 1 in 100 000 pregnancies (1% of monochorionic twin pregnancies). Conjoined twins are always MCMA twin pregnancies. Diagnosis with ultrasound in the first trimester is now the norm (on visualizing close and fixed apposition of the fetal bodies, with fusion of the skin lines at some point). A recent series of 14 cases from a single referral center reported that, following diagnosis, 20% of parents opted for termination and 10% of fetuses died *in utero*. Among those opting to continue the pregnancy, survival to discharge was only around 25%, and the majority of these had significant morbidity¹³⁶.

The classification of conjoined twins depends on the site of the union. The most common form is thoracopagus, in which the twins face each other and have junctions between chest and abdomen, often with conjoined livers, hearts and intestinal structures¹³⁶.

In ongoing pregnancies, detailed expert ultrasound imaging (with or without MRI) is important in order to detail the cardiovascular (and other) anatomy of the twins as far as possible prior to delivery. Although vaginal delivery of conjoined twins has been reported, there is a significant risk of obstructed labor, dystocia and uterine rupture,

so delivery by elective Cesarean section is now the rule¹³⁷. Such pregnancies should be assessed at a fetal medicine referral center, with multidisciplinary assessment and counseling. The pregnancy must be delivered at a center with expertise in the postnatal medical and surgical management of such cases. There are associated high rates of postnatal mortality and there is almost always morbidity.

GUIDELINE AUTHORS

A. Khalil, Fetal Medicine Unit, St George's Hospital, St George's University of London, London, UK

M. Rodgers, Centre for Reviews and Dissemination, University of York, UK

A. Baschat, The Johns Hopkins Center for Fetal Therapy, Baltimore, MD, USA

A. Bhide, Fetal Medicine Unit, St George's Hospital, St George's University of London, London, UK

E. Gratacos, Fetal Medicine Units and Departments of Obstetrics, Hospital Clinic-IDIBAPS, University of Barcelona, Barcelona, Spain

K. Hecher, Department of Obstetrics and Fetal Medicine, University Medical Center Hamburg-Eppendorf, Hamburg, Germany

M. D. Kilby, Centre for Women's and Children's Health, University of Birmingham and Fetal Medicine Centre, Birmingham Women's Foundation Trust, Birmingham, UK

L. Lewi, Department of Obstetrics and Gynecology, University Hospitals Leuven, Leuven, Belgium

K. H. Nicolaides, Harris Birthright Research Centre for Fetal Medicine, King's College Hospital, London, UK

D. Oepkes, Division of Fetal Medicine, Department of Obstetrics, Leiden University Medical Center, Leiden, The Netherlands

N. Raine-Fenning, Division of Child Health, Obstetrics and Gynaecology, School of Medicine, University of Nottingham, Nottingham, UK

K. Reed, Twin and Multiple Births Association (TAMBA)

L. J. Salomon, Hopital Necker-Enfants Malades, AP-HP, Université Paris Descartes, Paris, France

A. Sotiriadis, Department of Obstetrics and Gynaecology, Aristotle University of Thessaloniki, Thessaloniki, Greece

B. Thilaganathan, Fetal Medicine Unit, St George's Hospital, St George's University of London, London, UK

Y. Ville, Hospital Necker-Enfants Malades, AP-HP, Université Paris Descartes, Paris, France

CITATION

These Guidelines should be cited as: 'Khalil A, Rodgers M, Baschat A, Bhide A, Gratacos E, Hecher K, Kilby MD, Lewi L, Nicolaides KH, Oepkes D, Raine-Fenning N, Reed K, Salomon LJ, Sotiriadis A, Thilaganathan B, Ville Y. ISUOG Practice Guidelines: role of ultrasound in twin pregnancy. *Ultrasound Obstet Gynecol* 2016; 47: 247–263.'

REFERENCES

- National Collaborating Center for Women's and Children's Health (UK). *Multiple Pregnancy. The Management of Twin and Triplet Pregnancies in the Antenatal Period*. Commissioned by the National Institute for Clinical Excellence. RCOG Press: London, September 2011.
- Martin JA, Hamilton BE, Sutton PD, Ventura SJ, Menacker F, Kirmeyer S, Mathews TJ. Births: final data for 2006. *Natl Vital Stat Rep* 2009; 57: 1–102.
- Sebire NJ, Snijders RJ, Hughes K, Sepulveda W, Nicolaides KH. The hidden mortality of monochorionic twin pregnancies. *Br J Obstet Gynaecol* 1997; 104: 1203–1207.
- Joseph K, Liu S, Demissie K, Wen SW, Platt RW, Ananth CV, Dzakpasu S, Sauve R, Allen AC, Kramer MS; The Fetal and Infant Health Study Group of the Canadian Perinatal Surveillance System. A parsimonious explanation for intersecting perinatal mortality curves: understanding the effect of plurality and of parity. *BMC Pregnancy Childbirth* 2003; 3: 3.
- Hack KE, Derks JB, Elias SG, Franx A, Roos EJ, Voerman SK, Bode CL, Koopman-Esseboom C, Visser GH. Increased perinatal mortality and morbidity in monochorionic versus dichorionic twin pregnancies: clinical implications of a large Dutch cohort study. *BJOG* 2008; 115: 58–67.
- Southwest Thames Obstetric Research Collaborative (STORK). Prospective risk of late stillbirth in monochorionic twins: a regional cohort study. *Ultrasound Obstet Gynecol* 2012; 39: 500–504.
- Garne E, Andersen HJ. The impact of multiple pregnancies and malformations on perinatal mortality. *J Perinat Med* 2004; 32: 215–219.
- Luke B, Brown MB. The changing risk of infant mortality by gestation, plurality, and race: 1989–1991, versus 1999–2001. *Pediatrics* 2006; 118: 2488–2497.
- Chan A, Scott J, Nguyen A, Sage L. *Pregnancy Outcome in South Australia 2007*. Pregnancy Outcome Unit, SA Health: Adelaide, 2008.
- Elliott JP. High-order multiple gestations. *Semin Perinatol* 2005; 29: 305–311.
- Laws PJ, Hilder L. *Australia's Mothers and Babies 2006*. AIWH National Perinatal Statistics Unit: Sydney, 2008.
- Tucker J, McGuire W. Epidemiology of preterm birth. *BMJ* 2004; 329: 675–678.
- Salomon LJ, Cavicchioni O, Bernard JP, Duyme M, Ville Y. Growth discrepancy in twins in the first trimester of pregnancy. *Ultrasound Obstet Gynecol* 2005; 26: 512–516.
- Dias T, Mahsud-Dornan S, Thilaganathan B, Papageorgiou A, Bhide A. First-trimester ultrasound dating of twin pregnancy: are singleton charts reliable? *BJOG* 2010; 117: 979–984.
- Chaudhuri K, Su LL, Wong PC, Chan YH, Choolani MA, Chia D, Biswas A. Determination of gestational age in twin pregnancy: Which fetal crown–rump length should be used? *J Obstet Gynaecol Res* 2013; 39: 761–765.
- Lopriore E, Sueters M, Middeldorp JM, Klumper F, Oepkes D, Vandenbussche FP. Twin pregnancies with two separate placental masses can still be monochorionic and have vascular anastomoses. *Am J Obstet Gynecol* 2006; 194: 804–808.
- National Collaborating Center for Women's and Children's Health. *Multiple Pregnancy: Evidence Update*. Commissioned by the National Institute for Clinical Excellence. NICE: Manchester, March 2013.
- Dias T, Ladd S, Mahsud-Dornan S, Bhide A, Papageorgiou A, Thilaganathan B. Systematic labelling of twin pregnancies on ultrasound. *Ultrasound Obstet Gynecol* 2011; 38: 130–133.
- Sueters M, Middeldorp JM, Lopriore E, Oepkes D, Kanhai HH, Vandenbussche FP. Timely diagnosis of twin-to-twin transfusion syndrome in monochorionic twin pregnancies by biweekly sonography combined with patient instruction to report onset of symptoms. *Ultrasound Obstet Gynecol* 2006; 28: 659–664.
- de Villiers SF, Slaghekke F, Middeldorp JM, Walther FJ, Oepkes D, Lopriore E. Placental characteristics in monochorionic twins with spontaneous versus post-laser twin anemia-polycythemia sequence. *Placenta* 2013; 34: 456–459.
- Sankaran S, Rozette C, Dean J, Kyle P, Spencer K. Screening in the presence of a vanished twin: nuchal translucency or combined screening test? *Prenat Diagn* 2011; 31: 600–601.
- Prats P, Rodríguez I, Comas C, Puerto B. Systematic review of screening for trisomy 21 in twin pregnancies in first trimester combining nuchal translucency and biochemical markers: a meta-analysis. *Prenat Diagn* 2014; 34: 1077–1083.
- Agarwal K, Alfirevic Z. Pregnancy loss after chorionic villus sampling and genetic amniocentesis in twin pregnancies: a systematic review. *Ultrasound Obstet Gynecol* 2012; 40: 128–134.
- Hansen M, Kurinczuk JJ, Milne E, de Klerk N, Bower C. Assisted reproductive technology and birth defects: a systematic review and meta-analysis. *Hum Reprod Update* 2013; 19: 330–353.
- Royal College of Obstetricians and Gynaecologists. *Amniocentesis and Chorionic Villus Sampling*. Green-Top Guideline No. 8. RCOG Press: London, 2010.
- Gallot D, Vélémir L, Delabaere A, Accoceberry M, Niro J, Vendittelli F, Laurichesse-Delmas H, Jacquetin B, Lémery D. Which invasive diagnostic procedure should we use for twin pregnancies: chorionic villous sampling or amniocentesis? *J Gynecol Obstet Biol Reprod (Paris)* 2009; 38: S39–44.
- Hui L. Non-invasive prenatal testing for fetal aneuploidy: charting the course from clinical validity to clinical utility. *Ultrasound Obstet Gynecol* 2013; 41: 2–6.
- Gil MM, Quezada MS, Revello R, Akolekar R, Nicolaides KH. Analysis of cell-free DNA in maternal blood in screening for fetal aneuploidies: updated meta-analysis. *Ultrasound Obstet Gynecol* 2015; 45: 249–266.
- Evans MI, Goldberg JD, Horenstein J, Wapner RJ, Ayoub MA, Stone J, Lipitz S, Achiron R, Holzgreve W, Brambati B, Johnson A, Johnson MP, Shalhoub A, Berkowitz RL. Selective termination for structural, chromosomal, and mendelian anomalies: international experience. *Am J Obstet Gynecol* 1999; 181: 893–897.
- Machin G. Non-identical monozygotic twins, intermediate twin types, zygosity testing, and the non-random nature of monozygotic twinning: a review. *Am J Med Genet C Semin Med Genet* 2009; 151C: 110–127.
- Lewi L, Blickstein I, Van Schoubroeck D, Gloning KP, Casteels M, Brandenburg H, Fryns JP, Deprest J. Diagnosis and management of heterokaryotypic monochorionic twins. *Am J Med Genet A* 2006; 140: 272–275.
- Lewi L, Gratacos E, Ortibus E, Van Schoubroeck D, Carreras E, Higuera T, Perapoch J, Deprest J. Pregnancy and infant outcome of 80 consecutive cord coagulations in complicated monochorionic multiple pregnancies. *Am J Obstet Gynecol* 2006; 194: 782–789.
- Fratelli N, Prefumo F, Fichera A, Valcamonica A, Marella D, Frusca T. Nuchal translucency thickness and crown rump length discordance for the prediction of outcome in monochorionic diamniotic pregnancies. *Early Hum Dev* 2011; 87: 27–30.
- Memmo A, Dias T, Mahsud-Dornan S, Papageorgiou AT, Bhide A, Thilaganathan B. Prediction of selective fetal growth restriction and twin-to-twin transfusion syndrome in monochorionic twins. *BJOG* 2012; 119: 417–421.
- Maiz N, Staboulidou I, Leal AM, Minekawa R, Nicolaides KH. Ductus venosus Doppler at 11 to 13 weeks of gestation in the prediction of outcome in twin pregnancies. *Obstet Gynecol* 2009; 113: 860–865.
- Linskens IH, de Mooij YM, Twisk JW, Kist WJ, Oepkes D, van Vugt JM. Discordance in nuchal translucency measurements in monochorionic diamniotic twins as predictor of twin-to-twin transfusion syndrome. *Twin Res Hum Genet* 2009; 12: 605–610.
- Kagan KO, Gazzoni A, Sepulveda-Gonzalez G, Sotiriadis A, Nicolaides KH. Discordance in nuchal translucency thickness in the prediction of severe twin-to-twin transfusion syndrome. *Ultrasound Obstet Gynecol* 2007; 29: 527–532.
- D'Antonio F, Khalil A, Dias T, Thilaganathan B; Southwest Thames Obstetric Research Collaborative. Crown–rump length discordance and adverse perinatal outcome in twins: analysis of the Southwest Thames Obstetric Research Collaborative (STORK) multiple pregnancy cohort. *Ultrasound Obstet Gynecol* 2013; 41: 621–626.
- D'Antonio F, Khalil A, Pagani G, Papageorgiou AT, Bhide A, Thilaganathan B. Crown–rump length discordance and adverse perinatal outcome in twin pregnancies: systematic review and meta-analysis. *Ultrasound Obstet Gynecol* 2014; 44: 138–146.
- Kalish RB, Gupta M, Perni SC, Berman S, Chasen ST. Clinical significance of first trimester crown–rump length disparity in dichorionic twin gestations. *Am J Obstet Gynecol* 2004; 191: 1437–1440.
- D'Antonio F, Khalil A, Mantovani E, Thilaganathan B; Southwest Thames Obstetric Research Collaborative. Embryonic growth discordance and early fetal loss: the STORK multiple pregnancy cohort and systematic review. *Hum Reprod* 2013; 28: 2621–2627.
- Salomon LJ, Alfirevic Z, Bilardo CM, Chalouhi GE, Ghi T, Kagan KO, Lau TK, Papageorgiou AT, Raine-Fenning NJ, Stirnemann J, Suresh S, Tabor A, Timor-Tritsch IE, Toi A, Yeo G. ISUOG practice guidelines: performance of first-trimester fetal ultrasound scan. *Ultrasound Obstet Gynecol* 2013; 41: 102–113.
- Salomon LJ, Alfirevic Z, Berghella V, Bilardo C, Hernandez-Andrade E, Johnsen SL, Kalache K, Leung KY, Malinger G, Munoz H, Prefumo F, Toi A, Lee W; ISUOG Clinical Standards Committee. Practice guidelines for performance of the routine mid-trimester fetal ultrasound scan. *Ultrasound Obstet Gynecol* 2011; 37: 116–126.
- Hall JG. Twinning. *Lancet* 2003; 362: 735–743.
- Lewi L, Jani J, Blickstein I, Huber A, Gucciardo L, Van Mieghem T, Doné E, Boes AS, Hecher K, Gratacos E, Lewi P, Deprest J. The outcome of monochorionic diamniotic twin gestations in the era of invasive fetal therapy: a prospective cohort study. *Am J Obstet Gynecol* 2008; 199: 514.e1–8.
- Baxi LV, Walsh CA. Monoamniotic twins in contemporary practice: a single-center study of perinatal outcomes. *J Matern Fetal Neonatal Med* 2010; 23: 506–510.
- International Society of Ultrasound in Obstetrics and Gynecology, Carvalho JS, Allan LD, Chaoui R, Copel JA, DeVore GR, Hecher K, Lee W, Munoz H, Paladini D, Tutschek B, Yagel S. ISUOG Practice Guidelines (updated): sonographic screening examination of the fetal heart. *Ultrasound Obstet Gynecol* 2013; 41: 348–359.
- Rossi AC, D'Addario V. Umbilical cord occlusion for selective feticide in complicated monochorionic twins: a systematic review of literature. *Am J Obstet Gynecol* 2009; 200: 123–129.
- Roman A, Papanna R, Johnson A, Hassan SS, Moldenhauer J, Molina S, Moise KJ Jr. Selective reduction in complicated monochorionic pregnancies: radiofrequency ablation vs bipolar cord coagulation. *Ultrasound Obstet Gynecol* 2010; 36: 37–41.
- Bebington MW, Danzer E, Moldenhauer J, Khalek N, Johnson MP. Radiofrequency ablation vs bipolar umbilical cord coagulation in the management of complicated monochorionic pregnancies. *Ultrasound Obstet Gynecol* 2012; 40: 319–324.
- van den Bos EM, van Klink JM, Middeldorp JM, Klumper FJ, Oepkes D, Lopriore E. Perinatal outcome after selective feticide in monochorionic twin pregnancies. *Ultrasound Obstet Gynecol* 2013; 41: 653–658.
- Griffiths PD, Sharrack S, Chan KL, Bamfo J, Williams F, Kilby MD. Fetal brain injury in survivors of twin pregnancies complicated by demise of one twin as assessed by in utero MR imaging. *Prenat Diagn* 2015; 35: 583–591.
- Conde-Agudelo A, Romero R. Prediction of preterm birth in twin gestations using biophysical and biochemical tests. *Am J Obstet Gynecol* 2014; 211: 583–595.
- Conde-Agudelo A, Romero R, Hassan SS, Yeo L. Transvaginal sonographic cervical length for the prediction of spontaneous preterm birth in twin pregnancies: a systematic review and meta-analysis. *Am J Obstet Gynecol* 2010; 203: 128.e1–12.
- Romero R, Nicolaides K, Conde-Agudelo A, Tabor A, O'Brien JM, Cetingoz E, Da Fonseca E, Creasy GW, Klein K, Rode L, Soma-Pillay P, Fusey S, Cam C, Alfirevic Z, Hassan SS. Vaginal progesterone in women with an asymptomatic sonographic short cervix in the midtrimester decreases preterm delivery and neonatal morbidity: a systematic review and metaanalysis of individual patient data. *Am J Obstet Gynecol* 2012; 206: 124.e1–19.

56. Crowther CA. Hospitalisation and bed rest for multiple pregnancy. *Cochrane Database Syst Rev* 2001; 1: CD000110.
57. Yamasmit W, Chaitongwongwatthana S, Tolosa JE, Limpongsanurak S, Pereira L, Lumbiganon P. Prophylactic oral betamimetics for reducing preterm birth in women with a twin pregnancy. *Cochrane Database Syst Rev* 2012; 9: CD004733.
58. Norman JE, Mackenzie F, Owen P, Mactier H, Hanretty K, Cooper S, Calder A, Mires G, Danielian P, Sturgiss S, MacLennan G, Tydeman G, Thornton S, Martin B, Thornton JG, Neilson JP, Norrie J. Progesterone for the prevention of preterm birth in twin pregnancy (STOPPIT): a randomised, double-blind, placebo-controlled study and meta-analysis. *Lancet* 2009; 373: 2034–2040.
59. Rafael TJ, Berghella V, Alfirevic Z. Cervical stitch (cerclage) for preventing preterm birth in multiple pregnancy. *Cochrane Database Syst Rev* 2014; 9: CD009166.
60. Crowther CA, Han S. Hospitalisation and bed rest for multiple pregnancy. *Cochrane Database Syst Rev* 2010; 7: CD000110.
61. Valsky DV, Eixarch E, Martinez JM, Crispi F, Gratacós E. Selective intrauterine growth restriction in monochorionic twins: pathophysiology, diagnostic approach and management dilemmas. *Semin Fetal Neonatal Med* 2010; 15: 342–348.
62. Sueters M, Oepkes D. Diagnosis of twin-to-twin transfusion syndrome, selective fetal growth restriction, twin anemia-polycythemia sequence, and twin reversed arterial perfusion sequence. Best practice and research. *Best Pract Res Clin Obstet Gynaecol* 2014; 28: 215–226.
63. American College of Obstetricians and Gynecologists Committee on Practice Bulletins-Obstetrics; Society for Maternal-Fetal Medicine; ACOG Joint Editorial Committee. ACOG Practice Bulletin #56: Multiple gestation: complicated twin, triplet, and high-order multifetal pregnancy. *Obstet Gynecol* 2004; 104: 869–883.
64. Breathnach F, McAuliffe F, Geary M, Daly S, Higgins J, Dornan J, Morrison JJ, Burke G, Higgins S, Dicker P, Manning F, Mahony R, Malone FD; Perinatal Ireland Research Consortium. Definition of intertwin birth weight discordance. *Obstet Gynecol* 2011; 118: 94–103.
65. D'Antonio F, Khalil A, Morlando M, Thilaganathan B. Accuracy of predicting fetal loss in twin pregnancies using gestational age-dependent weight discordance cut-offs: analysis of the STORK multiple pregnancy cohort. *Fetal Diagn Ther* 2015; 38: 22–28.
66. Lewi L, Gucciardo L, Huber A, Jani J, Van Mieghem T, Doné E, Cannie M, Gratacós E, Diemert A, Hecher K, Lewi P, Deprest J. Clinical outcome and placental characteristics of monochorionic diamniotic twin pairs with early- and late-onset discordant growth. *Am J Obstet Gynecol* 2008; 199: 511.e1–7.
67. Khalil A, D'Antonio F, Dias T, Cooper D, Thilaganathan B; Southwest Thames Obstetric Research Collaborative (STORK). Ultrasound estimation of birth weight in twin pregnancy: comparison of biometry algorithms in the STORK multiple pregnancy cohort. *Ultrasound Obstet Gynecol* 2014; 44: 210–220.
68. Stirrup OT, Khalil A, D'Antonio F, Thilaganathan B, on behalf of the Southwest Thames Obstetric Research Collaborative (STORK). Fetal growth reference ranges in twin pregnancy: analysis of the Southwest Thames Obstetric Research Collaborative (STORK) multiple pregnancy cohort. *Ultrasound Obstet Gynecol* 2015; 45: 301–307.
69. D'Antonio F, Khalil A, Dias T, Thilaganathan B; Southwest Thames Obstetric Research Collaborative (STORK). Weight discordance and perinatal mortality in twins: analysis of the Southwest Thames Obstetric Research Collaborative (STORK) multiple pregnancy cohort. *Ultrasound Obstet Gynecol* 2013; 41: 643–648.
70. Gratacós E, Lewi L, Muñoz B, Acosta-Rojas R, Hernandez-Andrade E, Martinez JM, Carreras E, Deprest J. A classification system for selective intrauterine growth restriction in monochorionic pregnancies according to umbilical artery Doppler flow in the smaller twin. *Ultrasound Obstet Gynecol* 2007; 30: 28–34.
71. Gratacós E, Carreras E, Becker J, Lewi L, Enriquez G, Perapoch J, Higuera T, Cabero L, Deprest J. Prevalence of neurological damage in monochorionic twins with selective intrauterine growth restriction and intermittent absent or reversed end-diastolic umbilical artery flow. *Ultrasound Obstet Gynecol* 2004; 24: 159–163.
72. Chalouhi GE, Marangoni MA, Quibel T, Deloison B, Benzina N, Essaoui M, Al Ibrahim A, Stirnemann JJ, Salomon LJ, Ville Y. Active management of selective intrauterine growth restriction with abnormal Doppler in monochorionic diamniotic twin pregnancies diagnosed in the second trimester of pregnancy. *Prenat Diagn* 2013; 33: 109–115.
73. Inklaar MJ, van Klink JM, Stolk TT, van Zwet EW, Oepkes D, Lopriore E. Cerebral injury in monochorionic twins with selective intrauterine growth restriction: a systematic review. *Prenat Diagn* 2014; 34: 205–213.
74. Lopriore E, Sluimers C, Pasma SA, Middeldorp JM, Oepkes D, Walther FJ. Neonatal morbidity in growth-discordant monochorionic twins: comparison between the larger and the smaller twin. *Twin Res Hum Genet* 2012; 15: 541–546.
75. Ong SSC, Zamora J, Khan KS, Kilby MD. Prognosis for the co-twin following single-twin death: a systematic review. *BJOG* 2006; 113: 992–998.
76. Hillman SC, Morris RK, Kilby MD. Co-twin prognosis after single fetal death: a systematic review and meta-analysis. *Obstet Gynecol* 2011; 118: 928–940.
77. Shek NW, Hillman SC, Kilby MD. Single-twin demise: Pregnancy outcome. *Best Pract Res Clin Obstet Gynaecol* 2014; 28: 249–263.
78. Senat MV, Couderc S, Bernard J, Ville Y. The value of middle cerebral artery peak systolic velocity in the diagnosis of fetal anemia after intrauterine death of one monochorionic twin. *Am J Obstet Gynecol* 2003; 189: 1320–1324.
79. Nicolini U, Pisoni MP, Cela E, Roberts A. Fetal blood sampling immediately before and within 24 hours of death in monochorionic twin pregnancies complicated by single intrauterine death. *Am J Obstet Gynecol* 1998; 179: 800–803.
80. Senat MV, Bernard JP, Loizeau S, Ville Y. Management of single fetal death in twin-to-twin transfusion syndrome: a role for fetal blood sampling. *Ultrasound Obstet Gynecol* 2002; 20: 360–363.
81. Nakata M, Sumie M, Murata S, Miwa I, Kusaka E, Sugino N. A case of monochorionic twin pregnancy complicated with intrauterine single fetal death with successful treatment of intrauterine blood transfusion in the surviving fetus. *Fetal Diagn Ther* 2007; 22: 7–9.
82. Quintero RA, Morales WJ, Allen MH, Bornick PW, Johnson PK, Kruger M. Staging of twin-to-twin transfusion syndrome. *J Perinatol* 1999; 19: 550–555.
83. Quintero RAM, Dickinson JE, Morales WJ, Bornick PW, Bermúdez C, Cincotta R, Chan FY, Allen MH. Stage-based treatment of twin-to-twin transfusion syndrome. *Am J Obstet Gynecol* 2003; 188: 1333–1340.
84. Roberts D, Gates S, Kilby M, Neilson JP. Interventions for twin-to-twin transfusion syndrome: a Cochrane review. *Ultrasound Obstet Gynecol* 2008; 31: 701–711.
85. Roberts D, Neilson JP, Kilby MD, Gates S. Interventions for the treatment of twin-to-twin transfusion syndrome. *Cochrane Database Syst Rev* 2014; 1: CD002073.
86. Baschat AA, Barber J, Pedersen N, Turan OM, Harman CR. Outcome after fetoscopic selective laser ablation of placental anastomoses vs equatorial laser dichorionization for the treatment of twin-to-twin transfusion syndrome. *Am J Obstet Gynecol* 2013; 209: 234.e1–8.
87. Slaghekke F, Lopriore E, Lewi L, Middeldorp JM, van Zwet EW, Weingartner AS, Klumper FJ, DeKoninck P, Devlieger R, Kilby MD, Rustico MA, Deprest J, Favre R, Oepkes D. Fetoscopic laser coagulation of the vascular equator versus selective coagulation for twin-to-twin transfusion syndrome: an open-label randomised controlled trial. *Lancet* 2014; 383: 2144–2151.
88. Raboisson MJ, Fouron JC, Lamoureux J, Leduc L, Grignon A, Proulx F, Gamache S. Early intertwin differences in myocardial performance during the twin-to-twin transfusion syndrome. *Circulation* 2004; 110: 3043–3048.
89. Michelfelder E, Gottliebson W, Border W, Kinsel M, Polzin W, Livingston J, Khoury P, Crombleholme T. Early manifestations and spectrum of living-twin cardiomyopathy in twin-to-twin transfusion syndrome: relation to Quintero stage. *Ultrasound Obstet Gynecol* 2007; 3: 965–971.
90. Ville Y. Twin-to-twin transfusion syndrome: time to forget the Quintero staging system? *Ultrasound Obstet Gynecol* 2007; 30: 924–927.
91. Huber A, Diehl W, Zikulnig L, Bregenzner T, Hackelöer BJ, Hecher K. Perinatal outcome in monochorionic twin pregnancies complicated by amniotic fluid discordance without severe twin-to-twin transfusion syndrome. *Ultrasound Obstet Gynecol* 2006; 27: 48–52.
92. Van Mieghem T, Eixarch E, Gucciardo L, Done E, Gonzales I, Van Schoubroeck D, Lewi L, Gratacós E, Deprest J. Outcome prediction in monochorionic diamniotic twin pregnancies with moderately discordant amniotic fluid. *Ultrasound Obstet Gynecol* 2011; 37: 15–21.
93. Baud D, Windrim R, Keunen J, Kelly EN, Shah P, van Mieghem T, Seaward PG, Ryan G. Fetoscopic laser therapy for twin-to-twin transfusion syndrome before 17 and after 26 weeks' gestation. *Am J Obstet Gynecol* 2013; 208: 197.e1–7.
94. Middeldorp JM, Lopriore E, Sueters M, Klumper FJ, Kanhai HH, Vandenbussche FP, Oepkes D. Twin-to-twin transfusion syndrome after 26 weeks of gestation: is there a role for fetoscopic laser surgery? *BJOG* 2007; 114: 694–698.
95. Rossi AC, D'Addario V. Survival outcomes of twin-to-twin transfusion syndrome stage I: a systematic review of literature. *Am J Perinatol* 2013; 30: 5–10.
96. Robyr R, Lewi L, Salomon LJ, Yamamoto M, Bernard JP, Deprest J, Ville Y. Prevalence and management of late fetal complications following successful selective laser coagulation of chorionic plate anastomoses in twin-to-twin transfusion syndrome. *Am J Obstet Gynecol* 2006; 194: 796–803.
97. Assaf SA, Korst LM, Chmait RH. Normalization of amniotic fluid levels after fetoscopic laser surgery for twin-to-twin transfusion syndrome. *J Ultrasound Med* 2010; 29: 1431–1436.
98. Van Mieghem T, Lewi L, Gucciardo L, Dekoninck P, Van Schoubroeck D, Devlieger R, Deprest J. The fetal heart in twin-to-twin transfusion syndrome. *Int J Pediatr* 2010; Article ID 379792, DOI: 10.1155/2010/379792.
99. Herberg U, Bolay J, Graeve P, Hecher K, Bartmann P, Breuer J. Intertwin cardiac status at 10-year follow-up after intrauterine laser coagulation therapy of severe twin-to-twin transfusion syndrome: comparison of donor, recipient and normal values. *Arch Dis Child Fetal Neonatal Ed* 2014; 99: F380–385.
100. Spruijt M, Steggerda S, Rath M, van Zwet E, Oepkes D, Walther F, Lopriore E. Cerebral injury in twin-to-twin transfusion syndrome treated with fetoscopic laser surgery. *Obstet Gynecol* 2012; 120: 15–20.
101. Weisz B, Hoffmann C, Ben-Baruch S, Yinson Y, Gindes L, Katorza E, Shrim A, Bar Yosef O, Schiff E, Lipitz S. Early detection by diffusion-weighted sequence magnetic resonance imaging of severe brain lesions after fetoscopic laser coagulation for twin-to-twin transfusion syndrome. *Ultrasound Obstet Gynecol* 2014; 44: 44–49.
102. Stirnemann JJ, Quibel T, Essaoui M, Salomon LJ, Bussières L, Ville Y. Timing of delivery following selective laser photocoagulation for twin-to-twin transfusion syndrome. *Am J Obstet Gynecol* 2012; 207: 127.e1–6.
103. Hoffmann C, Weisz B, Yinson Y, Hogen L, Gindes L, Shrim A, Sivan E, Schiff E, Lipitz S. Diffusion MRI findings in monochorionic twin pregnancies after intrauterine fetal death. *AJNR Am J Neuroradiol* 2013; 34: 212–216.
104. Quarello E, Molho M, Ville Y. Incidence, mechanisms, and patterns of fetal cerebral lesions in twin-to-twin transfusion syndrome. *J Matern Fetal Neonatal Med* 2007; 20: 589–597.
105. Hillman SC, Morris RK, Kilby MD. Co-twin prognosis after single fetal death: a systematic review and meta-analysis. *Obstet Gynecol* 2011; 118: 928–940.
106. Banek CS, Hecher K, Hackelöer BJ, Bartmann P. Long-term neurodevelopmental outcome after intrauterine laser treatment for severe twin-to-twin transfusion syndrome. *Am J Obstet Gynecol* 2003; 188: 876–880.
107. Graef C, Ellenrieder B, Hecher K, Hackelöer BJ, Huber A, Bartmann P. Long-term neurodevelopmental outcome of 167 children after intrauterine laser treatment for severe twin-to-twin transfusion syndrome. *Am J Obstet Gynecol* 2006; 194: 303–308.
108. Graeve P, Banek C, Stegmann-Woessner G, Maschke C, Hecher K, Bartmann P. Neurodevelopmental outcome at 6 years of age after intrauterine laser therapy for twin-to-twin transfusion syndrome. *Acta Paediatr* 2012; 101: 1200–1205.
109. Slaghekke F, Kist WJ, Oepkes D, Pasma SA, Middeldorp JM, Klumper FJ, Walther FJ, Vandenbussche FP, Lopriore E. Twin anemia-polycythemia sequence: diagnostic criteria, classification, perinatal management and outcome. *Fetal Diagn Ther* 2010; 27: 181–190.

110. Lopriore E, Slaghekke F, Oepkes D, Middeldorp JM, Vandenbussche FP, Walther FJ. Hematological characteristics in neonates with twin anemia-polycythemia sequence (TAPS). *Prenat Diagn* 2010; 30: 251–255.
111. Lopriore E, Slaghekke F, Oepkes D, Middeldorp JM, Vandenbussche FP, Walther FJ. Clinical outcome in neonates with twin anemia-polycythemia sequence. *Am J Obstet Gynecol* 2010; 203: 54.e1–5.
112. Lopriore E, Slaghekke F, Kersbergen KJ, de Vries LS, Drogtróp AP, Middeldorp JM, Oepkes D, Benders MJ. Severe cerebral injury in a recipient with twin anemia-polycythemia sequence. *Ultrasound Obstet Gynecol* 2013; 41: 702–706.
113. Slaghekke F, van Klink JM, Koopman HM, Middeldorp JM, Oepkes D, Lopriore E. Neurodevelopmental outcome in twin anemia-polycythemia sequence after laser surgery for twin–twin transfusion syndrome. *Ultrasound Obstet Gynecol* 2014; 44: 316–321.
114. Genova L, Slaghekke F, Klumper FJ, Middeldorp JM, Steggerda SJ, Oepkes D, Lopriore E. Management of twin anemia–polycythemia sequence using intrauterine blood transfusion for the donor and partial exchange transfusion for the recipient. *Fetal Diagn Ther* 2013; 34: 121–126.
115. Dhillon RK, Hillman SC, Pounds R, Morris RK, Kilby MD. Comparison of Solomon technique against selective laser ablation for twin–twin transfusion syndrome: a systematic review. *Ultrasound Obstet Gynecol* 2015; 46: 526–533.
116. Moore TR, Gale S, Benirschke K. Perinatal outcome of forty nine pregnancies complicated by acardiac twinning. *Am J Obstet Gynecol* 1990; 163: 907–912.
117. Wong AE, Sepulveda W. Acardiac anomaly: current issues in prenatal assessment and treatment. *Prenat Diagn* 2005; 25: 796–806.
118. Lewi L, Valencia C, Gonzalez E, Deprest J, Nicolaides KH. The outcome of twin reversed arterial perfusion sequence diagnosed in the first trimester. *Am J Obstet Gynecol* 2010; 203: 213.e1–4.
119. Tan TY, Sepulveda W. Acardiac twin: a systematic review of minimally invasive treatment modalities. *Ultrasound Obstet Gynecol* 2003; 22: 409–419.
120. Pagani G, D'Antonio F, Khalil A, Papageorghiu A, Bhide A, Thilaganathan B. Intrafetal laser treatment for twin reversed arterial perfusion sequence: cohort study and meta-analysis. *Ultrasound Obstet Gynecol* 2013; 42: 6–14.
121. Chaveeva P, Poon LC, Sotiriadis A, Kosinski P, Nicolaides KH. Optimal method and timing of intrauterine intervention in twin reversed arterial perfusion sequence: case study and meta-analysis. *Fetal Diagn Ther* 2014; 35: 267–279.
122. Benirschke K, Kim CK. Multiple pregnancy. 1. *N Engl J Med* 1973; 288: 1276–1284.
123. Prefumo F, Fichera A, Pagani G, Marella D, Valcamonica A, Frusca T. The natural history of monoamniotic twin pregnancies: a case series and systematic review of the literature. *Prenat Diagn* 2015; 35: 274–280.
124. Raphael SL. Monoamniotic twin pregnancy. A review of the literature and a report of 5 new cases. *Am J Obstet Gynecol* 1961; 81: 323–330.
125. Wensinger JA, Daly RF. Monoamniotic twins. *Am J Obstet Gynecol* 1962; 83: 1254–1256.
126. Timmons JD, Dealvarez RR. Monoamniotic twin pregnancy. *Am J Obstet Gynecol* 1963; 86: 875–881.
127. Rossi AC, Prefumo F. Impact of cord entanglement on perinatal outcome of monoamniotic twins: a systematic review of the literature. *Ultrasound Obstet Gynecol* 2013; 41: 131–135.
128. Hack KE, Derks JB, Schaap AH, Lopriore E, Elias SG, Arabin B, Eggink AJ, Sollie KM, Mol BW, Duvekot HJ, Willekes C, Go AT, Koopman-Esseboom C, Vandenbussche FP, Visser GH. Perinatal outcome of monoamniotic twin pregnancies. *Obstet Gynecol* 2009; 113: 353–360.
129. Van Mieghem T, De Heus R, Lewi L, Klaritsch P, Kollmann M, Baud D, Vial Y, Shah PS, Ranzini AC, Mason L, Raio L, Lachat R, Barrett J, Khorsand V, Windrim R, Ryan G. Prenatal management of monoamniotic twin pregnancies. *Obstet Gynecol* 2014; 124: 498–506.
130. Dias T, Mahsud-Dornan S, Bhide A, Papageorghiu AT, Thilaganathan B. Cord entanglement and perinatal outcome in monoamniotic twin pregnancies. *Ultrasound Obstet Gynecol* 2010; 35: 201–204.
131. Auriolles-Garibay A, Hernandez-Andrade E, Romero R, Garcia M, Qureshi F, Jacques SM, Ahn H, Yeo L, Chaiworapongsa T, Hassan SS. Presence of an umbilical artery notch in monochorionic/monoamniotic twins. *Fetal Diagn Ther* 2014; 36: 305–311.
132. Middeldorp JM, Klumper FJ, Oepkes D, Lopriore E, Kanhai HH, Vandenbussche FP. Selective feticide in monoamniotic twin pregnancies by umbilical cord occlusion and transection. *Fetal Diagn Ther* 2008; 23: 121–125.
133. Quintero RA, Romero R, Reich H, Gonçalves L, Johnson MP, Carreño C, Evans MI. In-utero percutaneous umbilical cord ligation in the management of complicated monochorionic multiple gestations. *Ultrasound Obstet Gynecol* 1996; 8: 16–22.
134. Valsky DV, Martinez-Serrano MJ, Sanz M, Eixarch E, Acosta ER, Martinez JM, Puerto B, Gratacós E. Cord occlusion followed by laser cord transection in monochorionic monoamniotic discordant twins. *Ultrasound Obstet Gynecol* 2011; 37: 684–688.
135. Peeters SH, Devlieger R, Middeldorp JM, DeKoninck P, Deprest J, Lopriore E, Lewi L, Klumper FJ, Kontopoulos E, Quintero R, Oepkes D. Fetal surgery in complicated monoamniotic pregnancies: case series and systematic review of the literature. *Prenat Diagn* 2014; 34: 586–591.
136. Baken L, Rousian M, Kompanje EJ, Koning AH, van der Spek PJ, Steegers EA, Exalto N. Diagnostic techniques and criteria for first-trimester conjoined twin documentation: a review of the literature illustrated by three recent cases. *Obstet Gynecol Surv* 2013; 68: 743–752.
137. Agarwal U, Dahiya P, Khosla A. Vaginal birth of conjoined thoracopagus: a rare event. *Arch Gynecol Obstet* 2003; 269: 66–67.

APPENDIX 1 Grades of recommendations and levels of evidence used in these guidelines

Classification of evidence levels

1++	High-quality meta-analyses, systematic reviews of randomized controlled trials or randomized controlled trials with very low risk of bias
1+	Well-conducted meta-analyses, systematic reviews of randomized controlled trials or randomized controlled trials with low risk of bias
1–	Meta-analyses, systematic reviews of randomized controlled trials or randomized controlled trials with high risk of bias
2++	High-quality systematic reviews of case–control or cohort studies or high-quality case–control or cohort studies with very low risk of confounding, bias or chance and high probability that the relationship is causal
2+	Well-conducted case–control or cohort studies with low risk of confounding, bias or chance and moderate probability that the relationship is causal
2–	Case–control or cohort studies with high risk of confounding, bias or chance and significant risk that the relationship is not causal
3	Non-analytical studies, e.g. case reports, case series
4	Expert opinion

Grades of recommendations

A	At least one meta-analysis, systematic review or randomized controlled trial rated as 1++ and applicable directly to the target population; or systematic review of randomized controlled trials or a body of evidence consisting principally of studies rated as 1+ applicable directly to the target population and demonstrating overall consistency of results
B	Body of evidence including studies rated as 2++ applicable directly to the target population and demonstrating overall consistency of results; or extrapolated evidence from studies rated as 1++ or 1+
C	Body of evidence including studies rated as 2+ applicable directly to the target population and demonstrating overall consistency of results; or extrapolated evidence from studies rated as 2++
D	Evidence of level 3 or 4; or evidence extrapolated from studies rated as 2+
Good practice point	Recommended best practice based on the clinical experience of the guideline development group

Erratum

Khalil A, Rodgers M, Baschat A, Bhide A, Gratacos E, Hecher K, Kilby MD, Lewi L, Nicolaides KH, Oepkes D, Raine-Fenning N. ISUOG Practice Guidelines: role of ultrasound in twin pregnancy. *Ultrasound Obstet Gynecol* 2016; **47**: 247–263.

On Page 250, there is an inconsistency between information given in Figure 3 and that in the main text. The latter correctly states that umbilical artery Doppler is recommended ‘from 20 weeks’ gestation’ whilst it is incorrectly recommended from 16 weeks in Figure 3. The correct Figure 3 is as follows:

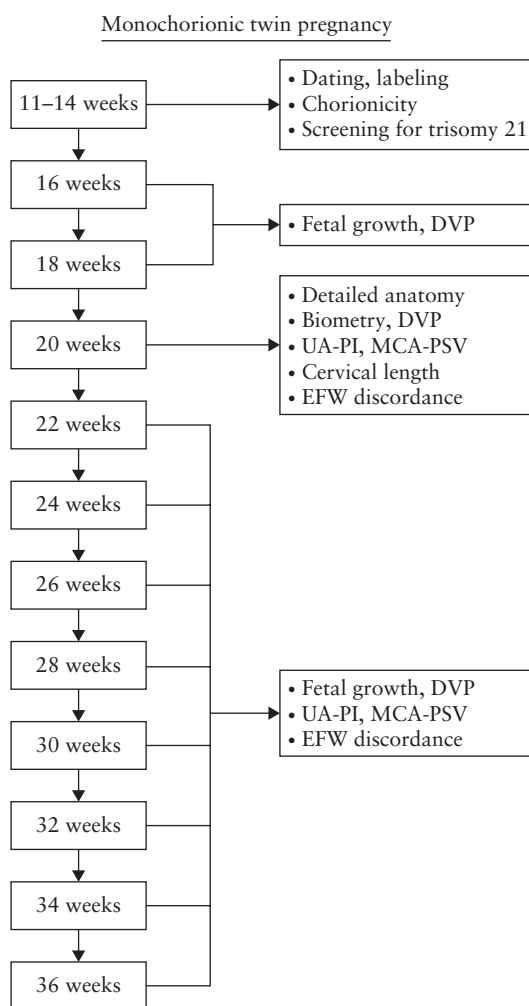


Figure 3 Ultrasound monitoring pathway in uncomplicated monochorionic twin pregnancy. DVP, deepest vertical pocket; MCA, middle cerebral artery; PI, pulsatility index; PSV, peak systolic velocity; UA, umbilical artery.

The authors apologize for this mistake.