

Prenatal diagnosis and outcome of fetal posterior fossa fluid collections

Gandolfi Colleoni G*., Contro E.*., Carletti A.*., Ghi T.*., Campobasso G.** Rembouskos G.**., Volpe G.***, Pilu G.*, Volpe P.**

From the Department of Obstetric and Gynecology, University of Bologna*, the Fetal Medicine Unit, Di Venere and Sarcone Hospitals, ASL Bari**, and the Department of Obstetrics and Gynaecology, University of Bari,***
Italy

Short title: Fetal posterior fossa fluid collections

Address for correspondence:

Prof. Gianluigi Pilu
Clinica Ostetrica e Ginecologica
Via Massarenti, 13
40138 Bologna

gianluigi.pilu@unibo.it

This article has been accepted for publication in *Ultrasound in Obstetrics & Gynecology* and is currently being edited and typeset. Readers should note that this article has been fully refereed, but has not been through the technical editing, copy-editing and proof correction process. Wiley-Blackwell and the International Society of Ultrasound in Obstetrics and Gynecology cannot be held responsible for errors or consequences arising from the use of information contained in this article; nor do the views and opinions expressed necessarily reflect those of Wiley-Blackwell or the International Society of Ultrasound in Obstetrics and Gynecology

ABSTRACT

Objective: to evaluate the accuracy of fetal imaging in differentiating posterior fossa fluid collections and to investigate the postnatal outcome of affected infants

Methods: a prospective observational study in two referral centers for prenatal diagnosis between 2001-2010; all fetuses with posterior fossa fluid collections underwent multiplanar neurosonography. Parents were also offered magnetic resonance imaging (MRI) and karyotyping. Postnatal records were reviewed.

Results: 105 fetuses were seen at a mean gestational age of 24 weeks (range 17-28). Sonographic diagnoses (Blake's pouch cyst in 32 cases, megacisterna magna in 27, Dandy-Walker malformation in 26, vermian hypoplasia in 17, cerebellar hypoplasia in 2, and arachnoid cyst in 1) were accurate in 87% of cases. MRI proved more informative only in 1/51 cases. Anatomic anomalies and/or chromosomal aberrations were found in 45%. Blake's pouch cysts and megacisterna magna underwent spontaneous resolution in utero in one third of cases and over 90% of survivors without associated anomalies demonstrated a normal developmental outcome at 1-5 years. Isolated Dandy-Walker malformation and vermian hypoplasia had a normal development only in 50% of cases.

Conclusions: Prenatal neurosonography and MRI are similarly accurate in the categorization of posterior fossa fluid collections since early gestation. Blake's pouch cyst and megacisterna magna are a risk factor for associated anomalies but when isolated have an excellent prognosis, with a high probability of intrauterine resolution and a normal intellectual development in almost all cases. Conversely, Dandy-Walker malformation and vermian hypoplasia even when they appear isolated antenatally have an abnormal outcome in half of the cases.

Key words: fetus, ultrasound, prenatal diagnosis, Cerebellar anomalies, Dandy-Walker malformation, Megacisterna magna,

Introduction

Abnormal fluid collections in the fetal posterior fossa encompass a wide spectrum of different entities, ranging from normal variants to severe anomalies.¹ They may have a similar anatomic as well as sonographic appearance, and diagnostic errors with significant implications on counselling and management have been described.²

More recently, several reports have shed some light on the normal and abnormal development of the posterior fossa contents, leading to a new clinical classification of fluid collections.³⁻⁷

In addition new advances in prenatal imaging have allowed a more detailed evaluation of fetal posterior fossa contents since early gestation.^{3, 6-14}

The aim of our study was to evaluate the diagnostic accuracy of fetal neurosonography¹⁵ and magnetic resonance imaging (MRI) and to assess the outcome of affected infants.

Patients and Methods

This was a prospective observational study conducted in 2 referral centers for prenatal diagnosis between December 2001 and January 2010. All fetuses diagnosed with an abnormal fluid collection in the posterior fossa were included. In all cases a detailed neurosonographic evaluation, including multiplanar visualization of the posterior fossa, was performed as previously described.^{6, 8, 12, 14-16} The categorization of sonographic findings was based on recent studies,^{3, 4, 7} and is summarized in Table 1 and Figure 1. In each case we attempted to evaluate the integrity of the cerebellar vermis, as this has been reported to have a major impact on the outcome.^{9, 17} Whenever possible, prenatal MRI was also performed and fetal karyotype was obtained. Prenatal diagnosis was compared with autopsy or postnatal MRI. A detailed follow-up was attempted in each case by consultation of medical records, interview with the parents and the paediatricians taking care of the infants.

Results

A total of 105 fetuses were included into the study. (Table 2) Mean gestational age at diagnosis was 24 weeks (range 17-28 weeks). Associated malformations were found in 48 cases (45%): other cerebral abnormalities in 23, chromosomal aberrations in 9 (3 trisomies 18, 2 trisomies 21, 1 trisomy 13, 1 triploidy, 1 unbalanced translocation, 1 mosaic 45X/46XX) and genetic syndromes in 3 (1 case each of Opitz, Phace and oral-facial-digital syndrome). In two cases the associated anomalies were only discovered after birth. The greatest difficulties we encountered in the sonographic categorization of posterior fossa fluid collections included the assessment of the position of the torcular and the evaluation of the integrity of the cerebellar vermis. The torcular Herophili is not clearly imaged with sonography due to acoustic shadowing from the skull bones and we inferred its position by observing the angulation of the tentorium (Figure 2). To evaluate the cerebellar vermis we used a combination of qualitative findings (visualization of fastigium and fissures)^{3, 6, 13, 14} as well as biometry.^{8, 10} Nevertheless we were frequently uncertain about vermian integrity, particularly in the context of Dandy-Walker malformation, because of upward compression from the posterior fossa cyst (Figure 3).

Twenty-five cases (25%) were lost at follow-up because parents refused to provide information, could not be reached, or autopsy reports were not available. Intrauterine regression of the posterior fossa abnormal findings was noted in 25% of cases. Of the remaining 67 cases, prenatal diagnosis was confirmed postnatally in 87%. There was one false positive of vermian hypoplasia and 7 incorrect diagnoses (Table 3). In at least two of these cases, the presence of cortical malformations that had escaped prenatal diagnosis resulted in a worst outcome than predicted antenatally.

The earliest diagnosis of a posterior fossa fluid collection was made with sonography at 17 weeks. At this time a considerable superior rotation of the vermis was noted. At 21 weeks a final diagnosis of Dandy-Walker malformation was made, with a seemingly intact cerebellar vermis (Figure 4). The fetal karyotype was normal, no other anomalies were identified, and the parents elected to continue the pregnancy. After birth a diagnosis of Opitz syndrome was made.

One fetus was diagnosed in utero with a Dandy Walker malformation by both ultrasound and MR and was found to have after termination of pregnancy a severe posterior fossa hemorrhage with secondary hydrocephalus (Figure 5).

Modifications of the sonographic findings throughout gestation were noted in several cases. Most frequently this consisted in the resolution of a Blake's pouch cyst or megacisterna magna. In at least one case however the interpretation of the sonographic findings was difficult at midgestation. An elevated but seemingly intact cerebellar vermis with a normal torcular was initially seen at 21 weeks, and a tentative diagnosis of Blake's pouch cyst was made. At 25 weeks however an expansion of the posterior fossa with elevation of the torcular was noted indicating a Dandy-Walker malformation that was confirmed by prenatal MR as well as postnatally (Figure 6). One fetus with cerebellar hypoplasia and associated cortical malformation had an unremarkable sonogram at 21 weeks' gestation.

Fetal MRI was performed in 51 cases at a mean gestational age of 26 weeks (range 22-34) with results very similar to sonography, providing a more accurate diagnosis in only one case (table 3). The main advantage of MRI was a better visualization of the torcular compared with ultrasound, while assessment of the integrity of the vermis remained difficult, particularly in early gestation (Figure 7).

At a follow-up of 1-5 years, an abnormal development was more common in cases with associated anomalies (46% versus 18% of cases). About 90% of foetuses with either Blake's pouch cyst or megacisterna magna and no associated anomalies had a normal neurologic development compared with only 50% of those with Dandy-Walker malformation and vermian hypoplasia (Table 4).

DISCUSSION

We believe that the most relevant result of our study is the demonstration that fetal neurosonography allows to categorize accurately since early gestation fluid collections of the fetal posterior fossa and to distinguish entities that have different clinical implications.

In our hands, prenatal diagnosis with sonography was correct in almost 90% of cases. We believe that the reason for the improvement in accuracy over previous studies^{1,2} depends upon the use of a multiplanar approach and particularly upon the documentation of the midsagittal plane, which is essential for the evaluation of the posterior fossa contents.^{3,5,11}

Caution is warranted in diagnosing cerebellar anomalies in early gestation because of the incomplete development of the cerebellar vermis¹⁸⁻²⁰, however, with meticulous scanning, we have been able to document Dandy-Walker malformation since 17 weeks.

Categorization of posterior fossa fluid collections has clinical relevance. Blake's pouch cyst and megacisterna magna, the most frequent diagnoses in our series, had a similar and much more favourable outcome than Dandy-Walker malformation and vermian hypoplasia. They were less frequently associated with other anomalies, underwent spontaneous resolution throughout gestation in one third of cases and when they were not associated with other anatomic or chromosomal anomalies demonstrated a normal postnatal neurodevelopment in about 90% of cases. This is well correlated with previous studies and suggest when isolated these conditions should probably be regarded as normal variants.^{11,21}

The term Blake's pouch cyst was originally introduced in infantile neuroradiology to indicate a type of obstructive hydrocephalus secondary to failure of formation of the foramen of Magendie and Luschka, resulting in a compressive cyst of the posterior fossa displacing superiorly the cerebellar vermis.²²⁻²⁴ More recently, the term has become popular in fetal imaging studies to indicate cases with a posterior fossa cyst displacing superiorly an intact cerebellar vermis, typically in association with a normal ventricular system and a normal size of the posterior fossa.^{3,7,11,13} This finding has been interpreted as failed or delayed regression of the Blake's pouch, an embryological structure continuous with the fourth ventricle. The entity described in the original neonatal studies and the one later described in fetal studies are likely to be different, as the latter has typically a normal outcome and appears to be rarely associated with ventriculomegaly. Megacisterna magna may be a variation of the Blake's pouch cyst.⁷ From a clinical perspective, the two conditions have many similarities.

Dandy-Walker malformation and vermian hypoplasia (previously referred to as Dandy-Walker variant)⁴ have been the subject of many postnatal and fetal studies and are probably the best known of posterior fossa cystic lesions.^{1, 6, 9, 16, 17, 25, 26} In agreement with previous studies, we have found a high proportion of multiple anomalies and abnormal neurodevelopment in these cases. It has been suggested that the prognosis of Dandy-Walker malformation is related to the anatomy of the vermis. Patients with a normal lobulation on MR had no associated brain malformation and demonstrated a better outcome.^{9, 17} However, assessing the morphology of the vermis in our cases was usually challenging because of the significant mass effect of the cyst, and we were frequently uncertain (Figure 3). As previously reported, posterior fossa hemorrhage may mimic dandy-Walker malformation.²⁷

Intrauterine evolution of posterior fossa fluid collections occurs frequently. Apart from the frequent disappearance of Blake's pouch cyst and megacisterna magna, in Dandy-Walker malformation posterior fossa expansion may occur late in gestation (Figure 4). As previously reported cerebellar hypoplasia may be manifest only in the third trimester.⁶

The relative accuracy of prenatal ultrasound versus MR is debated.^{28, 29} Similarly to others, we have found that when multiplanar sonography is satisfyingly obtained, MR rarely adds significant information, particularly at midgestation.²⁹ We suggest that MRI has the greatest advantage over sonography to better visualize the position of the torcular, an important finding to recognize Dandy-Walker malformation. Conversely, we have found that the assessment of the integrity of the vermis remains difficult with both techniques, particularly in early gestation. Indeed, the only false positive in our series was a diagnosis of vermian hypoplasia by both ultrasound and MRI. Similar difficulties were previously reported.^{30, 31} It should also be stressed that vermian hypoplasia may occur without the presence of a fluid collection and this complicates further the identification of this condition.⁶

To our knowledge this is the largest prospective series published thus far of posterior fossa fluid collections recognized in utero and we believe that our results provide useful information for the assessment and counselling of these cases. We do however acknowledge the limitations of our study, that are similar to those commonly encountered in clinical series of prenatal diagnosis of abnormal cerebral findings.³² About one quarter of our patients were lost to follow-up, and the postnatal assessment of survivors was performed by different pediatricians who did not use a standard protocol. This must certainly be kept in mind while interpreting our data.

In conclusion, ultrasound and fetal MRI perform similarly in the characterization of fetal posterior fossa abnormalities, and a correct diagnosis is made in about 90% of cases.

Megacisterna magna and Blake's pouch cysts are the most common antenatal diagnoses. These are frequently associated with other anatomic or chromosomal anomalies but when isolated have a good chance of intrauterine resolution and anyhow demonstrate a normal developmental outcome in over 90% of cases. Dandy-Walker malformation and vermian hypoplasia have a guarded prognosis, with a very high likelihood of associated anomalies and/or neurologic impairment.

REFERENCES

1. Bolduc ME, Limperopoulos C. Neurodevelopmental outcomes in children with cerebellar malformations: a systematic review. *Dev Med Child Neurol* 2009;51(4):256-67.
2. Carroll SG, Porter H, Abdel-Fattah S, Kyle PM, Soothill PW. Correlation of prenatal ultrasound diagnosis and pathologic findings in fetal brain abnormalities. *Ultrasound Obstet Gynecol* 2000;16(2):149-53.
3. Adamsbaum C, Moutard ML, Andre C, Merzoug V, Ferey S, Quere MP, Lewin F, Fallet-Bianco C. MRI of the fetal posterior fossa. *Pediatr Radiol* 2005;35(2):124-40.
4. Barkovich AJ, Millen KJ, Dobyns WB. A developmental and genetic classification for midbrain-hindbrain malformations. *Brain* 2009;132(Pt 12):3199-230.
5. Guibaud L, des Portes V. Plea for an anatomical approach to abnormalities of the posterior fossa in prenatal diagnosis. *Ultrasound Obstet Gynecol* 2006;27(5):477-81.
6. Malinger G, Lev D, Lerman-Sagie T. The fetal cerebellum. Pitfalls in diagnosis and management. *Prenat Diagn* 2009;29(4):372-80.
7. Robinson AJ, Goldstein R. The cisterna magna septa: vestigial remnants of Blake's pouch and a potential new marker for normal development of the rhombencephalon. *J Ultrasound Med* 2007;26(1):83-95.
8. Achiron R, Kivilevitch Z, Lipitz S, Gamzu R, Almog B, Zalel Y. Development of the human fetal pons: in utero ultrasonographic study. *Ultrasound Obstet Gynecol* 2004;24(5):506-10.
9. Klein O, Pierre-Kahn A, Boddaert N, Parisot D, Brunelle F. Dandy-Walker malformation: prenatal diagnosis and prognosis. *Childs Nerv Syst* 2003;19(7-8):484-9.
10. Malinger G, Ginath S, Lerman-Sagie T, Watemberg N, Lev D, Glezerman M. The fetal cerebellar vermis: normal development as shown by transvaginal ultrasound. *Prenat Diagn* 2001;21(8):687-92.
11. Zalel Y, Gilboa Y, Gabis L, Ben-Sira L, Hoffman C, Wiener Y, Achiron R. Rotation of the vermis as a cause of enlarged cisterna magna on prenatal imaging. *Ultrasound Obstet Gynecol* 2006;27(5):490-3.
12. Pilu G, Ghi T, Carletti A, Segata M, Perolo A, Rizzo N. Three-dimensional ultrasound examination of the fetal central nervous system. *Ultrasound Obstet Gynecol* 2007;30(2):233-45.
13. Pilu G, Segata M, Ghi T, Carletti A, Perolo A, Santini D, Bonasoni P, Tani G, Rizzo N. Diagnosis of midline anomalies of the fetal brain with the three-dimensional median view. *Ultrasound Obstet Gynecol* 2006;27(5):522-9.
14. Zalel Y, Yagel S, Achiron R, Kivilevich Z, Gindes L. Three-dimensional ultrasonography of the fetal vermis at 18 to 26 weeks' gestation: time of appearance of the primary fissure. *J Ultrasound Med* 2009;28(1):1-8.
15. ISUOG. Sonographic examination of the fetal central nervous system: guidelines for performing the 'basic examination' and the 'fetal neurosonogram'. *Ultrasound Obstet Gynecol* 2007;29(1):109-16.
16. Paladini D, Volpe P. Posterior fossa and vermian morphometry in the characterization of fetal cerebellar abnormalities: a prospective three-dimensional ultrasound study. *Ultrasound Obstet Gynecol* 2006;27(5):482-9.
17. Boddaert N, Klein O, Ferguson N, Sonigo P, Parisot D, Hertz-Pannier L, Baraton J, Emond S, Simon I, Chigot V, Schmit P, Pierre-Kahn A, Brunelle F. Intellectual prognosis of

- the Dandy-Walker malformation in children: the importance of vermian lobulation. *Neuroradiology* 2003;45(5):320-4.
18. Babcook CJ, Chong BW, Salamat MS, Ellis WG, Goldstein RB. Sonographic anatomy of the developing cerebellum: normal embryology can resemble pathology. *AJR Am J Roentgenol* 1996;166(2):427-33.
 19. Bromley B, Nadel AS, Pauker S, Estroff JA, Benacerraf BR. Closure of the cerebellar vermis: evaluation with second trimester US. *Radiology* 1994;193(3):761-3.
 20. Laing FC, Frates MC, Brown DL, Benson CB, Di Salvo DN, Doubilet PM. Sonography of the fetal posterior fossa: false appearance of mega-cisterna magna and Dandy-Walker variant. *Radiology* 1994;192(1):247-51.
 21. Dror R, Malinger G, Ben-Sira L, Lev D, Pick CG, Lerman-Sagie T. Developmental outcome of children with enlargement of the cisterna magna identified in utero. *J Child Neurol* 2009;24(12):1486-92.
 22. Calabro F, Arcuri T, Jenkins JR. Blake's pouch cyst: an entity within the Dandy-Walker continuum. *Neuroradiology* 2000;42(4):290-5.
 23. Cornips EM, Overvliet GM, Weber JW, Postma AA, Hoeberigs CM, Baldewijns MM, Vles JS. The clinical spectrum of Blake's pouch cyst: report of six illustrative cases. *Childs Nerv Syst*;26(8):1057-64.
 24. Tortori-Donati P, Fondelli MP, Rossi A, Carini S. Cystic malformations of the posterior cranial fossa originating from a defect of the posterior membranous area. Mega cisterna magna and persisting Blake's pouch: two separate entities. *Childs Nerv Syst* 1996;12(6):303-8.
 25. Has R, Ermis H, Yuksel A, Ibrahimoglu L, Yildirim A, Sezer HD, Basaran S. Dandy-Walker malformation: a review of 78 cases diagnosed by prenatal sonography. *Fetal Diagn Ther* 2004;19(4):342-7.
 26. Pilu G, Visentin A, Valeri B. The Dandy-Walker complex and fetal sonography. *Ultrasound Obstet Gynecol* 2000;16(2):115-7.
 27. Yuksel A, Batukan C. Fetal cerebellar hemorrhage in a severely growth-restricted fetus: natural history and differential diagnosis from Dandy-Walker malformation. *Ultrasound Obstet Gynecol* 2003;22(2):178-81.
 28. Levine D, Barnes PD, Robertson RR, Wong G, Mehta TS. Fast MR imaging of fetal central nervous system abnormalities. *Radiology* 2003;229(1):51-61.
 29. Malinger G, Lev D, Lerman-Sagie T. Is fetal magnetic resonance imaging superior to neurosonography for detection of brain anomalies? *Ultrasound Obstet Gynecol* 2002;20(4):317-21.
 30. Limperopoulos C, Robertson RL, Estroff JA, Barnewolt C, Levine D, Bassan H, du Plessis AJ. Diagnosis of inferior vermian hypoplasia by fetal magnetic resonance imaging: potential pitfalls and neurodevelopmental outcome. *Am J Obstet Gynecol* 2006;194(4):1070-6.
 31. Limperopoulos C, Robertson RL, Jr., Khwaja OS, Robson CD, Estroff JA, Barnewolt C, Levine D, Morash D, Nemes L, Zaccagnini L, du Plessis AJ. How accurately does current fetal imaging identify posterior fossa anomalies? *AJR Am J Roentgenol* 2008;190(6):1637-43.
 32. Melchiorre K, Bhide A, Gika AD, Pilu G, Papageorghiou AT. Counseling in isolated mild fetal ventriculomegaly. *Ultrasound Obstet Gynecol* 2009;34(2):212-24.

Table 1: categorization of posterior fossa fluid collections

| Findings | Diagnosis |
|--|--------------------------------|
| Upward rotation of an intact vermis with normal torcular | Blake's pouch cyst |
| Cisterna magna depth > 10 mm with intact and normally positioned cerebellum | Megacisterna magna |
| Hypoplastic vermis with normal torcular | Vermian hypoplasia |
| Upward rotation of the vermis (normal or hypoplastic) with elevated torcular | Dandy-Walker malformation |
| Large cisterna magna with small cerebellum | Cerebellar hypoplasia |
| Cyst with a mass effect resulting in distortion of the cerebellum | Posterior fossa arachnoid cyst |

Table 2. Sonography of posterior fossa abnormalities, associations with other anomalies, intrauterine regression, and accuracy of prenatal diagnosis

| Prenatal sonographic diagnosis | Cases | Associated Anomalies | Lost at follow-up | Regression in utero | Sonographic diagnosis confirmed postnatally |
|--------------------------------|-------|----------------------|-------------------|---------------------|---|
| Blake's pouch cyst | 32 | 8 | 3 | 11/27 | 17/18 |
| Megacisterna magna | 27 | 9 | 4 | 6/21 | 16/17 |
| Dandy Walker | 26 | 16(1*) | 7 | 0/8 | 16/19 |
| Vermian hypoplasia | 17 | 11(1*) | 9 | 0/8 | 6/8 |
| Cerebellar hypoplasia | 2 | 2 | 0 | 0/2 | 2/2 |
| Arachnoid cyst | 1 | 0 | 0 | 0/1 | 1/1 |
| TOT | 105 | 46 (2#) | 23 | 17/67 (25%) | 57/65 (87 %) |

* diagnosed at birth

Table 3. Discordancies between fetal sonographic and MRI diagnoses and postnatal diagnoses

| Sonography | Fetal MRI | Postnatal diagnosis |
|---------------------------|---------------------------|---|
| Blake's pouch cyst | Blake's pouch cyst | Arachnoid cyst |
| Blake's pouch cyst | Megacisterna magna | Megacisterna magna |
| Megacisterna magna | Megacisterna magna | Arachnoid cyst |
| Dandy-Walker malformation | Dandy-Walker malformation | Dandy-Walker malformation and cortical malformation |
| Dandy-Walker malformation | Dandy-Walker malformation | Joubert syndrome |
| Dandy-Walker malformation | Dandy-Walker malformation | Hemorrhage |
| Vermian hypoplasia | Vermian hypoplasia | Vermian hypoplasia and cortical malformation |
| Vermian hypoplasia | Vermian hypoplasia | Normal brain |

Table 4. Outcome of fetal posterior fossa fluid collections

| Prenatal sonographic diagnosis | Termination of pregnancy | Survivors with abnormal development (isolated finding) | Survivors with abnormal development (associated anomalies) |
|--------------------------------|--------------------------|--|--|
| Blake's pouch cyst | 2/32 | 1/20 | 1/5 |
| Megacisterna magna | 2/27 | 2/16 | 1/4 |
| Dandy Walker | 11/26 | 3/5 | 2/2* |
| Vermian hypoplasia | 2/17 | 1/3 | 2/2* |
| Cerebellar hypoplasia | 2/2 | 0 | 0 |
| Arachnoid cyst | 0/1 | 1/1 | 0 |
| TOTAL | 19/105 (18%) | 8/45 (18%) | 6/13 (43%) |

* in one case the presence of associated anomalies was only detected postnatally

LEGENDS TO FIGURES

Figure 1. Categorization of posterior fossa fluid collections: a,b) Blake's pouch cyst; c,d) megacisterna magna; e,f) vermian hypoplasia; g,h) Dandy-Walker malformation; i,j) cerebellar hypoplasia; k,l) arachnoid cyst of the posterior fossa

Figure 2. The position of the torcular *Herophili* (arrows) is inferred by the direction of the tentorium cerebelli. In a) the torcular is found in a normal position, at about the same level as the site of insertion of the neck muscles on the posterior skull; this is a Blake's pouch cyst. In b) the torcular is displaced higher than usual, indicating that this is a Dandy Walker malformation.

Figure 3. Dandy-Walker malformation in a 21 weeks' fetus. The transvaginal sonogram (a) fails to demonstrate the anatomic landmarks of the cerebellar vermis (arrow), fastigium and fissures, and we were uncertain whether this reflected hypoplasia or not. After termination of pregnancy, autopsy revealed a normally lobulated vermis (b).

Figure 4. This patient was referred at 17 weeks because of an abnormal appearance of the posterior fossa. The axial scan (a) revealed an open fourth ventricle (arrow), a normal finding prior to midgestation. However, the transvaginal sagittal scan (b) identified a greater than usual rotation of the cerebellum vermis (arrow) and a high-positioned tentorium, and we favoured the hypothesis of a posterior fossa malformation. At 20 weeks (c) Dandy-Walker malformation was confirmed.

Figure 5. This patient was referred because of severe ventriculomegaly. Additional findings included a posterior fossa fluid collection with superior displacement of the cerebellar vermis (a) and the absence of the septum pellucidum (b), which were confirmed by MR (c,d). A diagnosis of Dandy-Walker malformation with obstructive hydrocephalus and absence or disruption of the septum pellucidum was considered. After termination of pregnancy a severe cerebellar hemorrhage was demonstrated. On retrospect, the normal position of the tentorium was in contrast with the diagnosis of Dandy-Walker malformation. A T₁-weighted MR sequence was not obtained, while it would easily demonstrate the presence of blood in the posterior fossa.

Figure 6. This patient was referred at 20 weeks' gestation. The transvaginal sonogram demonstrated moderate elevation of the cerebellar vermis but the cisterna magna was not felt to be enlarged and the downslanting tentorium (arrow) suggested a normal position of the torcular. At 24 weeks (b) the

cisterna magna had increased in size, the rotation of the vermis was increased and the angle formed by the tentorium (arrow) suggested an upward displacement of the torcular. At this time, a diagnosis of Dandy-Walker malformation was made and this was confirmed by the prenatal (c) as well as postnatal MRI (d).

Figure 7. fetal MRI demonstration of the torcular. In a) a fetus with Blake's pouch cyst is seen to have the torcular (white arrow) implanted close to the insertion of the neck muscles (black arrow). In b) a fetus with Dandy-Walker malformation has an obvious upward displacement of the torcular (white arrow) compared with the neck muscles (black arrow). Notice also the greater size of the cisterna magna and the increased rotation of the cerebellar vermis compared with a).

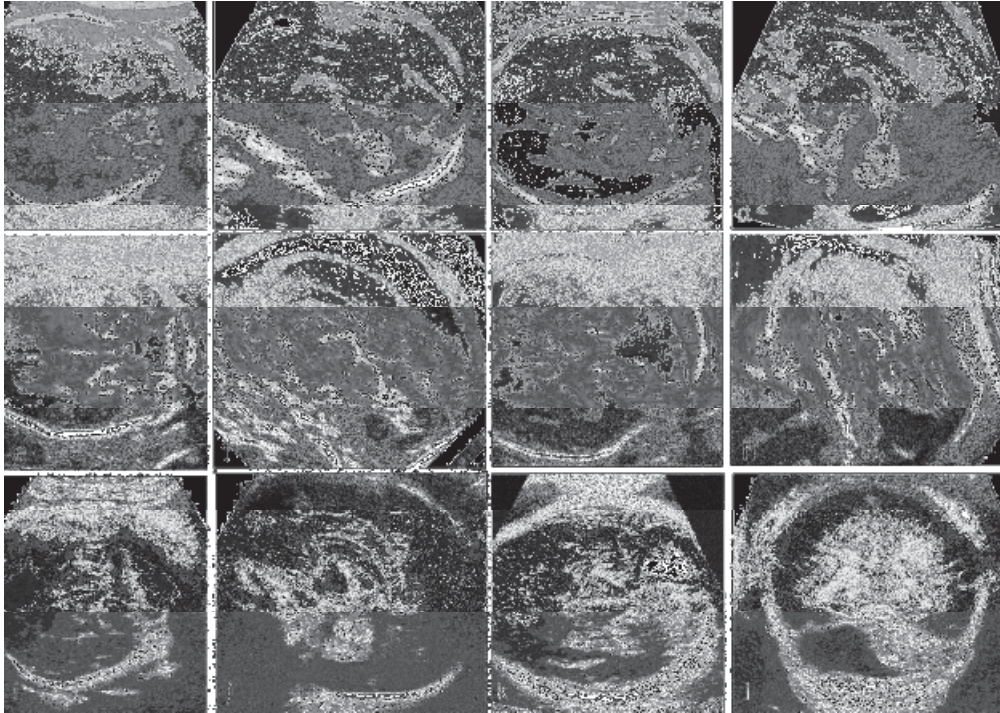


Figure 1. Categorization of posterior fossa fluid collections: a,b) Blake's pouch cyst; c,d) megacisterna magna; e,f) vermian hypoplasia; g,h) Dandy-Walker malformation; i,j) cerebellar hypoplasia; k,l) arachnoid cyst of the posterior fossa

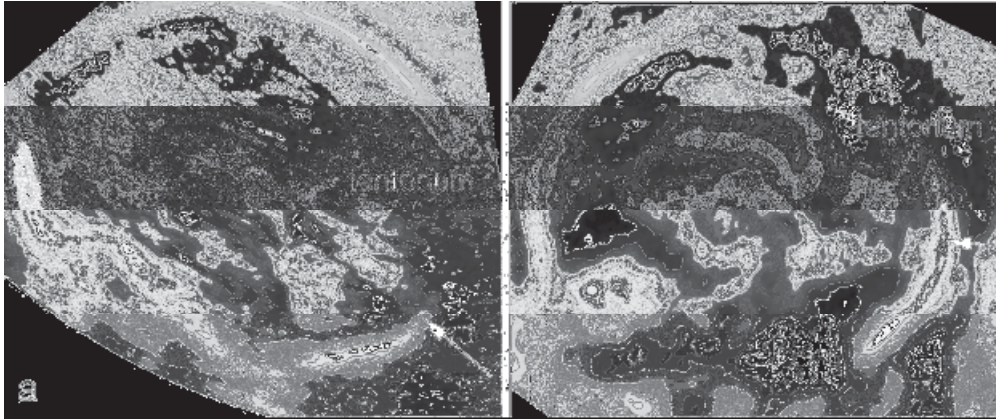


Figure 2. The position of the torcular Herophili (arrow) is inferred by the direction of the tentorium cerebelli. In a) the torcular is found in a normal position, at about the same level as the site of insertion of the neck muscles on the posterior skull; this is a Blake's pouch cyst. In b) the torcular is displaced higher than usual, indicating that this is a Dandy Walker malformation.

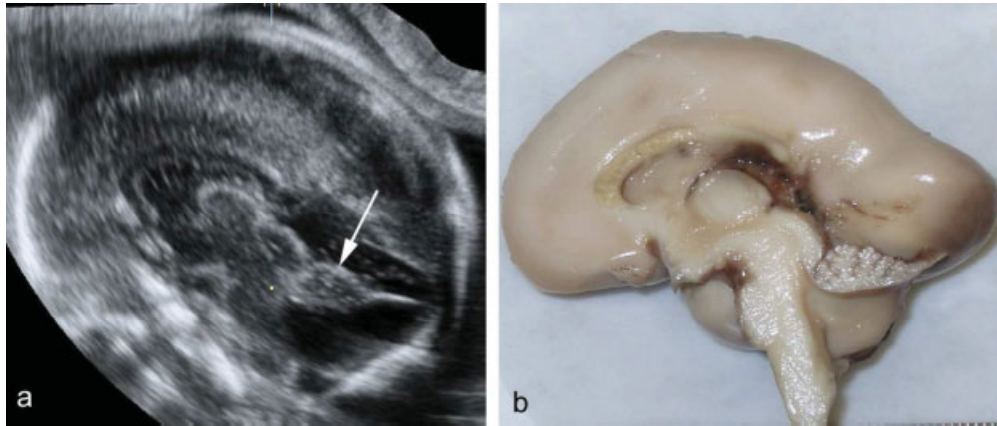


Figure 3. Dandy-Walker malformation in a 21 weeks' fetus. The transvaginal sonogram (a) fails to demonstrate the anatomic landmarks of the cerebellar vermis (arrow), fastigium and fissures, and we were uncertain whether this reflected hypoplasia or not. After termination of pregnancy, autopsy revealed a normally lobulated vermis (b).

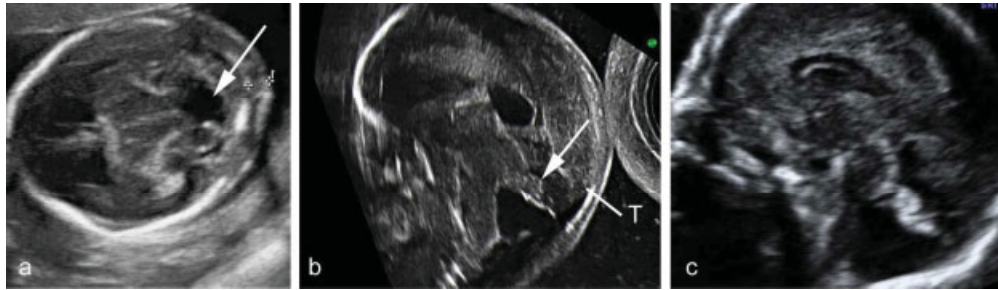


Figure 4. This patient was referred at 17 weeks because of an abnormal appearance of the posterior fossa. The axial scan (a) revealed an open fourth ventricle (arrow), a normal finding prior to midgestation. However, the transvaginal sagittal scan (b) identified a greater than usual rotation of the cerebellum vermis (arrow) and a high-positioned tentorium, and we favoured the hypothesis of a posterior fossa malformation. At 20 weeks (c) Dandy-Walker malformation was confirmed.

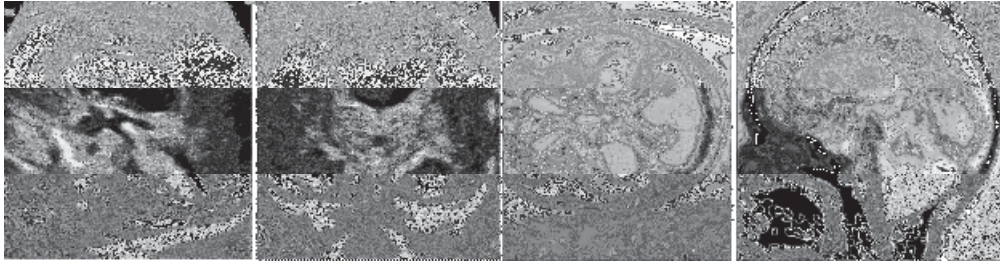


Figure 5. This patient was referred because of severe ventriculomegaly. Additional findings included a posterior fossa fluid collection with superior displacement of the cerebellar vermis (a) and the absence of the septum pellucidum (b), which were confirmed by MR (c,d). A diagnosis of Dandy-Walker malformation with obstructive hydrocephalus and absence or disruption of the septum pellucidum was considered. After termination of pregnancy a severe cerebellar hemorrhage was demonstrated. On retrospect, the normal position of the tentorium was in contrast with the diagnosis of Dandy-Walker malformation. A T1 MR sequence was not obtained, while it would easily demonstrate the presence of blood in the posterior fossa.

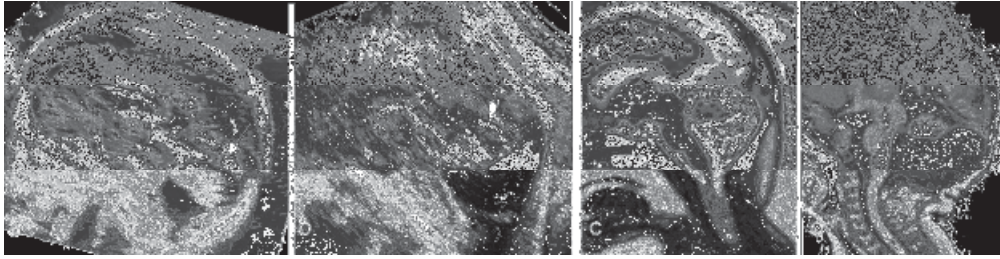


Figure 6. This patient was referred at 20 weeks' gestation. The transvaginal sonogram demonstrated moderate elevation of the cerebellar vermis but the cisterna magna was not felt to be enlarged and the downslanting tentorium (arrow) suggested a normal position of the torcular. At 24 weeks (b) the cisterna magna had increased in size, the rotation of the vermis was increased and the torcular was upwardly displaced. At this time, a diagnosis of Dandy-Walker malformation was made and this was confirmed by the prenatal (c) as well as postnatal MRI (d).

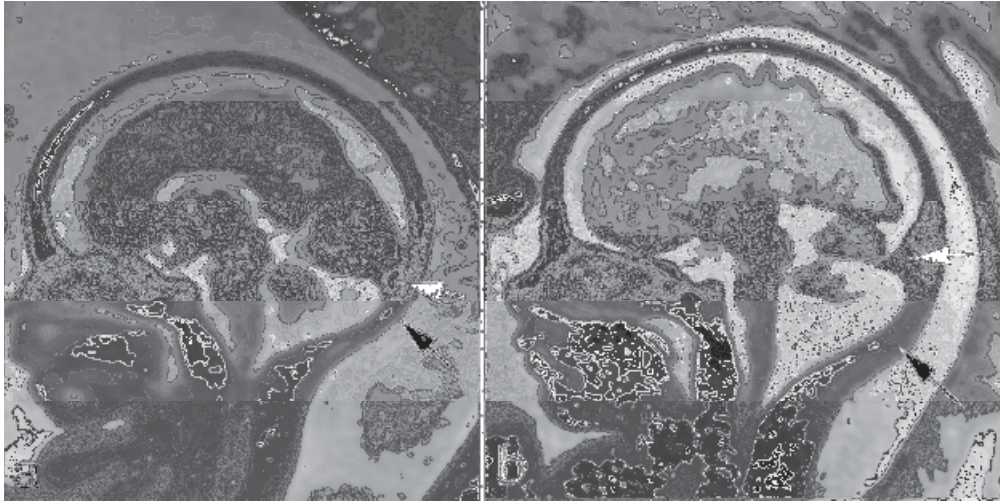


Figure 7. fetal MRI demonstration of the torcular. In a) a fetus with Blake's pouch cyst is seen to have the torcular (white arrow) implanted close to the insertion of the neck muscles (black arrow). In b) a fetus with Dandy-Walker malformation has an obvious upward displacement of the torcular (white arrow) compared with the neck muscles (black arrow). Notice also the greater size of the cisterna magna and the increased rotation of the cerebellar vermis compared with a).