



ISUOG Basic Training

The 20 + 2 Planes Approach to the Routine
Mid Trimester Scan

Learning objective

At the end of the lecture you will be able to:

- Explain how to perform a structured routine examination, including measurements, of the mid trimester fetus using the 2 overview & 20 planes approach

Key questions

1. What is the rationale behind the 2 overview & 20 planes (20+2) approach?
2. What are the 20+2 planes?
3. How do the planes relate to the ISUOG BT recommendations?
4. What abnormalities should be excluded when the 20+2 planes approach is performed correctly?

What is the rationale behind the 20 + 2 approach?

To provide a structured & logical method of examining the mid-trimester fetus by:

- Performing an anatomical review within the anatomical planes from which we obtain fetal biometry that also has the potential to exclude 50 fetal abnormal appearances.
 - Biparietal diameter (BPD)
 - Head circumference (HC)
 - Abdominal circumference (AC)
 - Femur length (FL)

What are the 20 + 2 planes?

- A combination of 2 overview sweeps & 20 planes of the fetus
- Each plane relates to a specific fetal section or view
- Measurement(s) to be taken* are included
- Each plane has a number of structures to be evaluated*
- Criteria for referral are included
- A combination that enable the potential exclusion of 50 abnormal fetal appearances**

* reference documents – ISUOG guidelines

** including a number of findings where interpretation as an abnormality will be decided locally

How do the planes relate to the ISUOG BT recommendations?

Reference documents:

Ultrasound Obstet Gynecol 2014; 43: 113-116
Published online in Wiley Online Library (wileyonlinelibrary.com). DOI: 10.1002/uog.12403

Ultrasound Obstet Gynecol 2011; 37: 116-126
Published online in Wiley Online Library (wileyonlinelibrary.com). DOI: 10.1002/uog.12403

Ultrasound Obstet Gynecol 2007; 29: 109-116
Published online in Wiley Online Library (wileyonlinelibrary.com). DOI: 10.1002/uog.12403

Ultrasound Obstet Gynecol 2013; 41: 348-359
Published online in Wiley Online Library (wileyonlinelibrary.com). DOI: 10.1002/uog.12403

ISUOG Education Committee training in obstetric & gynecological ultrasound (2014)

Practice guidelines for performance of the routine midtrimester scan (2011)

Sonographic examination of the fetal central nervous system (2007)

ISUOG Practice Guidelines (updated): sonographic screening examination of the fetal heart (2013)

ISUOG Education Committee recommendations for basic training in obstetric & gynecological ultrasound (UOG 2014; 43: 113-116)

Practice guidelines for performance of the routine midtrimester scan (UOG 2011; 37:116-126)

Sonographic examination of the fetal central nervous system (UOG 2007; 29: 109-116)

ISUOG Practice Guideline (updated):sonographic screening examination of the fetal heart (UOG 2013; 41: 348-359)

The 20 + 2 planes

Anatomical area	Plane	Description
Overview 1	Sweep 1	Longitudinal head & body for initial orientation
Spine	1	Sagittal complete spine with skin covering
	2	Coronal complete spine
	3	Coronal section of body
Head	4	Transventricular plane*
	5	Transthalamic plane*
	6	Transcerebellar plane*
Thorax	7	Lungs, 4 chamber view of heart
	8	Left ventricular outflow tract (LVOT)
	9	Right ventricular outflow tract (RVOT) & crossover of LVOT
	10	3 vessel trachea (3VT) view of heart

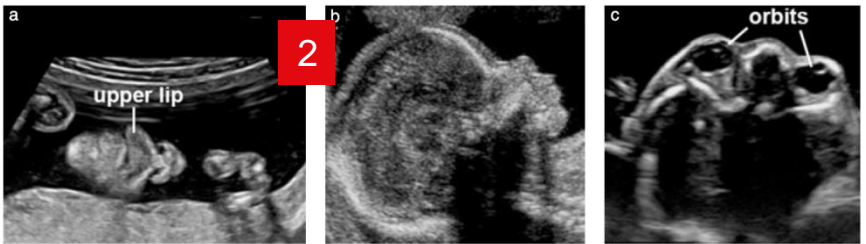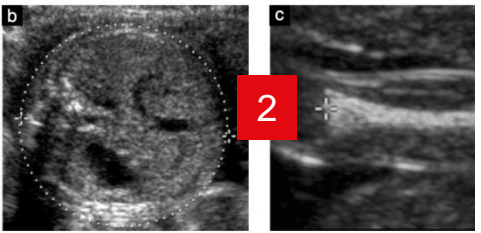
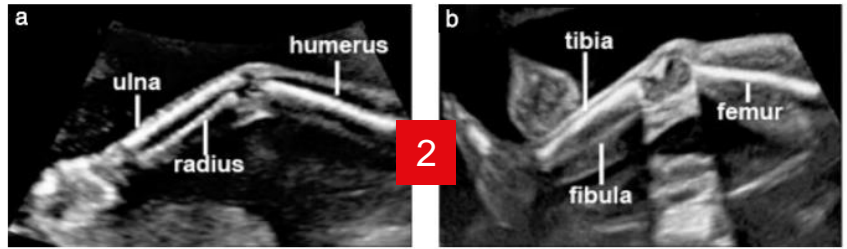
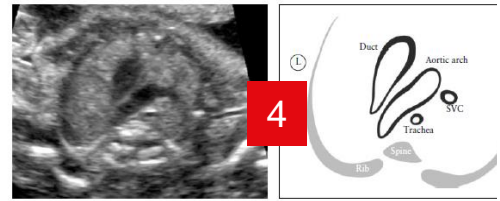
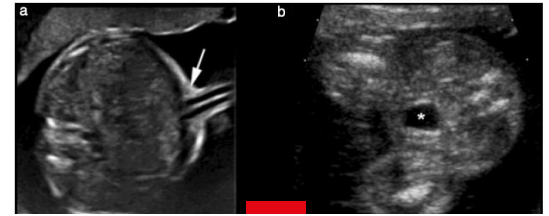
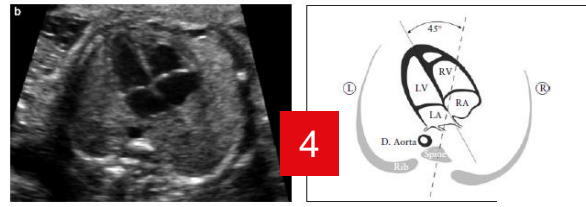
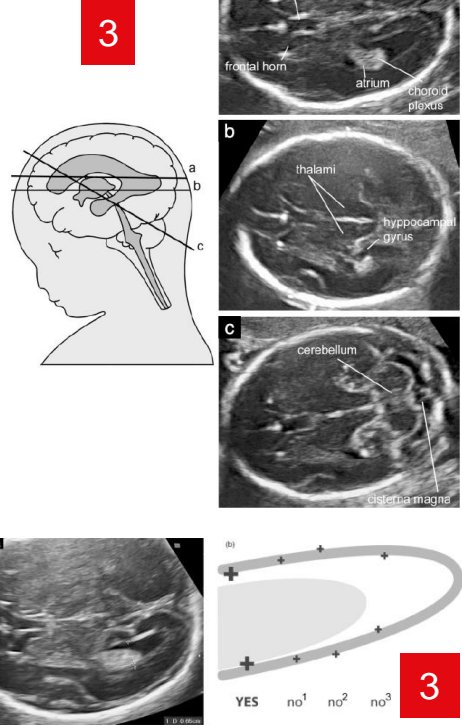
*Measurement required

The 20 + 2 planes

Anatomical area	Plane	Description
Abdomen	11	Transverse section of abdomen with stomach & umbilical vein*
	12	Transverse section of abdomen at cord insertion
	13	Transverse section(s) of left kidney & pelvis, right kidney & pelvis
Pelvis	14	Transverse section of pelvis, bladder, both umbilical arteries
Limbs	15	Femur diaphysis length*
	16	3 bones of both legs, both feet & normal relationships to both legs
	17	3 bones of both arms, both hands & normal relationships to both arms
Face	18	Coronal view of upper lip, nose & nostrils
	19	Both orbits, both lenses
	20	Median facial profile
Overview 2	Sweep 2	Transverse sweep of body from neck to sacrum, one vertebra at a time

*Measurement required

Sections required^{2,3,4}



ISUOG Education Committee recommendations for basic training in obstetric & gynecological ultrasound (UOG 2014; 43: 113-116)
 Practice guidelines for performance of the routine midtrimester scan (UOG 2011; 37:116-126)
 Sonographic examination of the fetal central nervous system (UOG 2007; 29: 109-116)
 ISUOG Practice Guideline (updated):sonographic screening examination of the fetal heart (UOG 2013; 41: 348-359)

What abnormalities should be excluded?

- The key to the 20+2 planes approach is understanding the importance of knowing what the **normal** ultrasound appearances are in each plane
- This knowledge equates to the **exclusion** of a range of **abnormal appearances** &/or abnormalities, rather than 'making a diagnosis'
- The range of abnormal appearances being sought may differ depending on local service requirements

Requirements from each plane

Plane	Description	Structures to be evaluated ^{2,3,4}	Measurement ^{2,3} & criteria for referral
Sweep 1	Longitudinal head & body for initial orientation	Fetal heart, skull	
1 (Spine)	Sagittal complete spine With skin covering	2 ossification centres of each vertebra (T1-S5), skin covering	
4 (Head)	Transventricular plane*	Skull size, shape, integrity & bone density, midline falx, Cavum septi pellucidi (CSP), Frontal (or anterior horns) of both lateral ventricles, Posterior horn (PH) of lower lateral ventricle*	PH, Refer if PH >10mm
7 (Thorax)	Lungs, 4 chamber view of heart	Cardiac situs, left & right lungs, 4 chamber view	

Practice guidelines for performance of the routine midtrimester scan (UOG 2010)

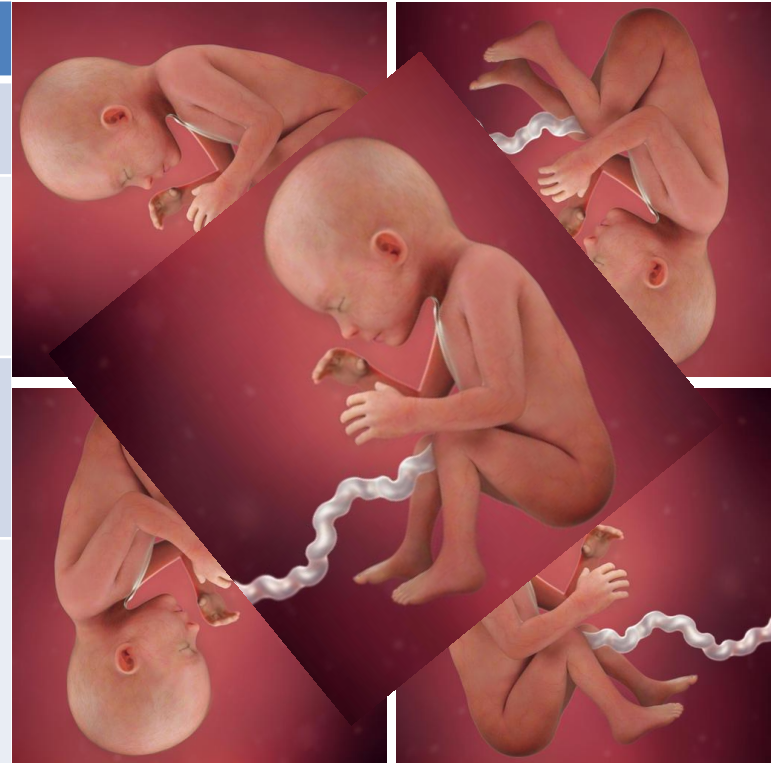Sonographic examination of the fetal central nervous system (UOG 20007)

ISUOG Practice Guideline (updated): sonographic screening examination of the fetal heart (UOG 2013)

* measurement required

Where in the uterus is sweep 1?

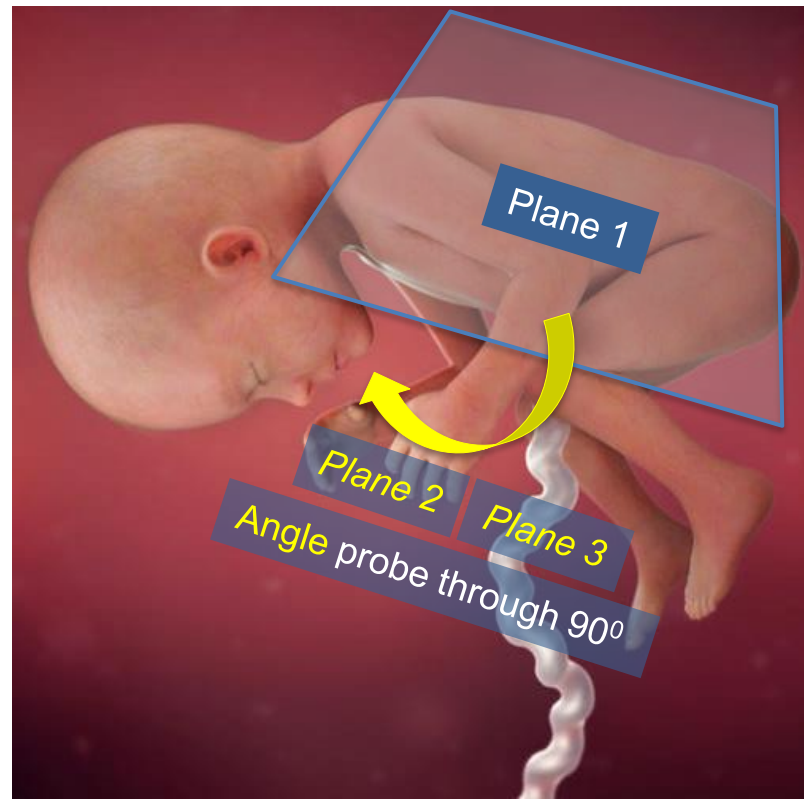
Plane	Description
Sweep 1	Longitudinal head & body for initial orientation
1	Sagittal complete spine with skin covering
2	Coronal complete spine
3	Coronal section of body
4	Transventricular plane*
5	Transthalamic plane*
6	Transcerebellar plane*
7	Lungs, 4 chamber view of heart
8	Left ventricular outflow tract (LVOT)
9	Right ventricular outflow tract (RVOT) & crossover of LVOT
10	3 vessel trachea (3VT) view of heart



*Measurement required

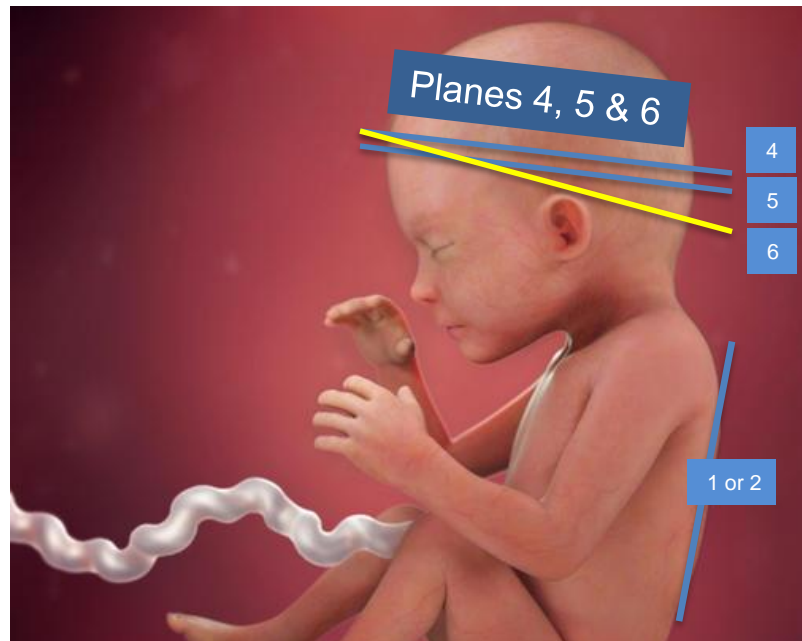
Moving through the 20 planes

Plane	Description
1	sagittal complete spine with skin covering
2	coronal complete spine
3	coronal section of body
4	Transventricular plane*
5	Transthalamic plane*
6	Transcerebellar plane*
7	Lungs, 4 chamber view of heart
8	Left ventricular outflow tract (LVOT)
9	Right ventricular outflow tract (RVOT) & crossover of LVOT
10	3 vessel trachea (3VT) view of heart



Moving through the 20 planes

Plane	Description
1	Sagittal complete spine with skin covering
2	Coronal complete spine
3	Coronal section of body
4	Transventricular plane*
5	Transthalamic plane*
6	Transcerebellar plane*
7	Lungs, 4 chamber view of heart
8	Left ventricular outflow tract (LVOT)
9	Right ventricular outflow tract (RVOT) & crossover of LVOT
10	3 vessel trachea (3VT) view of heart



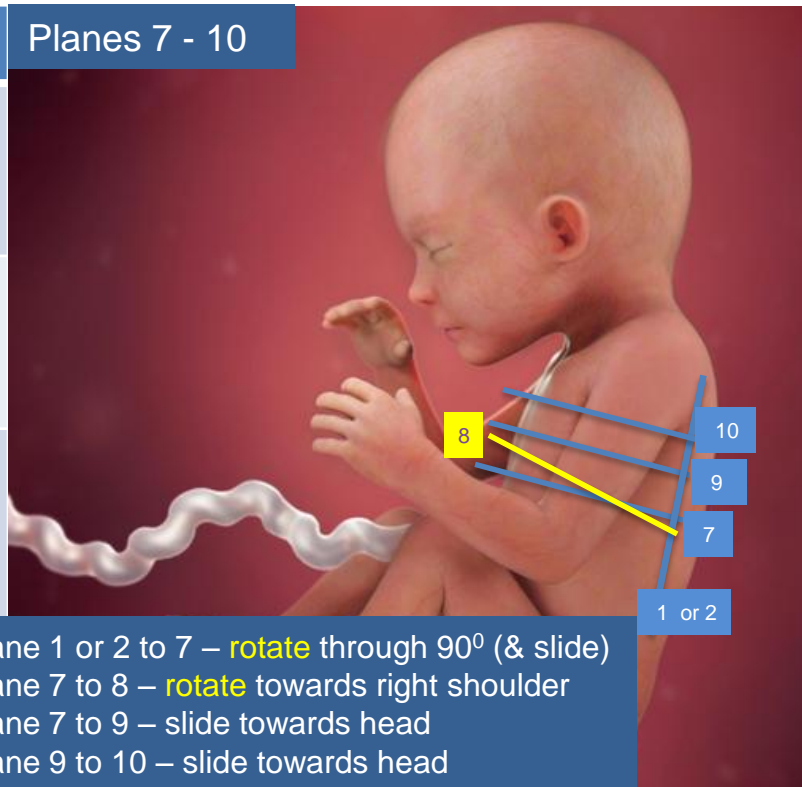
From plane 1 or 2 to 4 - **rotate** through 90°
From plane 4 to 5 – (**rotate** &) slide minimally
From plane 4 to 6 - **rotate**

*Measurement required

Moving through the 20 planes

Plane	Description
1	Sagittal complete spine with skin covering
2	Coronal complete spine
3	Coronal section of body
4	Transventricular plane*
5	Transthalamic plane*
6	Transcerebellar plane*
7	Lungs, 4 chamber view of heart
8	Left ventricular outflow tract (LVOT)
9	Right ventricular outflow tract (RVOT) & crossover of LVOT
10	3 vessel trachea (3VT) view of heart

Planes 7 - 10



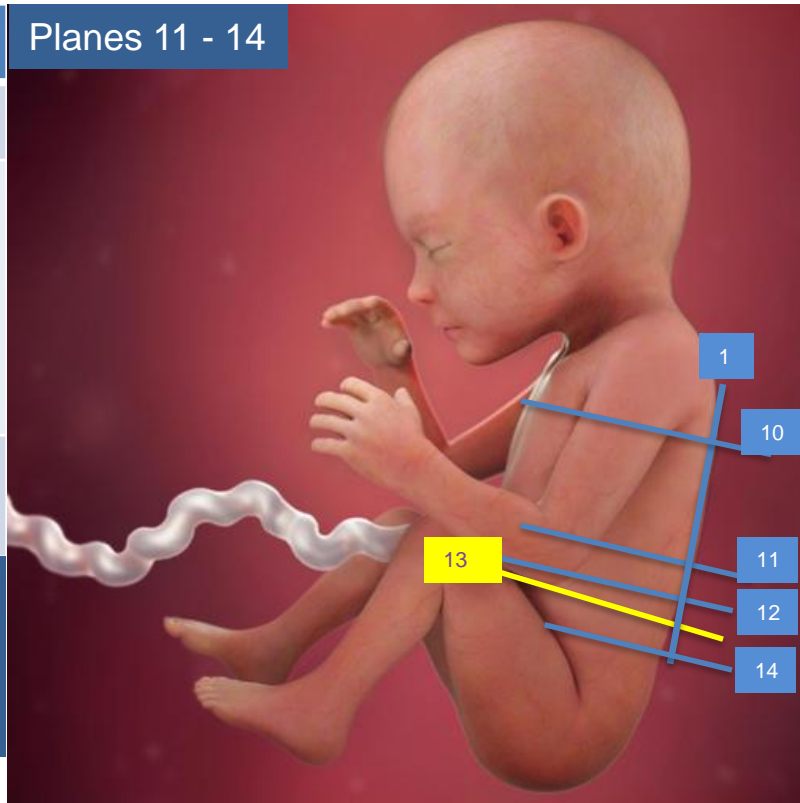
From plane 1 or 2 to 7 – **rotate** through 90° (& slide)
 From plane 7 to 8 – **rotate** towards right shoulder
 From plane 7 to 9 – slide towards head
 From plane 9 to 10 – slide towards head

Moving through the 20 planes

Plane	Description
10	3 vessel trachea (3VT) view of heart
11	Transverse section of abdomen with stomach & umbilical vein*
12	Transverse section of abdomen at cord insertion
13	Transverse section(s) of left kidney & pelvis, right kidney & pelvis
14	Transverse section of pelvis, bladder, both umbilical arteries

From plane 10 to 11 - slide
From plane 11 to 12 – slide
From plane 12 to 13 – slide (+ minimal **rotations**)
From plane 12 to 14 – slide

Planes 11 - 14

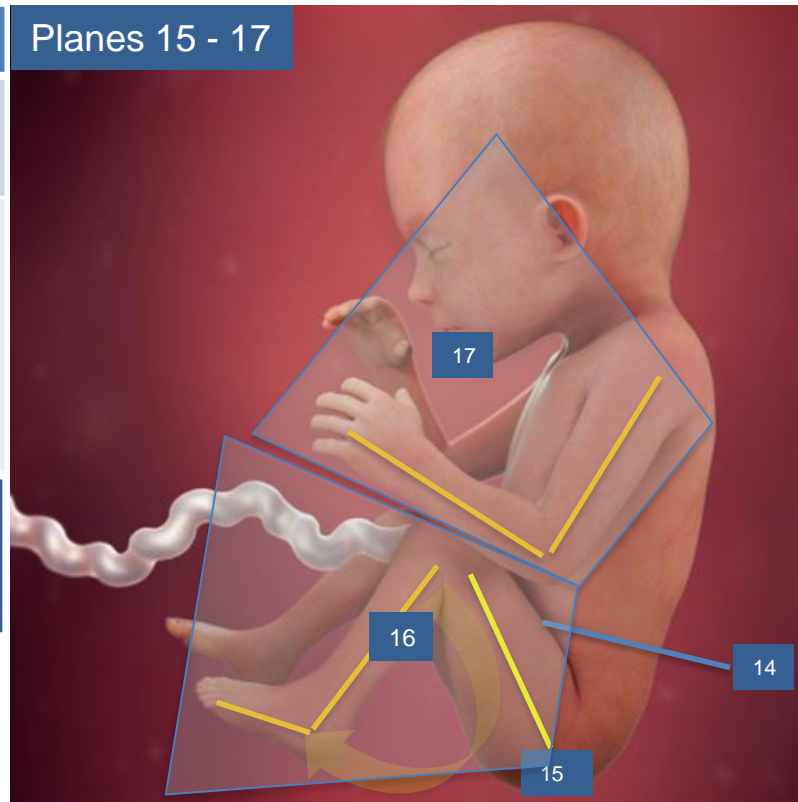


*Measurement required

Moving through the 20 planes

Plane	Description
14	Transverse section of pelvis, bladder, both umbilical arteries
15	Femur diaphysis length*
16	3 bones of both legs, both feet & normal relationships to both legs
17	3 bones of both arms, both hands & normal relationships to both arms

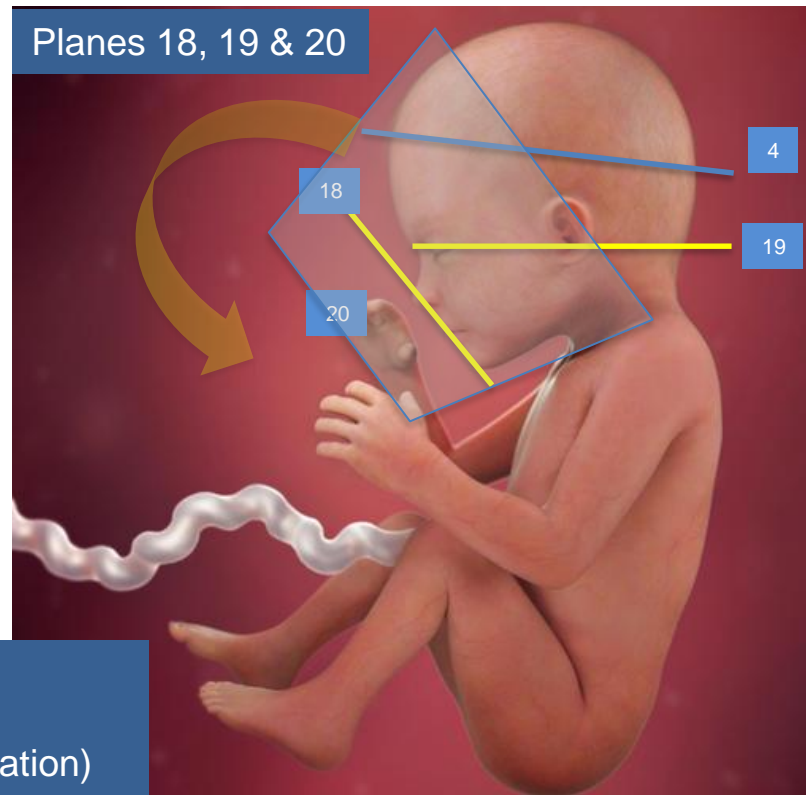
From plane 14 to 15 – slide & rotate
From plane 15 to 16 – slide, rotate (& angle)
From plane 14 to 17 – slide to upper chest, rotate (& angle)



*Measurement required

Moving through the 20 planes

Plane	Description
4	Transventricular plane
18	Coronal view of upper lip, nose & nostrils
19	Both orbits, both lenses
20	Median facial profile



From plane 4 to 18 – slide & **rotate** through 45° - 70° (& slide)
From plane 4 to 19 – slide (rotate minimally [dip for OP])
From plane 4 to 20 - slide, **angle** through 90° (& minimal rotation)

Exclusion of structural abnormalities

When performed correctly the 20 + 2 approach has the potential to exclude 50 abnormal fetal appearances, of which 20 + intrauterine death (IUD) **should** be excluded:

Plane	Anatomical area	Abnormal appearances
Sweep 1		1 + IUD
1-3	Spine	4 (6)
4-6	Head	4 (8)
7-10	Thorax	4 (16)
11-13	Abdomen	6 (8)
14	Pelvis	2 (3)
15-17	Limbs	1 (3)
18-20	Face	0 (5)
Sweep 2	all	all
TOTAL		20 + IUD (50)

20 + 2 planes & abnormal appearances

Plane	Area	Abnormal appearances (50+IUD) excluded by the correct 20+2 approach
Sweep 1		Anencephaly, Intrauterine death
1-3	Spine	Abnormal abdominal situs, left sided diaphragmatic hernia , meningocele, Open spina bifida , sacral agenesis, sacral coccygeal teratoma,
4-6	Head	Alobar holoprosencephaly, banana shaped cerebellum, cystic hygroma , large posterior fossa cyst, lemon shaped skull, occipital encephalocele, skin oedema, ventriculomegaly
7-10	Thorax	AVSD, CPAM , double aortic arch, ectopia cordis, overriding aorta, persistent left vena cava*, right aortic arch, severe aortic stenosis, coarctation & pulmonary stenosis, significant pericardial effusion (>4 mm) & pleural effusion (>4 mm) , situs inversus/ambiguous, tetralogy of Fallot, transposition, univentricular heart , VSD (moderate/large)
11-13	Abdomen	Ascites, bilateral renal agenesis, duodenal atresia , echogenic bowel*, gastroschisis, omphalocele , renal pelvic dilatation (>7 mm AP), small/absent stomach
14	Pelvis	Cystic renal dysplasia, lower urinary tract obstruction , 2 vessel cord
15-17	Limbs	Fixed flexion deformities wrist, severe skeletal dysplasia (some) , talipes
18-20	Face	Anophthalmia, cataract*, cleft lip, proboscis*, severe micrognathia

* Optional, for local decision as to whether or not included

20 + 2 planes criteria for referral

Plane	Area	Criteria for referral
ANY	ANY	Any appearance which is not normal
1-3	Spine	
4-6	Head	Atrium of lateral ventricle >10mm BPD, HC outside normal range of size chart
7-10	Thorax	
11-13	Abdomen	AC outside normal range of size chart One or both renal pelves >7 mm AP
14	Pelvis	
15-17	Limbs	FL outside normal range of size chart
18-20	Face	

AC - abdominal circumference
FL - femur length

BPD - biparietal diameter
HC - head circumference

Key points

1. Working through the 2 overview planes & 20 planes in the described sequence provides a logical & time efficient examination of the whole fetus
2. Examining the fetal anatomy correctly is more important than the order in which it is assessed
3. Your role is to distinguish between the range of normal & abnormal appearances of the mid trimester fetus
4. Any appearance which you cannot confirm as normal should be referred for a more experienced opinion



ISUOG Basic Training by **ISUOG** is licensed under a **Creative Commons Attribution-NonCommercial-NoDerivatives 4.0 International License**.

Based on a work at **<https://www.isuog.org/education/basic-training.html>**.

Permissions beyond the scope of this license may be available at **<https://www.isuog.org/>**