



15th World Congress on Ultrasound in Obstetrics and Gynecology

25-29 September 2005

Westin Bayshore Resort and Marina
Vancouver, Canada

Final Program

21 CME credits available from the EACCME
and 24 credits from the ACCME (US)
see page 5 for details



Organised by the
International Society of
Ultrasound in Obstetrics
and Gynecology
www.isuog.org

Critical dates and times

Registration opening hours

The registration area will be located in the main foyer of the Conference Centre (level one). The opening times are:

Sunday 25 September 2005	07:30–19:00
Monday 26 September 2005	07:30–17:30
Tuesday 27 September 2005	07:30–17:30
Wednesday 28 September 2005	07:30–17:30
Thursday 29 September 2005	07:30–12:45

Exhibition opening hours

The exhibition will be located in Salons A, B and C of the Bayshore Grand Ballroom (level one). The opening times are:

Sunday 25 September 2005	18:30–21:30 (Welcome reception)
Monday 26 September 2005	09:30–17:30
Tuesday 27 September 2005	09:30–17:30
Wednesday 28 September 2005	09:30–17:30
Thursday 29 September 2005	09:30–11:30

Speakers' preparation room opening hours

Speakers **MUST** check in their presentation at the speakers' preparation room at least 4 hours prior to the commencement of the session in which they are due to present. Speakers presenting in the morning should check in the day before.

The speakers' preparation room will be located in the Prospect Room (mezzanine area of level two). The speakers' preparation room will be open during the following times:

Sunday 25 September 2005	08:00–16:00
Monday 26 September 2005	08:00–17:30
Tuesday 27 September 2005	08:00–17:30
Wednesday 28 September 2005	08:00–17:30
Thursday 29 September 2005	07:30–13:30

PowerPoint poster presenters should have sent their PowerPoint slides in advance of the Congress. Failing that they may drop slides off the day before the scheduled day for poster presentation to ensure that their poster is included. Please note that the organisers cannot guarantee that PowerPoint posters can be included in the presentation if they are not received in advance.

N.B.: Chairpersons, speakers and poster presenters must refer to the guidelines on page 2 of this brochure.

Scientific program hours

The scientific program sessions will take place in the session halls, which are located in salons D, E and F off the exhibition hall/main lobby (level one) and in Salons 1 and 2 (level two). Please refer to the program for the exact location and timings of each session.

Sessions will take place during the following times:

Monday 26 September 2005	08:30–17:30
Tuesday 27 September 2005	08:30–17:30
Wednesday 28 September 2005	08:30–17:40
Thursday 29 September 2005	08:00–12:45

ISUOG meetings

ISUOG Annual General Meeting (AGM)

All fully paid delegates are automatically enrolled as ISUOG members and invited to attend the AGM.

Monday 26 September 2005 11:30 Room: Salons D–F

For details of scheduled ISUOG Committee meetings please refer to page 60 of this brochure.

Welcome message

I look forward to officially welcoming you to the 15th World Congress of ISUOG at our special opening ceremony on Sunday 25 September where we will start our meeting with a special tribute to Stuart Campbell, to whose brilliance we can attribute the success of our organisation to date. We are also deeply honoured this year to be joined by the Nobel Laureate, Dr Leland Hartwell, and our distinguished Gold Medal award winners who have contributed significantly to the further advancement of our profession. You can hear our distinguished guests present during our opening plenary sessions.

I would like to thank Knox Ritchie and Alain Gagnon for their hard work and dedication in chairing the Local Organising Committee and in welcoming us to their beautiful country. I also thank Karel Maršál particularly for his ongoing contributions to ISUOG during his immediate past Presidency and, in particular, through his work as Chair of the Scientific Committee in putting this meeting together. Your Board has been active this year in developing the future direction of ISUOG and if you have any suggestions as to how you would like to see ISUOG and this meeting move forward, please bring them to us here in Vancouver, or to our London Secretariat, where we are very fortunate to have a committed team of staff ready to answer your needs.

We hope you will all continue to participate in ISUOG's ongoing educational activities through our World Congresses, our International Scientific Meetings and through our outstanding monthly Journal under the leadership of our new Editor-in-Chief, Yves Ville. We hope that those of you who are presenting abstracts at the meeting will consider submitting your completed work to our Journal for publication and to contribute to the excellent scientific content that makes *Ultrasound in Obstetrics & Gynecology* stand out from the rest.

I am honoured to continue to serve as your President in the coming year. Please feel free to contact me personally if you feel that I can make your participation at this meeting in Vancouver more enjoyable – please enjoy your time in this wonderful city.



Lawrence D Platt, ISUOG President

Organising Committees**ISUOG Secretariat**

Unit 4, Blythe Mews, Blythe Road,
London W14 0HW, UK

Tel: +44 (0) 20 7471 9955

Fax: +44 (0) 20 7471 9959

Email: info@isuog.org

www.isuog.org

Chairman & ISUOG President

- Lawrence D Platt, USA

Co-Chairmen

- Alain L Gagnon, Canada
- JW Knox Ritchie, Canada

Local Organising Committee, Canada

- Peter Burns
- Peter Cooperberg
- Phyllis Glanc
- Sue Jamieson
- Jo-Ann Johnson
- Nancy Kent
- Giancarlo Mari, USA
- Dev Maulik, USA
- Lucie Morin
- David A Nyberg, USA
- Roger A Pierson
- Denise Pugash
- Greg Ryan
- Michiel C Van den Hof

ISUOG Meeting Planning Committee

- Ann Tabor, Denmark (Chair)
- Alfred Z Abuhamad, USA
- Joshua A Copel, USA
- Alain L Gagnon, Canada
- Karel Maršál, Sweden
- Kypros Nicolaidis, UK
- David A Nyberg, USA
- Gianluigi Pilu, Italy
- Lawrence D Platt, USA
- JW Knox Ritchie, Canada
- Yves Ville, France
- Ivan Zador, USA

ISUOG Scientific Committee

- Karel Maršál, Sweden (Chair)
- Beryl Benacerraf, USA
- Tom Bourne, UK
- Enrico Ferrazzi, Italy
- Steven R Goldstein, USA
- Davor Jurkovic, UK
- Kypros Nicolaidis, UK
- Baskaran Thilaganathan, UK
- Dirk Timmerman, Belgium
- Lil Valentin, Sweden

Executive Director

- Sarah Johnson, UK

Contents

Program (general)

Chairperson, speaker and poster presenter audio-visual guidelines	2
Invited speaker and abstract presenter declarations	4
Program orientation	5
CME accreditation	5
Program at a glance	6

Program (in detail)

Pre-Congress courses – Sunday 25 September 2005	8
Program – Monday 26 September 2005	11
Posters – Monday 26 September 2005	15
Program – Tuesday 27 September 2005	18
Posters – Tuesday 27 September 2005	24
Program – Wednesday 28 September 2005	29
Posters – Wednesday 28 September 2005	35
Program – Thursday 29 September 2005	40
Posters – Thursday 29 September 2005	44

Industry

Exhibition floor plan and list of exhibitors	47
Exhibitor profiles	48
Sponsors' activities	54

Social program 57**General information** 59**ISUOG business meetings** 60

Chairperson, speaker and poster presenter audio-visual guidelines

If you are chairing a session, speaking, or presenting a poster during the Congress, it is essential that you refer to the guidelines below. Please note that there may be several sections which are relevant to your activities. If, after reading the guidelines, you have any questions, please address them to the uniformed Congress staff in the speaker preparation room. The opening times are:

Sunday 25 September 2005	08:00–16:00
Monday 26 September 2005	08:00–17:30
Tuesday 27 September 2005	08:00–17:30
Wednesday 28 September 2005	08:00–17:30
Thursday 29 September 2005	07:30–13:30

The speaker preparation room is located in the Prospect Room on the mezzanine area of level two. Please use the escalators located in the Conference Centre to access this room.

Speakers and poster presenters

- Please check your presentation card (found in your registration pack) to confirm the date, time and location of your session. If you have any questions with regards to your presentation time, please contact the Congress uniformed staff in the speaker preparation room.

Chairpersons and speakers

- Please ensure that you meet at the front of the session hall 10–15 minutes before the start of the session, or in the case of live scan sessions 30 minutes prior, to introduce yourselves, and in order that the chairperson can confirm the format for the session.
- All presentations must be in English as there are no facilities for simultaneous translation. Please ensure that you speak slowly and clearly throughout. This will assist audience members who do not have English as their first language.
- Unless specifically stated there is no additional time allocated in sessions for discussion. Within the time that you have been allocated, you **MUST** allow a minimum of 25% of the total presentation time for questions, as dictated by the University of British Columbia CME authorities. For an 8-minute traditional oral presentation you should therefore plan **NO MORE THAN 6 MINUTES** for your talk, plus 2 minutes for questions. If you are presenting in the new 'just images' category, the allocated time is shorter (i.e. 2 minutes for presentation of your images plus 3 minutes for discussion).
- The program schedule is extremely tight so all speakers must adhere to the time allocated to them. The chairman will have a reminder light to assist them in keeping time. Should a speaker overrun they will be interrupted by the chairman who will request that the speaker stop. Please be considerate of other scheduled speakers if you are asked to conclude your talk and please do so promptly.

Applicable to chairpersons only

- There will be a host or hostess assigned to the session hall who will assist with any requirements you may have for the running of the session. A technician from the audio-visual team will also be available.
- There will be a roving microphone within each hall for discussion, which will be managed by the room host/hostess. Please direct the audience at the start of the sessions as to how questions will be managed to ensure the best use of the time available.

- At the start of the session, please ask the audience to turn off all mobile phones and pagers. Please also remind the audience that the recording of sessions is prohibited unless they have specific permission from the speakers.
- Please note that delegates will not be permitted to stand at the back of the hall due to fire regulations.
- Should a speaker not arrive for his/her presentation, please fill in the additional time with discussion, or provided all other speakers are present please move forward with the program. However please as far as possible try not to deviate dramatically from the advertised program because delegates will rely on precise timing as they move across sessions.

Applicable to speakers only

- All speakers must report to the speaker preparation room the day before their presentation. You will be able to check your presentation with the audio-visual staff whose responsibility it is to ensure the presentation is sent to the lecture hall prior to the session. All session halls are networked and presentations will be sent from the speaker preparation room to the session halls over the network.
- Presentation direct from a laptop is only permissible if pre-arranged. If you are presenting from your laptop you still need to report to the speaker preparation room the day before your presentation.
- If you are presenting a free communication abstract (i.e. with an 8 minute time slot) please note that you should **NOT** be presenting the background to your particular study or data set. This can be repetitive if several related studies are to be presented, and will be covered separately within the session if considered necessary. Time is short, so please keep your talk concise and focus only on your **NEW** data.

Poster presenters

- Obstetrics posters will be changed daily and gynecology posters will change once, on Wednesday 28 September. Obstetrics posters will be located in Cypress 1, Cypress 2 and gynecology only in the rear of Salon F. Posters will be on display from Monday 26 – Thursday 29 September 2005. You will have been previously informed of the day of your poster presentation. Please refer to the schedule below for the display, availability, installation and removal times.
- Presenters should in any case be available to answer questions at all break times indicated on the day of presentation. For those sessions where a chaired poster discussion session is scheduled (please refer to the enclosed program if you are unsure), PowerPoint presenters should arrive at the relevant poster area at least 10 minutes prior to the listed start time for the discussion group.

Special notes:

1. Please note there is no discussion session for the following poster sessions:
 - a. Fetal heart – Tuesday 27 September
 - b. Urogynecology – Wednesday 28 September

Applicable to traditional (hard copy) poster presenters only

- Posters must be removed according to the times above on the day that your poster is being presented. In the event that your poster has not been removed by the time stipulated, the poster

Chairperson, speaker and poster presenter audio-visual guidelines

will be taken down and disposed of by the Congress staff. ISUOG and the Congress Secretariat cannot be held responsible for destroyed/lost posters that were not removed by the stipulated time.

- A display board giving a display area of approximately 1000mm (width) x 1000mm (length) will be provided for your poster.
- A header panel with your poster number will be provided. This will not include the title of your poster.
- The poster display boards are Velcro compatible. Velcro will be provided to all poster presenters at the Congress. Should you require additional Velcro, this can be obtained from the speakers' preparation room or the registration desk.
- If you wish to keep your poster tube/container, please take these to the speakers' preparation room for storage. Please note that these are left at your own risk.

Applicable to PowerPoint poster presenters only

- PowerPoint posters should have been emailed in advance of the Congress to Professor Alain Gagnon.
- Presenters that have not emailed their PowerPoint posters in advance may check-in their posters at the speaker preparation room on the day PRIOR to the day of presentation. If you do not adhere to this, the organisers cannot guarantee that your poster will be included.
- On the day of presentation, PPT posters will be presented on a continuous rolling loop within the relevant themed poster session area and alongside the hard copy posters.

Poster display times

DAY	POSTER SESSION	Poster session discussion times	Room	Poster display time	Install your poster	Poster removal
Monday 26 September	P01 – Screening for chromosomal abnormalities	12:00 – 12:20	Cypress 1	08:30 – 17:30	08:00 – 08:30	By 17:30
	P02 – Central nervous system	12:25 – 12:45				
	P03 – Fetal anatomy and fetal anomalies I	12:00 – 12:45	Cypress 2			
Monday 26 and Tuesday 27 September	P07 – Abnormal bleeding	Tuesday 27 September 12:00 – 12:20	Salon F	13:30 Monday 26 to 17:30 Tuesday 27 September	Monday 26 September from 13:00 – 13:30	Tuesday 27 September by 17:30
	P08 – Ovarian masses and gynecological malignancies	Tuesday 27 September 12:25 – 12:45				
Tuesday 27 September	P04 – Fetal anatomy and fetal anomalies II	12:00 – 12:45 (Thorax and abdomen discussion forum only)	Cypress 1	08:30 – 17:30	08:00 – 08:30	By 17:30
	P05 – Fetal heart	Viewing only	Cypress 2			
	P06 – Multiple pregnancy	12:00 – 12:45				
Wednesday 28 September	P09 – Invasive procedures and fetal therapy	12:00 – 12:45	Cypress 1	08:30 – 17:30	08:00 – 08:30	By 17:30
	P10 – Fetal growth and well-being	12:00 – 12:20	Cypress 2			
	P11 – Labour	12:25 – 12:45	(P11 hardcopy posters are located in Cypress 1)			
Wednesday 28 and Thursday 29 September	P12 – Early pregnancy and acute gynecology	Wednesday 28 September 12:00 – 12:20	Salon F	08:30 Wednesday 28 to 13:30 Thursday 29 September	Wednesday 28 September from 08:00 – 08:30	Thursday 29 September by 13:30
	P13 – New technologies and gynecological oncology	Wednesday 28 September 12:25 – 12:45				
	P14 – Urogynecology	Viewing only				
Thursday 29 September	P15 – Maternal complications of pregnancy	10:40 – 11:10	Cypress 1	08:00 – 13:30	07:30 – 08:00	By 13:30
	P16 – New technologies in obstetric ultrasound	10:40 – 11:10	Cypress 2			

Invited speaker and abstract presenter declarations

Invited speakers

- J.S. Abramowicz Consultant for Philips Medical Systems. No financial relations.
 J.S. Carvalho Following my acceptance to do a live scan demonstration with any high resolution equipment, ALOKA representatives in the UK informed me that ALOKA will sponsor my airline ticket and hotel accommodation at the Congress. I do not serve on any of ALOKA's committees. I am committed to presenting the live scan demonstration regardless of whether or not the equipment to be used is an ALOKA ultrasound system.
- J.A. Copel Consultant for GE and Philips.
 S.R. Goldstein Consultant for Cook Ob/Gyn and Akrad Labs.
 L. Hartwell Serves on the scientific advisory board of Kereos.
 D. Jurkovic Aloka Co. Japan has donated an ultrasound machine to my department for the purpose of training.
 W. Lee Serves on the speakers' bureau and advisory board for GE Healthcare with limited 3D ultrasound research from the company. Consultant for GE Healthcare, Philips Medical Systems and Siemens Medical Solutions. Limited MRI research support from Siemens Medical Solutions.
- D. Levine R.F. Busse is an employee of GE Medical Systems and a co-author in the abstract "An evaluation of Real-time MR single shot fast spin echo imaging in visualisation of fetal midline corpus callosum and secondary palate."
- E. Merz Clinical Consultant for GE-Kretztechnik.
 A.K. Parsons Consultant for QA - Organon Inc and Wyeth-Ayerst.
 L.D. Platt Consultant for GE Medical Systems and a speaker for Philips Medical Systems.
 D.H. Pretorius Consultant for Philips and Toshiba. Equipment loans from GE and Philips.
 E.A. Stewart Drs. Stewart, Hynynen and Tempany serve as Consultants for Insightec within the Harvard Medical School conflict of interest guidelines.
 D. Timmerman Scanning equipment donated by ESAOTE.
 A. Toi Ultrasound equipment on loan for research from Philips.

The following invited speakers have not submitted a declaration of interests form:

- B. Benoit B. Cacciatore Y. Ville

Abstract presenters

- V. Catanzarite President of MMSI and PRCO.
 M. Crade Medical Director for Ultrasonix.
 J. Deng 4D data used in this study was acquired using a live 3D ultrasound system on free loan from Philips Ultrasound UK.
 V. Fernando Consultant for GE Medical Systems.
 L.F. Gonçalves Loaned IE-33 equipment was used to conduct the study for the following abstract: "Flip the coin: 360 degree visualisation of fetal structures with xMartix real-time 4D (RT4D) ultrasonography."
 J. Jirous ATC Company, Kuwait, will cover my Congress expenses associated with payment of ticket and accommodation. I am not using donated ultrasound machine and I am not a member of any consulting committee for a systems manufacturer.
 A. Kratochwil Consultant for GE-Kretztechnik.
 S.M. Lee I used Accuvix XQ and needed some help for managing the machine. The co-author, Ms. Park, is a Clinical Specialist for Medison Co., Ltd. She had a role as a technical supporter in this study. The other authors including myself have no personal relationship with Medison Co., Ltd.
 K.Y. Leung Our department is using a three-dimensional ultrasound machine on loan from Medison.
 D. Maulik Instrument used for the research presentation was purchased. I do not serve on any consulting committees for the manufacturer.
 D. Paladini The study has been produced on ultrasound equipment provided by GE for clinical trials only.
 L. Pasquini The fetal ECG equipment was provided by QinetiQ.
 D. Pretorius Equipment loan from General Electric Healthcare. Consulting and equipment loan from Philips Medical Systems.
 D. Pugash Honoraria received from Philips for case studies and lecture.

The following abstract presenters have not submitted a declaration of interests form:

- T. Kanasugi M. Khooshideh L. Nardozza B. Sonwane
 S. Khani I. Martínez-Wallin N. Pavlova T. Urbaniak
 A. Khaw J. Murotsuki D.A.L. Pedreira

List of invited faculty

J.S. Abramowicz, USA	G. Condous, UK	K. Hecher, Germany	D. Maulik, USA	J.W.K. Ritchie, Canada
A.Z. Abuhamad, USA	P. Cooperberg, Canada	J.C. Hobbins, USA	I. Meizner, Israel	G. Ryan, Canada
J.L. Alcázar, Spain	J.A. Copel, USA	J. Hyett, UK	E. Merz, Germany	W. Sepulveda, Chile
R.O. Bahado-Singh, USA	B.F. Cuneo, USA	S. Jamieson, Canada	D.M. Miller, Canada	E.A. Stewart, USA
R.H. Ball, USA	J. Deprest, Belgium	P. Jeanty, USA	P.T. Mohide, Canada	A. Tabor, Denmark
A. Barbera, USA	G.R. DeVore, USA	J.A. Johnson, Canada	T.R. Nelson, USA	S.L. Tan, Canada
A.A. Baschat, USA	H.P. Dietz, Australia	D. Jurkovic, UK	A. Ngu, Australia	A.C. Testa, Italy
B. Benacerraf, USA	P.M. Doubilet, USA	M.D. Kilby, UK	U. Nicolini, Italy	B. Thilaganathan, UK
B. Benoit, France	S.H. Eik-Nes, Norway	J. Kingdom, Canada	D.A. Nyberg, USA	D. Timmerman, Belgium
C.B. Benson, USA	D. Farquharson, Canada	T. Kiserud, Norway	D. Paladini, Italy	I.E. Timor-Tritsch, USA
H.G.K. Blaas, Norway	E. Ferrazzi, Italy	D. Krakow, USA	A.N. Papageorgiou, Canada	A. Toi, Canada
S. Blaser, Canada	K. Fong, Canada	W. Lee, USA	A.K. Parsons, USA	L.I.E. Valentin, Sweden
T. Bourne, UK	J.C. Fouron, Canada	F.P.G. Leone, Italy	R.A. Pierson, Canada	M.C. Van den Hof, Canada
C. Brezinka, Netherlands	A.L. Gagnon, Canada	J.P. Lerner, USA	G. Pilu, Italy	C. Verchere, Canada
M. Bronshtein, Israel	P. Glanc, Canada	D. Levine, USA	L.D. Platt, USA	Y. Ville, France
B. Cacciatore, Finland	B. Goldberg, USA	K.I. Lim, Canada	D.H. Pretorius, USA	J. Wladimiroff, Netherlands
S. Campbell, UK	S.R. Goldstein, USA	G. Malinger, Israel	D. Pugash, Canada	S.Y. Yagel, Israel
J.S. Carvalho, UK	P.B. Gordon, Canada	G. Mari, USA	R.A. Quintero, USA	I. Zalud, USA
R. Chaoui, Germany	L. Hartwell, USA	K. Maršál, Sweden	N.J. Raine-Fenning, UK	

Program orientation

- The **program at a glance** gives you an outline to each day's events including session titles and times, and all refreshment breaks.
- The **program pages** give you the detailed chronological listing of events – please note that most sessions run in parallel so you will need to read through all sessions of similar time to decide which best suits your needs.
- Rooms as well as days are colour coded to assist you in 'navigating' the program.
- In all poster and oral presentation listings the presenting authors names are underlined.
- All lectures which are supported by free communication abstracts have an 'OC' number listed next to them, you can use this to refer to the abstract book in your Congress bag and the detailed abstract.
- Some of the sessions included are 'live scan' or 'demonstration' time: these are live or video updates on the latest techniques and technologies in the field which support the scientific data in the same subject area.
- Related **posters** are also listed under each oral session. The poster titles are listed in the pages immediately following the day of oral sessions. Posters are referenced to 'P' numbers – you can use these both to locate the original abstracts in the abstract book, and to find the relevant posters in the dedicated poster areas.
- Posters which are presented in PowerPoint rather than hard copy format are suffixed by **PPT**.
- There are allocated chaired poster discussion times for some of the themed poster sessions. Authors of PowerPoint posters in these sessions will be present for these discussions to answer any questions that arise. All poster authors will be available by their posters during break times to answer questions. Please refer questions direct to the authors.
- Obstetrics poster displays change daily and gynecology posters every other day, so please take advantage of the allocated times each day for poster viewing and discussion.
- The **exhibition** hall opens at 09:30am each day – all refreshment breaks are located within this room.
- All poster and oral free communication sessions will be judged within their subject categories. The best oral and poster presentations in each session will receive certificates, and will be formally acknowledged in *Ultrasound in Obstetrics & Gynecology*. Presenting authors are advised that results of judging will be announced on Thursday 29 September at the closing ceremony and are encouraged to attend.

CME objectives

At the end of this program the attendee will understand the:

- role of ultrasound in screening, treating and managing low risk and high risk pregnancies
- role of ultrasound in detecting ovarian cancer
- role of ultrasound in diagnosing congenital heart disease
- role of ultrasound in assessing uterine pathologies
- role of ultrasound in assessing the fetal brain and nervous system
- role of ultrasound in improving assisted reproductive technologies
- use of ultrasound to complement first- and second-trimester risk assessment
- new approaches with therapeutic ultrasound in gynecology
- potential bio-effects of ultrasound on the developing fetus

Accreditation



The Division of
CONTINUING MEDICAL EDUCATION

The University of British Columbia (UBC), Faculty of Medicine, Division of Continuing Medical Education, is fully accredited by the Committee on Accreditation of Canadian Medical Schools (CACMS) and by reciprocity through the Accreditation Council for Continuing Medical Education (ACCME) of the United States to sponsor continuing medical education for physicians. The UBC Division of Continuing Medical Education designates this educational program as meeting the accreditation criteria for a maximum of 24.0 Category 1 credits toward the American Medical Association Physician's Recognition Award. There will be up to 9.0 additional hours of study credits available for those who attend the pre- and post-Congress courses. This program is an Accredited Group Learning Activity (Section 1) as defined by the Maintenance of Certification program of the Royal College of Physicians and Surgeons of Canada. This program has been reviewed and

approved by UBC Division of Continuing Medical Education. Each physician should claim only those credits he/she actually spent in the activity.

EACCME

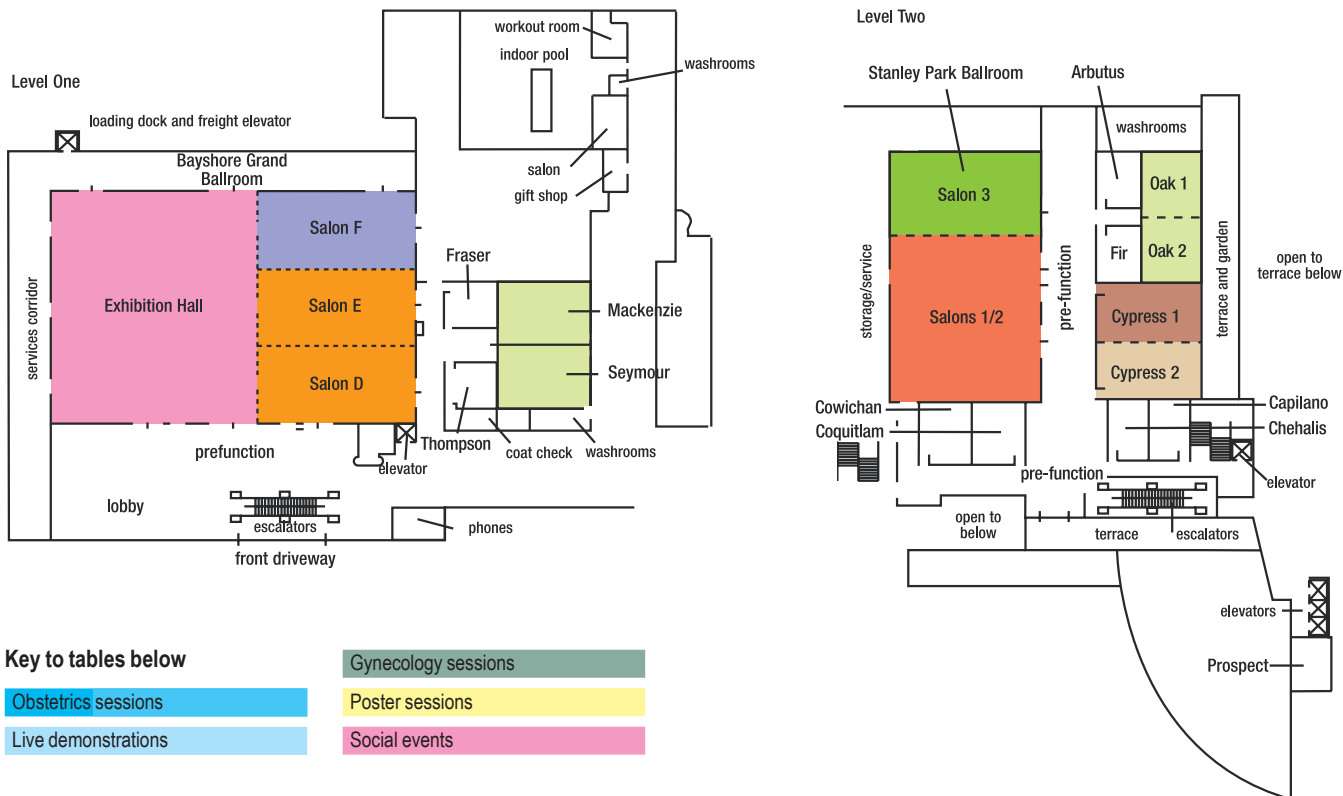
The International Society of Ultrasound in Obstetrics and Gynecology is accredited by the European Accreditation Council for Continuing Medical Education (EACCME) to provide the following CME activity for medical specialists. The EACCME is an institution of the European Union of Medical Specialists (UEMS), www.uems.be.

The 15th World Congress on Ultrasound in Obstetrics and Gynecology is designated for a maximum of 21 hours of European external CME credits. Each medical specialist should claim only those hours of credit that he/she actually spent in the educational activity.

EACCME credits are recognised as Physician's Recognition Award by the American Medical Association.

Program at a glance

Venue floor plan



Sunday 25 September 2005

	CYPRESS 1	CYPRESS 2	SALON 2	SALON 3	SEYMOUR	MACKENZIE	BAYSHORE GRAND BALLROOM
10:00-18:00	3D ultrasound: basic course	3D ultrasound: expert course	Fetal echocardiography	Central nervous system	11-14 week scan	Office gynecology	
10:30-18:00							
18:30-21:30							Opening ceremony and welcome reception

Monday 26 September 2005

	SALONS D-F	SALONS 1-2	SALONS D-E	SALON F	CYPRESS 1	CYPRESS 2	EXHIBITION HALL
					Poster viewing all day: P01 - Screening for chromosomal abnormalities P02 - Central nervous system	Poster viewing all day: P03 - Fetal anatomy and fetal anomalies I	
08:30-09:40	Opening plenaries: Recent advances						
09:40-10:10					Coffee and poster viewing		Coffee
10:10-11:30	Distinguished presentations						
11:30-12:00	ISUOG Annual General Meeting						
12:00-14:00				Poster viewing from 13:30 P07 - Abnormal bleeding P08 - Ovarian masses and gynecological malignancies	Poster discussion sessions P01, P02 & P03		Lunch
14:00-15:30		Central nervous system (CNS) I Live scan demonstration	Clinical dilemmas in obstetric ultrasound	New techniques and technologies in gynecology			
15:30-16:00					Coffee and poster viewing		Coffee
16:00-17:30		Fetal heart I Live scan demonstration	CNS II: controversies in managing abnormal findings	Abnormal bleeding and the management of uterine pathology			

Program at a glance

Tuesday 27 September 2005

	SALONS 1-2	SALONS D-E	SALON F	CYPRESS 1	CYPRESS 2	EXHIBITION HALL
			Poster viewing all day: P07 – Abnormal bleeding P08 – Ovarian masses and gynecological malignancies	Poster viewing all day: P04 – Fetal anatomy and fetal anomalies II	Poster viewing all day: P05 – Fetal heart P06 – Multiple pregnancy	
08:30–10:00	Fetal face and neck Live scan demonstration	Dilemmas in the management of monozygotic twins	Unsuspected findings in asymptomatic women			
10:00–10:30				Coffee and poster viewing		Coffee
10:30–12:00	Fetal heart II Live scan demonstration	Controversies in the management of labour	Demonstrations and debates in gynecology I			
12:00–14:00				Poster discussion sessions P04, P06, P07 & P08		Lunch
14:00–15:30	Thorax and abdomen Live scan demonstration	Fetal heart III	Management of ovarian masses: achieving a consensus			
15:30–16:00				Coffee and poster viewing		Coffee
16:00–17:30	Fetal skeleton Live scan demonstration	Management of abnormal findings in obstetric ultrasound	Managing disorders of ovarian function and subfertility			
19:00–24:00	Congress party at the Aquarium					

Wednesday 28 September 2005

	SALONS 1-2	SALONS D-E	SALON F	CYPRESS 1	CYPRESS 2	EXHIBITION HALL
			Poster viewing all day: P12 – Early pregnancy and acute gynecology P13 – New technologies and gynecological oncology P14 – Urogynecology	Poster viewing all day: P09 – Invasive procedures and fetal therapy	Poster viewing all day: P10 – Fetal growth and well-being P11 – Labour	
08:30–10:00	Fetal growth and fetal well-being Live scan demonstration	Stump the Professor	Magnetic resonance imaging (MRI) in obstetrics I			
10:00–10:30				Coffee and poster viewing		Coffee
10:30–12:00	Clinical benefits of 3D ultrasound Live scan demonstration	Intrauterine growth restriction (IUGR) I	Demonstrations and debates in gynecology II			
12:00–14:00				Poster discussion sessions P09, P10, P11, P12 & P13		Lunch
14:00–15:30	11–14 week scan Live scan demonstration	IUGR II	New technologies and gynecological malignancies			
15:30–16:00				Coffee and poster viewing		Coffee
16:00–17:40	18–23 week scan Live scan demonstration	Fetal surgery	Acute gynecology and ectopic pregnancy			

Thursday 29 September 2005

	SALONS 1-2	SALONS D-E	SALON F	CYPRESS 1	CYPRESS 2	EXHIBITION HALL
			Poster viewing all day: P12 – Early pregnancy and acute gynecology P13 – New technologies and gynecological oncology P14 – Urogynecology	Poster viewing all day: P15 – Maternal complications of pregnancy	Poster viewing all day: P16 – New technologies in obstetric ultrasound	
08:00–09:30	Maternal complications Live scan demonstration	New technologies in obstetrics	The use of ultrasound to assess the urogynecology patient			
09:30–10:30	Optimising the use of obstetric ultrasound Live scan demonstration	MRI in obstetrics II	Demonstrations and debates in gynecology III			
10:30–11:15				Poster discussion sessions P15 & P16		Coffee
11:15–12:45	Plenary: The optimum model for screening for chromosomal abnormalities					
12:45				Closing: Pizza and beer (level two)		



Sunday 25 September 2005

Pre-Congress courses

Course 1A 3D ultrasound: basic course Room: Cypress 1

Organised by the ISUOG 3D Focus Group

Course Directors: J.S. Abramowicz (USA); H.G.K. Blaas (Norway); T.R. Nelson (USA)

- 10:00 Welcome and introduction *T.R. Nelson (USA)*
- How 3D ultrasound works**
- 10:15 Equipment *T.R. Nelson (USA)*
- 10:30 Acquisition *T.R. Nelson (USA)*
- 10:45 Display *D.H. Pretorius (USA)*
- 11:00 Safety: keeping the fetus safe *J.S. Abramowicz (USA)*
- Scanning patients**
- 11:15 2D ultrasound: the pre-scan strategy *D.H. Pretorius (USA)*
- 11:30 3D ultrasound: getting a good volume *D.H. Pretorius (USA)*
- 11:45 4D ultrasound: heart acquisition *L.F. Gonçalves (USA)*
- 12:00 Archiving: types of data to save *W. Lee (USA)*
- Helping patients: part 1**
- 12:15 Lips, palates and faces *D.H. Pretorius (USA)*
- 12:30 Hearts *L.F. Gonçalves (USA)*

12:45–13:30 Lunch

- Helping patients: part 2**
- 13:30 Bones *J.S. Abramowicz (USA)*
- 13:45 Uteruses *A.K. Parsons (USA)*
- Clinical impact of 3D ultrasound**
- 14:00 Obstetrics *H.G.K. Blaas (Norway)*
- 14:15 Gynecology *A.K. Parsons (USA)*

14:30–14:50 Coffee

- 14:50 Delegates will then go to the Cypress 2 Room to join the second part of the expert course. Please see Course 1B for details of the afternoon program.

Course 1B 3D ultrasound: expert course Room: Cypress 2

Organised by the ISUOG 3D Focus Group

Course Directors: J.S. Abramowicz (USA); H.G.K. Blaas (Norway); T.R. Nelson (USA)

- 10:00 Welcome and introduction *H.G.K. Blaas (Norway)*
- 3D ultrasound efficacy**
- 10:15 Obstetrics *H.G.K. Blaas (Norway)*
- 10:30 Gynecology *A.K. Parsons (USA)*
- Expert solutions: obstetrics**
- 10:45 *B. Benoit (France)*
- 11:00 *W. Lee (USA)*
- 11:15 *I.E. Timor-Tritsch (USA)*
- 11:30 *G.R. DeVore (USA)*
- Expert solutions: gynecology**
- 11:45 *B. Benacerraf (USA)*
- 12:00 *A. Lev-Toaff (USA)*
- 12:15 *tbc*
- 12:30 *I.E. Timor-Tritsch (USA)*

12:45–13:30 Lunch

- Scanning tricks**
- 13:30 Matching the photograph: Bernard's secrets *B. Benoit (France)*
- 13:45 3D ultrasound off-line scanning: getting the best you can *B. Benacerraf (USA)*

Sunday 25 September 2005

- Computer tricks**
 14:00 Where am I in the volume? Multiplanar vs. rendered *W. Lee (USA)*
 14:15 How do I get the right view? *G.R. DeVore (USA)*

14:30–14:50 Coffee

Delegates from Course 1A will then join the rest of this program

- Real-world challenges**
 14:50 Obstetrics *B. Benoit (France)*
 15:05 Obstetrics *K. Baba (Japan)*
 15:20 Gynecology *A. Kratochwil (Austria)*
 15:35 Gynecology *D. Jurkovic (UK)*
 15:50 Obstetrics *I.E. Timor-Tritsch (USA)*
 16:05 Obstetrics *R. Chaoui (Germany)*
 16:20 Gynecology *A. Lev-Toaff (USA)*
 16:35 Gynecology *B. Benacerraf (USA)*

- Future enhancements**
 16:50 Clinical: additional clinical applications *A.Z. Abuhamad (USA)*
 17:05 Equipment improvements *L.D. Platt (USA)*

- How to make 3D ultrasound useful**
 17:20 Panellist: *L.D. Platt (USA)*
 17:35 Panellist: *A.K. Parsons (USA)*
 17:50–18:05 Panellist: *T.R. Nelson (USA)*

Course 2 11–14 week scan

Room: Seymour

Course Directors: J. Hyett (UK); J.A. Johnson (Canada); K. Nicolaidis (UK)

- 10:30 Introduction *J.A. Johnson (Canada)*
 10:45 Measuring the effectiveness of screening *J. Hyett (UK)*
 11:15 Increased nuchal translucency (NT) and chromosomal abnormalities *J.A. Johnson (Canada)*
 11:45 Adding biochemistry for risk assessment *J. Hyett (UK)*
 12:00 Other first trimester ultrasound markers *J. Sonek (USA)*
 12:30 Setting up an NT-based screening service *J.A. Johnson (Canada)*
 12:45 Moving to CVS (video presentation) *K. Nicolaidis (UK)*



The Fetal Medicine Foundation

13:15–14:15 Lunch

- 14:15 Increased NT in chromosomally normal fetuses *J. Sonek (USA)*
 14:45 Moving towards a 12-week echo *F. McAuliffe (Republic of Ireland)*
 15:05 Standardised measurement and quality assurance of NT *N. Greene (USA)*

15:25–15:55 Coffee

- 15:55 Live demonstration *N. Greene (USA); J. Lai (Canada)*
 16:25 The first trimester anomaly scan *N. Greene (USA)*
 16:45 Screening multiples *J.A. Johnson (Canada)*
 17:05 Incorporating other means of risk assessment *J. Hyett (UK)*
 17:25–17:55 Round up and multiple-choice questions (MCQ) *J. Hyett (UK); J.A. Johnson (Canada)*
(Test your knowledge with an MCQ-examination relating to the day's teaching activities. Those who pass the theoretical examination are eligible to apply for the practical component of the Fetal Medicine Foundation's certificate of competence in the 11–14 week scan.)

Course 3 Central nervous system

Room: Salon 3

Course Directors: G. Pilu (Italy); G. Maligner (Israel); I.E. Timor-Tritsch (USA)

Course aim: To provide an up-to-date actualisation of fetal neurosonography from the use of multiplanar views in the normal fetus to the diagnosis of specific pathologies during different stages of pregnancy.

- 10:00 The normal fetal brain. Multiplanar and 3D approach *I.E. Timor-Tritsch (USA)*
 11:00 Ventriculomegaly and hydrocephaly *G. Pilu (Italy)*
 12:00 Dorsal and ventral induction disorders. Agenesis of the corpus callosum *G. Pilu (Italy)*

13:00–14:00 Lunch



Sunday 25 September 2005

- 14:00 Malformations of cortical development *G. Malingier (Israel)*
 15:00 Cerebellar malformations *G. Malingier (Israel)*

15:45–16:15 Coffee

- 16:15 Prenatal insults, infective fetopathy *I.E. Timor-Tritsch (USA)*
 17:00–18:00 Diagnosis please – a quick test of your skills!

Course 4 Fetal echocardiography

Room: Salon 2

Course Director: R. Chaoui (Germany)

- 10:00 Introduction *R. Chaoui (Germany)*
 10:05 ISUOG basic cardiac screening guidelines *W. Lee (USA)*
 10:30 The planes in fetal echocardiography and their accuracy *S.Y. Yagel (Israel)*
 11:05 How to adjust the real-time image and the colour Doppler presetting for a proper cardiac scan *R. Chaoui (Germany)*
 11:35 Malformations detected in the 4CV *D. Paladini (Italy)*
 12:20 Malformations detected in the great vessel planes *R. Chaoui (Germany)*

13:05–14:05 Lunch

- 14:05 Cardiac and extracardiac malformations *D. Paladini (Italy)*
 14:35 Fetal arrhythmias *J.A. Cope (USA)*
 15:05 Cardiac evaluation in the genetic scan *G.R. DeVore (USA)*
 15:35 Fetal outcome after prenatal diagnosis *J.A. Cope (USA)*

16:05–16:35 Coffee

- 16:35 Use of multiplanar mode and 3D in diagnosis and teaching *G.R. DeVore (USA)*
 17:05 New technologies: tissue Doppler, 3D/4D *R. Chaoui (Germany)*
 17:35 Final discussion

Course 5 Office gynecology

Room: Mackenzie

Course Directors: T. Bourne (UK); S.R. Goldstein (USA)

Course aim: To demonstrate the role of ultrasound role in the management of common gynecological conditions seen in practice. Emphasis will be on short presentations of relevant data but speakers will aim to discuss clinical management, focusing on cases and video. The facilitator will encourage debate between the speakers and stimulate audience participation.

- 10:30 Welcome and introduction *T. Bourne (UK)*
 10:45 Emergency gynecology and assessing pelvic pain and infection in the office
Facilitator: S.R. Goldstein (USA)
Speakers: A.K. Parsons (USA); L.I.E. Valentin (Sweden)
 11:30 How do we manage miscarriage? What happens if no pregnancy can be seen at the time of the initial scan?
Facilitator: T. Bourne (UK)
Speakers: G. Condous (UK); E. Kirk (UK)
 12:15 The management of ectopic pregnancy: no treatment, medical treatment or surgery? (just images and case studies)
Facilitator: T. Bourne (UK)
Speakers: E. Kirk (UK); B. Cacciatore (Finland)

13:00–14:00 Lunch

- 14:00 A one-stop approach to assessing the fertility patient and assessing the ovary for potential fertility
Facilitator: S.L. Tan (Canada)
Speakers: R.A. Pierson (Canada); N.J. Raine-Fenning (UK)
 14:45 Investigating and treating women with problem periods. Should they all have sonohysterography?
Facilitator: A.K. Parsons (USA)
Speakers: F.P.G. Leone (Italy); S.R. Goldstein (USA)

15:30–16:00 Coffee

- 16:00 The endometrium after the menopause: can we use ultrasound to select women that need intervention?
Facilitator: S.R. Goldstein (USA)
Speakers: E. Ferrazzi (Italy); L.I.E. Valentin (Sweden)
 16:45 The management of ovarian pathology: using ultrasound to select women for surgery or conservative management (just images and case studies)
Facilitator: T. Bourne (UK)
Speakers: D. Timmerman (Belgium); A.C. Testa (Italy)
 17:30–18:00 Discussion and concluding remarks *T. Bourne (UK); S.R. Goldstein (USA)*



Monday 26 September 2005

08:30–09:40 Opening plenaries: Recent advances Room: Salons D–F

08:30	Chairs: K. Maršál (Sweden); J.W.K. Ritchie (Canada) Introduction and welcome <i>L.D. Platt (USA)</i>	
08:40	Developments in three-dimensional ultrasound in obstetrics <i>B. Benoit (France)</i>	OC1.01
09:00	The expanding role of magnetic resonance imaging in obstetrics and gynecology <i>D. Levine (USA)</i>	OC1.02
09:20	High-intensity focused ultrasound: the treatment of uterine fibroids and other potential applications <i>E.A. Stewart; M.J. So; F.M. Fennessy; N.J. McDannold; K. Hynynen; C.M.C. Tempny (USA)</i>	OC1.03

09:40–10:10 Coffee and poster viewing Exhibition area

10:10–11:30 Distinguished presentations Room: Salons D–F

Chairs: L.D. Platt (USA); A.L. Gagnon (Canada)
 Ian Donald Gold Medal lecture: Likelihood, privileges and obligations
J.C. Fouron (Canada)
 Ian Donald Technical Development lecture: Perspectives on ultrasound technology development
S. Maslak (USA)
 Keynote lecture: Editor's highlights: *Ultrasound in Obstetrics & Gynecology* over 15 years
S. Campbell (UK)
 Keynote lecture: The role of proteomics in obstetrics and gynecology
L. Hartwell (USA)

11:30–12:00 ISUOG Annual General Meeting Room: Salons D–F

12:00–14:00 Lunch Exhibition area

12:00–12:45 Poster discussion sessions

12:00–12:20	Poster session I: Chairs: J. Hyett (UK); G. Pilu (Italy) P01: Screening for chromosomal abnormalities	Room: Cypress 1 P01.01–P01.24
12:25–12:45	P02: Central nervous system	P02.01–P02.20
12:00–12:45	Poster session II: Chairs: B. Thilaganathan (UK); D. Pugash (Canada) P03: Fetal anatomy and fetal anomalies I	Room: Cypress 2 P03.01–P03.38
13:30–14:00	Poster viewing: (Poster session V) P07: Abnormal bleeding P08: Ovarian masses and gynecological malignancies	Room: Salon F P07.01–P07.14 P08.01–P08.13

14:00–15:30 Parallel: Central nervous system (CNS) I Room: Salons 1–2

14:00	Chairs: G. Malinge (Israel); A. Toi (Canada) Live scan demonstration <i>G. Pilu (Italy)</i>	
14:20	Video demonstration: Case illustrations of abnormalities <i>A. Toi (Canada)</i>	
14:35	Examination of the fetal brain by three-dimensional ultrasound: potential for routine neurosonographic studies <i>F.F. Correa; C. Lara; J. Bellver; J. Remohí; A. Pellicer; V. Serra (Spain)</i>	OC2.01
14:43	Sonographic characterization of the fetal cortex: a longitudinal study <i>B. Cohen-Sacher; T. Sagie-Lerman; D. Lev; G. Malinge (Israel)</i>	OC2.02
14:51	Objective evaluation of Sylvian fissure development by multiplanar three-dimensional ultrasound <i>P. Mittal; L.F. Gonçalves; J.P. Kusanovic; J. Espinoza; W. Lee; J.K. Nien; E. Soto; M.C. Treadwell; R. Romero (USA)</i>	OC2.03
14:59	Just images: Three-dimensional ultrasound and MRI in the assessment of fetal hydrocephalus <i>D. Jackson (USA)</i>	OC2.04
15:04	3D ultrasound evaluation of the fetal optic chiasm: a potential parameter for the differential diagnosis of developmental midline brain anomalies <i>J.P. Kusanovic; P. Mittal; L.F. Gonçalves; J. Espinoza; W. Lee; J.K. Nien; K. Richani; M.C. Treadwell; R. Romero (USA)</i>	OC2.05
15:12	"Intraventricular fused fornices": a marker for complex midline anomalies <i>J. Slevin; S. Blaser; D. Chitayat; H. Berger; W. Halliday; S. Keating; G. Ryan; A. Toi; S. Pantazi; C. Raybaud (Canada)</i>	OC2.06



Monday 26 September 2005

15:20 Long-term follow-up of prenatally diagnosed central nervous system anomalies OC2.07
J.H. Stupin; W. Henrich; M. Korell; K. von Weizsäcker; I. Grimmer; T. Michael; B. Stöver; J.W. Dudenhausen (Germany)

Related posters P02.01–P02.20

14:00–15:30 Parallel: Clinical dilemmas in obstetric ultrasound Room: Salons D–E

Chairs: Y. Ville (France); G. Ryan (Canada)

14:00 Overview: Can we justify the non-medical use of ultrasound?
Y. Ville (France)

14:10 Ultrasound in the daily practice: is it safe? OC3.01
J.S. Abramowicz; E. Sheiner (USA)

14:20 Informed consent and diagnostic accuracy
J.A. Copel (USA)

14:30 Discussion
J.S. Abramowicz¹; J.A. Copel¹; P.M. Doubilet¹; G. Ryan² (USA);²(Canada)

14:45 Dilemmas in fetal reduction OC3.03
L. De Catte; E. Sleurs; W. Foulon (Belgium)

15:00 Short-term outcome of trichorionic triplet pregnancies at 10–14 weeks: embryo reduction compared to expectant management OC3.04
A.T. Papageorghiou; V. Bakoulas; K. Avgidou; N. Sebire; K.H. Nicolaides (UK)

15:08 Prenatal diagnosis and outcome of congenital CMV infection in twin pregnancies OC3.05
S. Lipitz; Y. Yinon; S.Y. Yagel; M. Tepperberg; B. Feldman; R. Achiron; E. Schiff (Israel)

15:16 A comparison between prenatal diagnosis of severe fetal cytomegalovirus infection and postmortem examinations OC3.06
N. Léticée; T. Rossi; F. Jacquemard; F. Daffos (France)

14:00–15:30 Parallel: New techniques and technologies in gynecology Room: Salon F

Chairs: B. Goldberg (USA); D.H. Pretorius (USA)

14:00 Advances in ultrasound breast imaging
B. Goldberg (USA)

14:15 Ultrasound-guided interventional procedures in the breast
P.B. Gordon (Canada)

14:30 A critical appraisal of VOCAL imaging in gynecology OC4.01
N.J. Raine-Fenning (UK)

14:45 3D is an essential tool in gynecological imaging OC4.02
B. Benacerraf; T. Shipp; B. Bromley (USA)

15:00 Just images: The shadows of the IUD OC4.03
S.Y. Yagel; S.M. Cohen; D. Hochner-Celnikier; B. Messing; A. Lev-Sagie; D.V. Valsky (Israel)

15:05 What is the clinical relevance of major defects of the levator ani muscle? OC34.05
A. Steensma¹; H.P. Dietz² (Netherlands);²(Australia)

15:13 Computer assisted three-dimensional analysis of endometrial ultrasound images across the menstrual cycle OC4.05
R.A. Pierson; M.L. Kadash; A.R. Baerwald (Canada)

15:21 Changes in the gestational and yolk sac volumes with threatened and missed abortion by three-dimensional ultrasound OC4.06
I. Kweon; M.J. Kim; S.J. Kim; H.Y. Ahn; G.S.R. Lee; J.C. Shin (Republic of Korea)

15:30–16:00 Coffee and poster viewing Exhibition area

16:00–17:30 Parallel: Fetal heart I Room: Salons 1–2

Chairs: D. Paladini (Italy); D. Farquharson (Canada)

16:00 Live scan demonstration: First trimester
J.S. Carvalho (UK)

16:20 Video demonstration: Case illustrations of abnormalities in the first and early second trimesters
S.Y. Yagel (Israel)

16:30 Fetal cardiac output in fetuses at 11–14 weeks of gestation with increased nuchal translucency OC5.01
M. Bellotti; C. De Gasperi; I. Zucca; V. Bee; G. Rognoni; V. Fesslovà (Italy)

16:38 Detection rate of early fetal echocardiography and *in utero* development of congenital heart defects OC5.02
J. Smrcek; C. Berg; A. Geipel; U. Germer; U. Gembruch (Germany)

16:46 Routine transabdominal echocardiography at 11–14 weeks of gestation in fetuses with increased nuchal translucency OC5.03
M. Bellotti; V. Fesslovà; C. Lombardi; C. De Gasperi; V. Bee; G. Rognoni (Italy)



Monday 26 September 2005

16:54	Feasibility of first trimester screening of congenital heart disease with high frequency transabdominal probe <i>C. Lombardi; M. Bellotti; V. Fesslovà (Italy)</i>	OC5.04
17:02	Changes in fetal cardiac geometry with gestation: implications for three-dimensional fetal echocardiography <i>J. Espinoza; L.F. Gonçalves; J.K. Nien; W. Lee; J.P. Kusanovic; M.S. Schoen; M.C. Treadwell; R. Romero (USA)</i>	OC5.05
17:10	Three-dimensional echocardiography of the fetus using two-dimensional matrix array: the feasibility of multiplanar imaging <i>D. Maulik; R. Schiff; A. Lysikiewicz (USA)</i>	OC5.06
17:18	Comparison of 3D power Doppler ultrasound (3D-PDU) versus 3D with inversion mode rendering in 3D fetal echocardiography <i>R. Chaoui; K.S. Heling (Germany)</i>	OC5.07
	Related posters	P05.01–P05.29

16:00–17:30 Parallel: CNS II: controversies in managing abnormal findings Room: Salons D–E

	Chairs: G. Pilu (Italy); I.E. Timor-Tritsch (USA)	
16:00	Overview: Should all brain anomalies be referred for magnetic resonance imaging (MRI)? <i>G. Pilu (Italy)</i>	
16:05 (–17:00)	Discussion forum: Is MRI essential, preferential or unnecessary: a) in diagnosing and b) in managing absent corpus callosum? <i>G. Malinge (Israel)</i>	
16:10	Comments from panel <i>S. Blaser¹; D. Levine²; I.E. Timor-Tritsch²</i> <i>¹(Canada); ²(USA)</i>	
16:13	Is MRI essential, preferential or unnecessary: a) in diagnosing and b) in managing borderline ventriculomegaly? <i>S. Blaser (Canada)</i>	
16:18	Comments from panel <i>D. Levine¹; G. Malinge²; I.E. Timor-Tritsch¹</i> <i>¹(USA); ²(Israel)</i>	
16:21	Is MRI essential, preferential or unnecessary: a) in diagnosing and b) in managing partial agenesis of the vermis? <i>D. Levine (USA)</i>	
16:26	Comments from panel <i>S. Blaser¹; G. Malinge²; I.E. Timor-Tritsch³</i> <i>¹(Canada); ²(Israel); ³(USA)</i>	
16:29	Discussion <i>S. Blaser¹; D. Levine²; G. Malinge³; I.E. Timor-Tritsch²</i> <i>¹(Canada); ²(USA); ³(Israel)</i>	
17:00	Mild fetal ventriculomegaly: outcome related to sex and prenatal ventricular size (AW) in 211 cases <i>L. Masini; S. Ciotti; M. De Santis; G. Noia; M. Caldarelli; G. Tamburrini; R. Luciano; A. Caruso (Italy)</i>	OC6.01
17:08	Growth rate of corpus callosum in very premature infants <i>N. Anderson¹; I. Laurent²; N. Cook¹; T.E. Inder³</i> <i>¹(New Zealand); ²(France); ³(Australia)</i>	OC6.02
17:16	Posterior fossa and vermian morphometry in the characterization of fetal cerebellar abnormalities: a three-dimensional ultrasound study <i>D. Paladini; P. Volpe; M. Quarantelli (Italy)</i>	OC6.03
	Related posters	P02.01–P02.20

16:00–17:30 Parallel: Abnormal bleeding and the management of uterine pathology Room: Salon F

	Chairs: S.R. Goldstein (USA); P. Cooperberg (Canada)	
16:00	Overview <i>S.R. Goldstein (USA)</i>	
16:10	Assessing the endometrial cavity prior to surgery <i>D. Jurkovic (UK)</i>	OC7.01
16:25	A rational approach to assessing the uterus in women with abnormal bleeding <i>E. Ferrazzi; F.P.G. Leone; C. Lanzani (Italy)</i>	OC7.02
16:40	Symptomatic postmenopausal women with endometrial polyps removed by hysteroscopy: prevalence of atypical hyperplasia and cancer in a multicentre Italian study <i>E. Zupi; C. Exacoustos; F.P.G. Leone; M. Barbieri; A. Bulfoni; M.E. Coccia; E. Ferrazzi; P. Litta; U. Nicolini; L. Savelli; A.C. Testa; M. Vignali (Italy)</i>	OC7.03
16:48	Sonohysterography in the preoperative assessment of submucous myomas: an update <i>F.P.G. Leone; C. Lanzani; E. Ferrazzi (Italy)</i>	OC7.04



Monday 26 September 2005

16:56	Increasing detection of adenomyosis on ultrasound: imaging characteristics on transvaginal ultrasound using MRI as the gold standard <i>A. Lev-Toaff; D. Bergin; S. Chopra; F. Ors; D.G. Mitchell (USA)</i>	OC7.05
17:04	Arteriovenous malformations of the uterus: case series and a proposed protocol for management <i>P. Dar; S.J. Gross; I. Karmin; M.H. Einstein (USA)</i>	OC7.06
17:12	Uterine artery Doppler flow velocity following uterine fibroid embolization <i>Z. Novacovik; U. Kirste; E. Dorenberg; H. Husby; G. Haugen (Norway)</i>	OC7.07
17:20	Saline infusion for endometrial abnormalities: technique and findings in a small town <i>R. Sanders; C. Carlos; P. Combs (USA)</i>	OC7.08
	Related posters	P07.01–P07.14



International Society of Ultrasound in Obstetrics and Gynecology

Invitation to attend ISUOG's Annual General Meeting (AGM)

Monday 26 September 2005

11:30

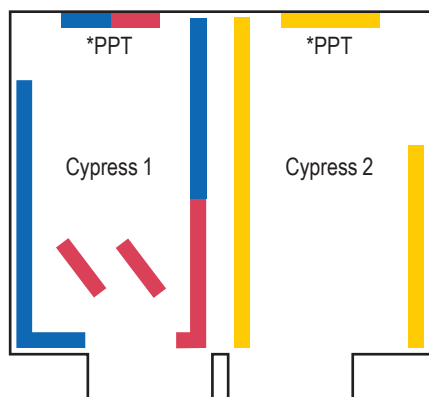
The Westin Bayshore Resort and Marina

Room: Salons D–F (level one)

Lunch will follow the AGM in the exhibition area

All fully paid delegates at ISUOG's 15th World Congress in Vancouver are automatically enrolled as members of ISUOG through to December 2006 and are encouraged to attend the AGM.

Monday poster sessions



Poster session

- Screening for chromosomal abnormalities
 - Central nervous system
 - Fetal anatomy and fetal anomalies I
- *PPT = PowerPoint presentations
Poster discussion sessions 12:00–12:45

Posters

- P01.10–P01.24
- P02.08–P02.20
- P03.20–P03.38

PowerPoint posters

- P01.01–P01.09
- P02.01–P02.07
- P03.01–P03.19

Monday 26 September 2005

Screening for chromosomal abnormalities

	Abstract no.	
Changing pattern of tertiary referrals for prenatal diagnosis in a major centre, Australia 1993–2002 <i>F.Y. Chan (Australia)</i>	P01.01	PPT
Screening for Down syndrome using first-trimester combined screening followed by second trimester detailed ultrasound examination: an economic evaluation <i>Y. Ville (France)</i>	P01.02	PPT
Screening for non chromosomal fetal malformations using first-trimester followed by second trimester detailed ultrasound examination: evaluation of the performance <i>Y. Ville (France)</i>	P01.03	PPT
Nasal bone assessment in first trimester detection of trisomy 21 <i>V. Borobio (Spain)</i>	P01.04	PPT
Second trimester sonographic markers in the risk calculation of Down syndrome <i>O. Torok (Hungary)</i>	P01.06	PPT
Do isolated choroid plexus cysts or an echogenic intracardiac foci warrant invasive genetic testing? <i>A. Ness (USA)</i>	P01.07	PPT
Contribution of fetal nasal bone measurement in midtrimester Down syndrome screening <i>R. Has (Turkey)</i>	P01.08	PPT
Increased NCAM expression and vascular development in trisomy 16 mouse embryos: relationship with nuchal translucency <i>M.N. Bekker (Netherlands)</i>	P01.09	PPT
Prenatal diagnosis of Patau syndrome: ultrasound and maternal serum screening: case report <i>D.F. Albu (Romania)</i>	P01.10	
Ultrasound and serum screening at 10–12 weeks of pregnancy with Down syndrome <i>D.F. Albu (Romania)</i>	P01.11	
Nuchal translucency reference range curve in the Espírito Santo State - Brazil <i>C.G.V. Murta (Brazil)</i>	P01.12	
Nuchal translucency in detection of aneuploidies <i>C.G.V. Murta (Brazil)</i>	P01.13	
First trimester screening is the most effective method of detecting Trisomy 21. An audit of the efficacy of the antenatal diagnosis of Trisomy 21 in a New Zealand region <i>J. Mitchell (New Zealand)</i>	P01.14	
Influence of sonographic markers in the second trimester of pregnancy on the risk of fetal Down syndrome in patients with advanced maternal age <i>M.R. Katagiri (Brazil)</i>	P01.15	
Is the karyotyping of fetuses with isolated choroid plexus cysts warranted? <i>C.T.C. Hsieh (Taiwan)</i>	P01.16	
Changing pattern of advanced maternal age and prenatal diagnostic procedures in a tertiary referral centre, Australia <i>F.Y. Chan (Australia)</i>	P01.17	
Women's knowledge and views of prenatal screening and diagnostic tests for fetal abnormality: an Irish perspective <i>C. Mulcahy (Republic of Ireland)</i>	P01.18	
Prenatal diagnosis of Down's syndrome in II and III trimester of pregnancy using ultrasound and echocardiography examination <i>K. Sadowski (Poland)</i>	P01.19	
Prenatal ultrasound findings in trisomy 18: report of 38 cases <i>J. Garwolinski (Poland)</i>	P01.20	
Prospective study on sonographic examination of Chinese fetal nasal bone in the screening of chromosomally abnormal fetuses in the mid-trimester <i>H.N. Xie (People's Republic of China)</i>	P01.21	

Monday poster sessions

	Abstract no.	
One year experience with first trimester screening with same day results <i>A. Ness (USA)</i>	P01.22	
Fetal nasal bone hypoplasia for ultrasound screening of chromosomal aneuploidy in high-risk pregnancy <i>S.Y. Kim (Republic of Korea)</i>	P01.23	
Multicenter study of nuchal translucency in Poland. A prospective study of 1,650 low-risk women <i>D. Borowski (Poland)</i>	P01.24	
Central nervous system		
Recurrence risk estimation after pregnancy termination based on sonographic detection of serious CNS anomalies <i>A. Kaasen (Norway)</i>	P02.01	PPT
Longitudinal development of the normal fetal brainstem <i>G. Malinger (Israel)</i>	P02.02	PPT
Cerebral ventriculomegaly: prenatal aspects and early post-natal evolution <i>N. Beurret Lepori (Switzerland)</i>	P02.03	PPT
Cerebral lateral ventricle width – an expression of ethnic diversity <i>Y. Romem (Israel)</i>	P02.04	PPT
Prenatal diagnosis of agenesis of the corpus callosum: advantages and pitfalls <i>O. Nevo (Canada)</i>	P02.05	PPT
The fetal cerebellar vermis: anatomy and biometry assessment using 4D volume contrast imaging in coronal plane <i>F. Vinals (Chile)</i>	P02.06	PPT
Outcomes of <i>in utero</i> subdural hemorrhages: three new cases <i>P. Heymans (Switzerland)</i>	P02.07	PPT
Potential pitfalls in fetal neurosonography <i>V. Serra (Spain)</i>	P02.08	
Holoprosencephaly, cyclops and proboscis: 3D ultrasonographic case <i>D. Prete (Brazil)</i>	P02.09	
The cisterna magna septa: a probable vestigial remnant of the roof of the rhombencephalic vesicle <i>A. Robinson (USA)</i>	P02.10	
Prenatal diagnosis of corpus callosum agenesis by ultrasound: outcome in 219 cases <i>J.P. Bault (France)</i>	P02.11	
Characteristics, associations and outcome of partial agenesis of corpus callosum in the fetus <i>P. Volpe (Italy)</i>	P02.12	
Prenatal diagnosis of Aicardi syndrome (AS) <i>J. Ochoa (Argentina)</i>	P02.13	
Rotation of the vermis in the fetus as a possible etiology for enlarged posterior fossa <i>Y. Zalel (Israel)</i>	P02.14	
Prenatal diagnosis of tetrasomy 9p associated to Dandy-Walker malformation <i>H. Werner (Brazil)</i>	P02.15	
Diagnosis and clinical attendance on fetuses with Galen's vein aneurysms: report of two cases <i>H. Werner (Brazil)</i>	P02.16	
Perinatal outcome of vein of galen aneurysms (VGA): report of two different cases. 3D Doppler color imaging <i>J. Ochoa (Argentina)</i>	P02.17	
Cerebral Doppler ultrasound in persistence of the ductus arteriosus in the premature infants <i>D.F. Albu (Romania)</i>	P02.18	
Prenatal diagnosis and further management of a huge fronto-orbito-nasal encephalocele: a case report <i>I. Špálová (Czech Republic)</i>	P02.19	
Prenatal diagnosis of enormous intra at extracranial teratoma <i>M. Ropacka (Poland)</i>	P02.20	
Fetal anatomy and fetal anomalies I		
First trimester screening in routine clinical practice in 5,189 pregnancies <i>A. Kossakiewicz (Germany)</i>	P03.01	PPT
Can severe macrosomia be detected at the time of nuchal translucency screening? <i>R. Hackmon (USA)</i>	P03.02	PPT
Early prenatal diagnosis of fetal structural abnormalities at first-trimester nuchal translucency screening <i>T. Kraemer (Germany)</i>	P03.03	PPT
Outcome of fetuses with an abnormality at 11–14 week scan <i>P.M. Boukobza (France)</i>	P03.04	PPT
Karyotyping or rapid testing: risk related indication and clinical implication of non-detected chromosomal disorders <i>P. Kozłowski (Germany)</i>	P03.05	PPT
First-trimester sonographic features of Trisomy 13 <i>A.T. Papageorgiou (UK)</i>	P03.06	PPT

Monday poster sessions

	Abstract no.	
Familial diseases revealed by a fetal anomaly <i>R. Robyr (France)</i>	P03.08	PPT
Sonographic features of Cornelia de Lange syndrome <i>D. Griffin (UK)</i>	P03.09	PPT
Hand positions in fetuses with Trisomy 18 <i>D. Levine (USA)</i>	P03.10	PPT
The incidence and significance of anomalies and soft markers after screening for Down syndrome by the integrated test <i>A. David (UK)</i>	P03.11	PPT
Linear insertion of the atrioventricular valves (LIAVV) without defect in trisomy: a new anatomical series of 243 new hearts <i>C. Fredouille (France)</i>	P03.12	PPT
Prenatal diagnosis of conotruncal anomalies: time to re-evaluate the best approach <i>F. Vinals (Chile)</i>	P03.13	PPT
Early diagnosis of fetal atrioventricular septal defects <i>J.M. Martínez (Spain)</i>	P03.14	PPT
Three-dimensional echocardiographic evaluation of ventricular septal defects in the fetus <i>M. Meyer-Wittkopf (Switzerland)</i>	P03.15	PPT
Perfect prenatal detection of congenital heart disease: is it a practical possibility? <i>C. McKenna (UK)</i>	P03.16	PPT
A nomogram of fetal clavicle length throughout gestation <i>M. Sokolovski (USA)</i>	P03.17	PPT
Sonographic diagnosis of Osteogenesis Imperfecta types IIB, III and IV <i>D. Griffin (UK)</i>	P03.18	PPT
Epiphysis and metaphysis prenatal ultrasound examination: normal aspect and a new sign for achondroplasia <i>J.P. Bault (France)</i>	P03.19	PPT
Changes in prenatal diagnosis and fetal medicine after the Perruche Case and the law passed on the 4th of March 2002 in France <i>N. Léticée (France)</i>	P03.20	
Cystic hygroma: natural history, diagnosis, management and outcome <i>G. Centini (Italy)</i>	P03.21	
Longitudinal volume analysis of jugular lymphatic sacs in fetuses with increased nuchal translucency <i>M.N. Bekker (Netherlands)</i>	P03.22	
Fetal defects and increased nuchal translucency thickness <i>L. Rosignoli (Italy)</i>	P03.27	
Determination of fetal gender by ultrasound at 11–14 weeks <i>S. The (Australia)</i>	P03.28	
Fetal Diagnostic Centre for Ultrasound and Echocardiography: ten years' experience <i>M. Respondek-Liberska (Poland)</i>	P03.29	
Sonotraining on the personal computer: innovative multimedia-software for further training in prenatal ultrasound diagnostics <i>H. Sedlaczek (Germany)</i>	P03.30	
Prenatal diagnosis of triploidy associated with sandal gap toe <i>S. Chandra (Canada)</i>	P03.31	
Prenatal ultrasound findings in trisomy 22: five case reports and a review of the literature <i>R. Stressig (Germany)</i>	P03.32	
Choroid plexus cysts as only marker of aneuploidies <i>J. Marin (Chile)</i>	P03.33	
Unusual presentation of DiGeorge syndrome <i>N. Léticée (France)</i>	P03.34	
Tri-dimensional ultrasonography suggestive of Costello syndrome, with identified PTPN11 mutation <i>J.M. Levailant (France)</i>	P03.35	
Sirenomelia: a case report <i>G.L. Fernandes (Brazil)</i>	P03.36	
Beare-Stevenson cutis gyrata syndrome with clover-leaf skull: two and three-dimensional findings <i>S.L. Lee (Singapore)</i>	P03.37	
Prenatal forehead edema in 4p- deletion, the "Greek warrior helmet" profile revisited <i>J.M. Levailant (France)</i>	P03.38	

Tuesday 27 September 2005

07:15–08:15 'Meet the Professor' breakfast sessions (registration required) Room: Marine

- The truth about 3D ultrasound
S. Campbell (UK)
S.R. Goldstein (USA)
 New concepts in prenatal diagnosis
J. Hobbins (USA)
 3D ultrasound of the fetus
W. Lee (USA)
 Why I'm addicted to 3D gynecological scanning
A.K. Parsons (USA)
 3D assessment of fetal cranio-facial development
J. Wladimiroff (Netherlands)

08:30–10:00 Parallel: Fetal face and neck Room: Salons 1–2

- Chairs: A.Z. Abuhamad (USA); D. Pugash (Canada)
- 08:30 Live scan demonstration
B. Benoit (France)
- 08:50 Video demonstration: Case illustrations of antenatal and postnatal anomalies
C. Verchere; D. Pugash (Canada)
- 09:10 Ultrasound measurement of the transverse diameter of fetal thymus OC8.01
J.Y. Cho¹; S.I. Jung¹; M.H. Moon¹; J.Y. Min¹; S.J. Yoo²
¹(Republic of Korea); ²(Canada)
- 09:18 Sonographic evaluation of the fetal hard palate and maxillary tooth buds OC8.02
L.F. Mok; S.L. Lee; S. Fook-Chong; D. Kanagalingam; H.K. Tan (Singapore)
- 09:26 Orbital measurements at 11–14 weeks of gestation OC8.03
N. Greene¹; J. Hyett²; L.D. Platt¹
¹(USA); ²(UK)
- 09:34 Prenatal diagnosis of an isolated cleft palate with 2D ultrasound: a case report OC8.04
C. McKenna (UK)
- 09:42 The association between the biparietal diameter and nasal bone ratio (BPD/NB) and fetal aneuploidy OC8.05
 in pregnancies between 15–22 weeks gestation
A. Odibo; L. Sprout; H.M. Sehdev; L. Dunn; G.A. Macones (USA)
- 09:50 Harlequin ichthyosis: sonographic findings at 25 weeks in an unsuspected pregnancy (case report) OC8.06
A. Kucinska-Chahwan; T. Roszkowski (Poland)

08:30–10:00 Parallel: Dilemmas in the management of mono chorionic twins Room: Salons D–E

- Chairs: J.W.K. Ritchie (Canada); A.L. Gagnon (Canada)
- 08:30 Discussion forum: OC9.01
 Selective fetocide in mono chorionic twins
J. Deprest¹; L. Lewi¹; E. Gratacos²; E. Ortibus¹; R. Devlieger¹; E. Carreras²
¹(Belgium); ²(Spain)
- 08:38 Chair to comment on ethics
J.W.K. Ritchie (Canada)
- 08:40 Randomized clinical trial of expectant management versus laser therapy for mono chorionic-diamniotic twin gestations OC9.02
 affected by selective intrauterine growth restriction and absent end-diastolic velocity of the umbilical artery
R.A. Quintero (USA)
- 08:48 Chair to comment on ethics
J.W.K. Ritchie (Canada)
- 08:50 Debate: Should we be performing selective fetocide in severe twin–twin transfusion syndrome (TTTS)?
 First speaker: *U. Nicolini (Italy)*
 Second speaker: *Y. Ville (France)*
- 08:58
- 09:06 Comments/reply
U. Nicolini (Italy)
- 09:08 Comments/reply
Y. Ville (France)
- 09:10 Discussion
J. Deprest¹; U. Nicolini²; R.A. Quintero³; Y. Ville⁴
¹(Belgium); ²(Italy); ³(USA); ⁴(France)
- 09:25 Long-term follow up of survivors of severe TTTS treated with laser OC9.03
K. Hecher; C. Graef; U. Herberg; M. Beck; A. Huber; P. Bartmann (Germany)

Tuesday 27 September 2005

09:35	Correlation of hemodynamic disturbances with the recipient death in TTTS <i>M. Ropacka; B. Kubiacyk; W. Markwitz; M. Dubiel; G.H. Breborowicz (Poland)</i>	OC9.04
09:43	Intertwin anastomoses in monozygotic placentas after fetoscopic laser coagulation for twin-twin transfusion syndrome: is there more than meets the eye? <i>L. Lewi¹; J. Jani¹; M. Cannie¹; R. Robyr²; Y. Ville²; K. Hecher³; E. Gratacos⁴; H. Vandecruys⁵; V. Vandecaveye¹; S. Dymarkowski¹; J. Deprest¹</i> ¹ (Belgium); ² (France); ³ (Germany); ⁴ (Spain); ⁵ (UK)	OC9.05
09:51	Reduction of the monozygotic pair in multifetal pregnancies improves outcome <i>V. Myers; D. Cramer; K. Rychlek; T. Finney; S. Weiner (USA)</i>	OC9.06
	Related posters	P06.01–P06.21

08:30–10:00 Parallel: Unsuspected findings in asymptomatic women Room: Salon F

	Chairs: L.I.E. Valentin (Sweden); E.A. Stewart (USA)	
08:30	Overview <i>L.I.E. Valentin (Sweden)</i>	
08:40	The endometrial echo revisited: have we created a monster? <i>S.R. Goldstein (USA)</i>	OC10.01
08:55	Asymptomatic endometrial polyps in postmenopausal women: sonographic surveillance or surgery? <i>F.P.G. Leone; C. Lanzani; T. Bignardi; C. Marciante; E. Ferrazzi (Italy)</i>	OC10.02
09:07	Recognising adhesions and para ovarian cysts <i>B. Cacciatore (Finland)</i>	
09:19	Predicting outcomes for fibroid therapies: Clinical research and genetics <i>E.A. Stewart; P. Somasundaram; K.L. Gross; E. Jones; C.C. Morton (USA)</i>	OC10.04
09:31	Endometrial thickness in post menopausal women: comparative study between patients with and without uterine bleeding <i>S. Valadares; M.J. Bernardo; S. Coutinho; I. Dias; N. Assunção (Portugal)</i>	OC10.05
09:39	Ultrasonographic findings in benign intrauterine lesions using power Doppler <i>E. Dreisler; S. Stampe Sorensen (Denmark)</i>	OC10.06
09:47	Asymptomatic endometrial polyps can be detected by power Doppler ultrasound <i>A. Jakab; L. Ovari; B. Juhasz; L. Birinyi; G. Bacsko; Z. Toth (Hungary)</i>	OC10.07

10:00–10:30 Coffee and poster viewing Exhibition area

10:30–12:00 Parallel: Fetal heart II Room: Salons 1–2

	Chairs: J.S. Carvalho (UK); K.I. Lim (Canada)	
10:30	Live scan demonstration <i>R. Chaoui (Germany)</i>	
10:50	Video demonstration: Case illustrations of key abnormalities in the second trimester <i>G.R. DeVore (USA)</i>	
11:00	Update on diagnosis and treatment of fetal arrhythmias (including video demonstration) <i>B.F. Cuneo; J. Strasburger; H. Zhao; R. Wakai (USA)</i>	OC11.01
11:15	Rendering in fetal echocardiography with STIC technology: evaluation of the “surgical plane” <i>S.Y. Yagel¹; A. Benachi²; D. Bonnet²; Y. Dumez²; D. Hochner-Celnikier¹; D.V. Valsky¹; L.Fermont²</i> ¹ (Israel); ² (France)	OC11.02
11:23	A new echographic marker for second–third trimester prenatal diagnosis of trisomy 21: the linear insertion of the atrioventricular valves without defect about 40,740 pregnancies <i>C. Fredouille; J.E. Develay-Morice; M. Gonzales; CFEF French College of Ultrasonography; M. Duyme (France)</i>	OC11.03
11:31	Fetal atrioventricular valves assessment using 4D volume rendering <i>F. Vinals; V. Pacheco; A. Giuliano (Chile)</i>	OC11.04
11:39	The “sad aorta” sign: prenatal diagnosis of anterior malposed aorta made easy <i>S. Abdullah; K. Lim; G.S. Sandor; R. Liston; D. Farquharson; J.C. Fouron (Canada)</i>	OC11.05
11:47	Off-line free angular M-mode: a useful diagnostic tool in fetal arrhythmias <i>K.E.C. De Groot; A. Iasci; J.S. Carvalho (UK)</i>	OC11.06
	Related posters	P05.01–P05.29

Tuesday 27 September 2005

10:30–12:00	Parallel: Controversies in the management of labour	Room: Salons D–E
	Chairs: B. Thilaganathan (UK); M.C. Van den Hof (Canada)	
10:30	Overview <i>B. Thilaganathan (UK)</i>	
10:40	Routine ultrasound on admission to the labour ward <i>A. Barbera (USA)</i>	OC12.01
10:50	Should ultrasound be performed before all operative deliveries? <i>J.A. Copel (USA)</i>	
11:00	Pelvic floor trauma in childbirth <i>H.P. Dietz (Australia)</i>	OC12.03
11:10	Engagement of the fetal head evaluated by perineal ultrasound in pregnancies with prelabor rupture of membranes <i>T.M. Eggebo; L.K. Gjessing; C. Heien; E. Smedvig; I. Økland; P. Rommunstad; K.Å. Salvesen (Norway)</i>	OC12.04
11:18	How to identify twins at low risk of spontaneous preterm delivery <i>L. Sperling; I. Qvist; C. Joergensen; K. Skajaa; A. Tabor (Denmark)</i>	OC12.05
11:26	Reference data representative of normal findings at 3D power Doppler ultrasound examination of the cervix from 17 to 41 gestational weeks <i>L. Rovas¹; P. Sladkevicius²; E. Strobel²; L. Valentin² ¹(Lithuania); ²(Sweden)</i>	OC12.06
11:34	<i>In utero</i> transfer in threatened preterm labour: can we avoid it by using transvaginal ultrasound scan assessment of the cervix? <i>A. Kulkarni; P. Wardle (UK)</i>	OC12.07
11:42	Clinical significance of antenatal sonographic diagnosis of a nuchal cord at term: double-blind prospective study <i>R. Levy; B. Furman; S. Oron; R. Arad; Z. Appelman; Z.J. Hagay (Israel)</i>	OC12.08
11:50	Just images: Three-dimensional assessment of the internal cervical os in pregnancies with and without premature labor or cervical incompetence <i>D. Jackson (USA)</i>	OC12.09
	Related posters	P11.01–P11.18

10:30–12:00	Parallel: Demonstrations and debates in gynecology I	Room: Salon F
	Chairs: A.K. Parsons (USA); R.A. Pierson (Canada)	
10:30	Overview: Improving research studies <i>A.K. Parsons (USA)</i>	
10:40	Case reports and video demonstration: Ultrasound and reproductive medicine <i>S.L. Tan (Canada)</i>	
10:55	Case reports and video demonstration: Ultrasound and reproductive medicine <i>R.A. Pierson (Canada)</i>	
11:10	3D power Doppler in the evaluation of painful leiomyomas and focal uterine thickening in pregnancy <i>S. Degani; A. Tamir; Z. Leibovitz; I. Shapiro; R. Gonen; G. Ohel (Israel)</i>	OC13.01
11:18	Localisation and removal of nonpalpable implanon devices with ultrasound: the first 3 years – a series of 200 patients <i>M. Gun (Australia)</i>	OC13.02
11:26	The clinical significance of sonographically detected fluid collection following hysterectomy <i>J. Har-Toov; S. Maslovitz; G. Fait; I. Wolman; I. Gull; R. Amster; A. Jaffa (Israel)</i>	OC13.03
11:34	Discussion forum: Statement on evidence-based management of asymptomatic endometrial pathology <i>E. Ferrazzi (Italy)</i>	
11:44	Discussion <i>A.K. Parsons¹; A.C. Testa²; S.L. Tan³ ¹(USA); ²(Italy); ³(Canada)</i>	
12:00–14:00	Lunch	Exhibition area

12:00–12:45	Poster discussion sessions	
12:00–12:45	Poster session III: Chairs: A.Z. Abuhamad (USA); A. Toi (Canada) P04: Fetal anatomy and fetal anomalies II: (Thorax and abdomen discussion forum)	Room: Cypress 1 P04.01–P04.54
12:00–12:45	Poster session IV: Chairs: Y. Ville (France); L. Morin (Canada) P05: Fetal heart (viewing only) P06: Multiple pregnancy (discussion forum)	Room: Cypress 2 P05.01–P05.29 P06.01–P06.22
12:00–12:20	Poster session V: Chairs: L.I.E. Valentin (Sweden); D. Jurkovic (UK) P07: Abnormal bleeding	Room: Salon F P07.01–P07.14
12:25–12:45	P08: Ovarian masses and gynecological malignancies	P08.01–P08.13

Tuesday 27 September 2005

14:00–15:30 Parallel: Thorax and abdomen Room: Salons 1–2

	Chairs: J. Wladimiroff (Netherlands); A. Toi (Canada)	
14:00	Overview: Antenatal prediction of lung hypoplasia remains problematic <i>J. Wladimiroff; J.A.M. Laudy (Netherlands)</i>	OC14.01
14:10	Live scan demonstration: Three-dimensional ultrasonography of the fetal thorax and abdomen – tips and tricks <i>W. Lee (USA)</i>	
14:30	Video demonstration: Case illustrations of abnormalities of the thorax and abdomen <i>H.G.K. Blaas (Norway)</i>	
14:40	Lung-to-head ratio and liver position to predict outcome in early diagnosed isolated left-sided diaphragmatic hernia fetuses: a multicenter study <i>J. Jani¹; A. Benachi²; R. Keller³; R. Favre²; O. Moreno⁴; H. Vandecruys⁵; M. Harrison³; J. Matis²; E. Gratacos⁴; K.H. Nicolaides⁵; J. Deprest¹</i> ¹ (Belgium); ² (France); ³ (USA); ⁴ (Spain); ⁵ (UK)	OC14.02
14:48	Prenatal evaluation of pulmonary volume and vascularity in congenital diaphragmatic hernia using three-dimensional ultrasonography <i>R. Ruano¹; M.C. Aubry²; B. Barthe²; V. Bunduki¹; M. Zugaib¹; Y. Dumez²; M. Dommergues²</i> ¹ (Brazil); ² (France)	OC14.03
14:56	Outcomes after the functional evaluation of fetal pulmonary vascular reactivity by the maternal hyperoxygenation test in diaphragmatic hernia <i>D. Wood; E. Done; S. Desai; A. Ness; J. Airoidi; R.E. Broth; V. Berghella; R.J. Librizzi; S. Weiner (USA)</i>	OC14.04
15:04	Feasibility of fetal gender assignment by ultrasound evaluation of the pelvic organs in second and third trimester <i>P. Glanc; S. Umranikar; D. Koff; G. Tomlinson; D. Chitayat (Canada)</i>	OC14.05
15:12	Fetal oesophagus scan screening: a new direct sign of normal, atresia, atresia with fistula and tubular duplication <i>J.E. Develay-Morice; G. Rathat; C. Fredouille; N. Frandji-Barbier; P. Marès (France)</i>	OC14.06
15:20	The impact of prenatal diagnosis of esophageal atresia <i>A. Brantberg; H.G.K. Blaas; S.H. Eik-Nes (Norway)</i>	OC14.07
	Related posters	P04.22–P04.54

14:00–15:30 Parallel: Fetal heart III: antenatal diagnosis of fetal cardiac defects and arrhythmias – does it make a difference? Room: Salons D–E

	Chairs: R. Chaoui (Germany); J.C. Fouron (Canada)	
14:00	Overview: How good a specialist cardiac scan is at 20 weeks at detecting cardiac defects accurately <i>J.C. Fouron (Canada)</i>	
14:08	How good is the routine obstetric cardiac scan? <i>S.H. Eik-Nes; E. Tegnander (Norway)</i>	OC15.01
14:16	What can we diagnose in the first trimester? <i>J.S. Carvalho (UK)</i>	OC15.02
14:24	The risk by nuchal translucency <i>J. Hyett (UK)</i>	OC15.03
14:32	Outcome of cardiac arrhythmias treated <i>in utero</i> <i>B.F. Cuneo; J. Leshko; M. Ovadia; J.C. Huhta (USA)</i>	OC15.04
14:40	Discussion <i>J.S. Carvalho¹; B.F. Cuneo²; S.H. Eik-Nes³; J.C. Fouron⁴; J. Hyett¹</i> ¹ (UK); ² (USA); ³ (Norway); ⁴ (Canada)	
15:00	Impact of training in the prenatal recognition of major cardiac anomalies <i>G. Michailidis; D. Wellesley; D.T. Howe (UK)</i>	OC15.05
15:08	Fetal PR interval: a comparison of electrical and mechanical methods <i>L. Pasquini; A. Seale; C. Belmar; S. Oseku-Afful; M. Thomas; H.M. Gardiner (UK)</i>	OC15.06
15:16	Isolated ventricular septal defects detected by colour Doppler flow: evolution during fetal and first year of life <i>A. Schwarze; U. Gembruch; M. Krapp; U. Germer; J. Smrcek; R. Axt-Fliedner (Germany)</i>	OC15.07
	Related posters	P05.01–P05.29

14:00–15:30 Parallel: Management of ovarian masses: achieving a consensus Room: Salon F

	Chairs: T. Bourne (UK); D.M. Miller (Canada)	
14:00	Overview <i>T. Bourne (UK)</i>	
14:10	The pros and cons of using mathematical models to predict malignancy in ovarian masses <i>D. Timmerman¹; A.C. Testa²; T. Bourne³; E. Ferrazzi²; C. Van Holsbeke¹; L. Valentin⁴</i> ¹ (Belgium); ² (Italy); ³ (UK); ⁴ (Sweden)	OC16.01



Tuesday 27 September 2005

14:25	Differential diagnosis of ovarian masses <i>J.L. Alcázar (Spain)</i>	OC16.02
14:40	Difficulties in characterising ovarian masses <i>I. Zalud (USA)</i>	OC16.03
14:55	Three-dimensional power Doppler ultrasound for discrimination between benign and malignant ovarian tumors <i>L. Jokubkiene; P. Sladkevicius; L. Valentin (Sweden)</i>	OC16.04
15:03	Sonoangiography with pulsed and color Doppler blood flow measurements and microvessel density assessment in malignant ovarian tumors <i>S. Czekierdowska; A. Czekierdowski; N. Stachowicz; J. Kotarski (Poland)</i>	OC16.05
15:11	The value of preoperative ultrasound in the selection of women with adnexal masses for laparoscopic surgery <i>J. Yazbek; J. Ben Nagi; E. Sawyer; S. Helmy; W.Y. Fok; D. Jurkovic (UK)</i>	OC16.06
15:19	Assessment of the vascular tree in ovarian tumors using 3D power Doppler ultrasound <i>P. Sladkevicius; L. Jokubkiene; L. Valentin (Sweden)</i>	OC16.07

Related posters P08.01–P08.13

15:30–16:00 **Coffee and poster viewing** *Exhibition area*

16:00–17:30 Parallel: Fetal skeleton *Room: Salons 1–2*

	Chairs: P. Jeanty (USA); D. Krakow (USA)	
16:00	Live scan demonstration <i>I. Meizner (Israel)</i>	
16:20	Overview and video demonstration: Skeleton dysplasia <i>D. Krakow (USA)</i>	
16:40	'The Shetland and the Clydesdale revisited': paternal height influences fetal humerus and femur length in the mid trimester <i>A. Wilde; M.J. Permezel; E.A. McCarthy; A. Ugoni; S.P. Walker (Australia)</i>	OC17.01
16:48	Relationship of three-dimensional volume decrease to two-dimensional linear shortening in pathologic fetal femur length <i>D. Jackson; N. Laymon (USA)</i>	OC17.02
16:56	Just images: Three- and two-dimensional sonography in the diagnosis of cranesynostosis <i>M.A. Rodríguez; G. Ripoll; E. Scazzocchio; C. Pedrero; M. Torrents; J. Mallafré (Spain)</i>	OC17.03
17:01	Just images: Four consecutive pregnancies affected by chondrodysplasia punctata in a woman with mixed connective tissue disease <i>K. Lim; D. Pugash; J.M. Friedman; S. Ensworth; L. Dahlgren; N. Kent (Canada)</i>	OC17.04
17:06	Arts and skeletal dysplasia <i>P. Jeanty (USA)</i>	

Related posters P04.07–P04.14

16:00–17:15 Parallel: Management of abnormal findings in obstetric ultrasound *Room: Salons D–E*

	Chairs: W. Sepulveda (Chile); R.A. Quintero (USA)	
16:00	Placenta accreta <i>B. Thilaganathan (UK)</i>	OC18.01
16:15	Case demonstrations and data on umbilical cord complications <i>W. Sepulveda (Chile)</i>	OC18.02
16:30	Just images: Isolated multiple large umbilical cord cysts and thick prominent Wharton's jelly <i>S. Abdullah; S.L. Yong; E. Lopez; S. Lalji; D. Pugash (Canada)</i>	OC18.03
16:35	Just images: Case report of a twin-pregnancy complicated by chorioamnionitis and placenta accreta: correlation between ultrasound, CT and MRI <i>F. Chantraine¹; P. Emonts¹; A. Thille¹; J.P. Schaaps¹; B.A. Tutschek²; J.M. Foidart¹ (Belgium); ²(Germany)</i>	OC18.04
16:40	Just images: Placental rim sign: a unique three-dimensional representation of circumvallate placentation <i>D. Jackson (USA)</i>	OC18.05
16:45	Ultrasonographic, pathologic and clinical prognostic factors in survival of fetuses with antenatally detected sacrococcygeal teratoma <i>D.H. Suh; S.M. Lee; S.E. Lee; S.S. Shim; J.S. Park; J.K. Jun; B.H. Yoon; H.C. Syn (Republic of Korea)</i>	OC18.06
16:53	Fetal echo and cardiovascular profile score (CVS) as a prognostic risk factor in fetal sacrococcygeal teratoma (SCT) <i>M. Respondek-Liberska; K. Janiak; S. Forsys (Poland)</i>	OC18.07
17:01	Intertwin venous flow imbalance in twin-twin transfusion syndrome (TTTS) <i>M. Yamamoto¹; J.P. Bernard²; Y. Takahashi²; F. Huard²; Y. Ville² (Chile); ²(France)</i>	OC18.08

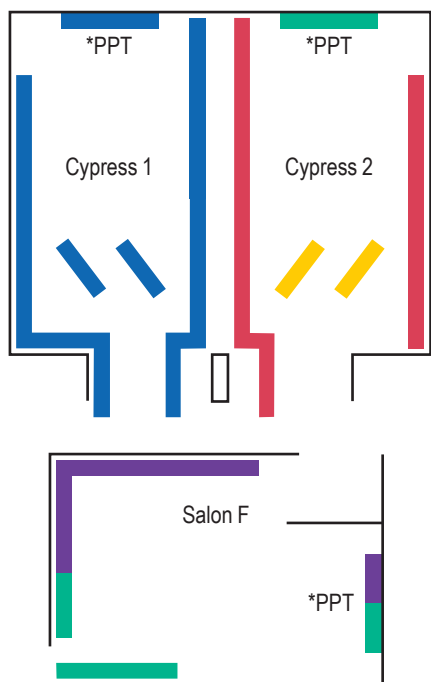
Tuesday 27 September 2005

16:00–17:15 **Parallel: Managing disorders of ovarian function and subfertility** Room: Salon F

	Chairs: S. Campbell (UK); S.L. Tan (Canada)	
16:00	Overview <i>S. Campbell (UK)</i>	
16:10	What can we learn about potential fertility from imaging the ovary? <i>R.A. Pierson (Canada)</i>	OC19.01
16:25	Colour Doppler and three-dimensional ultrasound and implantation of the human embryo <i>S.L. Tan (Canada)</i>	OC19.02
16:40	Three-dimensional vascular endometrial blood flow and “vascular cytokines”: a new approach of the uterine receptivity <i>N. Lédée; R. Lombroso; S. Dubanchet; Y. Hillion; C. Meynant; G. Chaouat; Y. Ville (France)</i>	OC19.03
16:48	Sonographic evaluation of posterior deep pelvic endometriosis: endovaginal-, transrectal- and vaginosonography to assess the extension of the disease <i>C. Exacoustos; A. Amadio; M.E. Romanini; C. Amoroso; B. Szabolcs; E. Zupi; D. Arduini (Italy)</i>	OC19.04
16:56	The use of a logistic regression model to predict early pregnancy viability in women undergoing IVF <i>J. Elson; C. Elson; T. Peachey; C. Fitzgerald; B. Lieberman (UK)</i>	OC19.05
17:04	Three-dimensional power Doppler imaging in polycystic ovary syndrome <i>Y.M. Mala; S.B. Ghosh; R. Tripathi (India)</i>	OC19.06



Tuesday poster sessions



Poster session	Posters	PowerPoint posters
Fetal anatomy and fetal anomalies II	P04.01–P04.21	
Thorax and abdomen	P04.30 P04.42–P04.54	P04.22–P04.29 P04.31–P04.41
Fetal heart	P05.01–P05.06 P05.10 P05.15–P05.16 P05.19–P05.29	P05.07–P05.09 P05.12–P05.13 P05.17–P05.18
Multiple pregnancy	P06.14–P06.21	P06.01–P06.13
Abnormal bleeding	P07.10–P07.14	P07.01–P07.07
Ovarian masses and gynecological malignancy	P08.07–P08.13	P08.01–P08.06

*PPT = PowerPoint presentations

Poster discussion sessions 12:00–12:45

Tuesday 27 September 2005

Fetal anatomy and fetal anomalies II

Abstract no.

Prenatal ultrasound diagnosis of fetal epidermolysis bullosa: case report <i>S. Alawami (Canada)</i>	P04.01
Prenatal 2D and 3D ultrasound of Stüve-Wiedemann syndrome <i>M.V. Senat (France)</i>	P04.02
Pfeiffer's syndrome type 2: case report <i>A. Melo (Portugal)</i>	P04.03
Unilateral facial cleft associated with increased nuchal translucency <i>D. Eroglu (Turkey)</i>	P04.04
Case presentation: monochorionic triplets each affected with cleft lip with or without cleft palate diagnosed by 3D ultrasound <i>S. Winsor (Canada)</i>	P04.05
A rare case of malignant cervical teratoma in twin pregnancy <i>G. Centini (Italy)</i>	P04.06
Prenatal diagnosis of diastematomyelia: review of eight cases <i>R. Has (Turkey)</i>	P04.08
Short femurs detected at 25 and 31 weeks of gestation diagnosed as Leroy I-cell disease in the postnatal period: a report of two cases <i>A. Yuksel (Turkey)</i>	P04.09
The prenatal ultrasound diagnostics of the absence of vertebral bodies in 20 weeks fetus with complex tumor in the spinal cord: a case report <i>L. Teregulova (Russia)</i>	P04.10
Fetal thanatophoric dysplasia-second trimester ultrasound examination <i>D.F. Albu (Romania)</i>	P04.11
Prenatal sonographic diagnosis of scoliosis and hemivertebra <i>Z. Toth (Hungary)</i>	P04.13
X-linked dominant chondrodysplasia punctata: presentation feature – premature punctate epiphyseal stippling <i>S. Umranikar (Canada)</i>	P04.14
Prenatal detection of single umbilical artery: accuracy of ultrasound and prediction of outcome <i>S. Gabrielli (Italy)</i>	P04.15
The giant umbilical cord <i>E. Antonelli (Switzerland)</i>	P04.16
Prenatal diagnosis of persisting right umbilical vein (PRUV): 3-dimensional sonography with power Doppler <i>P.Y. Yang (Taiwan)</i>	P04.17
Pitfalls in the sonographic diagnosis of vasa previa: confounding conditions and their implications <i>V. Catanzarite (USA)</i>	P04.18
Vena previa: prenatal sonographic diagnosis of a variant of vasa previa <i>D. Pugash (Canada)</i>	P04.19

Tuesday poster sessions

	Abstract no.	
Pre & postnatal imaging findings of fetal neoplasms <i>J.Y. Cho (Republic of Korea)</i>	P04.20	
Broad spectrum of ultrasound (US) findings of hydatidiform mole and molar mimicker <i>S.I. Jung (Republic of Korea)</i>	P04.21	
Thorax and abdomen		
Gender-specific fetal lung volume measured with 3-dimensional ultrasonography <i>F.A. Gerards (Netherlands)</i>	P04.22	PPT
3-Dimensional fetal lung volume measurements to predict pulmonary hypoplasia in pregnancies complicated by PROM <i>F.A. Gerards (Netherlands)</i>	P04.23	PPT
Lung volume assessment at midgestation with 3D ultrasound to predict pulmonary hypoplasia in fetuses with isolated congenital diaphragmatic hernia <i>J. Jani (Belgium)</i>	P04.24	PPT
Congenital diaphragmatic hernia: an evaluation of the prognostic value of the lung-to-head ratio and other ultrasound parameters <i>J. Pieles (Poland)</i>	P04.25	PPT
Evolution of antenatal detection and outcome in congenital diaphragmatic hernia (CDH): an 18 year French registry-based evaluation <i>J. Deprest (Belgium)</i>	P04.26	PPT
Outcome of fetal diaphragmatic hernia in a tertiary referral centre: 1997-2005 <i>J. Brewster (UK)</i>	P04.27	PPT
Population based cohort survey: prenatal diagnosis and outcome of congenital diaphragmatic hernia in UK <i>M.M. Khare (UK)</i>	P04.28	PPT
Is the finding of a central gall bladder an anatomic variant? <i>C. Lara (Spain)</i>	P04.29	PPT
Ultrasound findings of venous anomalies in the fetal liver <i>J.Y. Cho (Republic of Korea)</i>	P04.30	
Spontaneous resolution of fetal cholelithiasis <i>R. Hershkovitz (Israel)</i>	P04.31	PPT
Early sonographic diagnosis of fetal abdominal wall anomalies <i>L. Hernádi (Hungary)</i>	P04.32	PPT
Sonographic assessment of weight in fetuses with gastroschisis <i>L. Pereira (USA)</i>	P04.33	PPT
Prenatally diagnosed gastroschisis: the effect of changing mode of delivery <i>A.S. Letting (Norway)</i>	P04.34	PPT
Systematic review of morbidity of children diagnosed with gastroschisis <i>V. Mulik (UK)</i>	P04.35	PPT
Analysis of the hemodynamics of the renal artery and descending aorta in fetuses with renal disease using color Doppler ultrasound: longitudinal comparison to normal fetuses <i>I. Toshihiko (Japan)</i>	P04.36	PPT
Three-dimensional ultrasound estimation of fetal renal volumes in the second and third trimesters <i>D. Fauchon (Australia)</i>	P04.37	PPT
Fetal renal dilatation: a poor predictor for high grade vesicoureteric reflux <i>R. McEwing (New Zealand)</i>	P04.38	PPT
The value of the fetal renal pelvic anteroposterior diameter as a predictor of postnatal outcome <i>S.E. Lee (Republic of Korea)</i>	P04.39	PPT
Conservative treatment of pelvi-ureteric junction obstruction in children with antenatal diagnosis of hydronephrosis: lessons learned after 16 years of follow up <i>R. Rabinowitz (Israel)</i>	P04.40	PPT
Prenatal sonographic diagnosis of testicular torsion: a clinical dilemma <i>G. Fait (Israel)</i>	P04.41	PPT
A case of fetal hydrops in maternal Sjögren's syndrome with distal renal tubular acidosis <i>J.C. Shin (South Korea)</i>	P04.42	
Esophageal atresia and abnormal first trimester Doppler ultrasound of the ductus venosus: report of two cases <i>G.L. Fernandes (Brazil)</i>	P04.43	
Pentalogy of Cantrell: a case report <i>A.V. Carmo (Brazil)</i>	P04.44	
Cystic adenomatoid malformation type III: ultrasonographic findings <i>A.V. Carmo (Brazil)</i>	P04.45	
Increased nuchal translucency and Jeune's syndrome (Asphyxiating thoracic dystrophy) <i>L. Eslamian (Iran)</i>	P04.46	
Prenatal diagnosis of diffuse intrahepatic calcification <i>J. Brewster (UK)</i>	P04.47	
Prenatal imaging of fetal hepatoblastoma <i>R. Aviram (Israel)</i>	P04.48	

Tuesday poster sessions

	Abstract no.
Case series: Ductus venosus size in four fetuses with intra-abdominal masses <i>R.L. Arvon (USA)</i>	P04.49
Maternal smoking as a prognostic factor in prenatally diagnosed gastroschisis <i>A.S. Letting (Norway)</i>	P04.50
Unusual sonographic appearance of autosomal recessive polycystic kidney resembling medullary nephrocalcinosis <i>M. Okumura (Brazil)</i>	P04.51
Prenatal diagnosis of fetal urinoma <i>R. Aviram (Israel)</i>	P04.52
Prenatal diagnosis of meconium periorchitis <i>R. Aviram (Israel)</i>	P04.54
Fetal heart	
Is the nuchal index increased in fetuses with congenital structural heart defects? A prospective study <i>L. Dahlgren (Canada)</i>	P05.01
National database for fetal cardiac anomalies in 2004 <i>M. Respondek-Liberska (Poland)</i>	P05.02
The routine anomaly scan and detection of congenital heart disease <i>S. Kayani (UK)</i>	P05.03
Screening of congenital heart disease in a third world country: referral center <i>H. Munoz (Chile)</i>	P05.04
Antenatal diagnosis of cardiac anomalies in a Brazilian fetal medicine unit <i>G.L. Fernandes (Brazil)</i>	P05.05
Prenatal ultrasound diagnosis of complex congenital heart defects helps to choose rational tactics for delivery <i>I.G. Fedorova (Russia)</i>	P05.06
Sequential segmental analysis in the fetus with cardiac abnormalities <i>J.S. Carvalho (UK)</i>	P05.07 PPT
Technique of visualisation of a new cardiac marker for trisomy 21: the linear insertion of the atrioventricular valves (LIAVV) without defect <i>J.E. Develay-Morice (France)</i>	P05.08 PPT
Technique of fetal axial cardiac screening index (CSI) for generalists with or without three-dimensional equipment <i>D. Jackson (USA)</i>	P05.09 PPT
Prenatal diagnosis of congenital heart diseases using STIC Telemedicine (TELE-STIC) via internet link: preliminary results of 7 centers <i>F. Vinals (Chile)</i>	P05.10
Rendering with STIC technology in fetal echocardiography improves interatrial and interventricular septum evaluation <i>S.Y. Yagel (Israel)</i>	P05.12 PPT
Virtual casting of the fetal heart using live 3D ultrasound data processed by semi-automated internal surface detection <i>J. Deng (UK)</i>	P05.13 PPT
Prenatal diagnosis of two cases of right aortic arch <i>J.A. Duyos (Spain)</i>	P05.15
Prenatal diagnosis of right-sided aortic arch <i>M. Juan (Spain)</i>	P05.16
Fetal pulmonary artery diameters and ratios standardized for fetal biometric parameters <i>K. Lim (Canada)</i>	P05.17 PPT
Left ventricular aneurysm in a fetus complicated by arrhythmias <i>D. Wood (USA)</i>	P05.18 PPT
Constriction and complete occlusion of the ductus arteriosus associated with maternal use of acetaminophen <i>D. Wood (USA)</i>	P05.19
Prenatal diagnosis of ductus venosus agenesis: a report of two cases <i>G.L. Fernandes (Brazil)</i>	P05.20
Absent ductus venosus in a fetus resulting in a giant hepatic venous malformation and the Kasabach-Merrit syndrome <i>D. Wood (USA)</i>	P05.21
Ductus venosus dimensions during gestation <i>D. Wood (USA)</i>	P05.22
Congenital cytomegalovirus infection as a probable cause of premature closure of the foramen ovale <i>E. Carreras (Spain)</i>	P05.23
Fetal cardiac calcifications: report of four prenatally diagnosed cases <i>M.J. Simchen (Israel)</i>	P05.24
Cardiac rhabdomyomas <i>M.H. Billieux (Switzerland)</i>	P05.25
Cardiac rhabdomyoma in the left ventricular outflow tract of a fetus <i>K. Lim (Canada)</i>	P05.26

Tuesday poster sessions

	Abstract no.	
Fetal heart rate at 6,0 to 11,6 weeks of gestation <i>K. Wiêch (Poland)</i>	P05.27	
Evaluation of the fetal heart anatomy at 12,0 to 16,6 weeks of gestation <i>K. Wiêch (Poland)</i>	P05.28	
Evaluation of PR interval in fetuses of anti Ro positive pregnancies <i>L. Pasquini (UK)</i>	P05.29	
Multiple pregnancy		
Determination of chorionicity in twins gestation by 3D multiplanar ultrasound: measuring the thickness of the intraamniotic membrane <i>M.V. Senat (France)</i>	P06.01	PPT
Number of yolk sacs does not predict amnionicity in early first trimester monochorionic multiple gestations <i>O. Shen (Israel)</i>	P06.02	PPT
Discordant fetal infection for parvovirus in a dichorionic twin pregnancy <i>J.E. Dickinson (Australia)</i>	P06.03	PPT
Antenatal detection of arterio-venous (A-V) anastomoses in monochorionic twins: can we incorporate it in routine twin surveillance? <i>A. Sau (UK)</i>	P06.04	PPT
Naturally conceived twins with monochorionic placentation have the highest risk of fetal loss <i>L. Sperling (Denmark)</i>	P06.05	PPT
Natural history of amniotic fluid volume discordance in monochorionic-diamniotic twins <i>M. Swiatkowska-Freund (Poland)</i>	P06.06	PPT
Instability of Doppler cerebral blood flow in monochorionic twins <i>S. Degani (Israel)</i>	P06.07	PPT
TTTS before the limits of fetoscopic surgery <i>L. Lewi (Belgium)</i>	P06.08	PPT
Fetal echocardiography in twin-twin transfusion syndrome (TTTS) can identify risk factors for neonatal systemic hypertension (NSH) <i>J.E. Tolosa (USA)</i>	P06.09	PPT
The role of ultrasound assessment in predicting intrauterine fetal demise after fetoscopic laser photocoagulation for twin-twin transfusion syndrome <i>K. Ishii (Japan)</i>	P06.11	PPT
Changes in urine production using three-dimensional ultrasound in twin-twin transfusion syndrome treated by laser <i>M. Yamamoto (Chile)</i>	P06.12	PPT
Conservative management of acardiac twins: report of two cases <i>G.L. Fernandes (Brazil)</i>	P06.13	PPT
Four cases of a complete hydatidiform mole co-existing with a live fetus <i>M.Y. Kim (Republic of Korea)</i>	P06.14	
Diprosopus tetraophthalmos: a case report <i>A.V. Carmo (Brazil)</i>	P06.15	
Cojoined twins: thoracoomphalopagus <i>M. Ropacka (Poland)</i>	P06.16	
3D: a case of double twin <i>G. Centini (Italy)</i>	P06.17	
Monochorionic, diamniotic triplet pregnancy with cord entanglement <i>C.E. Portmann (Australia)</i>	P06.18	
Is twin pregnancy more vulnerable to cervical incompetence? <i>S.J. Choi (Republic of Korea)</i>	P06.19	
Normograms of the cervical length and cervical length changes in twin pregnancies: a prospective observational study <i>K.H. Park (Republic of Korea)</i>	P06.20	
Can we predict fetal growth from maternal weight changes in twin pregnancies? <i>K.J. Lee (South Korea)</i>	P06.21	
Abnormal bleeding		
Giant endometrial cyst of the uterine wall: a case report <i>M. Wielgos (Poland)</i>	P07.01	PPT
Recurrent uterine arteriovenous malformation after selective embolization and uneventful delivery <i>P. Dar (USA)</i>	P07.02	PPT
Deep lower abdominal pain caused by a hysterotomy defect in two post-caesarean non-pregnant women <i>L. Skibsted (Denmark)</i>	P07.03	PPT
Uterine vascular abnormality in a post-abortion case: a transitional sonographic finding in a tissue repair process <i>H.S. Wong (New Zealand)</i>	P07.04	PPT
Uterine fibroid embolization – inpatient vs outpatient therapy: a comparison of cost, safety and patient satisfaction <i>M. Baerlocher (Canada)</i>	P07.05	PPT
"Lollo-cath": a new intrauterine bioptic catheter for sonohysterography with endometrial sampling <i>F.P.G. Leone (Italy)</i>	P07.06	PPT

Tuesday poster sessions

	Abstract no.	
Sonohysterographic findings of endometrial abnormalities in women with polycystic ovary disease <i>E.J. Lee (South Korea)</i>	P07.07	PPT
Asymptomatic postmenopausal women with endometrial polyps removed by hysteroscopy: prevalence of atypical hyperplasia and cancer in a multicentre Italian study <i>F.P.G. Leone (Italy)</i>	P07.10	
Ultrasound guided IUD implantation <i>R.A.M. Sá (Brazil)</i>	P07.11	
Early endometrial changes following successful implantation post embryo transfer: a three-dimensional ultrasound study <i>E. Zohav (Israel)</i>	P07.12	
Assessment of physiological changes during the menstrual cycle by 3D/4D ultrasonography <i>A. Kratochwil (Austria)</i>	P07.13	
Dynamic assays of inhibin B, anti-Mullerian hormone and estradiol following FSH stimulation and ovarian ultrasonography as predictors of IVF outcome <i>R. Rabinowitz (Israel)</i>	P07.14	
Ovarian masses and gynecological malignancies		
Clear cell adenofibroma/fibrosarcoma of the ovary: ultrasound, macroscopic and histopathologic findings – a case report <i>P. Calda (Czech Republic)</i>	P08.01	PPT
Tissue block ultrasound and ovarian cancer diagnosis <i>M. Crade (USA)</i>	P08.02	PPT
Maternal adnexal masses: a diagnostic and management challenge <i>P. Glanc (Canada)</i>	P08.03	PPT
Bilateral asynchronous adnexal torsion: conservative sonographic-based management with laparoscopic detorsion and sparing of twisted ischemic adnexa <i>F.P.G. Leone (Italy)</i>	P08.04	PPT
Sigmoid endometriosis: sonographic-based conservative management by LNG-IUS <i>F.P.G. Leone (Italy)</i>	P08.05	PPT
Pre-operative staging of endometrial cancer: transvaginal sonography is the key <i>A.C. Testa (Italy)</i>	P08.06	PPT
The role of RI and PI index in the diagnostic of ovarian malignancy in clinic practice <i>M.A. Pascual (Spain)</i>	P08.07	
Fine needle aspiration (FNA) of adnexal cysts: 2 years' experience by a single operator <i>E. Almadani (Canada)</i>	P08.08	
Pelvic masses score (PMS): a new scoring system to evaluate pelvic masses <i>A. Rossi (Italy)</i>	P08.09	
Combined use of ultrasound and CA 125 level for predicting pelvic node metastasis in endometrial cancer <i>S.J. Kim (Republic of Korea)</i>	P08.10	
The great imitator: gastrointestinal stromal tumor mimicking malignant ovarian tumor <i>L. Hereter (Spain)</i>	P08.11	
Value of ultrasonography in diagnosis of pathological changes in ovaries <i>T. Urbaniak (Poland)</i>	P08.12	
Multiple regression analysis of ultrasonography parameters for differentiation diagnosis of malignant from benign ovarian lesions with abundant blood vessels <i>J. Zhang (People's Republic of China)</i>	P08.13	



Wednesday 28 September 2005

07:00–08:30 Preparing scientific presentations (registration required) **Room: Oak 1**
P. Jeanty (USA)

07:15–08:15 'Meet the Professor' breakfast sessions (registration required) **Room: Marine**
 Obstetrical sonography: tricks of the trade
A.Z. Abuhamad (USA)
B. Benoit (France)
T. Bourne (UK)
 Sonographic signs of microdeletion 22q11
R. Chaoui (Germany)
 3D/4D echocardiography: the latest and the greatest
G.R. DeVore (USA)
 Practical aspects of 3D ultrasound
D.H. Pretorius (USA)

08:30–10:00 Parallel: Fetal growth and well-being **Room: Salons 1–2**

Chairs: D. Maulik (USA); G. Ryan (Canada)

08:30 Overview: New approaches to old problems
D. Maulik (USA)

08:40 Predicting remaining time of pregnancy: a new approach to the prediction of day of delivery OC20.01
S.H. Eik-Nes; H.G.K. Blaas; P. Grøttum; H. Gjessing (Norway)

08:55 Live scan demonstration: Doppler and biophysical profile
A.A. Baschat (USA)

09:15 Volume flow estimation OC20.02
E. Ferrazzi; S. Rigano; A. Padoan; R. Rollo (Italy)

09:25 Middle cerebral artery peak systolic velocity: a new Doppler parameter in the evaluation of SGA fetuses with an abnormal umbilical artery OC20.03
G. Mari; M. Balasubramaniam; J. Nien; J. Kusanovic; J. Espinoza; L. Goncalves; E. Soto; J. Santolaya; M. Treadwell (USA)

09:35 Effects of maternal hyperoxia with and without normocapnia in utero placental and fetal Doppler studies OC20.04
M.J. Simchen¹; J. Tesler²; T. Azami²; D. Preiss²; L. Fedorko²; E. Goldszmidz²; J. Fisher²; J. Kingdom²; C.R. Storch²; L.K. Hornberger³
¹(Israel); ²(Canada); ³(USA)

09:43 Epidemiologic and statistical pitfalls in prediction models for fetal weight estimation OC20.06
W. Lee; M. Balasubramaniam; I. Chutkay; R.L. Deter; L.F. Goncalves; J. Espinoza; R. Romero (USA)

Related posters P10.01–P10.43

08:30–10:00 Parallel: Stump the Professor **Room: Salons D–E**

Chairs: A.L. Gagnon (Canada); P. Glanc (Canada)
 Panel: B. Benacerraf (USA); K. Hecher (Germany); P. Jeanty (USA); L.D. Platt (USA); I.E. Timor-Tritch (USA)

08:30 Just images: What's that cyst in your cervix? OC21.01
J.P. Schmidt; R.J. Gratton; B. Richardson; W. Dawson (Canada)

08:45 Just images: A fluttering of the fetal chest OC21.02
C.E. Portmann; S. Sinnott; R. Justo; P. Borzi (Australia)

09:00 Just images: So what's the chorionicity here? OC21.03
T.L. Pressey (Canada)

09:15 Just images: What's this colour below the fetal head? OC21.04
R.L. Arvon; M. O'Neill; G. Bega; S. Weiner (USA)

09:30 Just images: Is there any calcium in that skull? OC21.05
L.F. Goncalves; E. Soto; K. Richani; P. Devers; J. Espinoza; W. Lee; M.C. Treadwell; R. Romero (USA)

09:45 Just images: A fetus feeling bloated OC21.06
A. Ness; G. Bega; D.C. Wood; S. Weiner; V. Berghella (USA)

Wednesday 28 September 2005

08:30–10:00 Parallel: Magnetic resonance imaging (MRI) in obstetrics I Room: Salon F

	Chairs: D.A. Nyberg (USA); D. Levine (USA)	
08:30	Overview <i>D.A. Nyberg (USA)</i>	
08:40	Applicability of diffusion-weighted images in fetal MRI <i>S. Dymarkowski; M. Cannie; V. Vandecaveye; R. Devlieger; P. Demaerel; J. Deprest (Belgium)</i>	OC22.01
08:48	An evaluation of real-time MR single shot fast spin echo imaging in visualization of fetal midline corpus callosum and secondary palate <i>D. Levine; C. Cavazos; J. Kazan; R.F. Busse; V. Dialani; C. McKenzie; R. Robertson; C. Robson; T.Y. Poussaint; N. Rofsky (USA)</i>	OC22.02
08:56	Fetal growth and development of the posterior fossa and vermis and MRI <i>D.M. Twickler (USA)</i>	OC22.03
09:04	Fetal neurosonography and MRI in the diagnosis of malformations of cortical development <i>G. Malinge; T. Lerman-Sagie; C. Hoffmann; D. Kidron; D. Lev; L. Ben-Sira (Israel)</i>	OC22.04
09:12	Fetal CNS assessment by transvaginal 3D sonography and MRI <i>R.K. Pooh; K.H. Pooh (Japan)</i>	OC22.05
09:20	Multi-slice technique for 3D sonography <i>A. Kratochwil (Austria)</i>	OC22.06
09:28	MRI of fetal cerebral lesions in severe twin-twin transfusion syndrome: confrontation with ultrasound <i>M. Molho; E. Quarello; Y. Ville (France)</i>	OC22.07
09:36	Feasibility of MRI as preoperative guidance tool for laser coagulation in twin-twin transfusion syndrome <i>L. Lewi; M. Cannie; V. Vandecaveye; J. Jani; F. De Keyzer; S. Dymarkowski; J. Deprest (Belgium)</i>	OC22.08
09:44	Panel discussion: The future of MRI in obstetrics <i>All speakers</i>	

10:00–10:30 Coffee and poster viewing Exhibition area

10:30–12:00 Parallel: Clinical benefits of 3D ultrasound Room: Salons 1–2

	Chairs: T.R. Nelson (USA); P.T. Mohide (Canada)	
10:30	Live scan demonstration: 3D to reduce scan time <i>B. Benacerraf (USA)</i>	
10:50	Live scan demonstration: Fetal weight estimation using 3D <i>W. Lee (USA)</i>	
11:05	3D to assist in clinical diagnosis: video demonstration of fetal anomalies <i>E. Merz (Germany)</i>	
11:15	3D to assist in clinical diagnosis: video demonstration of fetal anomalies <i>D.H. Pretorius (USA)</i>	
11:25	Reference data representative of normal findings at 2D and 3D gray scale ultrasound examination of the cervix from 17 to 41 gestational weeks <i>L. Rovas¹; P. Sladkevicius²; E. Strobel¹; L. Valentin²</i> <i>¹(Lithuania); ²(Sweden)</i>	OC23.01
11:33	Assessment of cardiac function impairment by four-dimensional echocardiography with inversion mode rendering in fetal congenital heart disease <i>D. Paladini; P. Volpe; M. Vassallo; G. Sglavo; P. Martinelli (Italy)</i>	OC23.02
11:41	Sonographic tomography: a fundamental use of 3D ultrasound in fetal imaging <i>B. Benacerraf; T. Shipp; B. Bromley (USA)</i>	OC23.03
11:49	Questions to the speakers <i>L.D. Platt (USA)</i>	

10:30–12:00 Parallel: Intrauterine growth restriction (IUGR) I Room: Salons D–E

	Chairs: C. Brezinka (Netherlands); J. Kingdom (Canada)	
10:30	Overview: Progress in the management of IUGR <i>J. Kingdom (Canada)</i>	
10:40	Video demonstration: Left portal vein – watershed in fetal venous circulation <i>T. Kiserud (Norway)</i>	
10:50	Doppler, cardiotocography and biophysical profile <i>A.A. Baschat (USA)</i>	OC24.01
11:10	Long-term follow-up of IUGR <i>K. Maršál; D. Ley; J. Brodzki; E. Tideman; A. Hellstrom (Sweden)</i>	OC24.02
11:20	Changes in Doppler waveform of ductus venosus: a comparison between IUGR and congenital heart diseases <i>M. Bellotti; C. De Gasperi; I. Zucca; V. Bee; G. Rognoni (Italy)</i>	OC24.03

Wednesday 28 September 2005

11:28	Relationship between prenatal Doppler findings and neurodevelopmental outcome at 2 years of age in intrauterine growth restriction <i>A.A. Baschat; N. Hashmi; M.L. Kush; R. Viscardi; C.R. Harman (USA)</i>	OC24.04
11:36	The proportion of umbilical blood shunting through the ductus venosus in nonhuman primate fetuses <i>M. Tchirikov¹; H.J. Schröder¹; N. Schlabritz-Loutsevitch²; N. Beindorff¹; P.W. Nathanielsz²; K. Hecher¹ (Germany); ²(USA)</i>	OC24.05
11:44	Short-term effect of betamethasone administration on MCA blood flow velocimetry on preterm intrauterine growth restricted fetuses <i>A. Smolin; M. Mazor; E. Maymon; A. Bashiri; D. Dukler; A. Bolotin; A. Golan; R. HersHKovitz (Israel)</i>	OC24.06
11:52	Usefulness of measurement of the fetal thymus in the diagnosis of IUGR: a preliminary result <i>J.Y. Cho; S.I. Jung; M.H. Moon; J.Y. Min; M.J. Song; J.A. Kim; M.Y. Kim (Republic of Korea)</i>	OC24.07
	Related posters	P10.01–P10.43

10:30–12:00 Parallel: Demonstrations and debates in gynecology II Room: Salon F

	Chairs: T. Bourne (UK); P. Glanc (Canada)	
10:30	Case demonstration: Ovarian masses <i>D. Timmerman (Belgium)</i>	
10:45	Case demonstration: Recognising non-gynecological malignancy <i>J.P. Lerner (USA)</i>	
11:00	Intra- and interobserver agreement for morphologic assessment of adnexal masses using three-dimensional ultrasound <i>J.L. Alcázar; M. Garcia-Manero; C. Laparte; J.A. Minguez; M. Jurado; G. Lopez-Garcia (Spain)</i>	OC25.01
11:08	The role of sonographic examination in the follow up of gynecological neoplasms <i>A.C. Testa; E. Fruscella; M. Ludovisi; R. De Vincenzo; M. Malaggesi; D. Basso; G. Scambia; G. Ferrandina (Italy)</i>	OC25.02
11:16	A prospective evaluation of the ovarian crescent sign and the risk of malignancy index for the diagnosis of ovarian malignancy <i>J. Yazbek; K. Hillaby; J. Ben Nagi; E. Sawyer; S. Helmy; D. Jurkovic (UK)</i>	OC25.03
11:24	Malignant and benign adnexal tumors vascularity assessment with three-dimensional power Doppler sonography, soluble vascular adhesion molecule-1 (VCAM-1) and soluble endoglin (CD-105) measurements <i>A. Czekirowski; S. Czekirowska; A. Smolen; W. Bednarek; J. Kotarski (Poland)</i>	OC25.04
11:32	Discussion forum: Statement on evidence-based management of simple cysts in postmenopausal women <i>L.I.E. Valentin (Sweden)</i>	
11:42	Discussion <i>P. Glanc¹; J.P. Lerner²; D. Timmerman³; L.I.E. Valentin⁴ (Canada); ²(USA); ³(Belgium); ⁴(Sweden)</i>	

12:00–14:00 Lunch Exhibition area

12:00–12.45 Poster discussion sessions

12:00–12:45	Poster session VI: Chairs: M.D. Kilby (UK); G. Ryan (Canada) P09: Invasive procedures and fetal therapy	Room: Cypress 1 P09.01–P09.33
12:00–12:20	Poster session VII: Chairs: K. Hecher (Germany); J.A. Copel (USA) P10: Fetal growth and well-being	Room: Cypress 2 P10.01–P10.43
12:25–12:45	P11: Labour	P11.01–P11.18
12:00–12:20	Poster session VIII: Chairs: T. Bourne (UK); A.K. Parsons (USA) P12: Early pregnancy and acute gynecology	Room: Salon F P12.01–P12.16
12:25–12:45	P13: New technologies and gynecological oncology	P13.01–P13.08
	Poster viewing: P14: Urogynecology	P14.01–P14.05

14:00–15:30 Parallel: 11–14 week scan Room: Salons 1–2

	Chairs: A. Tabor (Denmark); K. Fong (Canada)	
14:00	Overview <i>A. Tabor (Denmark)</i>	
14:10	Live scan demonstration <i>D.A. Nyberg (USA)</i>	
14:30	Video demonstration: Case illustrations of abnormalities detected at 11–14 weeks <i>M. Bronshtein (Israel)</i>	
14:42	First trimester screening for trisomy 21: a statewide evaluation <i>J.E. Dickinson; P. O'Leary; N. Breheny; C. Bower; J. Goldblatt; N. Hadlow; B.G. Hewitt; A. Murch; R. Stock; S. Wilson (Australia)</i>	OC26.01
14:50	Umbilical cord diameter at 11–14 weeks of gestation: relationship to nuchal translucency, ductus venosus blood flow and chromosomal defects <i>A. Schwarze; P. Kreiselmaier; M. Krapp; J. Smrcek; R. Axt-Fliedner (Germany)</i>	OC26.02



Wednesday 28 September 2005

14:58	Outcome of fetuses with enlarged nuchal translucency and normal karyotype <i>C.M. Bilardo; M.A. Muller; E. Pajkrt; M.M. van Zalen; O.P. Bleker (Netherlands)</i>	OC26.03
15:06	Screening for chromosomal abnormalities by ductus venosus Doppler in the first trimester <i>C.G.V. Murta; A.F. Moron; L.C. França; F.A.P. Vasques; F.H.C. Carvalho; M.R. Kataguiri (Brazil)</i>	OC26.04
15:14	Chromosome analysis with increased resolution for fetuses with nuchal translucency >99% percentile and normal results from aneuploidy screening <i>K. Sundberg; M. Kirchoff; H. Rose; T. Bryndorf (Denmark)</i>	OC26.05
15:22	First trimester maternal serum level of pregnancy associated plasma protein A is an independent factor of fetal maxillary bone length <i>T.K. Lau; L.W. Chan; T.N. Leung; T.Y. Fung; D.S. Sahota; T.Y. Leung (Hong Kong)</i>	OC26.06

Related posters

from: P01.01–P01.24
P03.03–P03.24

14:00–15:30 Parallel: IUGR II Room: Salons D–E

	Chairs: K. Maršál (Sweden); J. Kingdom (Canada)	
14:00	Case reports: Optimal management / timing of delivery (Panel to give opinions on how to manage each case) <i>K. Maršál (Sweden)</i> Panellists: <i>C. Brezinka (Netherlands); K. Hecher (Germany); J. Kingdom (Canada); A.N. Papageorgiou (Canada)</i>	
14:35	Management and prognosis of IUGR infants <i>A.N. Papageorgiou (Canada)</i>	OC27.01
14:50	An economic analysis of the role of Doppler velocimetry and fetal biophysical profile in the timing of delivery of the preterm growth-restricted fetus <i>A.O. Odibo; G.A. Macones (USA)</i>	OC27.02
14:58	Qualitative venous Doppler flow waveform analysis in preterm IUGR-fetuses with ARED flow: correlation to short-term outcome <i>A. Schwarze; U. Gembruch; M. Krapp; U. Germer; J. Smrcek; R. Axt-Fliedner (Germany)</i>	OC27.03
15:06	Intervention thresholds for severe early onset growth restriction <i>A.A. Baschat¹; C. Bilardo²; U. Germer³; J. Hartung³; S. Rigano⁴; C. Berg³; M.L. Kush¹; A. Bhide⁵; H.L. Galan¹; B. Thilaganathan²; E. Ferrazzi²; K. Hecher³; U. Gembruch³; C.P. Weiner¹; C.R. Harman¹ (USA); ²(Netherlands); ³(Germany); ⁴(Italy); ⁵(UK)</i>	OC27.04
15:14	Human uterine artery blood volume flow at mid-gestation: relationship to uterine artery Doppler velocimetry and placental site <i>S. Rigano¹; S. Boito¹; G. Pennati¹; F. Gervaso¹; A. Padoan¹; L. Socci¹; P. Ficarazzi¹; G. Pardi¹; F.C. Battaglia²; E. Ferrazzi¹ (Italy); ²(USA)</i>	OC27.05
15:22	Second trimester diagnosis of severe placental insufficiency in women with elevations of either alpha-fetoprotein or human chorionic gonadotropin <i>J. Kingdom; M. Toal; D. Chitayat; A. Toi; R. Windrim; V. Chaddha (Canada)</i>	OC27.06

Related posters

P10.01–P10.43

14:00–15:30 Parallel: New technologies and gynecological malignancies Room: Salon F

	Chairs: D. Timmerman (Belgium); P. Cooperberg (Canada)	
14:00	Overview <i>D. Timmerman (Belgium)</i>	
14:10	The role of contrast media in the diagnosis and management of ovarian masses <i>A.C. Testa¹; G. Ferrandina¹; E. Fruscella¹; C. Van Holsbeke²; E. Ferrazzi¹; F.P.G. Leone¹; D. Arduini¹; C. Exacoustos¹; D. Bokor¹; G. Scambia¹; D. Timmerman² (Italy); ²(Belgium)</i>	OC28.01
14:25	The non-gestational uterus: how can magnetic resonance imaging help us better understand ultrasound? <i>P. Cooperberg (Canada)</i>	
14:40	Trials on animals and clinical patients of interventional alcoholic therapy in ovarian endometrial cysts <i>L.X. Wang; Y.L. Li; L.L. Zong; J.Y. Wang (People's Republic of China)</i>	OC28.02
14:48	Colour Doppler assessment of blood flow in cases of lymphatic metastases in endometrial cancer <i>W. Sawicki; B. Ćepiewankiewicz; J. Stelmachów; K. Cendrowski (Poland)</i>	OC28.03
14:56	Transvaginal ultrasound in comparison to MRI for the evaluation of early stages of cervical cancer <i>M. Hrehorcak; L. Rob; T. Belsan; M.J. Halaska; A. Slegrova; R. Vlk (Czech Republic)</i>	OC28.04
15:04	A new method of transvaginal ultrasound-guided polypectomy: a feasibility study <i>J. Ben Nagj; C. Lee; J. Yazbek; D. Ofili-Yebovi; A. Davies; D. Jurkovic (UK)</i>	OC28.05
15:12	Real-time 3D ultrasound imaging of the clitoris <i>J. Deng; N.S. Crouch; S.M. Creighton; A.D. Linney; A. Todd-Pokropek; C.H. Rodeck (UK)</i>	OC28.06

Wednesday 28 September 2005

15:20	3D transvaginal gynecological ultrasound using Accuvix XQ Prestige: an operator-independent examination <i>E. Fritz; J. Marin; M. Roman (Chile)</i>	OC28.07
15:28	SAFE-T-CHOICE: A new transvaginal ultrasound guided device to improve imaging in surgical abortions <i>R. Aviram; Z. Klein; Y. Beyth; M. Zeituni; A. Fishman (Israel)</i>	OC28.08
	Related posters	P13.01–P13.08

15:30–16:00 **Coffee and poster viewing** *Exhibition area*

16:00–17:30 Parallel: 18–23 week scan Room: Salons 1–2

	Chairs: J.C. Hobbins (USA); J.A. Johnson (Canada)	
16:00	Live scan demonstration: Screening markers <i>J.C. Hobbins (USA)</i>	
16:20	Video demonstration: Case illustrations of unusual anomalies <i>P. Jeanty (USA)</i>	
16:38	Iliac crest angle: a novel approach for detection of fetuses with Down syndrome <i>W. Lee; M. Balasubramaniam; M.D. Powell; L.F. Gonçalves; J. Espinoza; R. Romero (USA)</i>	OC29.01
16:46	Prevalence of an aberrant right subclavian artery (ARSA) in normal fetuses: a new soft marker for trisomy 21 risk assessment <i>R. Chaoui; G. Thiel; K.S. Heling (Germany)</i>	OC29.02
16:54	Fetal ovarian cysts: prenatal diagnosis and management <i>E. Antolín¹; R. Pérez¹; M.C. Viñuela¹; I. Ilic²; O. Martínez¹; L. Ortiz¹ (Spain); ²(Serbia)</i>	OC29.03
17:02	Just images: The flying fetus <i>C.E. Portmann; S. Sinnott (Australia)</i>	OC29.04
17:07	Just images: Ambiguous genitalia prenatal diagnosis: congenital adrenal hyperplasia <i>M.A. Rodríguez; C. Millán; P. Prats; M. Ruiz; M. Torrents; B. Serra (Spain)</i>	OC29.05
17:12	Just images: Ultrasound diagnosis of ectopia cordis and anencephaly associated with amniotic bands <i>I.D. Burd; J.K. Baxter; G. Bega; D.C. Wood; M. Hamel; V. Berghella; S. Weiner (USA)</i>	OC29.06
17:17	Just images: The tale of the caudal appendage <i>C.E. Portmann; B. Sutton; S. Sinnott (Australia)</i>	OC29.07
17:22	Prenatal diagnosis of an isolated fetal malformation: the accuracy of ultrasound in excluding additional anomalies <i>M. Segata; M. Piva; A. Banfi; S. Grotti; A. Perolo; D. Prandstraller; N. Rizzo; G. Pilu (Italy)</i>	OC29.08
	Related posters	from: P03.01–P03.38 P04.01–P04.21

16:00–17:40 Parallel: Fetal surgery Room: Salons D–E

	Chairs: J. Deprest (Belgium); R.A. Quintero (USA)	
16:00	Developments in the management of fetal lung abnormalities <i>G. Ryan (Canada)</i>	
16:10	Developments in the dilatation of cardiac valves <i>C.B. Benson (USA)</i>	OC30.02
16:20	Developments in fetal intervention for congenital diaphragmatic hernia <i>J. Deprest¹; J. Jani¹; E. Gratacos²; A. Greenough³; K. Allegaert¹; V. Martinez-Ibanez² (Belgium); ²(Spain); ³(UK)</i>	OC30.03
16:30	Developments in amniopatch <i>R.A. Quintero; E.V. Kontopoulos; R.H. Chmait; P.W. Bornick; M.H. Allen (USA)</i>	OC30.04
16:40	Obstructive uropathy: the time to re-think fetal therapy? <i>M.D. Kilby (UK)</i>	OC30.04a
16:50	Developments in the treatment of twin–twin transfusion syndrome <i>R.H. Ball (USA)</i>	OC30.05
17:00	Improving results with percutaneous fetal endoscopic tracheal occlusion for severe left congenital diaphragmatic hernia: a controlled study <i>J. Jani¹; E. Gratacos²; H. Vandecruys³; K. Allegaert¹; E. Carrera²; A. Greenough³; J.L. Peiro²; K.H. Nicolaidis³; J. Deprest¹ (Belgium); ²(Spain); ³(UK)</i>	OC30.06
17:08	Selection of cases for fetal pulmonary valvuloplasty <i>H.M. Gardiner; L. Pasquini; A. Barlow; C. Belmar; R. Franklin; P.D. Daubeney; M.L. Rigby; S. Kumar (UK)</i>	OC30.07
17:16	Stage-related outcome in severe mid-trimester twin–twin transfusion syndrome treated by fetoscopic laser coagulation <i>A. Huber; W. Diehl; T. Bregenzer; B.J. Hackelöer; K. Hecher (Germany)</i>	OC30.08

Wednesday 28 September 2005

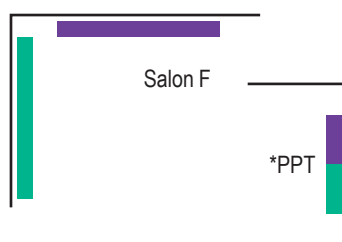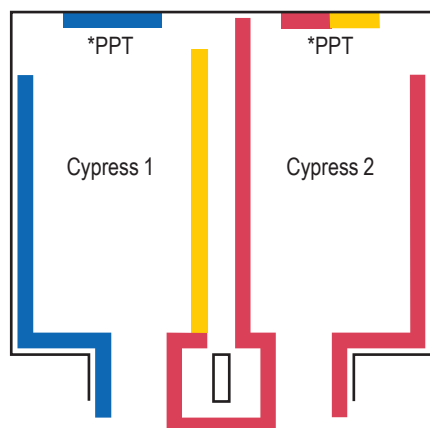
17:24	Weight discordance decreases after laser therapy for twin–twin transfusion syndrome <i>R. Chmait¹; Y.L. Chang²; P.W. Bornick¹; R.A. Quintero¹</i> ¹ (USA); ² (Taiwan)	OC30.09
17:32	Learning curve for fetoscopic laser surgery for severe twin–twin transfusion syndrome can be shortened <i>F.Y. Chan¹; R. Cincotta¹; B. Soong¹; P. Bornick²; M. Allen²; R.A. Quintero²</i> ¹ (Australia); ² (USA)	OC30.10
	Related posters	P09.01–P09.33

16:00–17:30 Parallel: Acute gynecology and ectopic pregnancy Room: Salon F

	Chairs: T. Bourne (UK); A. Ngu (Australia)	
16:00	Overview <i>T. Bourne (UK)</i>	
16:10	Diagnosing ectopic pregnancy <i>G. Condous (UK)</i>	OC31.01
16:25	Evidence-based management of tubal ectopic pregnancy <i>B. Cacciatore (Finland)</i>	
16:40	The role of ultrasound in acute gynaecology and its impact on management <i>Z. Haider; G. Condous; E. Kirk; A. Khalid; A. Syed; T. Bourne (UK)</i>	OC31.03
16:48	Can the ultrasonographic appearance of an ectopic pregnancy determine the likelihood of success for the conservative management? <i>E. Kirk¹; G. Condous¹; Z. Haider¹; T. Chang¹; B. Van Calster²; T. Bourne¹</i> ¹ (UK); ² (Belgium)	OC31.04
16:56	Prevalence of pathology in women presenting with pelvic pain and/or bleeding to an inner London acute gynaecology unit <i>Z. Haider; G. Condous; A. Khalid; E. Kirk; A. Syed; T. Bourne (UK)</i>	OC31.05
17:04	Sonographic appearance of the uterine cavity following treatment with mifepristone and misoprostol for termination of pregnancy <i>R. Aviram; Z. Klein; A. Fishman; R. Tepper; O. Markovitch (Israel)</i>	OC31.06
17:12	Can the hCG ratio be used to predict likelihood of success of conservative management of ectopic pregnancies? <i>E. Kirk¹; O. Gevaert²; Z. Haider¹; G. Condous¹; T. Bourne¹</i> ¹ (UK); ² (Belgium)	OC31.07
17:20	What is the optimal approach to accurately classifying failing pregnancies of unknown location (PULs)? <i>G. Condous¹; E. Kirk¹; Z. Haider¹; B. Van Calster²; S. Van Huffel²; D. Timmerman²; T. Bourne¹</i> ¹ (UK); ² (Belgium)	OC31.08
17:28	Just images: Conservative ultrasound-based management of cervical heterotopic pregnancy <i>F.P.G. Leone; T. Bignardi; A. Pigni; M.L. Muggiasca; E. Ferrazzi (Italy)</i>	OC31.09
	Related posters	P12.01–P12.16



Wednesday poster sessions



Poster session

	Invasive procedures and fetal therapy
	Fetal growth and well being
	Labour
	Early pregnancy and acute gynecology
	New technologies and gynecological oncology
	Urogynecology

*PPT = PowerPoint presentations

Poster discussion sessions 12:00–12:45

Posters

P09.21–P09.33
P10.14–P10.31 P10.33–P10.43
P11.09–P11.18
P12.12–P12.16
P13.07–P13.08

PowerPoint posters

P09.01–P09.20
P10.01–P10.12 P10.32
P11.01–P11.08
P12.01–P12.11
P13.01–P13.06
P14.01–P14.05

Wednesday 28 September 2005

Invasive procedures and fetal therapy

	Abstract no.	
Correlations between ultrasound and fetal haematological parameters in 67 fetuses infected with cytomegalovirus (CMV) <i>F. Jacquemard (France)</i>	P09.01	PPT
Transabdominal embryofetoscopy: 6 cases of first trimester prenatal diagnosis for congenital anomalies <i>K. Lee (Republic of Korea)</i>	P09.02	PPT
Evaluation of the complications of amniocentesis in pregnant women with uterine myomas <i>A. Yuksel (Turkey)</i>	P09.03	PPT
Amniocentesis: no longer "a shot in the dark" <i>P. Tripathi (UK)</i>	P09.04	PPT
A randomized single blinded trial of subfreezing versus room temperature needles to reduce pain with amniocentesis <i>J. Wax (USA)</i>	P09.05	PPT
Pregnancy outcome in rh alloimmunized patients managed through amniotic fluid spectrophotometry or Doppler ultrasonography of the fetal middle cerebral artery <i>L. Nardoza (Brazil)</i>	P09.06	PPT
Measurement of fetal middle cerebral artery peak systolic velocity before and after intrauterine transfusions <i>A.V. Carmo (Brazil)</i>	P09.07	PPT
Expectant management in unexplained fetal anemia: report of two cases and proposal for a registry <i>V. Catanzarite (USA)</i>	P09.08	PPT
Selective fetoscopic laser ablation therapy for twin–twin transfusion syndrome <i>M. Walker (USA)</i>	P09.09	PPT
Fetoscopic laser ablation of the placental vascular equator in twin–twin transfusion syndrome <i>A.T. Papageorghiou (UK)</i>	P09.10	PPT
Is decreased individual placental territory responsible for umbilical artery absent/reverse end-diastolic velocity in twin–twin transfusion syndrome? <i>R.A. Quintero (USA)</i>	P09.11	PPT
Fetoscopic laser photocoagulation of communicating vessels for twin–twin transfusion syndrome: Japanese 2 years' experiences and considering Stage 3 sub-classification <i>T. Murakoshi (Japan)</i>	P09.12	PPT
The impact of laser therapy on fetal growth discordance in twin–twin transfusion syndrome <i>R. Sa (Brazil)</i>	P09.13	PPT
Analysis of fetal growth following laser therapy in twin–twin transfusion syndrome <i>R. Sa (Brazil)</i>	P09.14	PPT
Recurrence of twin–twin transfusion syndrome (TTTS) and feto-fetal hemorrhage: two complications of laser treatment with distinct ultrasound features <i>R. Robyr (France)</i>	P09.15	PPT
Decrease in recipient to donor fetal venous flow imbalance (R/D index) in twin–twin transfusion syndrome after successful laser treatment <i>M. Yamamoto (Chile)</i>	P09.16	PPT

Wednesday poster sessions

	Abstract no.	
Radiofrequency ablation for twin reversed arterial perfusion sequence <i>S. Hayashi (Japan)</i>	P09.17	PPT
Intrauterine repair of spina bifida: short-term clinical outcomes <i>A. Fernandes Moron (Brazil)</i>	P09.18	PPT
Validation of the ovine fetus as an experimental model for the human myelomeningocele defect: preliminary results <i>D.A.L. Pedreira (Brazil)</i>	P09.19	PPT
Fetal therapeutic bronchoscopy in animal model: modified technique, applications and perspectives <i>D.A.L. Pedreira (Brazil)</i>	P09.20	PPT
Amniocentesis should always be performed in women with a dilated cervix in the 2nd trimester: results from the GNPRH international cohort study <i>L. Pereira (USA)</i>	P09.21	
Amniocentesis and ductus venosus Doppler blood flow velocity waveforms <i>A. Helbig (Norway)</i>	P09.22	
Transabdominal chorionic villus for prenatal diagnosis: 3½ years' experience at a tertiary centre <i>A. Jerullo (UK)</i>	P09.23	
Pain associated with transabdominal chorionic villus sampling: anticipated versus actual <i>J. Wax (USA)</i>	P09.24	
Middle cerebral artery peak systolic velocity and the prediction of fetal anaemia in alloimmunized pregnancies: Experience from a developing country <i>F. Alkazaleh (Jordan)</i>	P09.26	
Selective termination in complicated monochorionic pregnancies <i>B. Puerto (Spain)</i>	P09.27	
Laser therapy for fetal treatment in complicated monochorionic twin pregnancies: experience in Brazil <i>D.A.L. Pedreira (Brazil)</i>	P09.28	
Preliminary experience with endoscopic laser surgery for severe TTTS <i>C. Vayssiere (France)</i>	P09.29	
Perinatal outcomes with laser therapy for severe twin–twin transfusion syndrome <i>F.Y. Chan (Australia)</i>	P09.30	
Intrauterine vesicoamniotic shunt of posterior urethral valve at early second trimester <i>J.C. Shin (South Korea)</i>	P09.31	
Fetal surgery for cystic adenomatoid malformation: a case report <i>G.L. Fernandes (Brazil)</i>	P09.32	
Successful management of a congenital oral tumor by ex utero intrapartum treatment (EXIT) procedure <i>M. Nakata (Japan)</i>	P09.33	
Fetal growth and well-being		
A new three-dimensional (3D) ultrasound formula to optimize weight estimation in the small fetus remote from term <i>J. Siemer (Germany)</i>	P10.01	PPT
Validation of fetal weight estimation models: a review of the world's literature <i>W. Lee (USA)</i>	P10.02	PPT
Relationship between estimated fetal weight and amniotic fluid index in the third trimester <i>N. Vohra (USA)</i>	P10.04	PPT
Nitric oxide donors and fluid therapy increase fetal growth in gestational hypertension <i>H. Valensise (Italy)</i>	P10.05	PPT
The relationship of Doppler and biophysical parameters in growth restricted fetuses (IUGR) <i>A.A. Baschat (USA)</i>	P10.06	PPT
Inferior vena cava and ductus venosus Doppler in preterm IUGR fetuses <i>G. Mari (USA)</i>	P10.07	PPT
Can perinatal mortality in IUGR fetuses delivered at less than 28 weeks' gestation be predicted by the product of MCA PSV and DV PI? <i>G. Mari (USA)</i>	P10.08	PPT
Uterine venous flow in normal and complicated pregnancies: a methodological study <i>A. Thuring (Sweden)</i>	P10.09	PPT
Three-dimensional ultrasonographic assessment of placental volumes in pregnancies complicated by absent umbilical diastolic flow: initial results <i>R. Ruano (Brazil)</i>	P10.10	PPT
Quantitative evaluation of placental vasculature in pregnancies with absent umbilical diastolic flow by 3D-power ultrasonography <i>R. Ruano (Brazil)</i>	P10.11	PPT
Fetal renal blood flow velocimetry in patients with idiopathic oligohydramnios <i>R. Hershkovitz (Israel)</i>	P10.12	PPT
The Singapore General Hospital charts of fetal size: head circumference, abdominal circumference and femur length <i>H.K. Tan (Singapore)</i>	P10.14	

Wednesday poster sessions

	Abstract no.	
French fetal biometry: reference equations and comparison with other charts <i>P. Boukobza (France)</i>	P10.15	
Intrauterine growth velocity in assisted reproduction and spontaneous pregnancies <i>B.C.P. Chan (Hong Kong)</i>	P10.17	
Ultrasound-determined fetal subcutaneous tissue thickness (SCTT) for a birthweight prediction model <i>H. Valensise (Italy)</i>	P10.18	
Intrauterine growth restriction and fetal body composition <i>H. Valensise (Italy)</i>	P10.19	
Fetal orbital biometry: a cross-sectional study <i>A.C. Kuah (Singapore)</i>	P10.20	
The outcome of IUGR with oligohydramnios identified at routine morphology ultrasound <i>C. Portmann (Australia)</i>	P10.21	
A prospective trial of the fetal biophysical vs the modified biophysical in the management of high-risk pregnancies <i>A. Jamal (Iran)</i>	P10.22	
Doppler assessment of the fetal aortic isthmus blood flow in small for gestational age and growth restricted fetuses <i>M. del Rio (Spain)</i>	P10.23	
Doppler, NST and biophysical profile changes in severe IUGR: a longitudinal prospective randomized study <i>E. Cosmi (Italy)</i>	P10.25	
Temporal sequence of hemodynamic changes in severe IUGR fetuses: a randomised study <i>E. Cosmi (Italy)</i>	P10.26	
The size of the ductus venosus in fetal growth restriction <i>J. Airolidi (USA)</i>	P10.27	
Ductus venosus velocimetry in the prediction of fetal acidemia: which is the best parameter? <i>C.G.V. Murta (Brazil)</i>	P10.28	
Venous-arterial pulsatility index in the prediction of fetal acidemia in pregnancies with placental insufficiency <i>C.G.V. Murta (Brazil)</i>	P10.29	
Transverse cerebral sinus Doppler velocimetry in the prediction of birth acidemia <i>C.G.V. Murta (Brazil)</i>	P10.30	
Is Doppler reversed flow of the ductus venosus an indication for prompt delivery of the extremely IUGR fetus at less than 28 weeks' gestation? <i>G. Mari (USA)</i>	P10.31	
Qualitative venous Doppler waveform and computerized cardiotocogram analysis in relation to intrauterine death: a report of five cases <i>Y. Chitrit (France)</i>	P10.32	PPT
Umbilical artery Doppler velocimetry in growth restricted fetuses at extreme of prematurity <i>K. Khadawardi (Canada)</i>	P10.33	
Middle cerebral artery Doppler utility in fetal-maternal hemorrhage <i>J. Airolidi (USA)</i>	P10.34	
Is notching in the umbilical artery Doppler waveform a benign finding? A case report <i>R. Hackmon (USA)</i>	P10.35	
Case report study: presence of large round subchorionic "tumour" from first trimester until delivery at 37th week of gestation and late fetal growth retardation using colour Doppler technique <i>A. Papadimitriou (Greece)</i>	P10.36	
Unusual appearance of placental haematoma in a patient affected with deficit of factor XIII and venous thrombosis <i>G. Nazzaro (Italy)</i>	P10.37	
Uterine artery Doppler in pregnancies at high risk for utero-placental insufficiency <i>M. Segata (Italy)</i>	P10.38	
Comparison of first and second trimester uterine arterial Doppler to predict pregnancy outcome in a longitudinal cohort <i>W.W.K. To (Hong Kong)</i>	P10.39	
Cerebro- and cardiovascular responses and oxygen consumption during prolonged hypoxia in fetal sheep <i>S. Gruessner (Germany)</i>	P10.40	
Loss of agreement with higher angle correction in Doppler velocimetry. A mathematical demonstration <i>M. Yamamoto (Chile)</i>	P10.41	
Middle cerebral artery Doppler for fetal anemia evaluation in isoimmunized pregnancies <i>M. Onofriescu (Romania)</i>	P10.42	
Severe congenital cytomegalovirus infection without maternal serology indicative of seroconversion: the need for high index of suspicion <i>Y. Goldberg (Israel)</i>	P10.43	

Wednesday poster sessions

Labour

	Abstract no.	
Amniotic fluid sludge observed during ultrasound examination and prediction of preterm delivery <i>E. Bujold (Canada)</i>	P11.01	PPT
A centile chart for cervical length between 16–32 weeks' gestation <i>K. Norman (South Africa)</i>	P11.02	PPT
Vaginal bleeding and cervical length of ≤ 25 mm as predictors of preterm delivery: a prospective study <i>A. Bashiri (Israel)</i>	P11.03	PPT
Factors affecting the actual delivery date in term singleton pregnancy <i>G.J. Kim (Republic of Korea)</i>	P11.04	PPT
Two-dimensional ultrasound assessment of the cervix in prolonged pregnancy for prediction of time to start of labor and time to delivery <i>E. Strobel (Sweden)</i>	P11.05	PPT
3D ultrasound assessment of the cervix for predicting time to spontaneous onset of labor and time to delivery in prolonged pregnancy <i>L. Rovas (Lithuania)</i>	P11.06	PPT
Transvaginal ultrasonographic cervical measurement in predicting failed labor induction and Caesarean delivery for failure to progress <i>K.H. Park (Republic of Korea)</i>	P11.07	PPT
Mifepristone is an effective ripening agent in postdates primips with cervical length ≥ 2.5 cm but mode of delivery correlates with birthweight: a randomised, placebo controlled double blind study <i>V. Thakur (UK)</i>	P11.08	PPT
Nuchal cord: is it a sonographic dilemma? <i>R. Hershkovitz (Israel)</i>	P11.09	
Ultrasonographic cervical length measurement in the assessment of preterm delivery risk <i>T. Urbaniak (Poland)</i>	P11.10	
Position of the fetal head evaluated by transabdominal ultrasound in pregnancies with prelabor rupture of membranes <i>T.M. Eggebø (Norway)</i>	P11.11	
Doppler assessment of the uteroplacental circulation during Nifedipin therapy for preterm labor <i>V. Marsoosi (Iran)</i>	P11.12	
3D power Doppler ultrasound assessment of the cervix for prediction of successful induction of labor with prostaglandins in prolonged pregnancy <i>L. Rovas (Lithuania)</i>	P11.15	
Ultrasonographic evaluation of the lower uterine segment and risk of uterine scar separation in women with prior Cesarean: a systematic review <i>E. Bujold (Canada)</i>	P11.16	
Focal atony of the lower uterine segment: a distinct cause of postpartum hemorrhage <i>R.J. Stiller (USA)</i>	P11.17	
Sonography of severe post-Caesarean endometritis requiring hysterectomy <i>S. Gabrielli (Italy)</i>	P11.18	

Early pregnancy and acute gynecology

Reducing the number of follow up visits for pregnancies of unknown location <i>E. Kirk (UK)</i>	P12.01	PPT
Management of ectopic pregnancy: comparison of pelvic ultrasound findings and β -HCG trends in unruptured and ruptured cases <i>P. Tripathi (UK)</i>	P12.02	PPT
Can we improve the performance of logistic regression analysis for predicting the outcome of pregnancies of unknown location (PULs)? <i>G. Condous (UK)</i>	P12.03	PPT
Fertility outcome after ectopic pregnancy <i>S. Khazardoost (Iran)</i>	P12.04	PPT
Paradoxical flare-up effect of methotrexate on the trophoblast in cervical pregnancy <i>Y. Goldberg (Israel)</i>	P12.05	PPT
The sonographic findings in tubal ectopic pregnancies with low β -hCG blood levels <i>Y. Goldberg (Israel)</i>	P12.06	PPT
The value of transvaginal sonography in surgical evacuation of retained products of conception <i>S. Premila (UK)</i>	P12.07	PPT
Prediction of fetal loss following ultrasound diagnosis of a live fetus at 6–10 weeks of gestation <i>M. Rajaei (Iran)</i>	P12.08	PPT
3D sonography in gestational and placental volume measurements in women with first trimester bleeding <i>D. Borowski (Poland)</i>	P12.09	PPT
Is it possible to predict successful treatment response to methotrexate earlier than seven days? <i>E. Kirk (UK)</i>	P12.10	PPT
Conservative ultrasound-based management of ovarian pregnancy <i>F.P.G. Leone (Italy)</i>	P12.11	PPT

Wednesday poster sessions

	Abstract no.	
Transvaginal ultrasound in the management of ectopic pregnancy <i>P. Tripathi (UK)</i>	P12.12	
4D/3D ultrasound-guided embryo transfer <i>A. Nazzaro (Italy)</i>	P12.14	
3D power Doppler perifollicular blood flow indexes and oocyte competence during IVF cycles <i>A. Nazzaro (Italy)</i>	P12.15	
Midluteal-phase Doppler assessment of uterine artery flow in nonpregnant women having a history of recurrent spontaneous abortions <i>C. Exacoustos (Italy)</i>	P12.16	
New technologies and gynecological oncology		
3D/4D examinations in cervical cancer <i>A. Kratochwil (Austria)</i>	P13.01	PPT
The use of 3D rendering, VCI-C, 3D power Doppler and B-flow in the evaluation of cornual pregnancy with arterio-venous fistula <i>D.V. Valsky (Israel)</i>	P13.03	PPT
Long-term follow up of ovarian volume after uterine artery embolization <i>M. Walker (Canada)</i>	P13.04	PPT
Sonographic evaluation of intratumor vascularity with standard and 3D color Doppler: clinical implications <i>A.C. Fleischer (USA)</i>	P13.05	PPT
Importance of fine needle aspiration biopsy of parametria in cervical cancer <i>W. Sawicki (Poland)</i>	P13.06	PPT
Ultrasound guided removal of the elusive Implanon rod <i>R.V. Roberts (Australia)</i>	P13.07	
Assessment of changes in volume and vascularity of the ovaries during the normal menstrual cycle using three-dimensional power Doppler ultrasound <i>L. Jokubkiene (Sweden)</i>	P13.08	
Urogynecology		
Evaluation of patients with stress urinary incontinence by perineal ultrasound <i>M. Onofriescu (Romania)</i>	P14.01	PPT
The value of bladder wall thickness measurement in the assessment of overactive bladder syndrome <i>L. Chan (Australia)</i>	P14.02	PPT
Is vaginal childbirth to blame for rectocele development? <i>H.P. Dietz (Australia)</i>	P14.03	PPT
TVT and monarc suburethral slings: a case control trial <i>H.P. Dietz (Australia)</i>	P14.04	PPT
Usefulness of transvaginal sonography in assessment of patients with stress incontinence <i>W. Sawicki (Poland)</i>	P14.05	PPT



Thursday 29 September 2005

07:00–08:00 'Meet the Professor' breakfast sessions (registration required) Room: Marine

- How is this fetus doing? Disease-specific antenatal testing
A.A. Baschat (USA)
- Fetal heart defects (detection in 40,000 pregnancies)
S.H. Eik-Nes (Norway)
- 3D ultrasound and fetal syndromes
D. Paladini (Italy)
- Timing of delivery for the growth-restricted fetus
J.W.K. Ritchie (Canada)
- Ultrasound diagnosis of endometrial pathology
D. Timmerman (Belgium)
- Complications in monozygotic twins
Y. Ville (France)

08:00–09:30 Parallel: Maternal complications Room: Salons 1–2

- Chairs: S.H. Eik-Nes (Norway); G. Mari (USA)
- 08:00 Live scan demonstration: Abdominal organs
P. Glanc (Canada)
- 08:20 Video demonstration: Illustrations of the use of ultrasound in managing non-obstetric complications of pregnancy
P. Glanc (Canada)
- 08:30 What do we do with ovarian cysts diagnosed in pregnancy? OC32.01
D. Jurkovic (UK)
- 08:40 First-trimester uterine artery Doppler and ischaemia modified albumin in women who subsequently develop severe pre-eclampsia OC32.02
F. Prefumo; A.T. Papageorghiou; D. Gaze; P. Collinson; B. Thilaganathan (UK)
- 08:48 Diastolic flow index of the uterine artery Doppler waveform: a novel marker for downstream placental resistance OC32.03
A. Khaw; O. Turan (UK)
- 08:56 Compliance index (CI) of the uterine artery as a predictor of hypertensive disorders and growth restriction in low risk pregnancies OC32.04
*N. Klep¹; A. Kurjak²
¹(Austria); ²(Croatia)*
- 09:04 Modification of maternal and fetal circulation under moderate plasmatic volume expansion for pre-eclampsia OC32.05
J. Nizard; B. Arabin (Netherlands)
- 09:12 Maternal hemodynamic changes after laser therapy followed by amnioreduction for mid-trimester twin-twin transfusion syndrome OC32.06
J. Nizard; I. Gussi; Y. Ville (France)
- 09:20 Pregnancy in women with hypertrophic or dilated cardiomyopathy: the role of ultrasound examination for planning rational strategies OC32.07
I.G. Fedorova; O.A. Pitirimova; E.D. Bespalova (Russia)
- Related posters P15.01–P15.19

08:00–09:30 Parallel: New technologies in obstetrics Room: Salons D–E

- Chairs: D. Maulik (USA); D. Pugash (Canada)
- 08:00 Overview
D. Maulik (USA)
- 08:10 Multi-slice imaging of the normal fetal heart: a new promising tool? OC33.01
E. Sleurs; L. De Catte (Belgium)
- 08:18 Fetal cardiac ejection fraction assessed from 4D ultrasound: spatiotemporal image correlation and volume calculation OC33.02
L.U. Larsen; N. Uldbjerg; E. Sloth; K. Sorensen; O.B. Petersen (Denmark)
- 08:26 Early visualization of the fetal coronary arteries by four-dimensional ultrasonography with B-flow imaging and spatiotemporal image correlation (STIC) OC33.03
L.F. Gonçalves; J. Espinoza; J.P. Kusanovic; G. Mari; W. Lee; E. Soto; J. Santolaya-Forgas; M.C. Treadwell; R. Romero (USA)
- 08:34 Clinical application and usefulness of three-dimensional extended image (3D XI) in obstetrics OC33.04
H.S. Won; H.J. Cho; S.K. Kim; J.Y. Shim; P.R. Lee; A. Kim (South Korea)
- 08:42 Just images: Dynamic magnetic resonance imaging (DMR) as a new technology: clinical feasibility in obstetrics OC33.05
H.J. Cho; H.S. Won; S.K. Kim; J.Y. Shim; P.R. Lee; A. Kim (South Korea)
- 08:47 A longitudinal kinematical study of fetal hand movements through 4D ultrasound OC33.06
G. D'Ottavio; S. Zoia; L. Blason; A. Scabar; M. Bulgheroni; U. Castiello (Italy)

Thursday 29 September 2005

08:55	Expression of VEGF-C in human placenta during early pregnancy and quantitative placental pulsatile blood flow by ultrasonography <i>R.O. Rie (Japan)</i>	OC33.07
09:03	What is the best video compression algorithm for digital fetal ultrasound video clips? <i>D. Watson; I. Kromin; F.Y.C. Chan; L. Kastanis; A. Lee-Tannock; G. Duncombe; G. Gardener; A. Chang (Australia)</i>	OC33.08
09:11	Value of CT3D helical scanner during third trimester for diagnosis of osteochondrodysplasias and dysostosis <i>M. Molho; J. Roume; Y. Ville (France)</i>	OC33.09
09:19	Glucose influx rate of fetal organs during acute hypoxia measured by positron emission tomography: the pilot study <i>M. Tchirikov; W. Brenner; M. Strohner; R. Buchert; H.J. Schröder; N. Beindorff; K. Hecher (Germany)</i>	OC33.10

Related posters

P16.01–P16.15

08:00–09:30 Parallel: The use of ultrasound to assess the urogynecology patient Room: Salon F

	Chairs: I.E. Timor-Tritsch (USA); H.P. Dietz (Australia)	
08:00	Overview <i>I.E. Timor-Tritsch (USA)</i>	
08:10	Video demonstration: Three-dimensional ultrasound of the pelvic floor <i>H.P. Dietz (Australia)</i>	
08:25	Transperineal three-dimensional ultrasound to assess the anal sphincter <i>S.Y. Yagel; R. Patkova; D.V. Valsky (Israel)</i>	OC34.01
08:40	Vesical endometriosis: sonographic diagnosis and follow up after surgery <i>C. Exacoustos; M.E. Romanini; A. Amadio; C. Amoroso; B. Szabolcs; E. Zupi; D. Arduini (Italy)</i>	OC34.02
08:48	The use of volumetric transvaginal ultrasound probe to evaluate the anal sphincter anatomy in women <i>F. Guerra; R. Avendaño; C. Mayorga; C. Nannig; P. Matamala; R. Gutierrez; G.A. Campos (Chile)</i>	OC34.03
08:56	Postpartum evaluation of the anal sphincter by transperineal 3D ultrasound in primiparous women after normal vaginal delivery and after surgical repair of 3rd-degree tears <i>D.V. Valsky; R. Patkova; B. Messing; D. Rozenak; S.Y. Yagel (Israel)</i>	OC34.04
09:04	Pelvic floor trauma in labour <i>H.P. Dietz; V. Lanzarone (Australia)</i>	OC4.04
09:12	Dimensions of the levator hiatus in symptomatic women <i>H.P. Dietz; A.B. Steensma (Australia)</i>	OC34.06
09:20	Measurement of muscles of anal canal using 3D ultrasound <i>D.H. Pretorius; N.M. Guaderrama; J. Liu; C.W. Nager; G. Sheehan; R.K. Mittal (USA)</i>	OC34.07

Related posters

P14.01–P14.05

09:30–10:30 Parallel: Optimising the use of obstetric ultrasound Room: Salons 1–2

	Chairs: K. Hecher (Germany); S. Jamieson (Canada)	
09:30	Live scan demonstration: Making the most of your equipment <i>G.R. DeVore (USA)</i>	
09:50	Video demonstration: Importance and identification of artefacts <i>P. Jeanty (USA)</i>	
10:05	Chorionicity determination is the key factor in the antenatal care of twins <i>L. Sperling; I.Q. Qvist; C.J. Jørgensen; K.S. Skajaa; A.T. Tabor (Denmark)</i>	OC35.01
10:13	Individual and group learning curves for ultrasound fetal biometry measurements: cumulative sum analysis <i>S. Weerasinghe; A. Revel; H. Mirghani; F. Abu-Zidan (UAE)</i>	OC35.02
10:21	Effect of maternal hydration on amniotic fluid index <i>N. Lorzadeh; S. Najafi; M. Parsa; C. Kasemirad (Iran)</i>	OC35.03

09:30–10:30 Parallel: MRI in obstetrics II Room: Salons D–E

	Chairs: D. Levine (USA); D.A. Nyberg (USA)	
09:30	BOLD magnetic resonance imaging during fetal hypoxia <i>M. Tchirikov; H.J. Schröder; U. Wedegärtner; K. Hecher (Germany)</i>	OC36.01
09:38	The use of a single MRI biometric parameter to accurately quantify fetal relative lung volume in fetuses with suspicion of pulmonary hypoplasia <i>M.M. Cannie; J. Jani; R. Devlieger; J. Deprest; S. Dymarkowski (Belgium)</i>	OC36.02
09:46	The fetal kinked brainstem: sign of a severely dysgenetic brain <i>D. Levine; A. Stroustrup Smith; R. Robertson; P. Barnes (USA)</i>	OC36.03
09:54	The value and merits of ultrasonography and magnetic resonance in the diagnosis and prognosis of diaphragmatic hernias <i>H. Werner; P. Dalto; R.C. Domingues; T.M. Fazecas; L. Pereira; F.M. Peixoto; F. Guerra; C.P.S.P. Werner (Brazil)</i>	OC36.04



Thursday 29 September 2005

10:02	Importance of MRI in the diagnosis of congenital diaphragmatic hernia <i>G.L. Fernandes; M.V. Bueno; R. Chojniak; M.R. Torloni; F.S. Guimarães; M. Sancovski; S. Peixoto; A. Fernandes Moron (Brazil)</i>	OC36.05
10:10	Just images: Case report of an intracranial teratoma presenting as disorganized cranial anatomy on routine 20-week ultrasound <i>J.P. Schmidt; R.J. Gratton; R.G. Gagnon; W. Dawson (Canada)</i>	OC36.06
10:15	Just images: Congenital epulis: prenatal diagnosis with ultrasound and MRI <i>M. Echevarria; A. Muñoz; N. Maiz; M. Torrents; B. Serra; J. Mallafre (Spain)</i>	OC36.07
10:20	Just images: Prenatal diagnosis of the primary congenital lymphedema <i>H. Werner; P. Daltro; R.C. Domingues; T.M. Fazecas; L. Pereira; C.P.S.P. Werner (Brazil)</i>	OC36.08
10:25	Just images: Amniotic sac protrusion through a myometrial defect at 22 weeks: ultrasonographic and MRI diagnosis <i>L. Gucciardo; M.H. Billieux; E. Antonelli; O. Irion (Switzerland)</i>	OC36.09
	Related posters	P16.01–P16.15

09:30–10:30 Parallel: Demonstrations and debates in gynecology III Room: Salon F

	Chairs: D. Timmerman (Belgium); D. Jurkovic (UK)	
09:30	Case reports and video demonstrations: Early pregnancy complications <i>D. Jurkovic (UK)</i>	
09:40	Is it safe to perform uterine curettage in women with no signs of an intrauterine pregnancy on transvaginal ultrasound? <i>G. Condous¹; E. Kirk¹; Z. Haider¹; C. Lu²; S. Van Huffel²; D. Timmerman²; T. Bourne¹ (UK); ²(Belgium)</i>	OC37.01
09:48	Ultrasound and histological findings in women with suspected incomplete miscarriage <i>E. Ofuasia; E. Sawyer; D. Ofili-Yebovi; J. Yazbek; S. Helmy; D. Jurkovic (UK)</i>	OC37.02
09:56	Routine use of ultrasound guided curettage for incomplete abortion or missed abortion: 5 years experience <i>L.M. Lopes¹; C.P. Weiner²; R.A.M. Sá¹; M.B. da Silva¹; A.L.M. Dourado¹; I.B. Costa Jr¹ (Brazil); ²(USA)</i>	OC37.03
10:04	Discussion forum: Statement on achieving a consensus on the management of PULs <i>G. Condous (UK)</i>	
10:14	Discussion <i>G. Condous¹; D. Jurkovic¹; I.E. Timor-Tritsch² (UK); ²(USA)</i>	

10:30–11:15 Coffee and poster discussion sessions

10:40–11:10	Poster session IX: Chairs: J.W.K. Ritchie (Canada); G. Mari (USA) P15: Maternal complications of pregnancy	Room: Cypress 1 P15.01–P15.19
10:40–11:10	Poster session X: Chairs: D. Maulik (USA); J.S. Abramowicz (USA) P16: New technologies in obstetric ultrasound	Room: Cypress 2 P16.01–P16.15
	Poster viewing: (Poster session VIII) P12: Early pregnancy and acute gynecology P13: New technologies and gynecological oncology P14: Urogynecology	Room: Salon F P12.01–P12.16 P13.01–P13.08 P14.01–P14.05



Thursday 29 September 2005

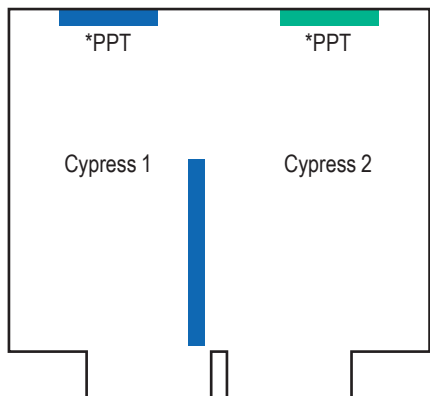
11:15–12:45 Plenary: The optimum model for screening for chromosomal abnormalities **Room: Salons 1–3**

11:15	Chairs: S. Campbell (UK); J.A. Johnson (Canada) Screening for Down syndrome using first-trimester combined screening followed by second trimester ultrasound examination: evaluation of the compliance <i>Y. Ville; P. Rozenberg; L. Bussières; S. Chevet; J.P. Bernard (France)</i>	OC38.01 & OC38.02
11:25	One-stop clinic for assessment of risk (OSCAR) for trisomy 21 in singleton pregnancies at 11 to 13+6 weeks of gestation <i>A.T. Papageorghiou; K. Avgidou; R. Bindra; K. Spencer; K.H. Nicolaides (UK)</i>	OC38.03
11:33	The implementation of the integrated screening test for Down syndrome in a government hospital <i>B. Weisz; P. Jones; L. Chitty; C.H. Rodeck; P.P. Pandya (UK)</i>	OC38.04
11:41	Abortion rate after chorionic villus sampling and amniocentesis: a 7-year national registry study <i>A. Tabor; Ø. Lidegaard (Denmark)</i>	OC38.05
11:49	Panel discussion: The ideal model for screening for chromosomal abnormalities NT and first-trimester biochemistry <i>J. Hyett (UK)</i>	
11:53	NT and second-trimester biochemistry <i>L.D. Platt (USA)</i>	
11:57	Second-trimester biochemistry and the genetic sonogram <i>D.A. Nyberg (USA)</i>	
12:01	Second-trimester biochemistry and fetal biometry <i>R.O. Bahado-Singh (USA)</i>	
12:05	Panel discussion <i>R.O. Bahado-Singh¹; J. Hyett²; J.A. Johnson³; D.A. Nyberg⁴; P.P. Pandya²; A.T. Papageorghiou²; L.D. Platt¹; A. Tabor⁴; Y.Ville⁵</i> ¹ (USA); ² (UK); ³ (Canada); ⁴ (Denmark); ⁵ (France)	
12:35	Free communication and poster awards	
	Related posters	P01.01–P01.24

12:45 Closing: Pizza and beer **Level 2**



Thursday poster sessions



Poster session	Posters	PowerPoint posters
 Maternal complications of pregnancy	P15.13–P15.19	P15.01–P15.12
 New technologies in obstetric ultrasound		P16.01–P16.15
*PPT = PowerPoint presentations		
Poster discussion sessions 12:00–12:45		

Thursday 29 September 2005

Maternal complications of pregnancy

	Abstract no.	
Ophthalmic and central retinal arteries Doppler as a new parameter to distinguish moderate to severe preeclampsia <i>A.L.D. Diniz (Brazil)</i>	P15.01	PPT
Ophthalmic and central retinal arteries Doppler in preeclamptic women with visual disturbance and headache <i>A.L.D. Diniz (Brazil)</i>	P15.02	PPT
Ocular hyperperfusion in preeclamptic women demonstrated by ophthalmic and central retinal arteries Doppler <i>A.L.D. Diniz (Brazil)</i>	P15.03	PPT
Ductus venosus Doppler waveform analysis: a new tool for the early prediction of preeclampsia? <i>H.F. Yazicioglu (Turkey)</i>	P15.04	PPT
The application of logistic regression risk modelling to second trimester uterine artery Doppler screening for pre-eclampsia <i>A. Khaw (UK)</i>	P15.05	PPT
Evaluation of the maternal and placental circulation by 3D Doppler at 14–25 weeks of gestation: normal vs pregnancies complicated with pre-eclampsia <i>I. Zalud (USA)</i>	P15.07	PPT
Intra-observer variability in flow mediated vasodilation (FMVD) in normal pregnancies <i>K. Lim (Canada)</i>	P15.08	PPT
USG scan in predicting the size of the newborn in obese mother <i>E.M. Romejko-Wolniewicz (Poland)</i>	P15.09	PPT
Umbilical, fetal middle cerebral and uterine arteries Resistance and Pulsatility indices in well controlled insulin dependent gestational diabetes <i>J. Santolaya-Forgas (USA)</i>	P15.10	PPT
The effect of glyburide on amniotic fluid index in pregnancies complicated by diabetes <i>C. Warshak (USA)</i>	P15.11	PPT
Association of first trimester uterine artery Doppler indices with maternal diastolic cardiac function <i>A.T. Papageorghiou (UK)</i>	P15.12	PPT
Amniocentesis and tests of fetal lung maturity in diabetics <i>G.L. Fernandes (Brazil)</i>	P15.13	



Thursday poster sessions

	Abstract no.	
Post Cesarean section sonographic fluid collection and febrile morbidity <i>A. Abudher (Libya)</i>	P15.14	
Resolution of Ballantyne syndrome following the resolution of fetal hydrops secondary to congenital parvovirus infection <i>W. Harry (USA)</i>	P15.15	
The risk factors of emergency Cesarean hysterectomy for placenta previa <i>G.S.R. Lee (Republic of Korea)</i>	P15.16	
Use of 3D transvaginal ultrasound for assessment of C/S scar integrity after spontaneous vaginal delivery <i>J. Jirous (Kuwait)</i>	P15.18	
Hepatic multicystic disease and pregnancy <i>H. Werner (Brazil)</i>	P15.19	
New technologies in obstetric ultrasound		
MR evaluation of the fetal corpus callosum in relation to gestational age <i>D.M. Twickler (USA)</i>	P16.01	PPT
Three-dimensional fetal sonography: is it always feasible? <i>P. Heymans (Switzerland)</i>	P16.02	PPT
"Flip the coin": 360-degree visualization of fetal anatomical structures with xMatrix 4D real-time ultrasonography <i>L.F. Gonçalves (USA)</i>	P16.03	PPT
Three-dimensional extended imaging™: a new display modality for three-dimensional ultrasound examination <i>K.Y. Leung (Hong Kong)</i>	P16.04	PPT
Measurement of fetal urine production by three-dimensional (3D) ultrasound in normal pregnancy <i>S.M. Lee (Republic of Korea)</i>	P16.05	PPT
Internet based remote interpretation of the 3D-4D datasets <i>I. Zador (USA)</i>	P16.07	PPT
Objective quality measure of compressed fetal ultrasound video clips <i>F.Y. Chan (Australia)</i>	P16.08	PPT
3D inversion mode combined with STIC: a novel technique for fetal heart ventricle volume quantification <i>S.Y. Yagel (Israel)</i>	P16.09	PPT
200 fetal tele-ultrasound consultations: clinical value and cost-effectiveness <i>F.Y. Chan (Australia)</i>	P16.10	PPT
Quantitative fetal umbilical venous volume flow between 11 and 14 weeks: a pilot study <i>M. Tchirikov (Germany)</i>	P16.12	PPT
Confirmation of first trimester fetal abnormalities at termination of pregnancy <i>B.C.P. Chan (Hong Kong)</i>	P16.13	PPT
F-18-fluorodeoxyglucose (FDG) uptake of fetal organs during acute hypoxia measured by positron emission tomography (PET): the pilot study <i>M. Tchirikov (Germany)</i>	P16.14	PPT
First trimester prenatal diagnosis of fetal RhD status and gender by real-time PCR in maternal serum <i>G. Pescia (Switzerland)</i>	P16.15	PPT



See our family of new products at ISUOG!

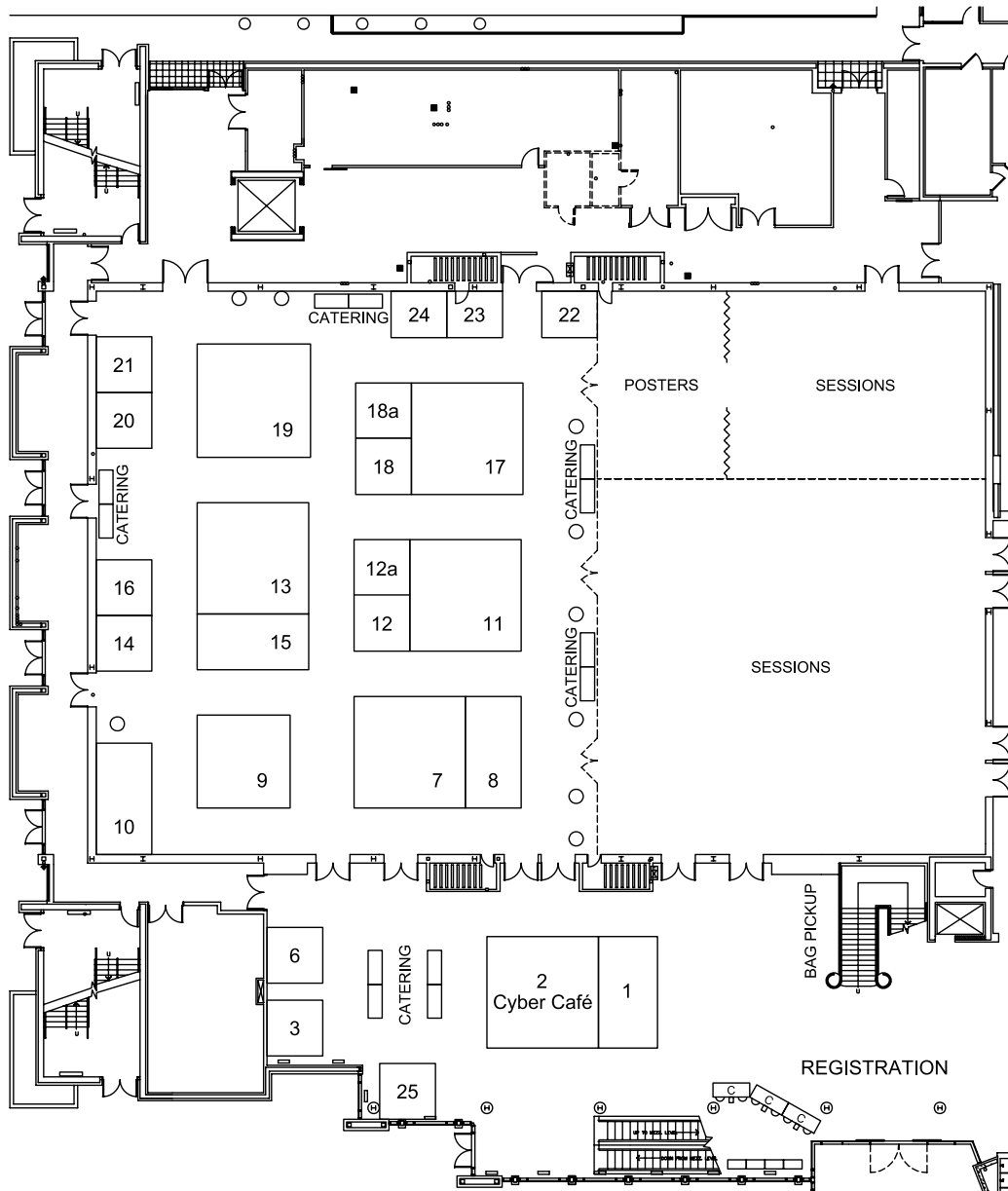


Introducing the newest additions to our family – the HD11 XE and HD3 systems.

Visit our booth and see our other new system – the iU22.

PHILIPS

Exhibition floor plan



List of exhibitors

	Stand no.		Stand no.
ALOKA	17	Medison Co., Ltd.	19
American Institute of Ultrasound in Medicine	24	Mindray Co., Ltd.	10
AS Software, Inc.	3	NTD Laboratories Inc	12a
Astraira Software GmbH	23	PerkinElmer Life & Analytical Sciences	15
CIVCO Medical Instruments	25	Philips Medical Systems	13
ContextVision AB	14	R4, LLC	16
Elsevier Canada	22	Siemens Medical Solutions USA, Inc.	7
ESAOTE S.p.A	9	Sonultra	2
GE Healthcare	11	Sound Ergonomics, LLC	18
GeneCare Medical Genetics Center	20	Taylor & Francis/Parthenon Publishing	18a
International Vasa Previa Foundation	12	TeraRecon, Inc.	21
ISUOG	1	Ultrasonix Medical Corporation	8
Karl Storz Endoscopy Canada	6		

Exhibitor profiles

ALOKA

6-22-1, Mure, Mitaka-shi, Tokyo, Japan

Tel: +81 422 45 6049

Fax: +81 422 45 4058

Email: int-sle2@aloka.co.jp

Website: www.aloka.com

Contact: Masaki Akita (International Sales Division)

ALOKA, headquartered in Tokyo, is a leading manufacturer of medical devices which introduced the world's 1st diagnostic ultrasound system in 1960. With more than 50 years history in medical diagnostic ultrasound, it is one of the longest experienced and most innovative companies in the diagnostic ultrasound market.

At ISUOG 2005, ALOKA is proud to exhibit our latest version of the premium "Prosound alpha 10" and the "Prosound SSD-3500", both equipped with the perfect solutions for obstetrics/gynecology examination.

Stand no: 17

American Institute of Ultrasound in Medicine

14750 Sweitzer Lane, Suite 100

Laurel, MD 20707, USA

Tel: +1 301 498 4100 / 800 638 5352

Fax: +1 301 498 4450

Website: www.aium.org

Stand no: 24

AS Software, Inc.

80 South Woodland Street, Englewood

NJ 07631, USA

Tel: +1 201 541 1900

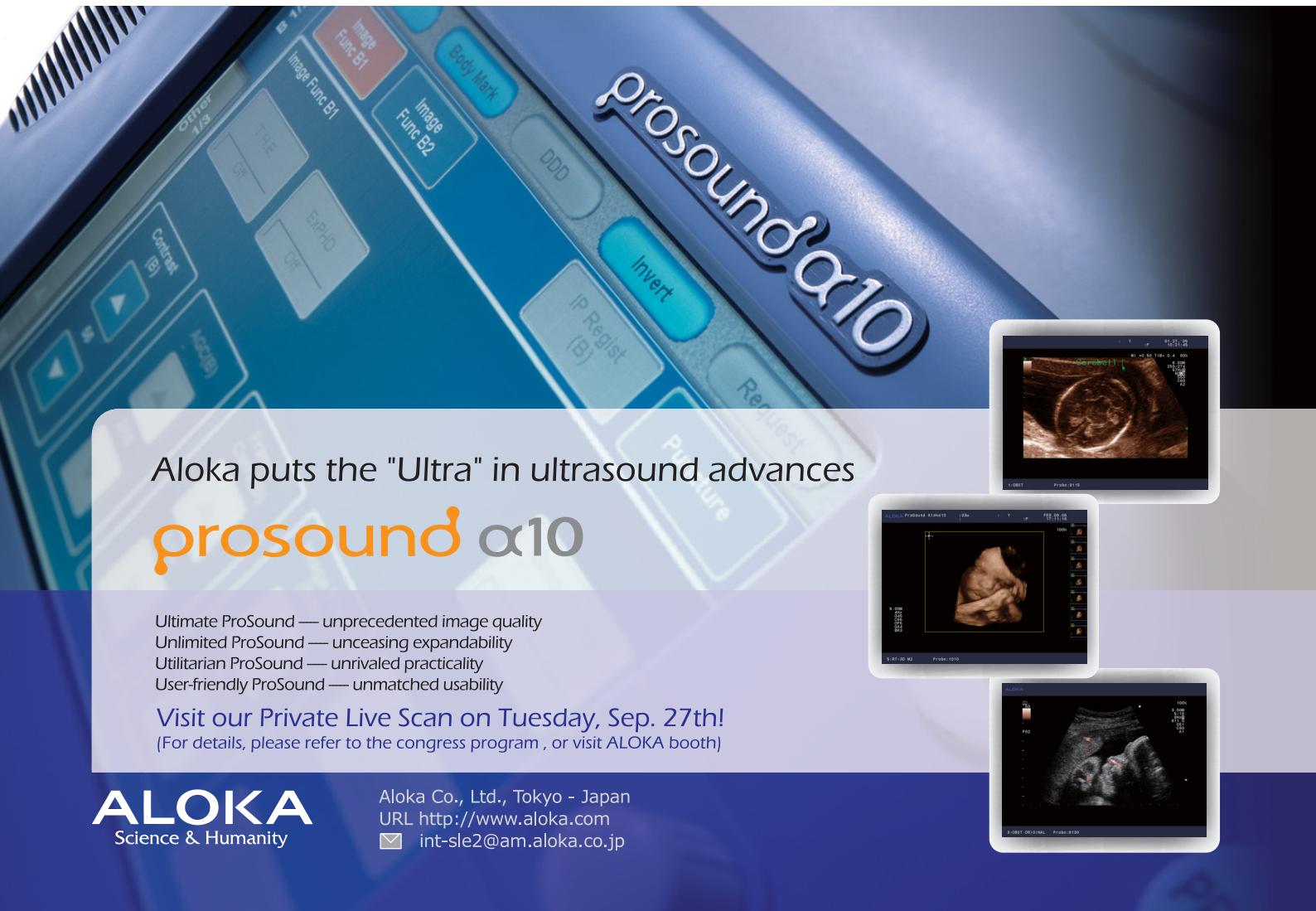Fax: +1 201 541 1199

Email: knathanson@as-software.com

Contact: Kim Nathanson

Stand no: 3

AS Software Inc. provides a total solution for ob/gyn specialising in ultrasound reporting, EMR and Dicom Image Management Systems, which offer both physicians and hospitals state-of-the-art Enterprise data management solutions. For over 14 years, AS Software Inc. has been providing high scale ultrasound reporting systems tailored to meet your needs. We at AS Software Inc. aim to meet your satisfaction by thinking one step ahead, knowing your requirements and implementing your new tools that will remain "state-of-the-art" for many years.



Aloka puts the "Ultra" in ultrasound advances

prosound α10

Ultimate ProSound — unprecedented image quality

Unlimited ProSound — unceasing expandability

Utilitarian ProSound — unrivaled practicality

User-friendly ProSound — unmatched usability

Visit our Private Live Scan on Tuesday, Sep. 27th!

(For details, please refer to the congress program, or visit ALOKA booth)

ALOKA
Science & Humanity

Aloka Co., Ltd., Tokyo - Japan

URL <http://www.aloka.com>

✉ int-sle2@am.aloka.co.jp

Exhibitor profiles

Astraia Software GmbH

Zettler Str.29, 80992 Munich, Germany
 Tel: +49 89 127 1147 0
 Fax: +49 89 127 1147 17
 Email: denk@astraia.de
 Website: www.astraia.com
 Contact: *Roland Denk*

Stand no: 23

Astraia provides safe, reliable state-of-the-art software solutions for documentation and reporting in medicine with specific emphasis on women's health. We serve the needs of hospitals, scientists, researchers, specialists and GPs by:

- providing easily-used, well-designed software modules
- ensuring the incorporation of the highest quality medical knowledge
- supporting most major languages, ultrasound systems and connectivity standards
- maintaining close relationships with world-renowned experts.

For more details, visit our website or visit stand 23.

CIVCO Medical Instruments

102 First Street South, Kalona
 IA 52247-9589, USA
 Tel: +1 800 445 6741 / 319 656 4447
 Fax: +1 877 329 2482 / 319 656 4451
 Email: info@civco.com
 Website: www.civco.com

Stand no: 25

CIVCO is a global specialist in the design, manufacture and marketing of specialised medical products for diagnostic and minimally invasive surgical procedures. CIVCO partners with the world's leading imaging and device original equipment manufacturers to supply innovative products, such as image-guided biopsy systems, positioning and stabilising equipment and consumable infection control covers. CIVCO also offers a complete line of imaging supplies including cardiology accessories, gels, disinfectants, printers and print media.

ContextVision AB

Torshamnsgatan 39, Kista, SE-164 40, Sweden
 Tel: +46 8 750 4008
 Fax: +46 8 750 5494
 Email: info@contextvision.se
 Website: www.contextvision.se
 Contact: *Peter Koevomees*

Stand no: 14

Context Vision is an independent provider of image enhancement for clinical imaging professionals. In magnetic resonance imaging (MRI), digital X-ray and ultrasound, we analyse and enhance the significant information in digital images for clearer, quicker and more efficient diagnoses. We offer customisable and seamlessly integrated solutions within an extensive range of manufacturers' equipment. Visit us at stand 14 to learn more about our products.

Elsevier Canada

1 Goldthorne Avenue, Toronto
 Ontario M8Z 5S7, Canada
 Tel: +1 416 253 3643 / 866 896 3332 ext 556
 Fax: +1 416 255 5456
 Website: www.elsevier.ca

Stand no: 22

ESAOTE S.p.A

International Activities: Via di Caciolle
 15, 50127 Florence, Italy
 Tel: +39 055 42291
 Fax: +39 055 422 9208
 Email: international.sales@esaote.com
 Website: www.esaote.com

Stand no: 9

ESAOTE is introducing its new MyLab line of ultrasound systems at the 2005 ISUOG World Congress: the MyLab15, MyLab25 and MyLab50. In addition to the line of MyLab systems, ESAOTE is also exhibiting its new 4D imaging solution, the Picus-Just 4D system.

Don't forget to stop by the ESAOTE stand to enter the contest for a free 2006 ISUOG World Congress registration! The form is in your delegate bag!

GE Healthcare

PO Box 414, Milwaukee, WI 53201, USA
 Tel: +1 866 344 3633
 Website: www.gehealthcare.com

Stand no: 11

GE Healthcare provides transformational medical technologies that will shape a new age of patient care. GE Healthcare's expertise in medical imaging and information technologies, medical diagnostics, patient monitoring systems, disease research, drug discovery and biopharmaceuticals is dedicated to detecting disease earlier and tailoring treatment for individual patients. GE Healthcare offers a broad range of services to improve productivity in healthcare and enable healthcare providers to better diagnose, treat and manage patients. For more information visit our website.

GeneCare Medical Genetics Center

201 Sage Road, Suite 300, Chapel Hill
 NC 27514, USA
 Tel: +1 800 277 4363 / 919 942 0021
 Fax: +1 919 967 9519
 Email: Gstuddard68@cs.com
 Contact: *Greg Studdard*

Stand no: 20

GeneCare is an international, clinical and research center which provides comprehensive genetic services, including: chromosomal; DNA; FISH; biochemical analyses; early screen® first trimester™ screening with nuchal translucency (NT), nasal bone/freeBeta/PAPP-A; second trimester AFP/freeBeta screening; genetic counselling and consults from ABMG certified geneticists. We provide official Fetal Medicine Foundation NT and nasal bone training courses.

Exhibitor profiles

International Vasa Previa Foundation

PO Box 272293, Boca Raton
FL 33427-2293, USA
Tel: +1 561 504 3540
Fax: +1 561 347 0291
Email: info@vasaprevia.com
Website: www.IVPF.org

The International Vasa Previa Foundation (IVPF) believes that infant death due to vasa previa is an avoidable tragedy. The technology exists to detect vasa previa but it is rarely diagnosed because prenatal screening for the condition is not the standard of care. However, infant death and injury are preventable when vasa previa is prenatally diagnosed.

It only takes a moment to diagnose life...

Stand no: 12

different countries. All full paying delegates in Vancouver will automatically be registered as members of ISUOG and will receive a 12-month subscription to ISUOG's official journal *Ultrasound in Obstetrics & Gynecology*, as well as special reduced rates to attend our 2006 World Congress in London (3-7 September 2006). Membership includes online access to all 'White Journal' issues dated back to 1991 and to accepted articles in advance of publication. Our publishers, John Wiley & Sons, will be demonstrating our online Journal services at our booth. To find out more about membership, the 2006 World Congress, or the Journal please visit us at stand 1 in the registration area.

ISUOG

Unit 4 Blythe Mews, Blythe Road
London W14 0HW, UK
Tel: +44 (0) 20 7471 9955
Fax: +44 (0) 20 7471 9959
Email: info@isuog.org
Website: www.isuog.org

The International Society of Ultrasound in Obstetrics and Gynecology (ISUOG) now represents over 2500 members in 85

Stand no: 1

Karl Storz Endoscopy Canada

2345 Argentia Road, Suite 100, Mississauga
ON L5N 8K4, Canada
Tel: +1 905 816 8108
Fax: +1 905 858 5976
Email: kdonaldson@karlstorz.ca
Website: www.karlstorz.com
Contact: Keith Donaldson

Stand no: 6

One

One World One Language

MyLab World

MyLab15



MyLab20



MyLab50



MyLab70



MyLab90



Exhibitor profiles

Medison Co., Ltd.

Medison Venture Tower Annex 997-10,
Daechi-Dong, Gangnam-Gu, Seoul, Korea 135-280
Tel: +82 2 2194 1145
Fax: +82 2 2194 1129
Email: marketing@medison.com
Website: www.medison.com
Contact: Jon Kim

Medison Co., Ltd. is an industry-leading manufacturer of medical ultrasound systems. Medison was founded in 1985 and pioneered the first commercial real-time 3D ultrasound scanner and we offer a complete range of ultrasound products from portable to premium class digital 3D systems.

Come experience the latest technology from the leader in 3D ultrasound technology at stand 19.

Mindray Co., Ltd.

Mindray Building, Keji 12th Road South
High-Tech Industrial Park, Shenzhen 518057
People's Republic of China
Tel: +86 755 2658 2492 / 2658 2888
Fax: +86 755 2658 2500
Email: intl-market@mindray.com.cn
Website: www.mindray.com.cn

Since its foundation in 1991, Mindray Co., Ltd. has been engaged in R&D, manufacture and sales of medical equipment covering

Stand no: 19

ultrasound system, laboratory instrument and reagent, and patient monitor. Strictly complying with ISO9001/ISO13485 quality standards and CE/FDA regulations, Mindray's products have been widely accepted by customers all over the world for their first-class quality and cost-effective price. Nowadays, Mindray has developed into China's largest medical equipment manufacturer and one of the pioneers in the industry.

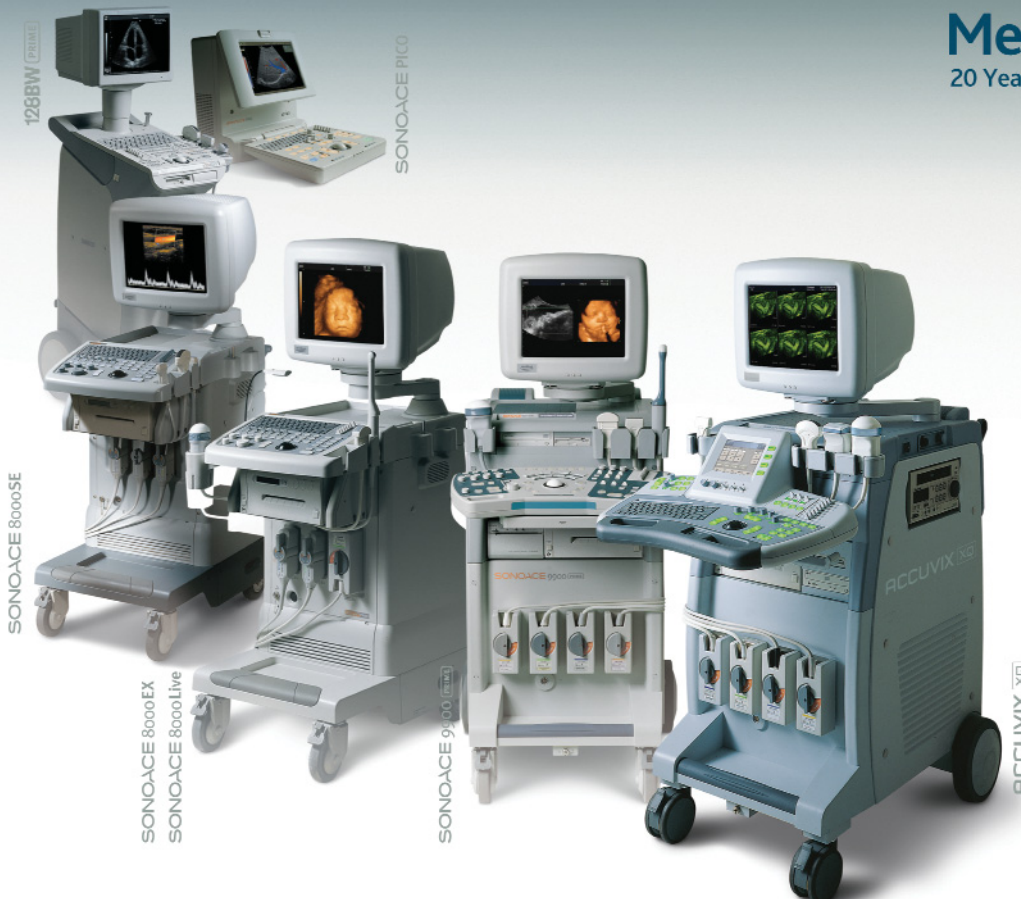NTD Laboratories Inc.

403 Oakwood Road, Huntington Station
NY 11746, USA
Tel: +1 631 425 0800
Fax: +1 631 425 0811
Email: rachelz@ntdlabs.com
Website: www.ntdlabs.com
Contact: Rachel Zone

Stand no: 12a

NTD Laboratories Inc. is a commercial and research laboratory which specialises in prenatal screening. We have a history of research and innovation of more than 20 years. We have introduced major innovations in prenatal screening, including dried-blood sampling and the identification of free Beta hCG for first trimester Down syndrome screening. Our ongoing commitment is to continually improve prenatal screening through earlier and more accurate detection.

see it all
MEDISON
www.medison.com info@medison.com



Medison Ultrasound

20 Years of Excellence in Diagnostic Ultrasound

Medison, the original pioneer of 3D ultrasound technology has been providing affordable and innovative ultrasound solutions to the medical community for the past twenty years.

Our extensive product line covers the entire application spectrum from the technically advanced 4D ultrasound systems to the compact, color portable systems, all capable of providing the most accurate and comprehensive ultrasound diagnosis available today.

Contact us to learn more about Medison's industry leading line up of ultrasound systems.

Medison ultrasound,
leading with innovation and ingenuity.

Medison Events at 2005 ISUOG

Tuesday, September 27th
Live Scanning Exhibition (Full Day)
• Experience first hand, the latest ultrasound technology from Medison

Wednesday, September 28th
Medison Satellite Session (12:00 - 14:00)
• Clinical Advantages of 3D eXtended Imaging Technology
• Includes Live Scan Demonstration Session

Join us for a dinner cruise party celebrating the 2006 WFUMB event in Seoul of the beautiful Vancouver harbor on the evening of 28th, Wednesday. Space is limited so please visit our booth to RSVP your ticket for this event.

Exhibitor profiles

PerkinElmer Life & Analytical Sciences

Stand no: 15

710 Bridgeport Avenue, Shelton, CT 06484, USA

Tel: +1 203 402 6878

Fax: +1 203 944 4950

Email: megan.nicolari@perkinelmer.com

Website: www.perkinelmer.com

Contact: Megan Nicolari

Philips Medical Systems

Stand no: 13

Tel: +1 888 647 4285

Website: www.medical.philips.com

Too often, advanced medical technology serves to complicate everyday workflow. Philips designs medical technology to simplify our lives. Advanced yet easy to experience. With customised services and systems in women's health, radiology, cardiology, oncology, emergency and critical care, and molecular imaging. Philips – it just makes sense. Visit us at stand 13.

R4, LLC

Stand no: 16

6802 West Snowville Road, Brecksville

OH 44141, USA

Tel: +1 440 546 4272

Fax: +1 440 546 4282

Website: www.csc-groupinfo.com

Contact: Bob Carson

R4, LLC is a full-service provider of ultrasound information systems. R4 ACERT is the only fully integrated ultrasound reporting, image acquisition, storage and retrieval, and telemedicine system in the women's healthcare market. Customised to meet practice needs and able to interface to any HIS, RIS, scheduling and billing system, R4 solutions support the smallest maternal fetal-medicine practice to the largest hospital ob/gyn department. Discover how your practice can *perform more exams in less time* – visit stand 16.

Siemens Medical Solutions USA, Inc.

Stand no: 7

Ultrasound Division, 1230 Shorebird Way

Mountain View, CA94039-7393, USA

Tel: +1 650 969 9112

Fax: +1 650 968 1833

Website: www.siemens.com

Siemens Medical Solutions Ultrasound Division proudly supports the SONOLINE and ACUSON product lines. We are the world's largest supplier of premium ultrasound systems and the worldwide leader in the production and sale of general imaging systems.

Approximately 700,000 diagnostic ultrasound exams are performed each day in hospitals, clinics and doctors' offices around the world using Siemens SONOLINE™ and ACUSON™ ultrasound systems.

Sonultra Corporation

Cyber Café – Stand no: 2

PO Box 3910, Beverly Hills

California 90212-0910, USA

Tel: +1 310 557 1750

Fax: +1 310 861 9054

Email: dparker@sonultra.com

Website: www.sonultra.com

Contact: Don Parker

Improve your quality assurance, productivity, billing, and data mining! Sonultra Corporation's patent pending technology, open architecture and mobile solutions can help you. We offer hand-held or PC-based reporting and image management solutions that easily integrate with your existing PACS/HIS/RIS infrastructure. Sonultra's solutions can improve your report distribution, centralise your long-term archiving and standardise your practice. These are only some of the reasons administrators, IT Departments and your colleagues have made Sonultra their solution of choice since 1986.

Sound Ergonomics, LLC

Stand no: 18

6830 NE Bothell way, #C236, Kenmore

WA 98028, USA

Tel: +1 800 425 8151

Fax: +1 206 366 0183

Email: ctcoffin@soundergonomics.com

Website: www.soundergonomics.com

Contact: Carolyn Coffin

Sound Ergonomics, LLC is a consulting company that provides educational services and adaptive products for the prevention of occupational musculoskeletal disorders related to scanning. Our services include educational lectures, workshops and clinical site evaluations. Our products include exam room chairs, tables, support cushions, educational videos and cable support arm bands.

Taylor & Francis/Parthenon Publishing

Stand no: 18a

Richmond House, White Cross, South Road

Lancaster LA1 4XF, UK

Tel: +44 1524 585702

Fax: +44 1524 585718

Email: fwaters@crcpress.com

Website: www.tandf.co.uk

Contact: Faye Waters

Considered a leading publisher in ultrasound in obstetric and gynecologic medicine, the newly formed Taylor & Francis (merging the well-known companies Parthenon Publishing, Martin Dunitz, Dekker, Bios and CRC Press) is an international company with a strong list of medical publications particularly in ultrasound in maternal, fetal and neonatal medicine. On display will be a range of new textbooks and journals by leading authorities. Taylor & Francis are proud to be the publisher of the Journals *Maternal Fetal and Neonatal Medicine*, *Ultrasound Review in Obstetrics and Gynecology* and *Hypertension in Pregnancy*.

Exhibitor profiles

TeraRecon, Inc.

2955 Campus Drive, Suite 325, San Mateo
CA 94403, USA

Tel: +1 650 653 4240

Fax: +1 650 372 1101

Website: www.terarecon.com

Contact: Steve Sandy

TeraRecon provides diagnostic imaging solutions that include portable and mid-range colour Doppler ultrasound systems for clinical applications, AQUARIUS R workstations for post-processing CT and MR, and AQUARIUSNET SONIC processing servers for enterprise-wide distribution and navigation of ultrasound images.

TeraRecon's multi-disciplinary ultrasound scanners includes the UF-750XT portable colour Doppler and UF-850XTD, a digital, mid-range colour Doppler system for private practice physicians, general and vascular surgeons, and radiology and cardiology applications.

Stand no: 21

Ultrasonix Medical Corporation

301-3480 Gilmore Way
Burnaby, BC V5G 4Y1, Canada

Tel: +1 604 437 9500

Fax: +1 604 437 9502

Email: rossa@ultrasonix.com

Website: www.ultrasonix.com

Contact: Rossa Sung

Stand no: 8

Ultrasonix Medical Corporation is a privately held corporation specialising in ultrasound and informatics. Ultrasonix is dedicated to providing its customers with superior ultrasound solutions and support. Working in partnership with a growing network of global partnership, Ultrasonix is constantly expanding its coverage and services, making its leading-edge technology available around the world.

The new Sonix series presents three system packages that will meet your image needs and budget, providing the perfect balance of performance and affordability.

Ultrasonix Medical Corporation

A Company Dedicated to Ultrasound

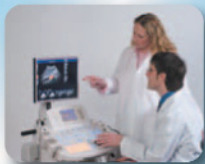

Image Clarity and Confidence

Clarity – advanced image processing algorithms

Real-time Spatial Compounding – contrast resolution and border definition

Panoramic Imaging – extended field of view

Harmonic Imaging – improved contrast resolution and signal to noise ratio

3D and 4D volume imaging



Simplicit™ User Interface & Ergo Metrics

Logical key grouping – fast access to main functions

Touch screen – instant access without sub-menus

Q Sonix – one button access for auto population of patient data probe selection, and presets

Horizontal and vertical slant movement of console

17" Flat panel LCD monitor

4 - wheel swivel



Image Management and Storage

80 gigabyte hard drive

Front load CD / DVD writer

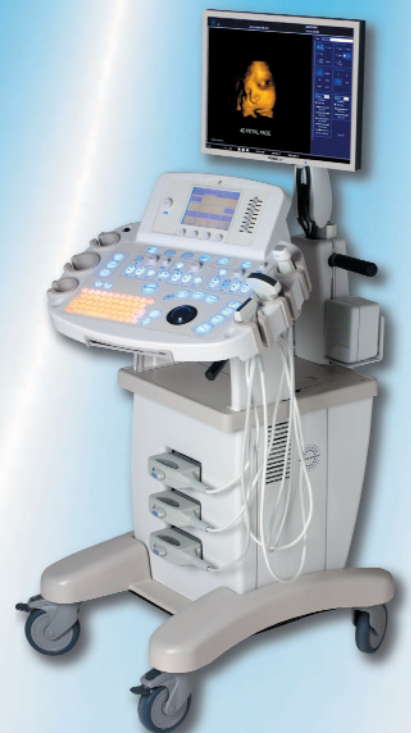2 Front load USB ports

DICOM 3.0 – worklist, print, store

Multiple peripheral outputs (composite color, B&W, VGA, digital, and S-Video)

Modem and network connection

Sonix SP



BALANCE OF PERFORMANCE & AFFORDABILITY

Please visit www.ultrasonix.com or contact your local dealer for more information.

301-3480 Gilmore Way, Burnaby, BC Canada V5G 4Y1 Tel: (604) 437-9500 Fax: (604) 437-9502 Toll Free: 1-866-437-9508

Sponsors' activities

Scientific program sessions

Unrestricted educational grants have been provided to support all the scientific program activities on this page.

The **11–14 scan pre-Congress course** (Sunday 25 September 2005) has been supported by **Medison**.

Live scan demonstrations

Sponsors provide systems and support for all technical services to bring live scan sessions to you. Scientific content is defined by ISUOG.

Salons 1–2

Session start time	Monday	Tuesday	Wednesday	Thursday
08:00				Philips Maternal complications
08:30		GE Healthcare Fetal face and neck	Siemens Fetal growth and well-being	
09:30				GE Healthcare Optimising the use of obstetric ultrasound
Coffee	Poster sessions: ESAOTE S.p.A			
10:30		Siemens Fetal heart II	GE Healthcare Clinical benefits of 3D ultrasound	
Lunch	Poster sessions: ESAOTE S.p.A			
14:00	ESAOTE S.p.A Central nervous system (CNS) I	Medison Thorax and abdomen	Medison 11–14 week scan	
Coffee	Poster sessions: ESAOTE S.p.A			
16:00	Aloka Fetal heart I	Philips Fetal skeleton	Philips 18–23 week scan	



Sponsors' activities

Private sponsor activities

The following activities do not form part of the scientific program and the World Congress and ISUOG are not responsible for the content of these sessions.

Hospitality and live scanning activities

Room	Monday	Tuesday	Wednesday
Oak 1	Philips Forward thinking technologies to a select audience	Philips Forward thinking technologies to a select audience	
Oak 2	Siemens Live scan sessions using Antares and Sequoia ultrasound systems	Siemens Live scan sessions using Antares and Sequoia ultrasound systems	Siemens Live scan sessions using Antares and Sequoia ultrasound systems
Mackenzie	GE Healthcare Meet the expert sessions 10:00–10:30 Dr. Benoit 12:45–13:45 Dr. Vinals 15:30–16:00 Dr. Benacerraf	Medison Lectures by: Dr Cafici Mr. Wisher Followed by live scanning. <i>These sessions will take place during scheduled break times</i>	GE Healthcare Meet the expert sessions 10:00–10:30 Dr. DeVore 12:45–13:45 Dr. Davies 15:30–16:00 Dr. Platt
Seymour		Aloka Live scan sessions	

Oak 1 and 2 are located on level two. Seymour and Mackenzie are located on level one.

Formal live scan demonstrations take place during advertised break times on each day. It is at the discretion of the sponsor whether invitations are required to attend.

Lunchtime satellite symposia (12:45–13:45)

Room	Monday	Tuesday	Wednesday
Salon 3	Philips	GE Healthcare	Medison Clinical advantages of 3D eXtended imaging in ob/gyn (including live scan demonstration) Chair: Professor Sepulveda Speaker: Professor Hye-Sung Won

ISUOG would like to thank all of its sponsoring partners for their generous support of this year's World Congress



GE Healthcare


SIEMENS

ALOKA
THE INNOVATOR IN ULTRASOUND

PHILIPS

see it all
MEDISON

ESAOTE
THE IMAGE OF INNOVATION™



We see a way to improve visualization
of complex anatomy with imaging
planes unattainable in 2D

We see a way to
reduce gynecological
exam time by 30%

See with clarity.
Diagnose with confidence.

www.siemens.com/medical

Results may vary. Data on file.

USD-175-5A

The new ACUSON Antares™ ultrasound system, premium edition is designed to let you see with unprecedented clarity—so you can diagnose your patients with increased confidence. This is the most technologically sophisticated Antares system Siemens has ever offered, with the advanced clinical and workflow capabilities you need to enhance the efficiency of your practice and fulfill all your clinical needs. The Antares system, premium edition is ideal for your practice

ISUOG Booth #7

today, and for the future with its highly ergonomic design, advanced system architecture, state-of-the-art workflow and proven upgradeability. Its remarkable 2D, color Doppler, 3D, and 4D imaging quality and impressive vascular and OB imaging capabilities make it just as versatile as it is confidence-inspiring.

SIEMENS
medical

Social program

Social functions

Please book tickets at the registration desk. Tickets are subject to availability and will be offered on a first-come, first-served basis.

Opening ceremony and welcome reception

Sunday 25 September 2005

18:30–21:30

Venue: Exhibition area (Bayshore Grand Ballroom).

This event is free to all fully registered delegates and registered accompanying persons.

Cost per person:

Fully registered delegates and registered accompanied persons provided pre-booked	Complimentary
---	---------------

Day delegates and additional tickets	USD \$25.00
--------------------------------------	-------------

18:30–20:00 Opening ceremony

Featuring a special musical tribute to Stuart Campbell

20:00–21:30 Welcome reception

Drinks and canapés

Congress party

Tuesday 27 September 2005

19:00–24:00

Venue: Vancouver Aquarium

Delegates will have an exclusive opportunity to experience the Vancouver Aquarium by night. Very conveniently located in the heart of Stanley Park, just minutes walk from the Westin, the Aquarium is the largest in Canada and houses an extraordinary array of over 800 different animals and tropical fish. Drink wine with the beluga whales, dine with the dolphins or dance with the reef sharks, and don't miss this truly unique evening!

Cost per person: USD \$79.00

Dress: Smart-casual

Optional tours

To receive a 10% discount on Gray Line tours or overnight packages, please visit www.grayline.ca/tours/scripts/graylinelocations/locationsmain.asp?location=vancouver. Access to this website is available via the Congress website (www.isuog.2005.com).

N.B.: Discounts are valid on all tours taken up to 6 October 2005.

Gray Line Tours have a permanent desk at the Westin Bayshore Resort and Marina where tours may also be booked and tickets collected. This desk is located next to the Concierge desk in the main Hotel foyer.

Tour disclaimer

Tickets are subject to availability and will be offered on a first-come, first-served basis.

Accompanying person's program

An accompanying person's program is being offered and includes the following:

- Vancouver deluxe grand city tour
- Vancouver guide book
- Opening ceremony and welcome reception
- entrance to the exhibition (including lunch and refreshments)

Cost per person: USD \$175.00

Accompanying persons can be registered onsite at the registration desk.

**With grateful thanks to Ultrasonix for their generous support of our official Congress party.
Ultrasonix are pleased to welcome ISUOG delegates to Vancouver.**





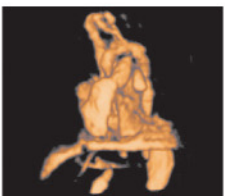
Living proof.

Volume Ultrasound studies allow you to accomplish more by providing additional clinical information, advanced visualization tools and enhanced workflow.


Proof point. The Voluson® 730 enables you to capture – within seconds – a full fetal heart cycle beating in real-time, and save the volume for later analysis. The result is a comprehensive fetal cardiac exam, including 4-chamber views and visualization of the outflow tracts for early detection of abnormalities.

And more babies living healthy lives – the real bodies of evidence.

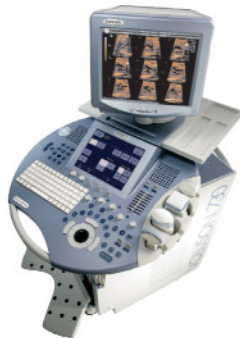Accomplish more with Volume Ultrasound. See us at Booth 11 or visit www.gehealthcare.com/ultrasound.



Inversion Mode and STIC of fetal heart



TUI and STIC of fetal heart



imagination at work

General information

Cash machine

A cash machine is located in the Conference Centre foyer.

Catering

Coffee and light lunches will be served in the exhibition hall and in the foyer areas on levels one and two of the Conference Centre.

Certificate of attendance

Certificates of attendance will be available from the CME desk on Thursday 29 September 2005 for all registered delegates who complete the CME education questionnaire.

Cloakrooms

A complimentary cloakroom service for clothing and reasonably sized items is available during the opening hours of the Congress. Items of value should not be left in the cloakroom. Please make sure you collect all your belongings at the end of each day. Forgotten and unclaimed items will be donated to local charities after 30 days.

The cloakroom is located in the main foyer of the Conference Centre and is open during the following times:

Sunday 25 September 2005	09:00–21:30
Monday 26 September 2005	07:30–18:00
Tuesday 27 September 2005	08:00–18:00
Wednesday 28 September 2005	08:00–17:30
Thursday 29 September 2005	07:00–14:30

Congress Secretariat

Concorde Services Ltd
42 Canham Road, London W3 7SR
United Kingdom
Tel: +44 (0) 20 8743 3106
Fax: +44 (0) 20 8743 1010
Email: isuog@concorde-uk.com
Website: www.isuog2005.com

Contact onsite at the registration desk.

Currency exchange

Banks are normally open between 09:30/10:00 and 15:00 on weekdays, although some banks in central Vancouver are open from 09:00–17:00.

Disclaimer

All best endeavours will be made to present the program as printed. However the 15th World Congress on Ultrasound in Obstetrics and Gynecology and its agents reserve the right to alter or cancel without prior notice, any of the arrangements, timetables, plans or other items relating directly or indirectly to the Congress for any reason beyond its reasonable control. The 15th World Congress on Ultrasound in Obstetrics and Gynecology and its agents are not liable for any loss or inconvenience caused as a result of such alteration.

Duplication/Recordings

Photography, audio taping, video recording, digital taping or any other form of duplication is strictly prohibited in the session halls and poster areas, **except** with the express consent, IN ADVANCE, of ISUOG and the speakers involved.

First aid

Should you require first aid treatment, please contact the registration desk staff.

Future meetings

Literature regarding future meetings of interest to participants is displayed in the mezzanine area of level two of the Conference Centre.

ISUOG Secretariat

Unit 4, Blythe Mews
Blythe Road, London W14 0HW
United Kingdom
Tel: +44 (0) 20 7471 9955
Fax: +44 (0) 20 7471 9959
Email: congress@isuog.org
Website: www.isuog.org

Contact onsite at stand no. 1.

Lost property

Please hand any lost property to the staff at the registration desk where it will be made available for collection. At the end of the Congress any unclaimed items will be held at the venue for 30 days, after which they will be donated to local charities.

Messages

The telephone and fax numbers for people wishing to leave messages for you during the Congress opening hours are:

Tel: +1 (604) 682 3377
Fax: +1 (604) 687 3102

Name badges

Please wear your name badges at all times as an aid to identification. Name badge holders have been colour coded as follows:

Full delegates	Blue
Day delegates/Pre-Congress courses	Clear
Invited faculty	Blue with ribbon
Exhibitors	Yellow
Accompanying persons	Red

Official language

The official language of the Congress is English. No simultaneous translation will be available.

Smoking policy

Smoking is not permitted inside the Resort or Conference Centre. Smoking is permitted in the outside areas (i.e. balconies).

Telephones

Telephone terminals are located throughout the venue. Please note that all telephones accept credit cards and coins.

Tourist information

A tourist information desk will be situated in the foyer opposite the Concierge and Gray Line Tours desks.

ISUOG business meetings

Date	Start time	End time	Meeting	Room
Saturday 24 September	09:00		ISUOG Board	Marine
Sunday 25 September	10:00	12:00	Meeting Planning Committee (MPC)	Marine
Sunday 25 September	13:00	15:00	Scientific Committee	Marine
Monday 26 September	07:45	08:15	Session Chairs' Briefing	Seymour
Monday 26 September	10:00	10:30	Free Communications Judging Committee	Seymour
Monday 26 September	11:30	12:00	Annual General Meeting (ALL DELEGATES)	Salons D-F
Monday 26 September	16:00	17:30	ISUOG Editors	Marine
Monday 26 September	17:30	19:30	Editorial Board	Marine
Tuesday 27 September	07:30	08:30	New Media Committee	TBC
Tuesday 27 September	09:00	11:00	Education Committee	Marine
Tuesday 27 September	12:00	13:30	3D Focus Group	Marine
Tuesday 27 September	15:30	17:30	Fetal Echocardiography Focus Group	Capilano
Wednesday 28 September	12:00	13:00	MPC: Exhibitors' Closing Meeting	Oak 1
Wednesday 28 September	12:00	13:00	Safety Committee	Capilano
Wednesday 28 September	12:00	13:30	Fetal MRI Focus Group	Seymour
Thursday 29 September	07:00	09:00	ISUOG Board (supplementary)	Oak
Thursday 29 September	08:30	10:00	Standards Committee	Capilano
Thursday 29 September	10:45	12:15	Perinatal Doppler Focus Group	Oak

Notes





16th World Congress on Ultrasound in Obstetrics and Gynecology

3–7 September 2006
London, UK

Critical dates 2006

January	Call for papers
3 March	Exhibition/sponsorship discount deadline
3 April	Abstract submission and reduced registration rate deadline
May/June	Confirmation of accepted/rejected abstracts
3 July	Early bird registration rate deadline
3 September	Onsite registration opens

Please check our Congress website in due course for further details and updates.

www.isuog2006.com

Full delegate fees include a one-year membership to ISUOG and subscription to *Ultrasound in Obstetrics & Gynecology*. Existing members also benefit from reduced fees to attend the World Congress. Find out more about ISUOG membership or JOIN NOW at www.isuog.org



Organised by the
International Society of
Ultrasound in Obstetrics
and Gynecology
www.isuog.org

Congress Secretariat:
ISUOG, Unit 4 Blythe Mews
Blythe Road, London W14 0HW, UK
Tel: +44 (0) 20 7417 9955
Fax: +44 (0) 20 7417 9959
Email: congress@isuog.org



ISUOG would like to acknowledge the financial support of the following major sponsors:

Platinum level sponsors



GE Healthcare

PHILIPS

SIEMENS

Gold level sponsors

see it all
MEDISON

Silver level sponsors

ALOKA
THE INNOVATOR IN ULTRASOUND

ESAOTE
THE IMAGE OF INNOVATION™



15th World Congress on Ultrasound
in Obstetrics and Gynecology



Organised by the
International Society of
Ultrasound in Obstetrics
and Gynecology
www.isuog.org

Congress Secretariat:
Concorde Services Ltd
42 Canham Road, London W3 7SR, UK
Tel: +44 (0) 20 8743 3106
Fax: +44 (0) 20 8743 1010
Email: isuog@concorde-uk.com
www.isuog2005.com

