



ISUOG Basic Training

Examining the Upper Lip, Face & Profile

Learning objectives

At the end of the lecture you will be able to:

- Describe how to obtain the 3 planes required to assess the anatomy of the fetal face
- Recognise the differences between the normal & most common abnormal ultrasound appearances of the 3 planes

Key questions

1. What are the key ultrasound features of plane 18 (upper lip)?
2. What are the key ultrasound features of plane 20 (profile)?
3. What probe movements are required to move from plane 18 (upper lip) to plane 20 (profile)?
4. Which abnormalities should be excluded after correct assessment of planes 18(upper lip),19 (orbits) & 20 (profile)?

The 20 + 2 planes

Anatomical area	Plane	Description
Overview 1	Sweep 1	Longitudinal head & body for initial orientation
Spine	1	Sagittal complete spine with skin covering
	2	Coronal complete spine
	3	Coronal section of body
Head	4	Transventricular plane*
	5	Transthalamic plane*
	6	Transcerebellar plane*
Thorax	7	Lungs, 4 chamber view of heart
	8	Left ventricular outflow tract (LVOT)
	9	Right ventricular outflow tract (RVOT) & crossover of LVOT
	10	3 vessel trachea (3VT) view of heart

* measurement required

The 20 + 2 planes

Anatomical area	Plane	Description
Abdomen	11	Transverse section of abdomen with stomach & umbilical vein*
	12	Transverse section of abdomen at cord insertion
	13	Transverse section(s) of left kidney & pelvis, right kidney & pelvis
Pelvis	14	Transverse section of pelvis, bladder, both umbilical arteries
Limbs	15	Femur diaphysis length*
	16	3 bones of both legs, both feet & normal relationships to both legs
	17	3 bones of both arms, both hands & normal relationships to both arms
Face	18	Coronal view of upper lip, nose & nostrils
	19	Both orbits, both lenses
	20	Median facial profile
Overview 2	Sweep 2	Transverse sweep of body from neck to sacrum, one vertebra at a time

* measurement required

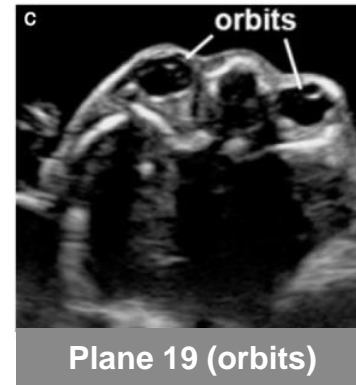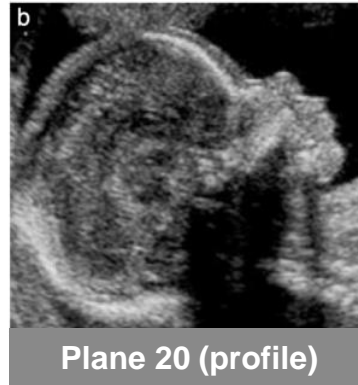
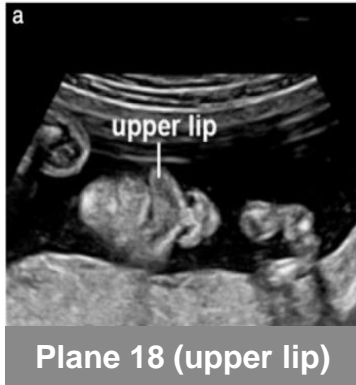20 + 2 planes abnormal appearances

Plane	Area	Abnormal appearances (50+IUD) excluded by the correct 2+20 approach
Sweep 1		Anencephaly, IUD
1-3	Spine	Abnormal abdominal situs, left sided diaphragmatic hernia, meningocoele, Open spina bifida, sacral agenesis, sacral coccygeal teratoma,
4-6	Head	Alobar holoprosencephaly, banana shaped cerebellum, cystic hygroma, large posterior fossa cyst, lemon shaped skull, occipital encephalocoele, skin oedema, ventriculomegaly
7-10	Thorax	AVSD, CPAM, double aortic arch, ectopia cordis, overriding aorta, persistent left vena cava*, right aortic arch, severe aortic stenosis, coarctation & pulmonary stenosis, significant pericardial effusion (>4 mm) & pleural effusion (>4 mm), situs inversus/ambiguous, tetralogy of Fallot, transposition, univentricular heart
11-13	Abdomen	Ascites, bilateral renal agenesis, duodenal atresia, echogenic bowel*, gastroschisis, omphalocoele, renal pelvic dilatation (>7mm AP), small/absent stomach
14	Pelvis	Cystic renal dysplasia, lower urinary tract obstruction, 2 vessel cord
15-17	Limbs	Fixed flexion deformities wrist, severe skeletal dysplasia (some), talipes
18-20	Face	Anophthalmia, cataract*, cleft lip, proboscis*, severe micrognathia

* optional, for local decision as to whether or not included

ISUOG guideline

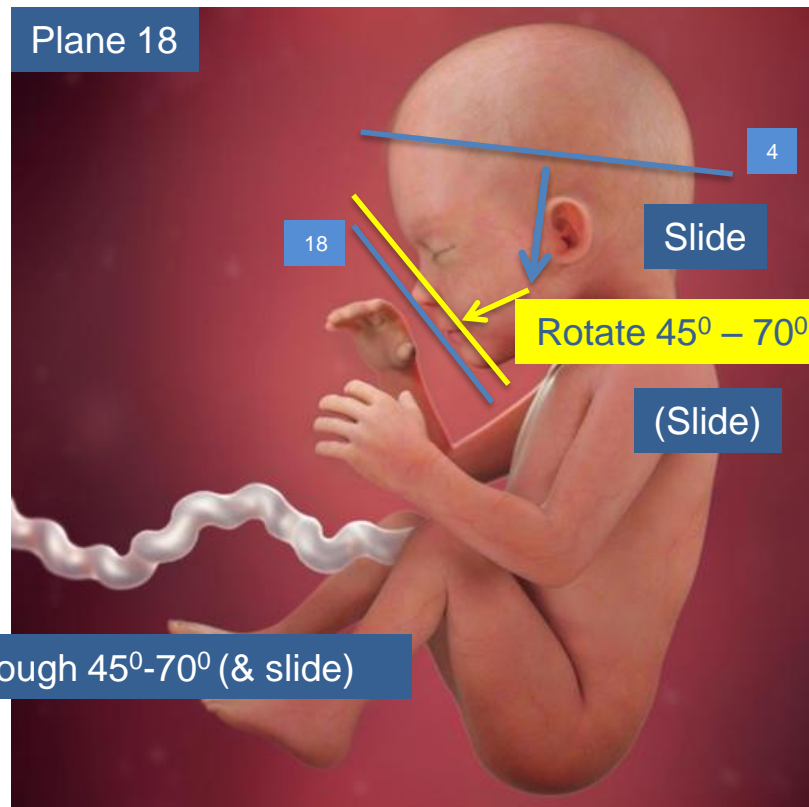
- Minimum evaluation of the fetal face should include an attempt to visualise the upper lip for possible cleft anomaly
- If technically feasible, other facial features that can be assessed include the median facial profile, orbits, nose and nostrils



Practice guidelines for performance of the routine midtrimester scan (UOG 2011; 37:116-126)

Plane 18 (upper lip) – probe movements

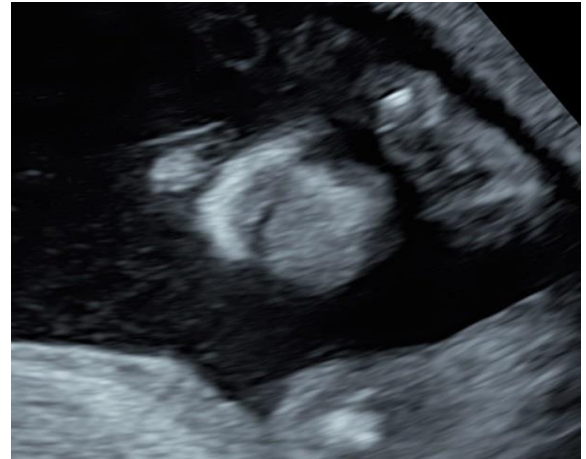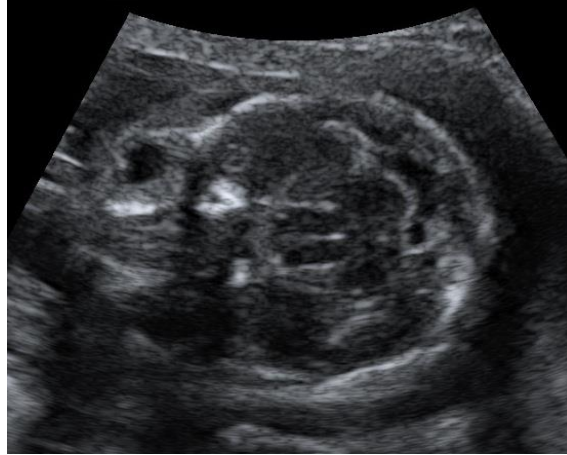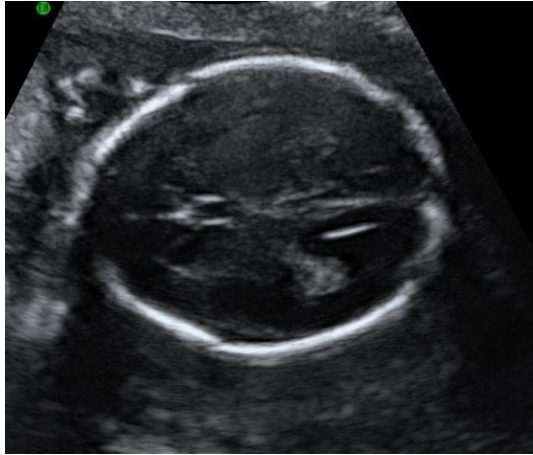Plane	Description
4	Transventricular plane
18	Coronal view of upper lip, nose & nostrils
19	Both orbits, both lenses
20	Both orbits, both lenses Median facial profile



From plane 4 to 18 - slide & rotate through 45°-70° (& slide)

Plane 18 (upper lip) - probe movements

- HC section, midline horizontal, slide
- Orbits & cerebellum section, rotate 45° - 70°
- Coronal section of face, slide to lips & nasal tip



What is an adequate section?

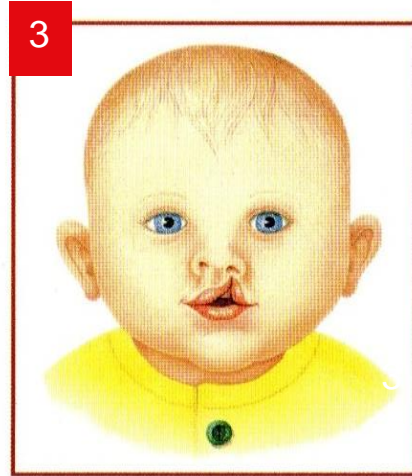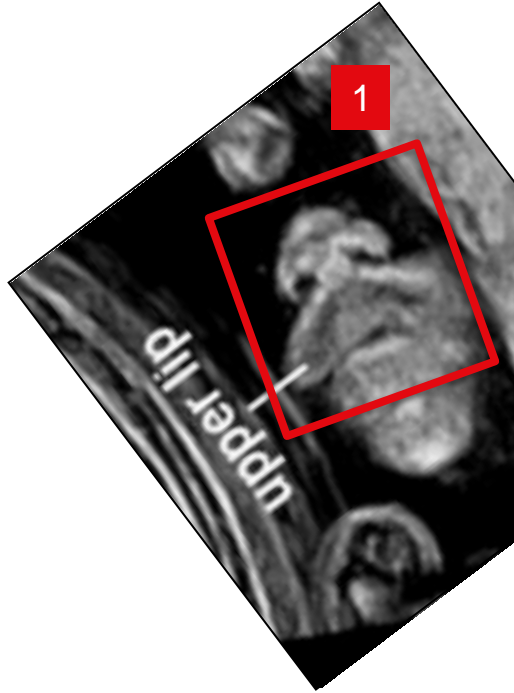


Fig 4. Incomplete unilateral cleft lip

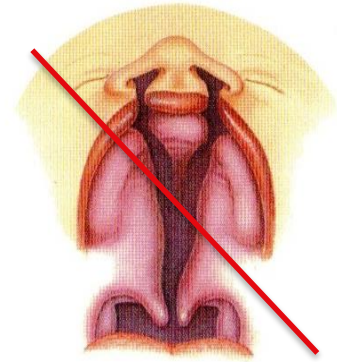
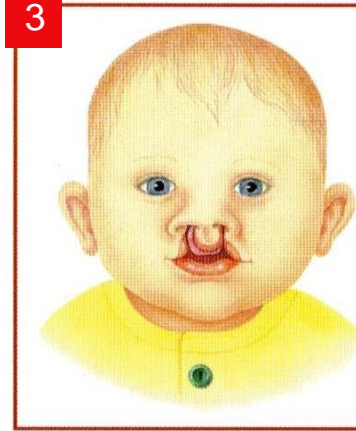
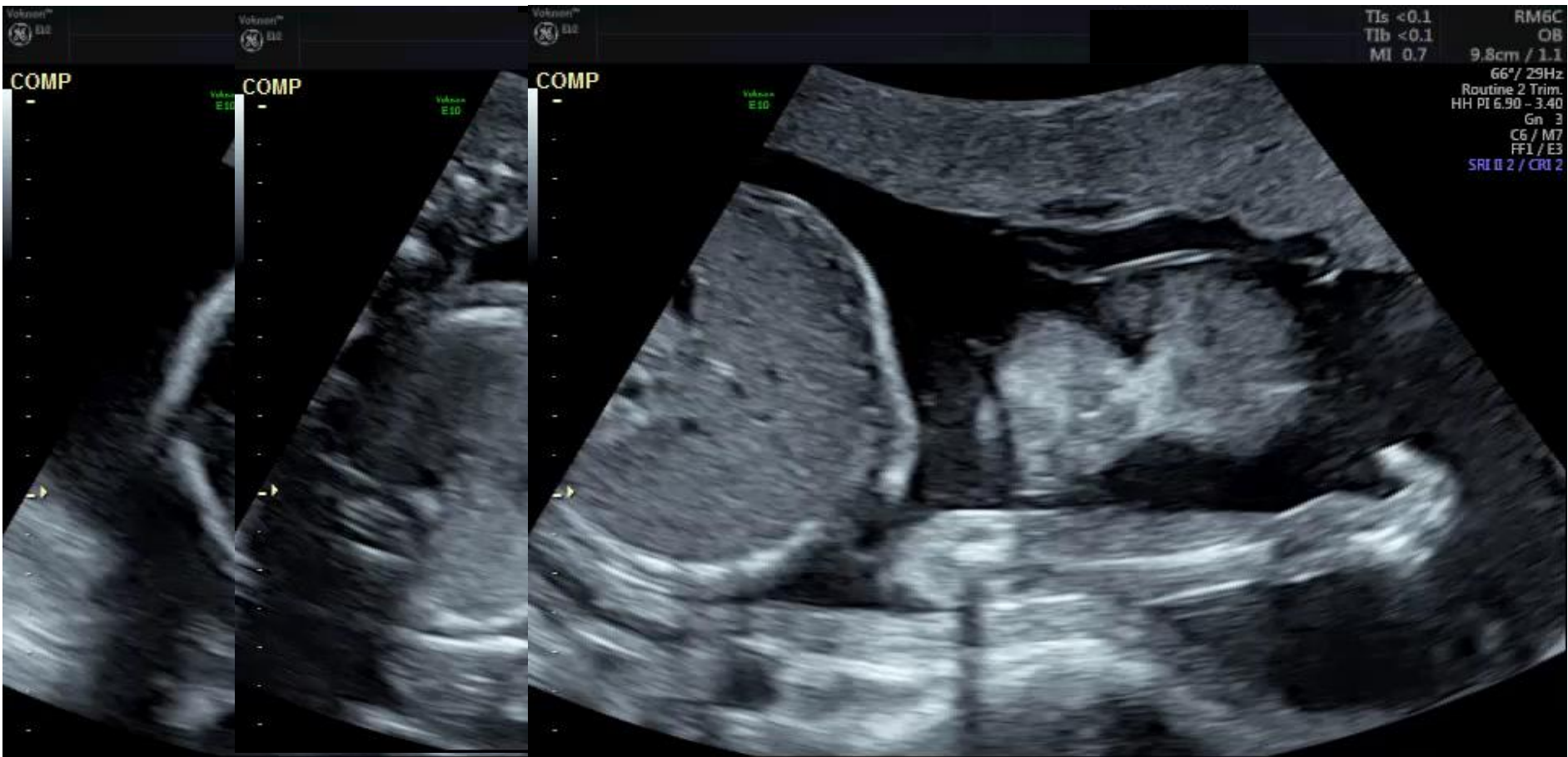


Fig 6. Bilateral cleft lip, alveolus & palate

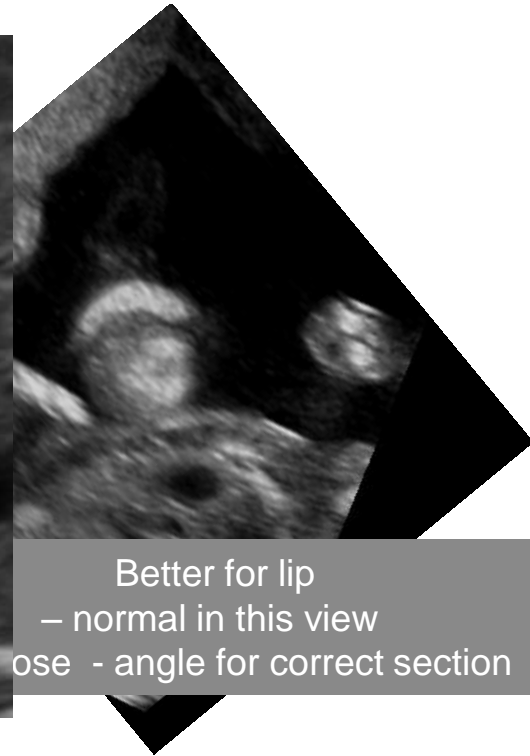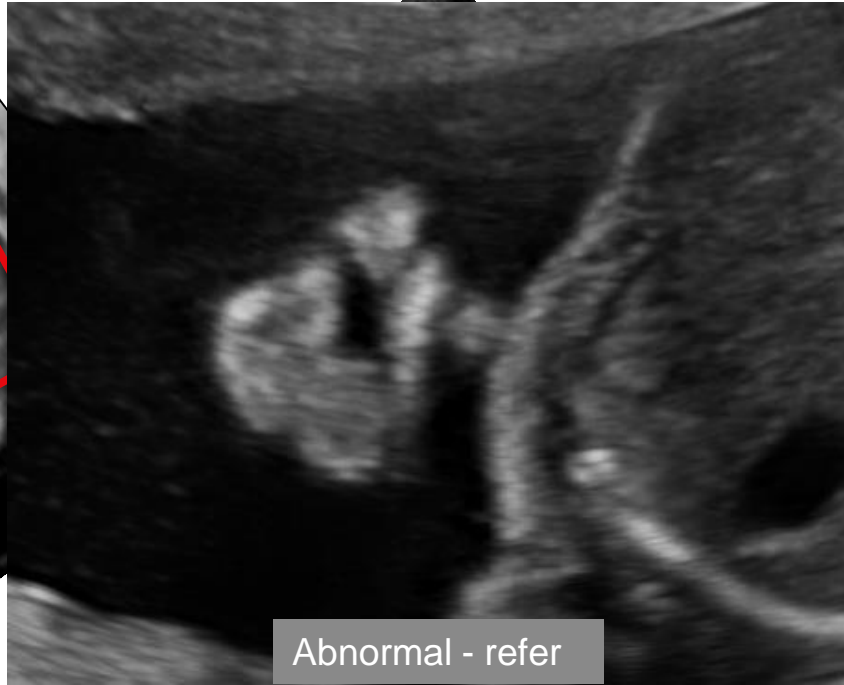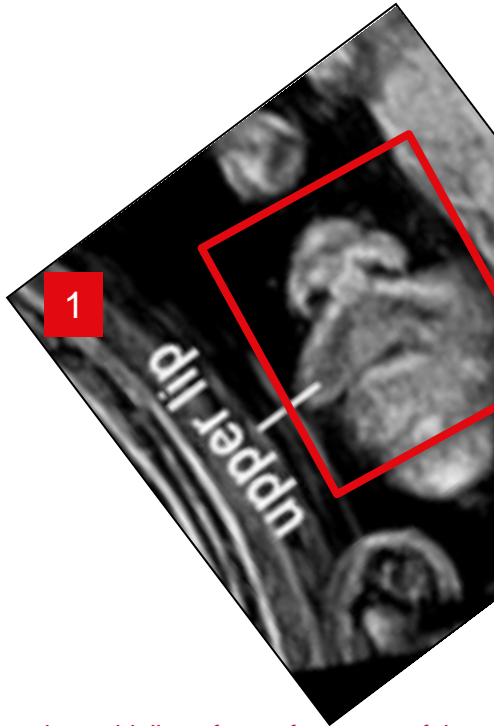Figure 25.1. Development shown in red.

Practice guidelines for performance of the routine midtrimester scan, UOG 2011; 37:116-126

Fitzgerald M J & Fitzgerald M, Human Embryology, 1994, 168-173. Chudleigh T & Cook K, Cleft Lip & Palate: A Guide for Sonographers, prepared by CLAPA, 2001.



What is an adequate section?

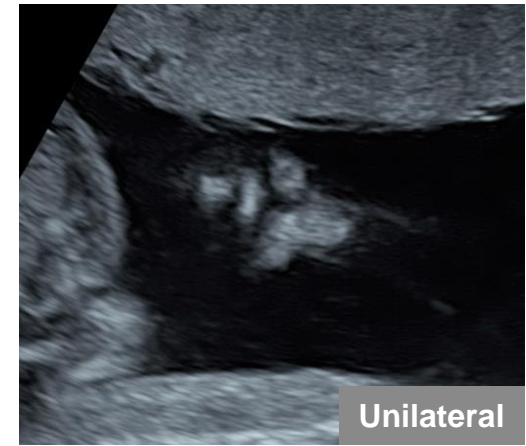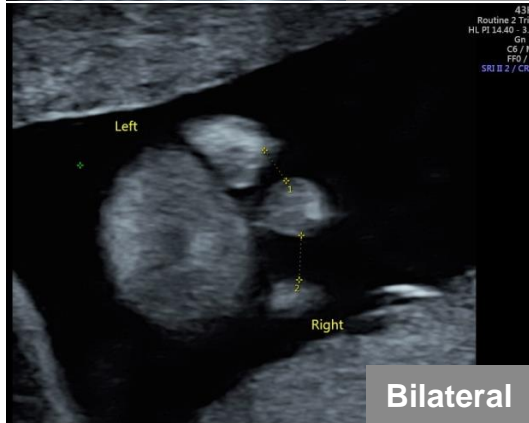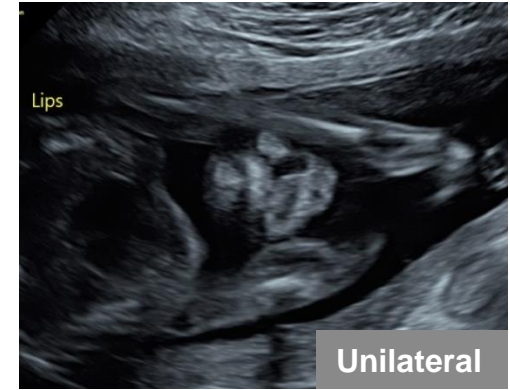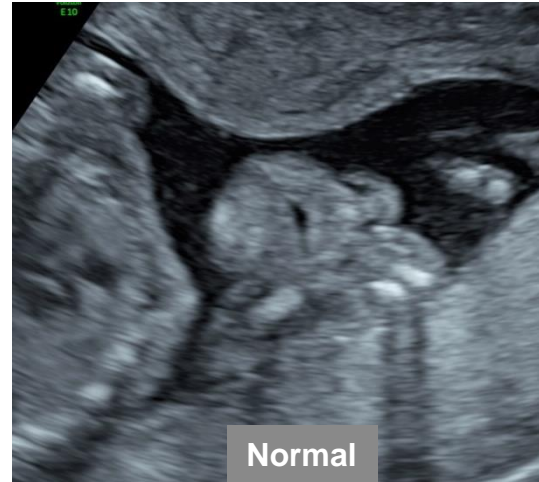
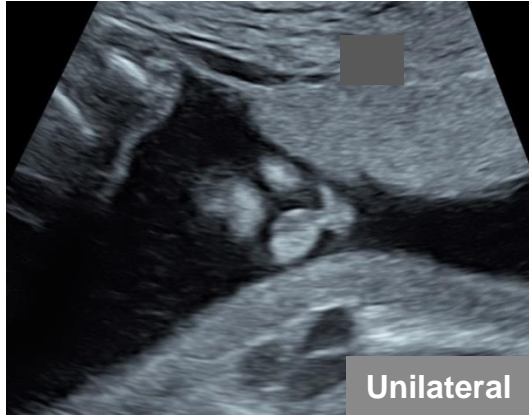


Practice guidelines for performance of the routine mid-trimester scan, UOG, 2011, **37**:116-126/
Fitzgerald M J & Fitzgerald M, In *Human Embryology*, 1994: 168-173. Chudleigh T & Cook K, *Cleft Lip & Palate: A Guide for Sonographers*, prepared by CLAPA, 2001.

Terminology & incidence

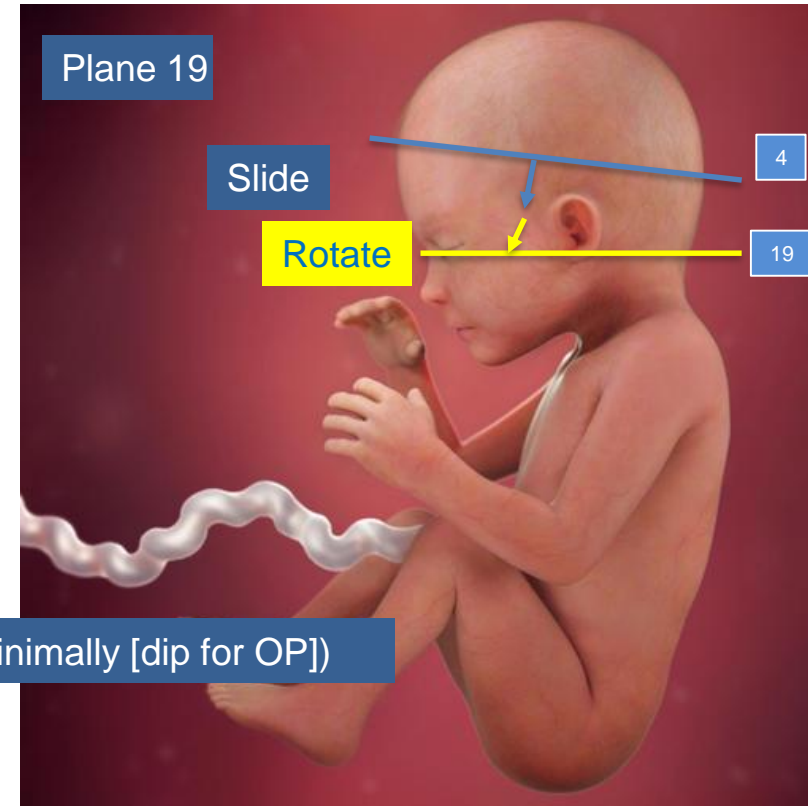
- In the context of facial clefting, 'lip' may describe upper lip only or upper lip & alveolar ridge/alveolus
- Overall incidence of cleft lip & palate malformations (live births) in Europe ~1:700. Similar to that of Down's syndrome & talipes
- Isolated cleft lip (+/- alveolar ridge) 25%
- Cleft lip, alveolar ridge & palate, of varying degrees, 35%
 - 25% unilateral
 - 10% bilateral
- Isolated cleft palate 40%

Normal or abnormal?



Plane 19 (orbits) - probe movements

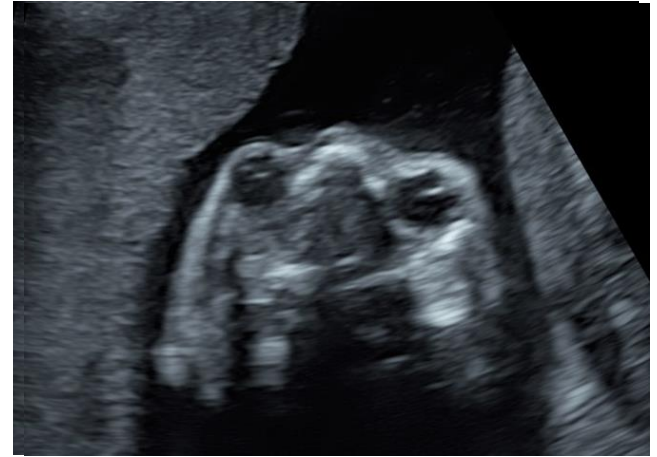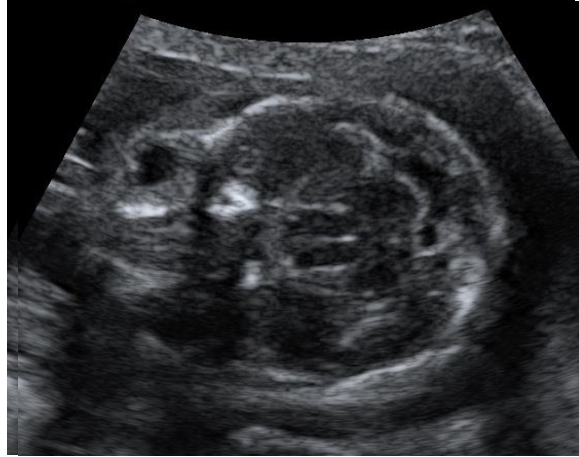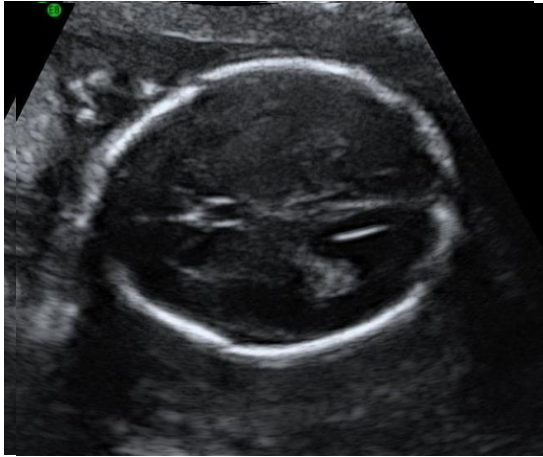Plane	Description
4	Transventricular plane
18	Coronal view of upper lip, nose & nostrils
19	Both orbits, both lenses
20	Median facial profile



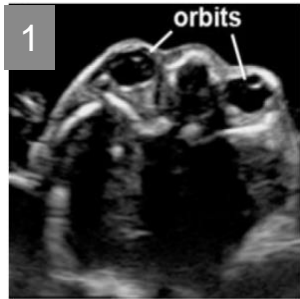
From plane 4 to 19 – slide (**rotate** minimally [dip for OP])

Plane 19 (orbits) - probe movements

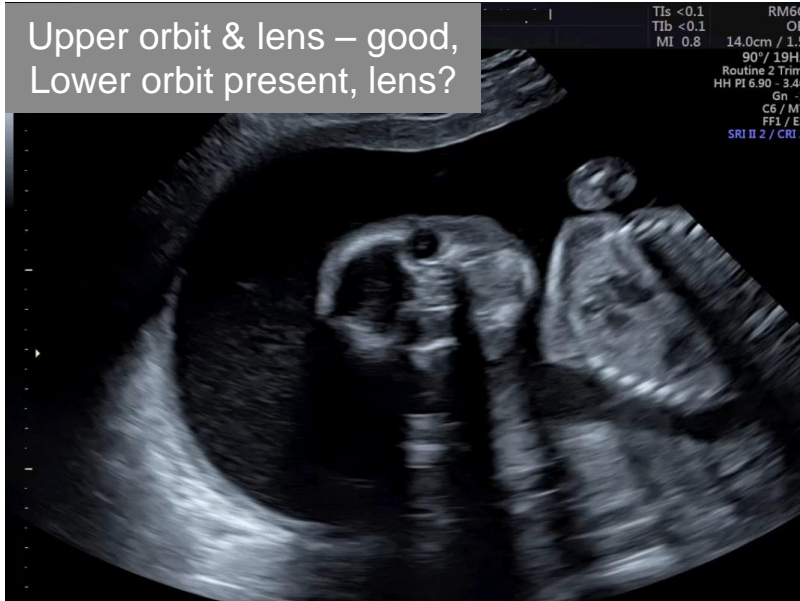- HC section, midline horizontal → slide
- Orbits & cerebellum section → rotate towards neck minimally
- Section will be ~OT → dip ($\sim 90^\circ$) for OP section



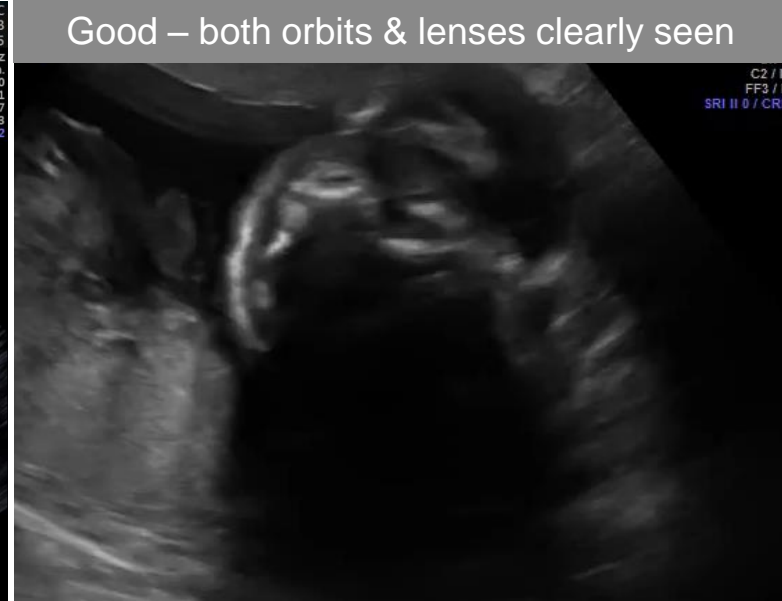What is an adequate section?



Upper orbit & lens – good,
Lower orbit present, lens?

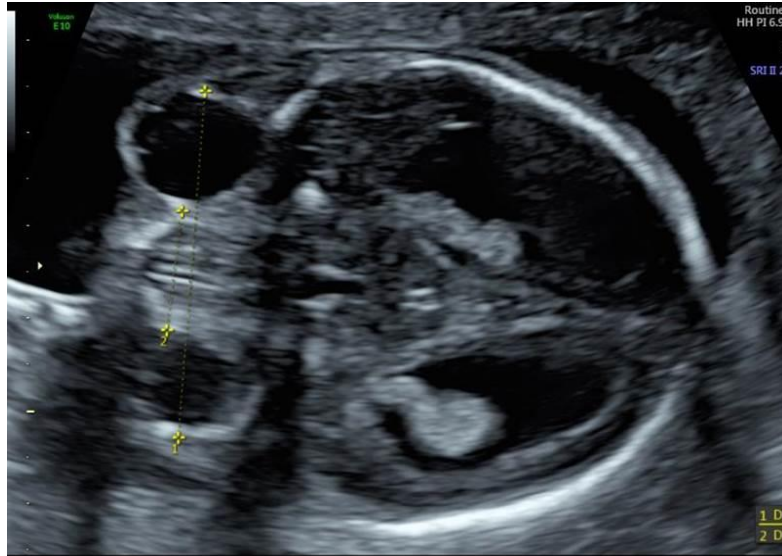
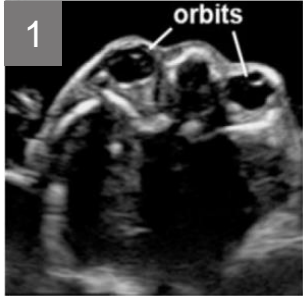


Good – both orbits & lenses clearly seen

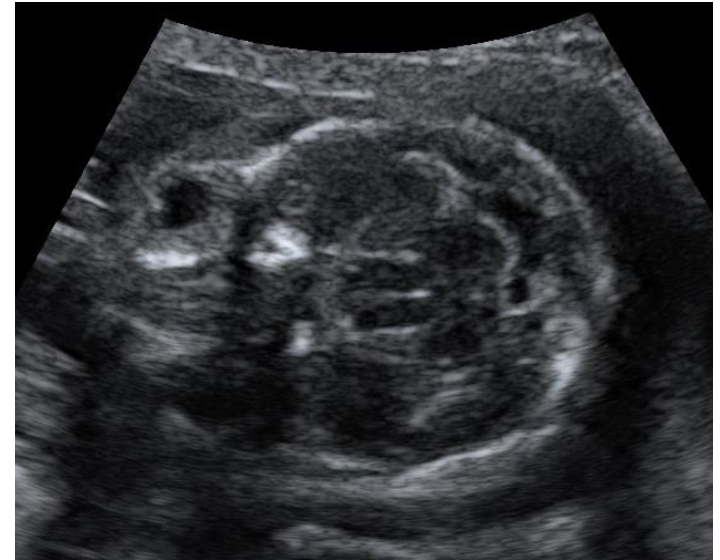

Practice guidelines for performance of the routine midtrimester scan, UOG, 2011, 37:116-126)

Normal or abnormal?



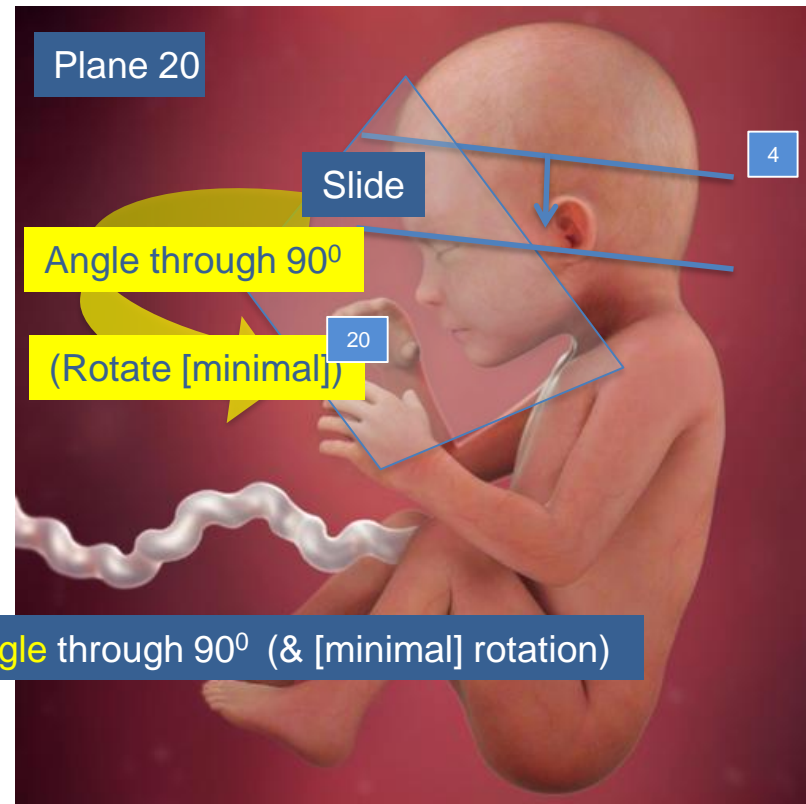
Size discrepancy of orbits - abnormal*
(?ventricles)
Refer



?Normal ? nondiagnostic
- Section good enough to confirm
appearances normal?

Plane 20 (profile) – probe movements

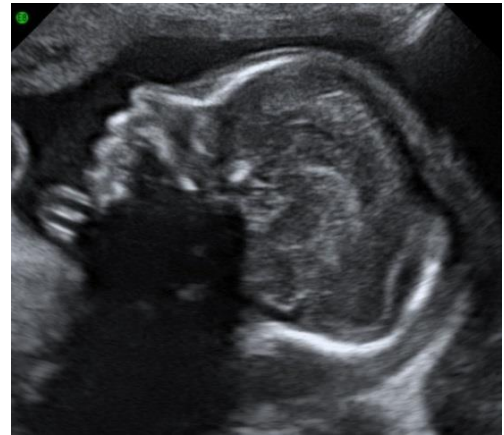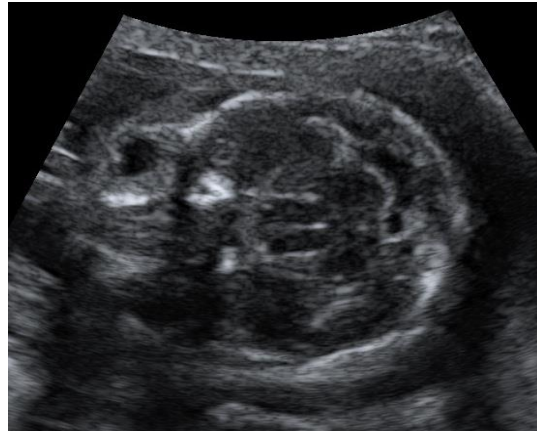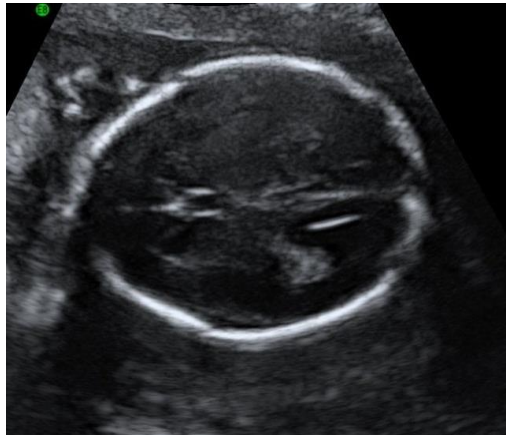Plane	Description
4	Transventricular plane
18	Coronal view of upper lip, nose & nostrils
19	Both orbits, both lenses
20	Median facial profile



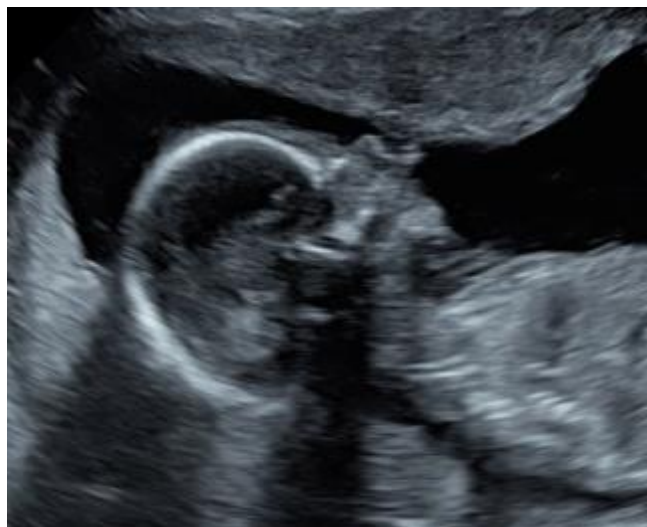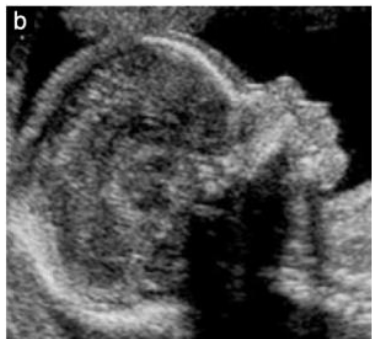From plane 4 to 20 - slide, angle through 90° (& [minimal] rotation)

Plane 20 (profile) - probe movements

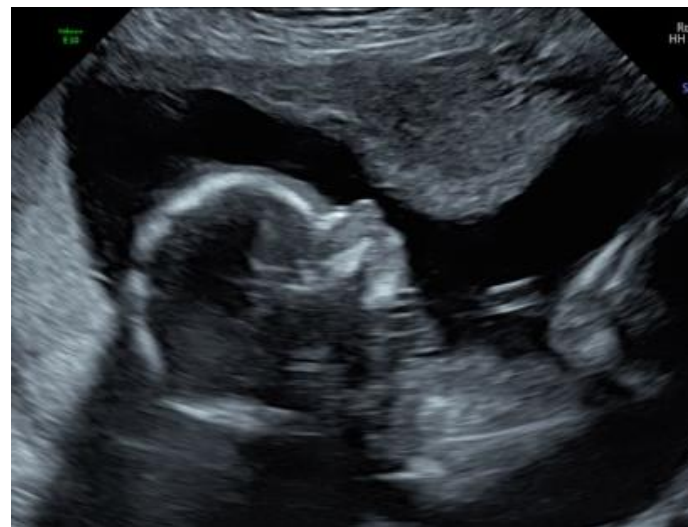- HC section, midline horizontal, slide
- Angle probe through 90° to produce mid-sagittal section
- Minimal rotation of probe to acquire correct section



What is an adequate section?

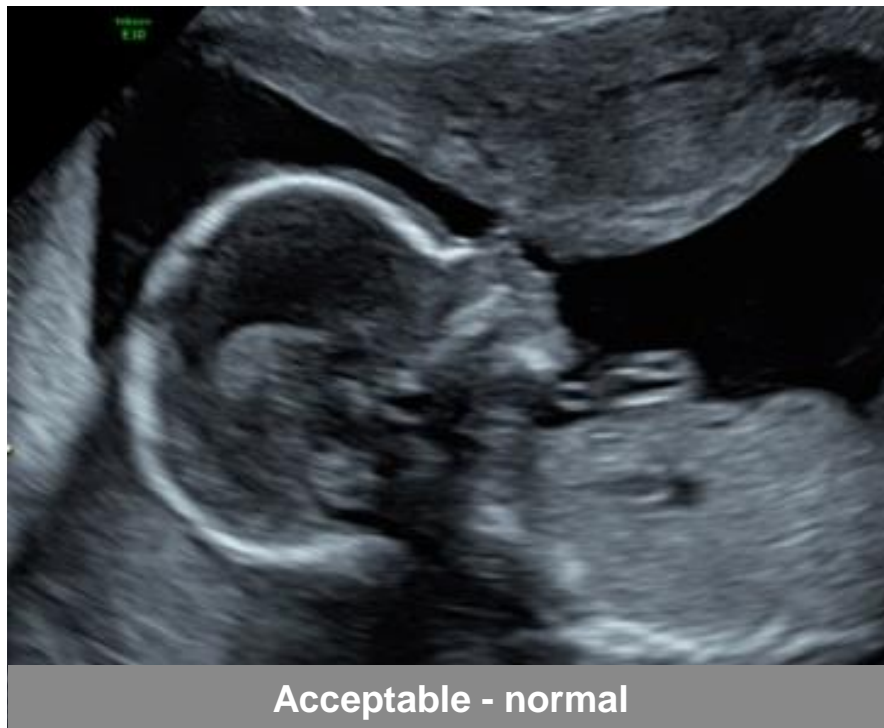
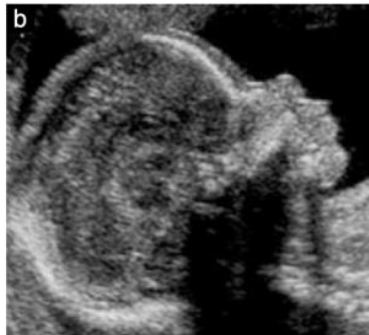
Incorrect section, para-sagittal
- Slide (minimally)

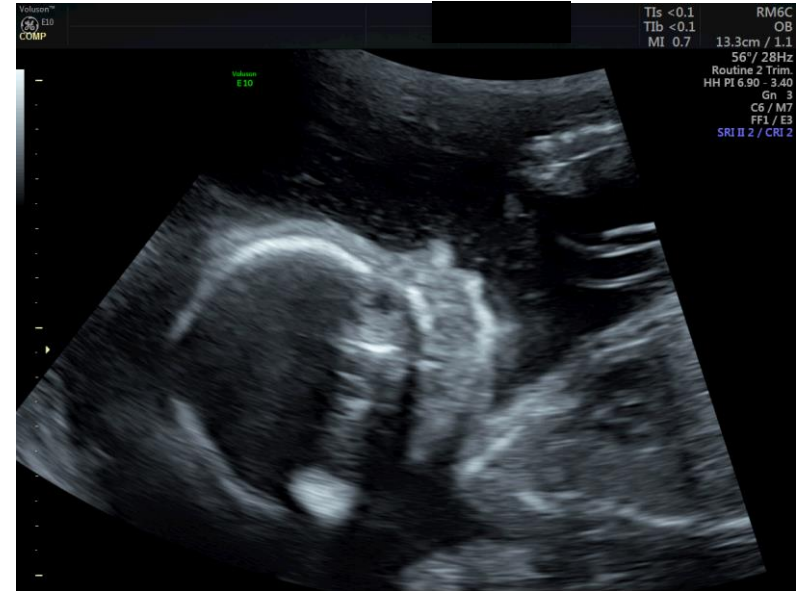
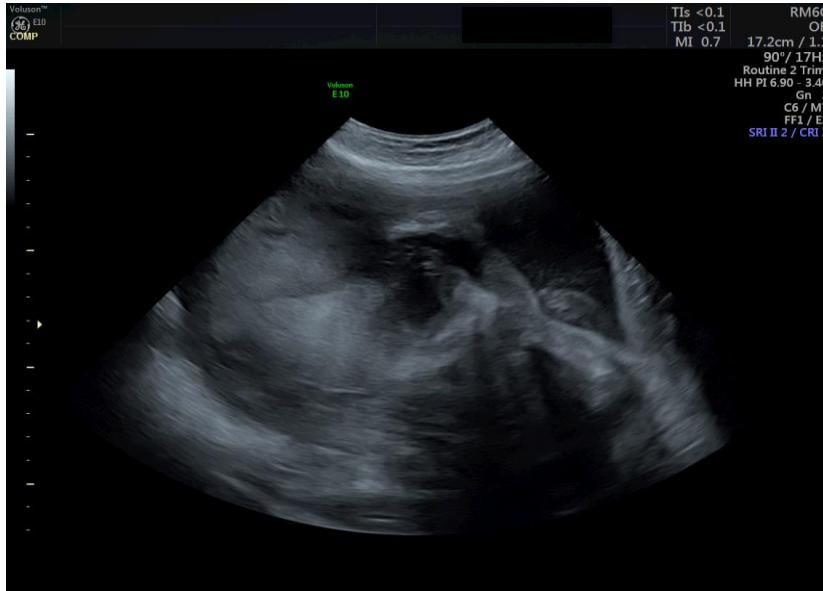
Incorrect section or abnormal?
?Chin - slight rotation

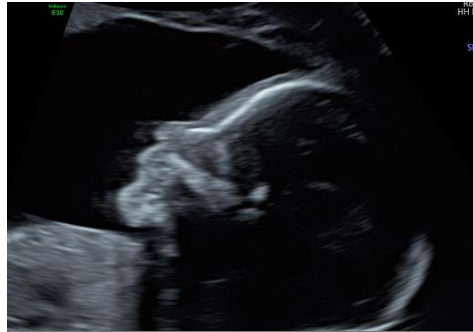What is an adequate section?



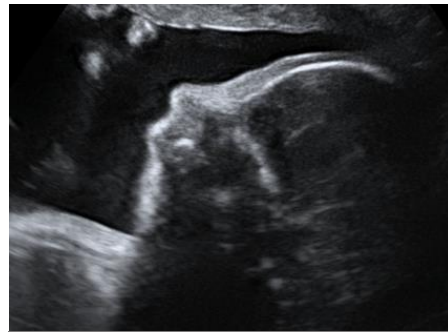What is an adequate section?



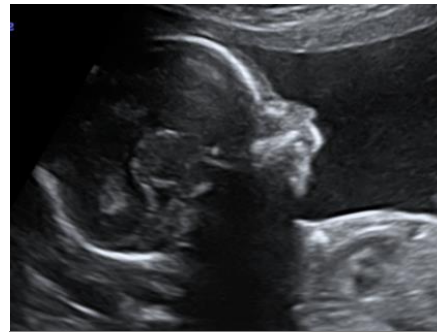Normal or abnormal?



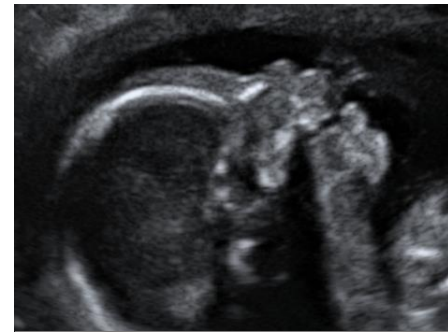Normal



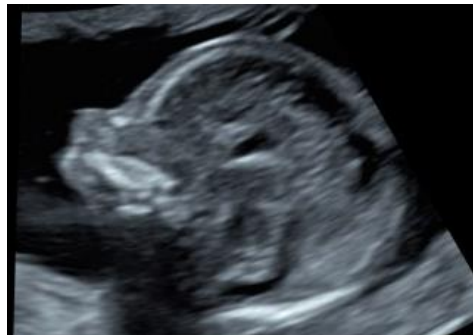Abnormal - refer



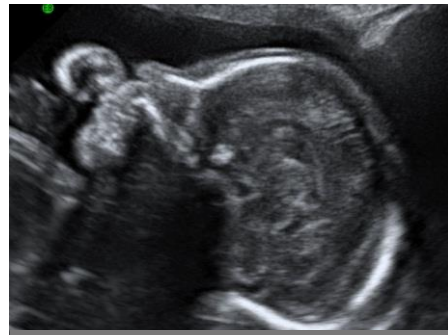Abnormal - refer



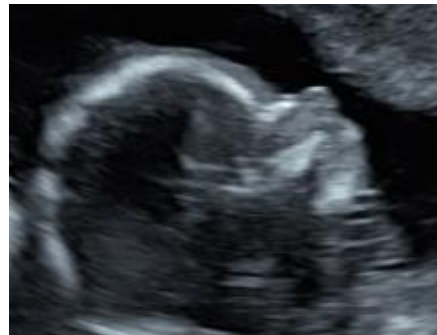?Normal



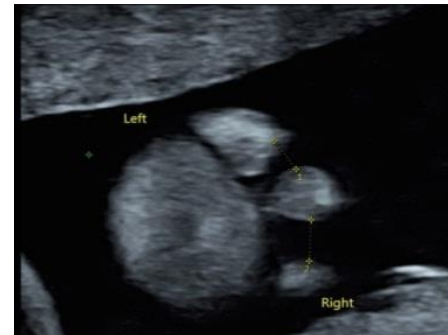Abnormal - refer



Normal



?Section correct - (normal)



Lip of above

Key points

1. Imaging the upper lip correctly is important as facial clefting has a birth incidence similar to Down's syndrome & talipes.
2. Evaluation of the orbits & lenses can be performed from an occiput transverse position, providing that the lower orbit & lens are adequately imaged.
3. Orbital anomalies & detectable abnormalities of the lens are rare.

Key points

4. The most common reason for incorrectly suspecting micrognathia in a normal fetus is failing to appreciate that the section obtained is oblique, rather than truly mid-sagittal. False positives decrease with experience.
5. If you are unable to confirm the normal appearance of all the structures in planes 18-20, the woman should be referred for a more detailed examination.
6. Practice, performed correctly, makes perfect.



ISUOG Basic Training by **ISUOG** is licensed under a **Creative Commons Attribution-NonCommercial-NoDerivatives 4.0 International License**.

Based on a work at **<https://www.isuog.org/education/basic-training.html>**.

Permissions beyond the scope of this license may be available at **<https://www.isuog.org/>**