



ISUOG Basic Training

Examining the Uterus, Cervix, Ovaries & Adnexae: Normal Findings

Learning objective

At the end of the lecture you will be able to:

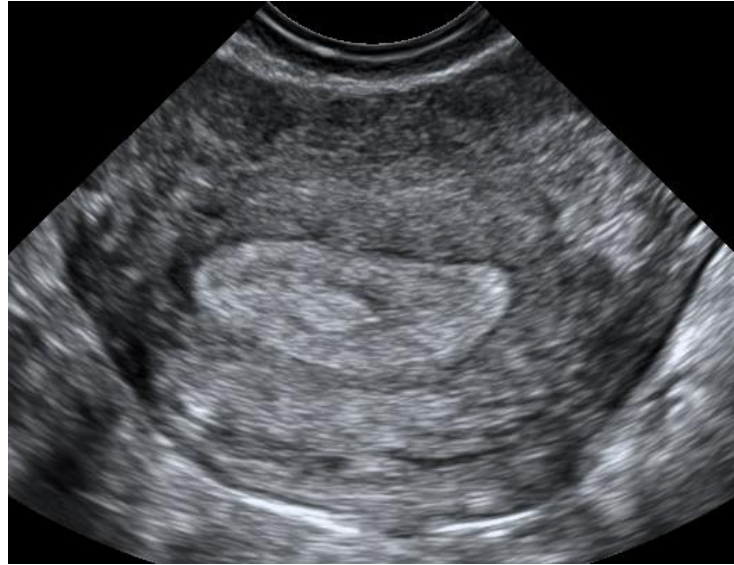- Recognise the typical ultrasound appearances of a normal gynaecological ultrasound examination

Key questions

- What is the correct scanning technique to image the cervix, uterus and ovaries effectively?
- What are the principal ultrasound features of:
 - The normal cervix
 - The normal uterus
 - The normal ovary/adnexae
- How do I recognise a correctly positioned IUD?

Abdominal gynecological ultrasound examination- orientation

On a transverse scan patient's right side is shown to the left on screen

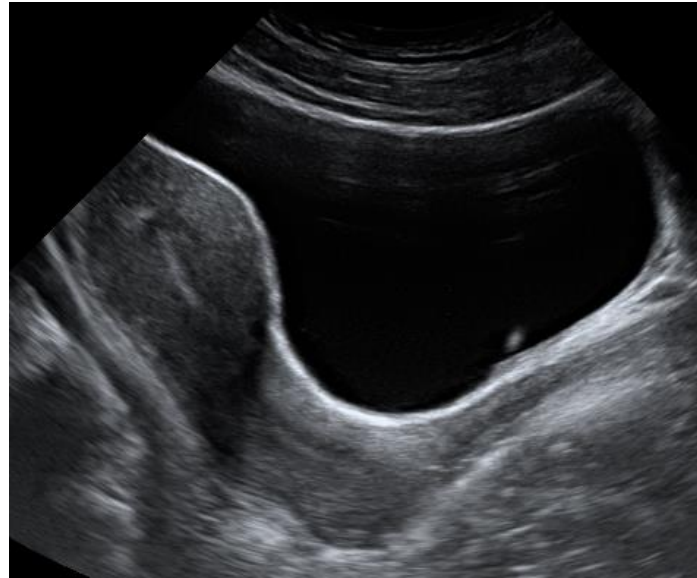


Patient's right side

Patient's left side

Abdominal gynecological ultrasound examination- orientation

On a longitudinal scan cranial is shown to the left on the screen

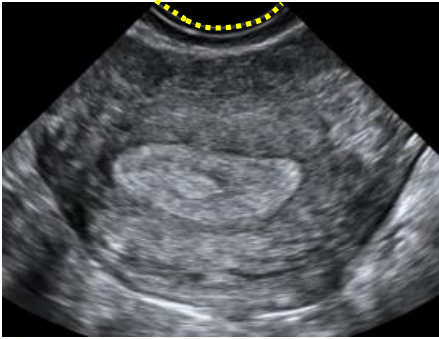


Cranial
(patient's head)

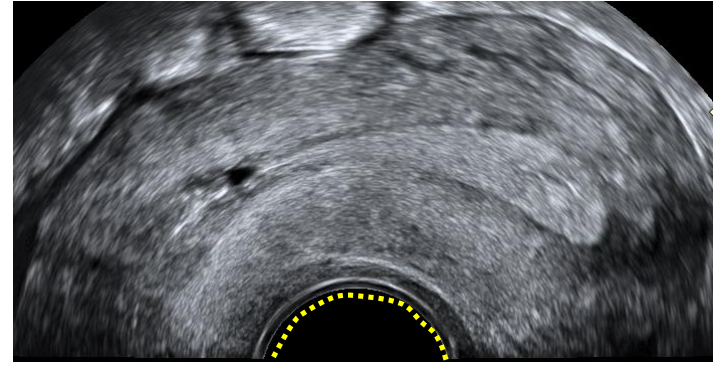
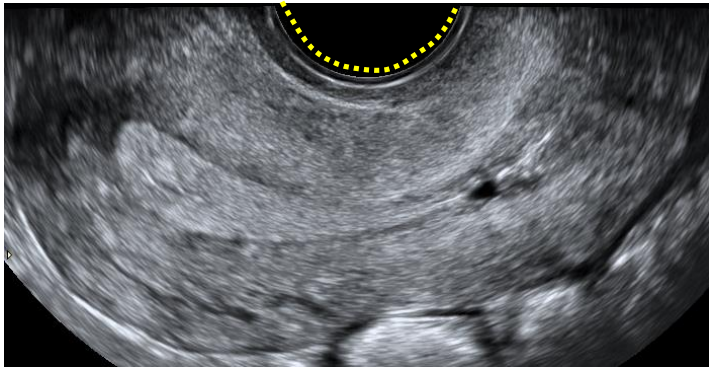
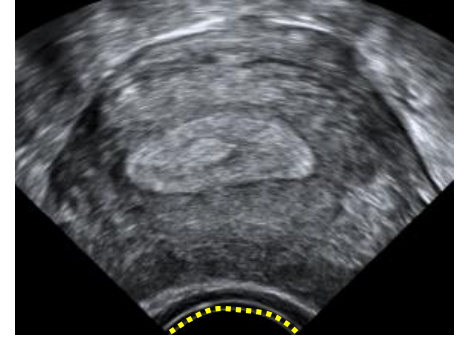
Caudal
(patient's feet)

Vaginal gynecological ultrasound examination- orientation

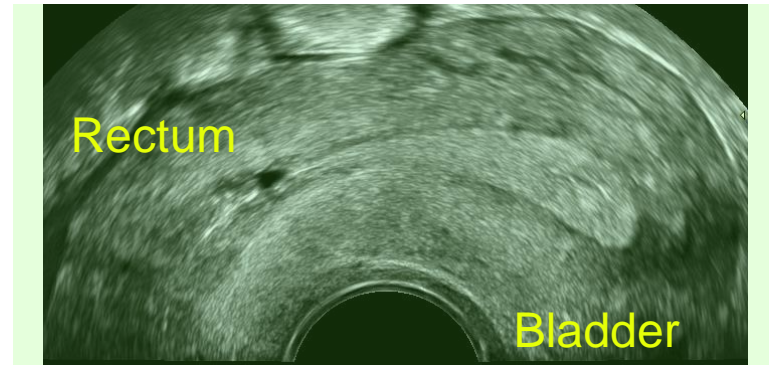
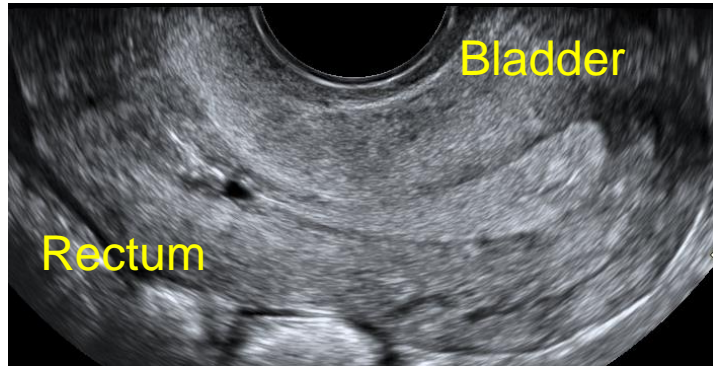
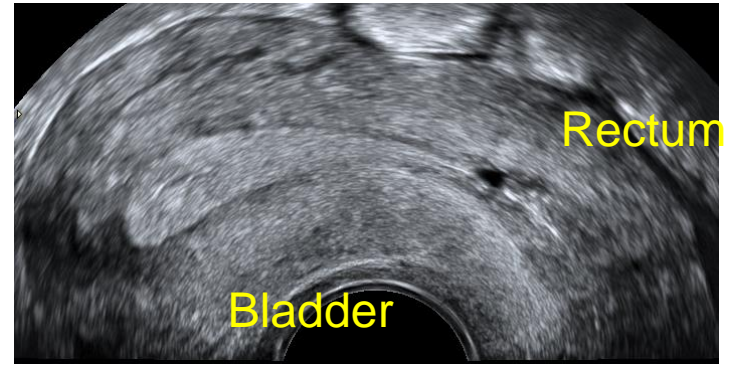
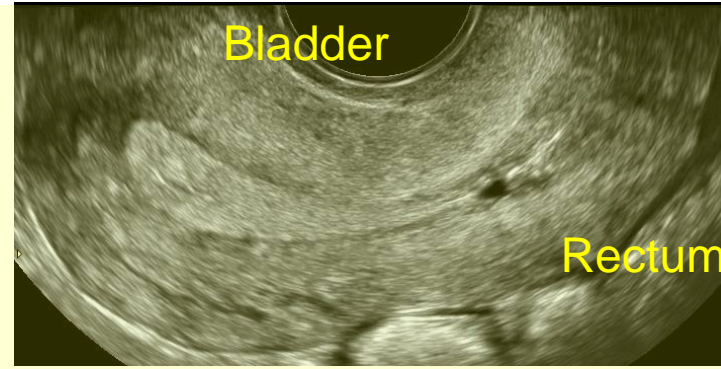
Patient's right



Patient's right



Uterus in anteversion (& slight anteflexion)



Vaginal or abdominal scan?

Abdominal scan

- Low frequency
- Poor resolution
- Good overview
- Scan the abdomen
- Full bladder

Vaginal (rectal) scan

- High frequency
- Superb resolution
- Poor overview
- Abdomen not seen
- Empty bladder

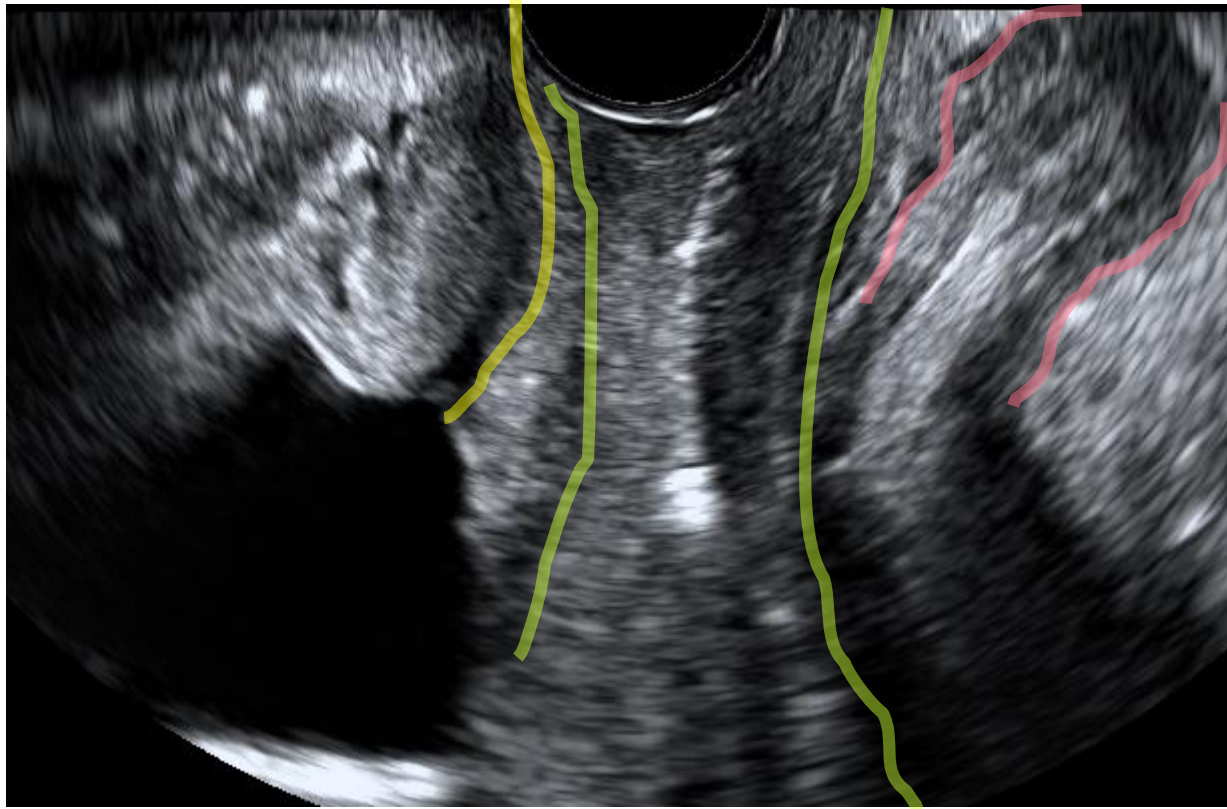
Gynecological ultrasound

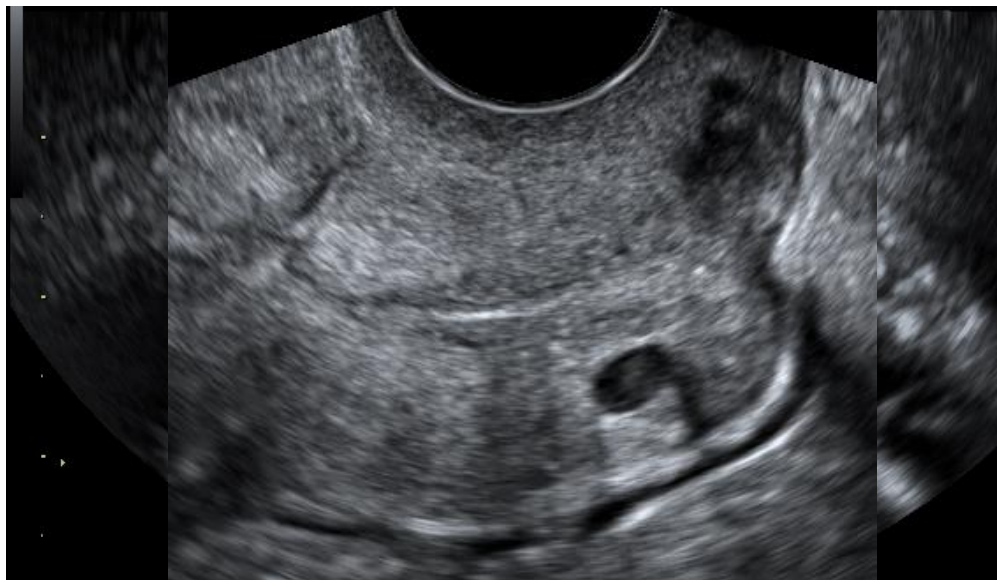Examination technique

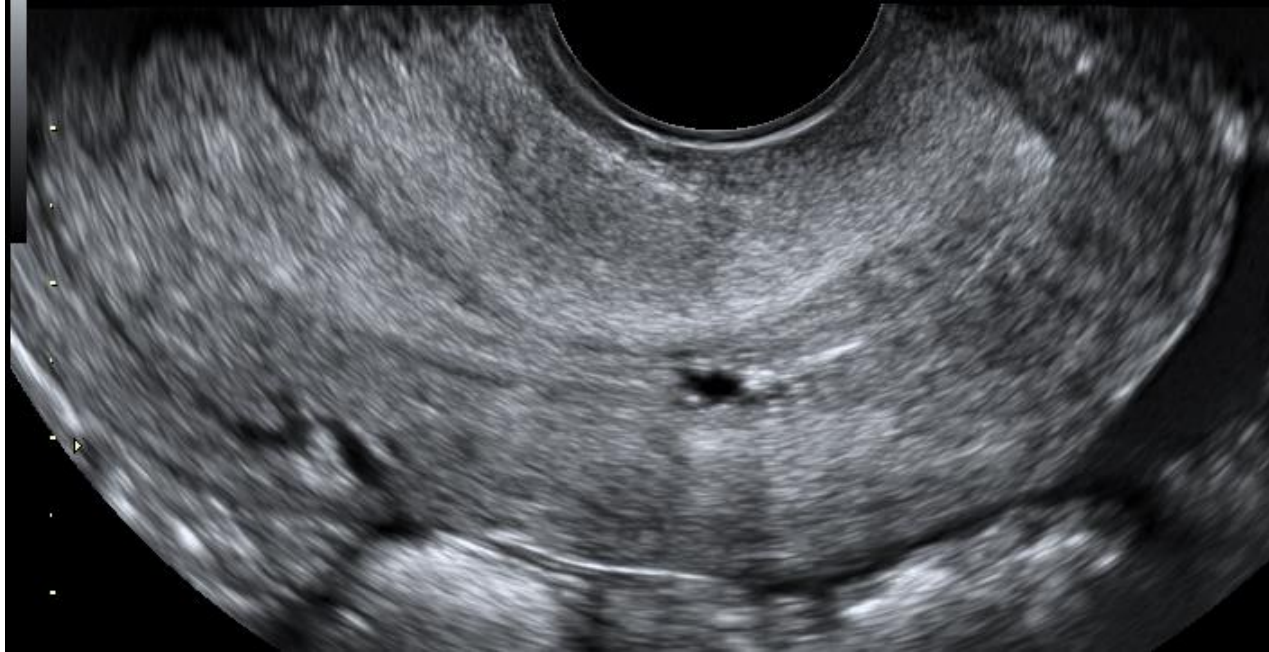
Systematic examination technique

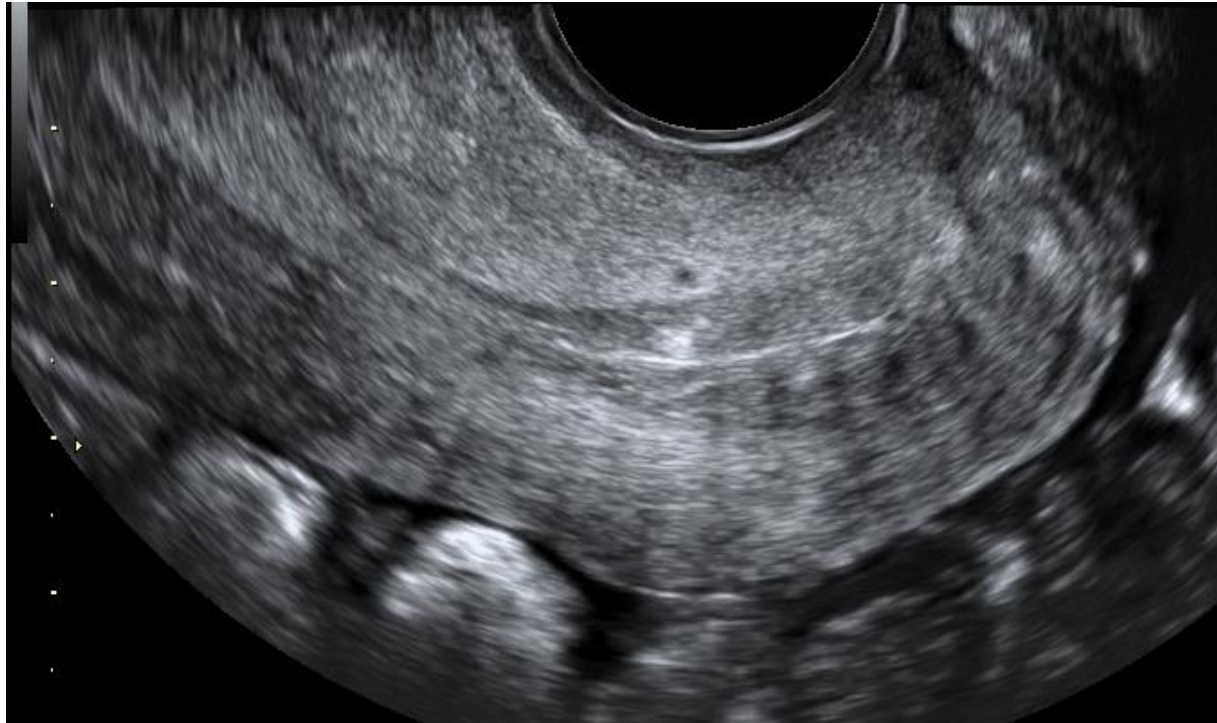ALWAYS THE SAME PROCEDURE

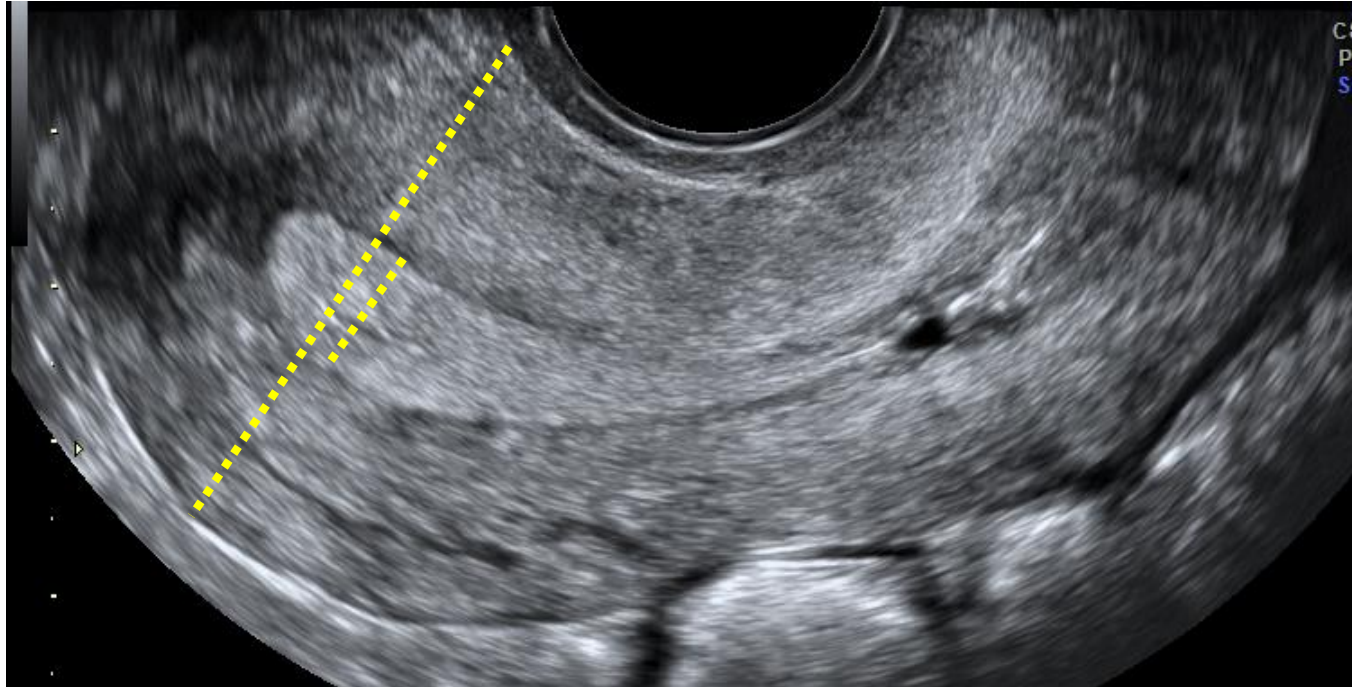
Vaginal scan

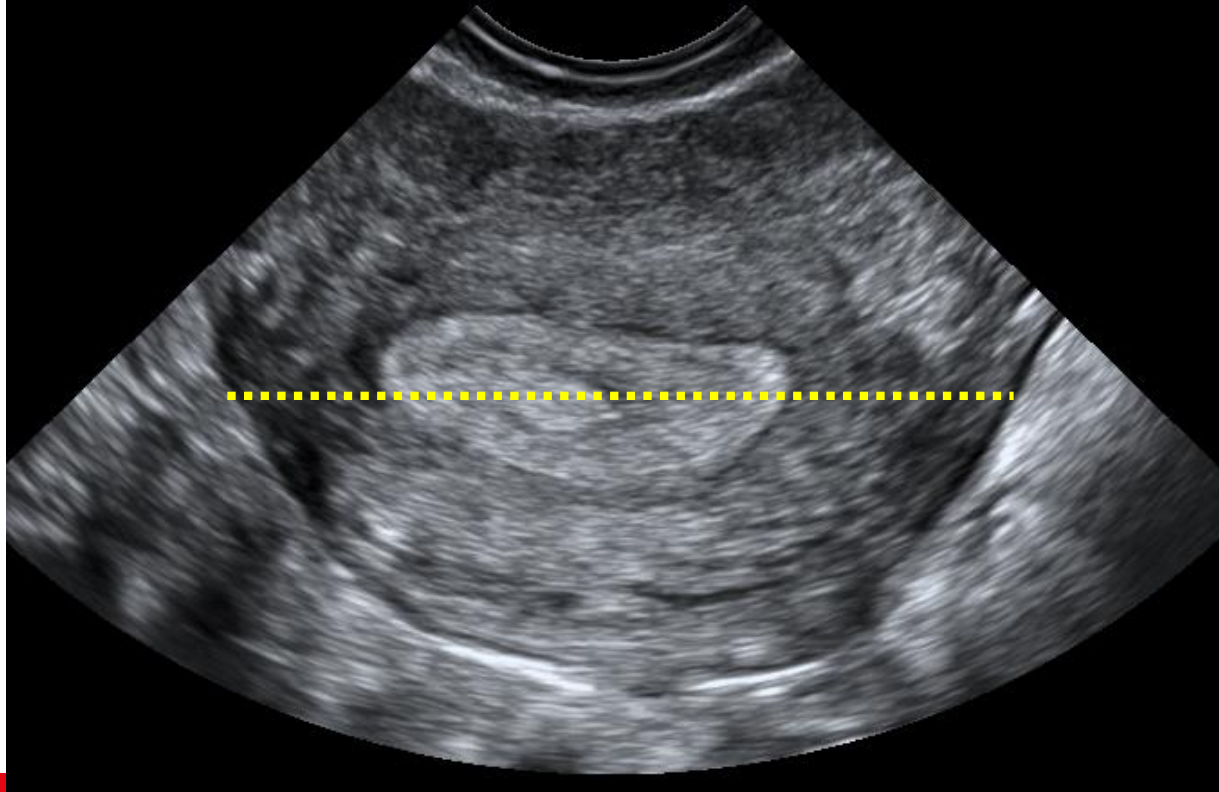




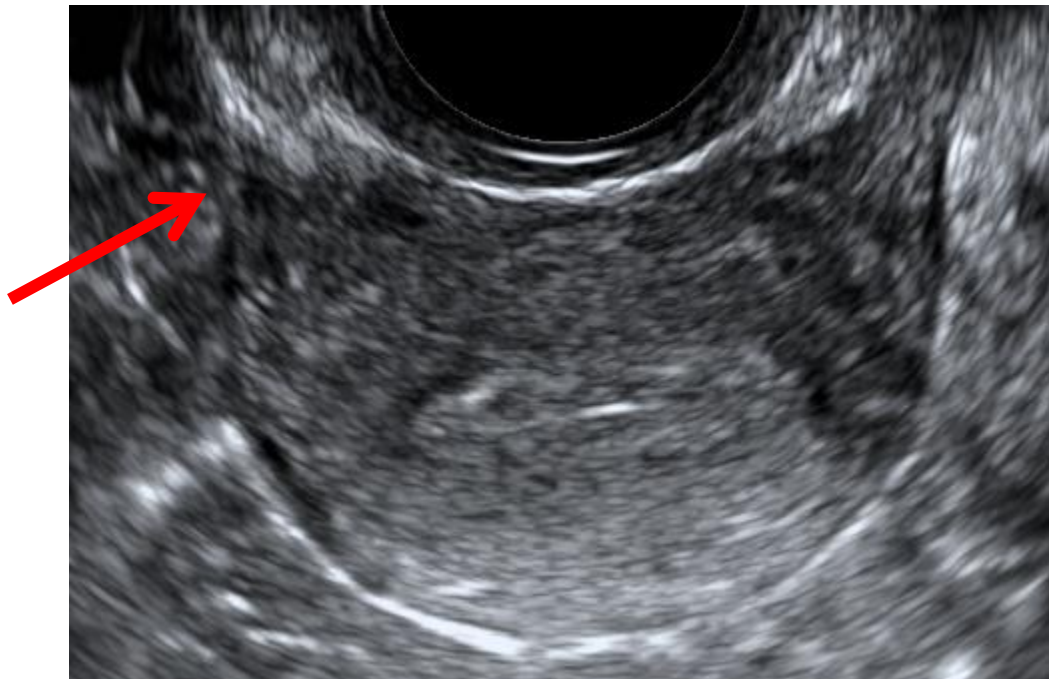

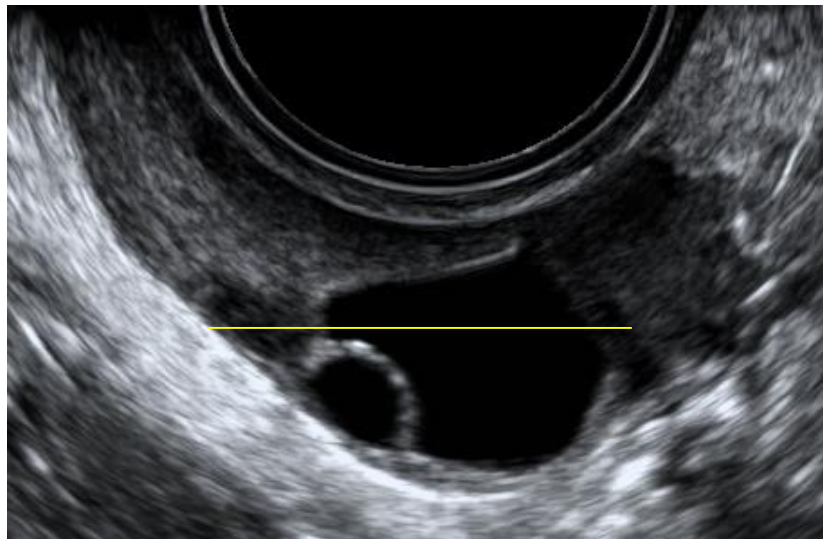


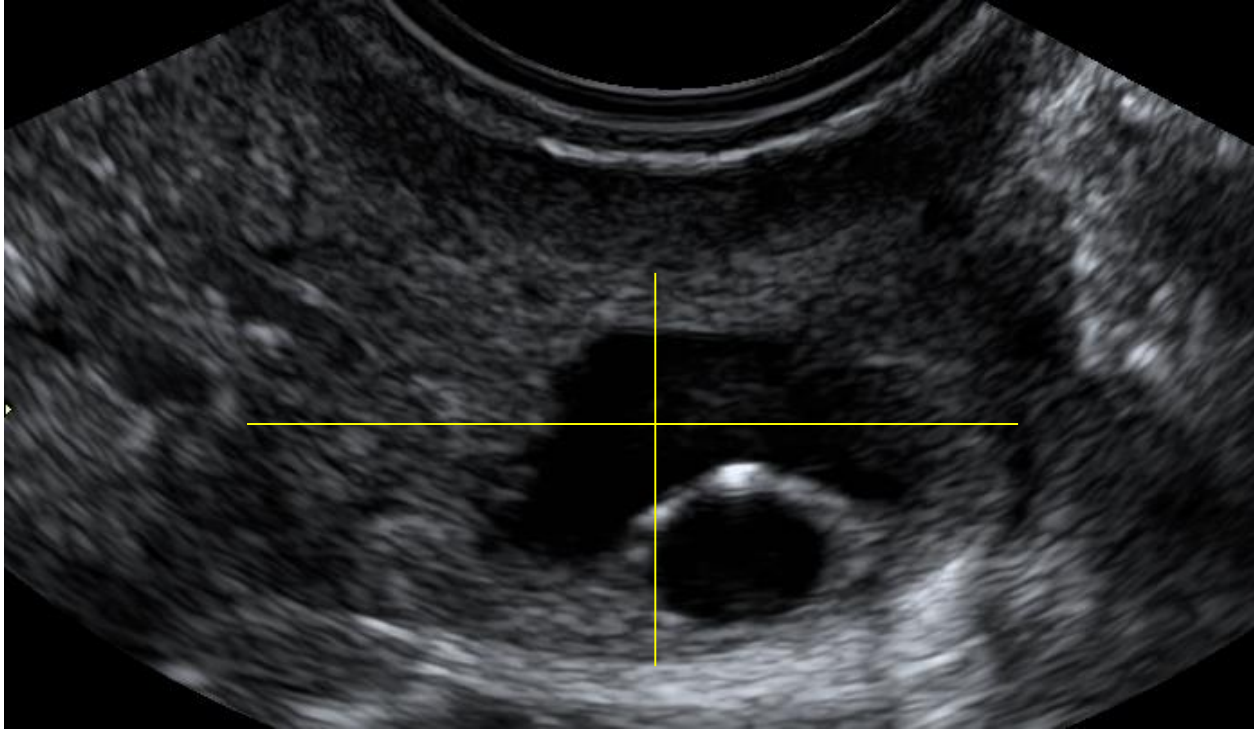



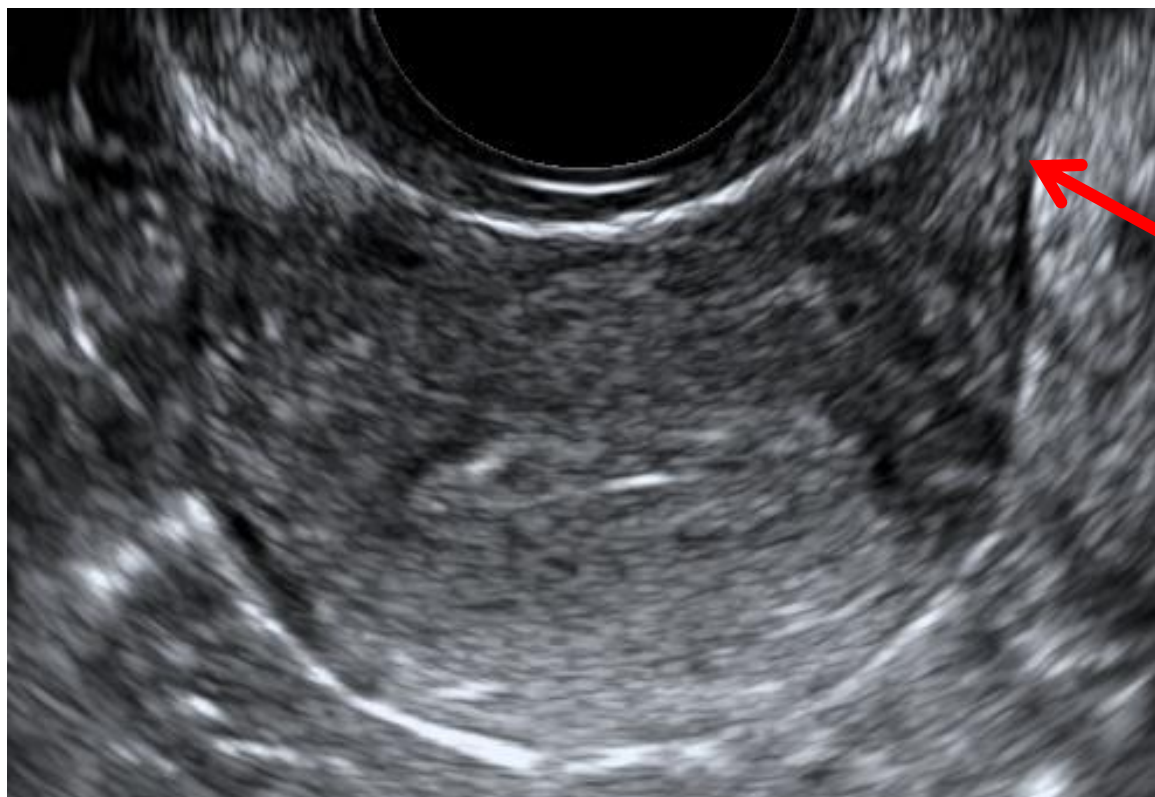
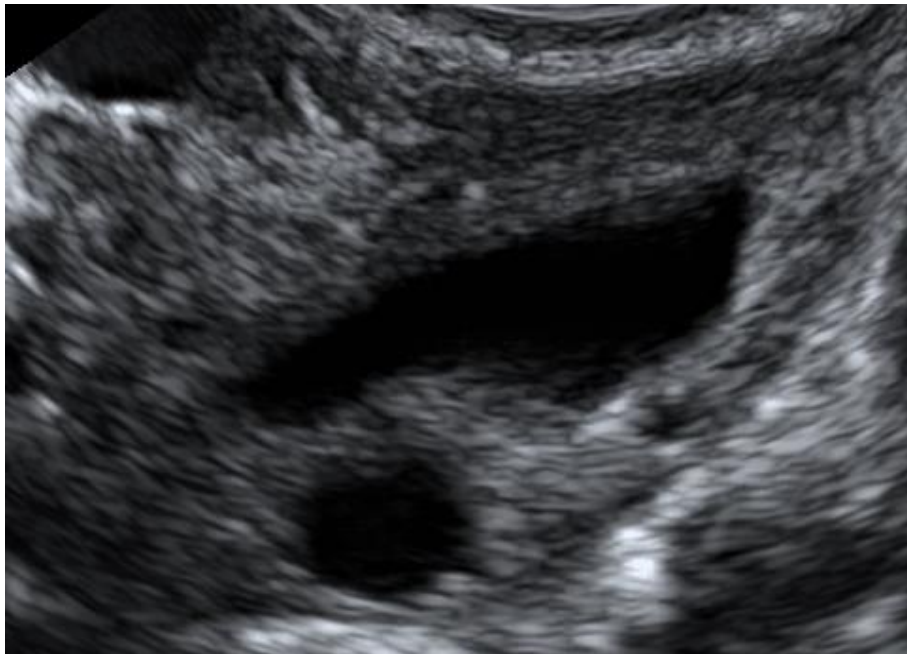
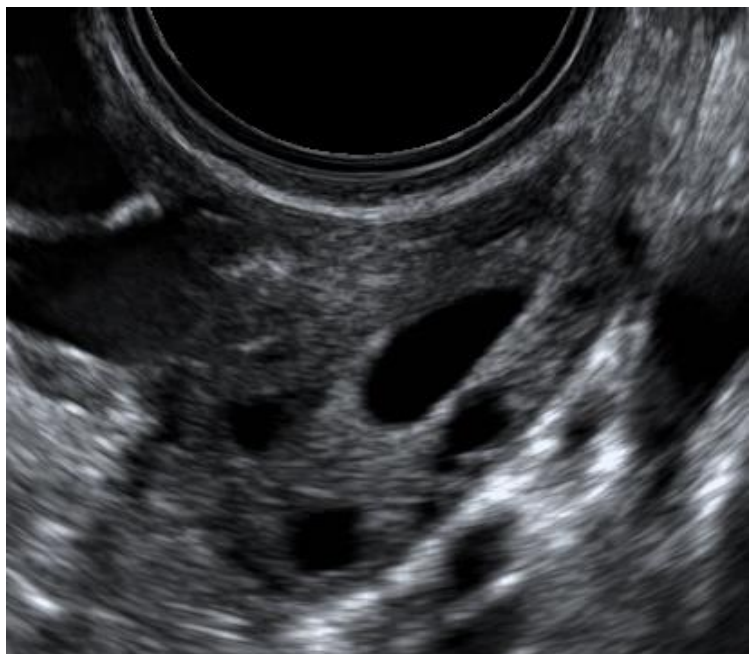
Finding the ovaries

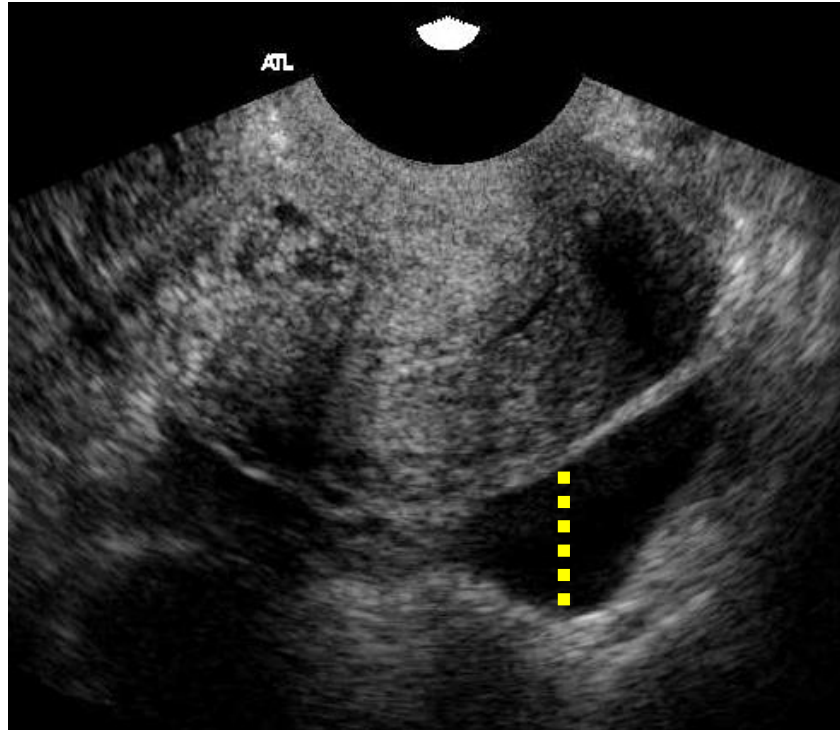




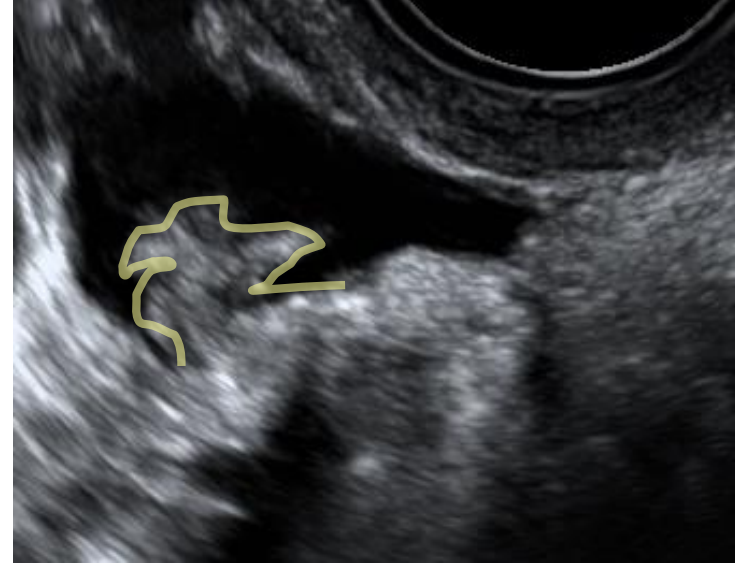
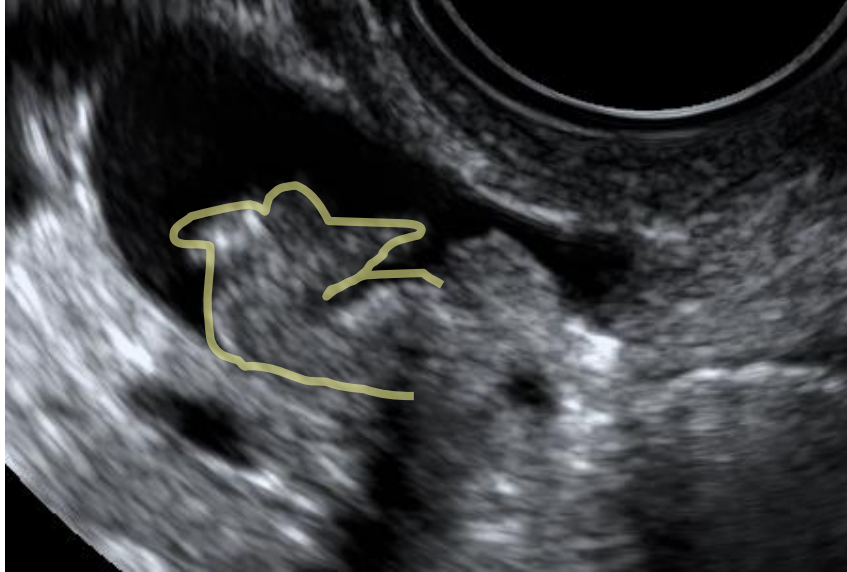




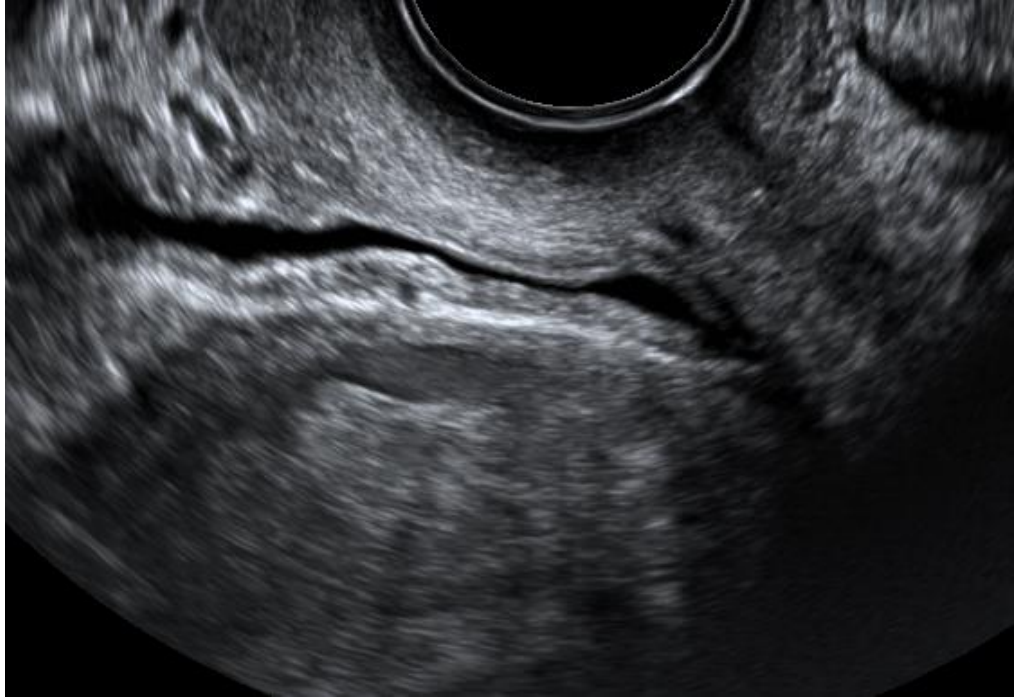



Normal tubes may be seen if there is fluid in the pouch of Douglas



Urinary Bladder



Vaginal ultrasound is a dynamic and interactive examination

- Check the mobility of organs
 - Fixed organs = adhesions
- Check for site specific tenderness
 - Which organs are involved in a painful process?

Abdominal scan

Abdominal scan

Full bladder?

**YES, if primary scan
(NO), if supplementary
scan**

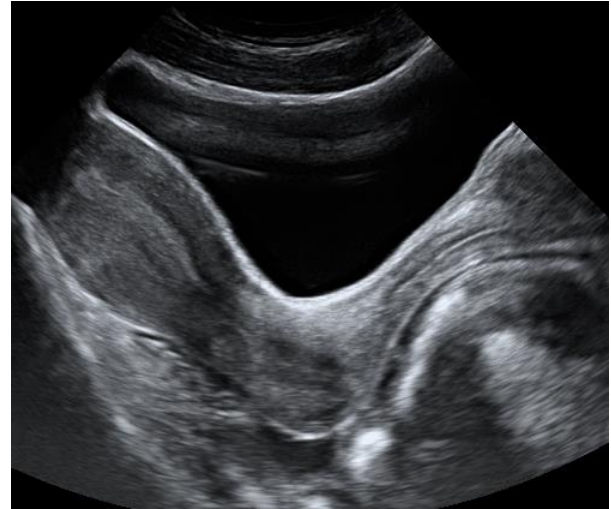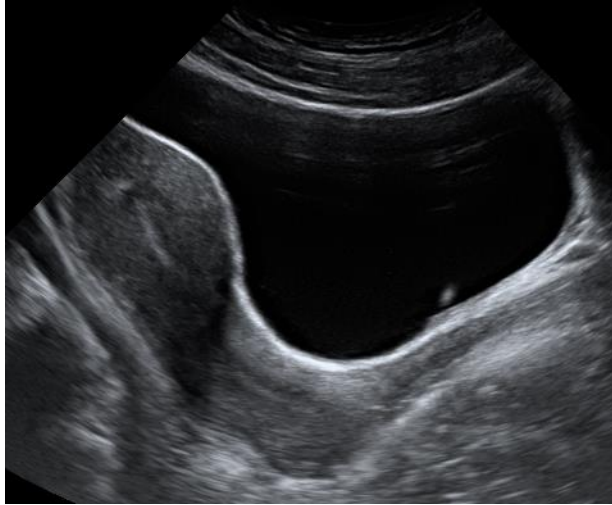
Gynecological ultrasound Examination technique

Systematic examination technique

ALWAYS THE SAME PROCEDURE

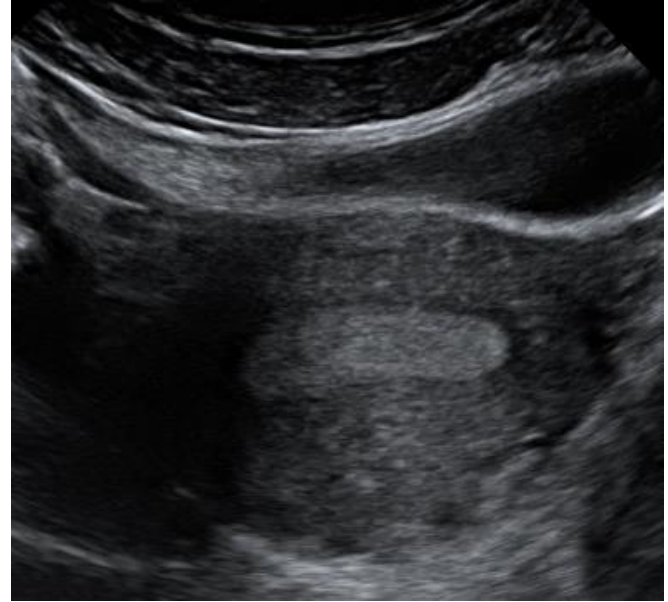
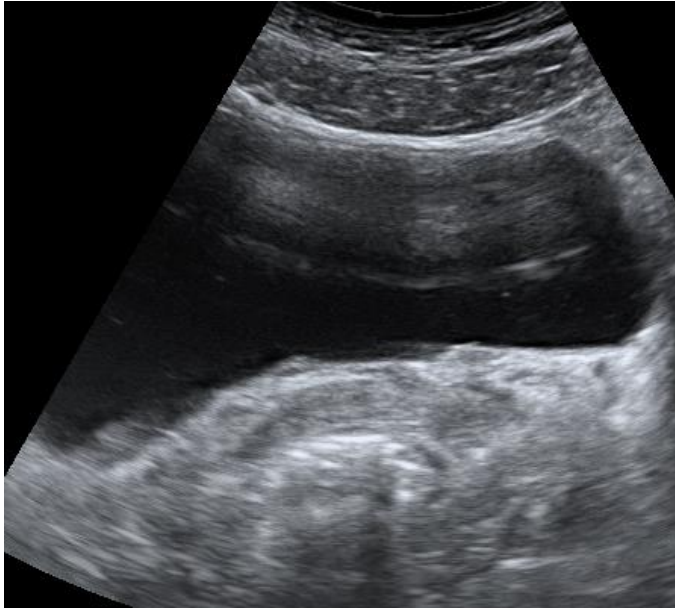
Abdominal ultrasound

Sagittal scan of the uterus

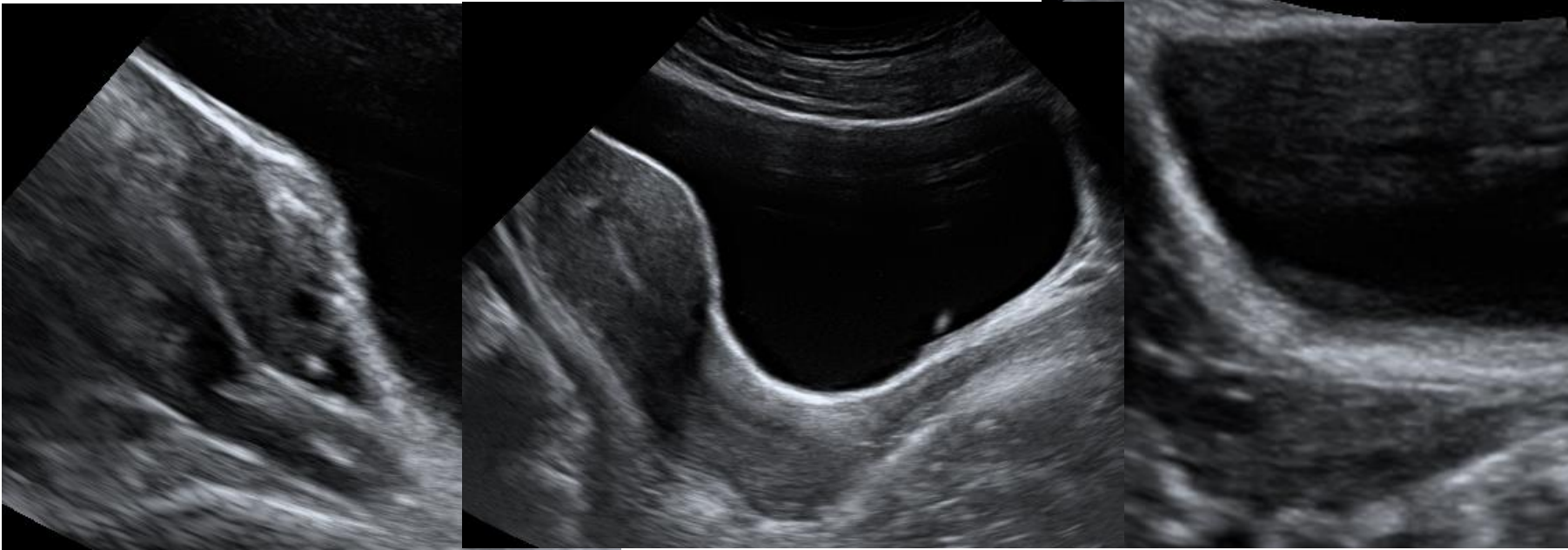


Abdominal scan

Transverse scan through the uterus



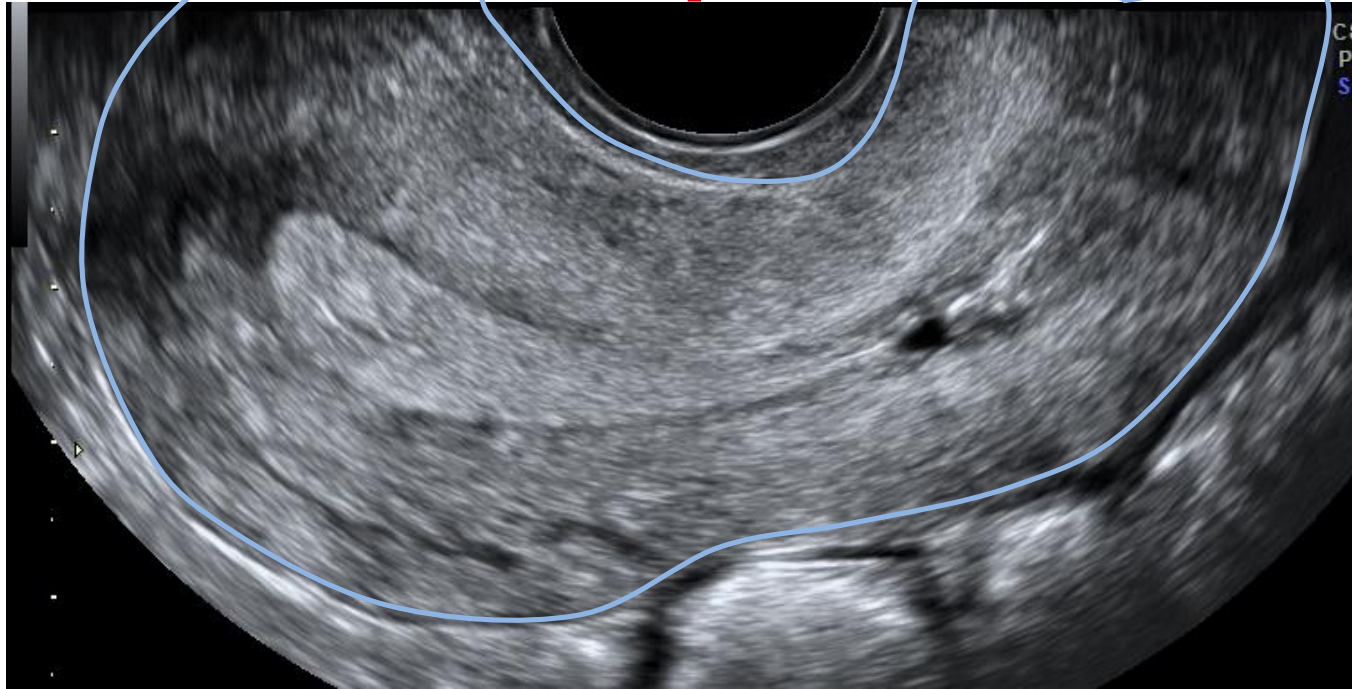
Abdominal scan - finding the ovaries



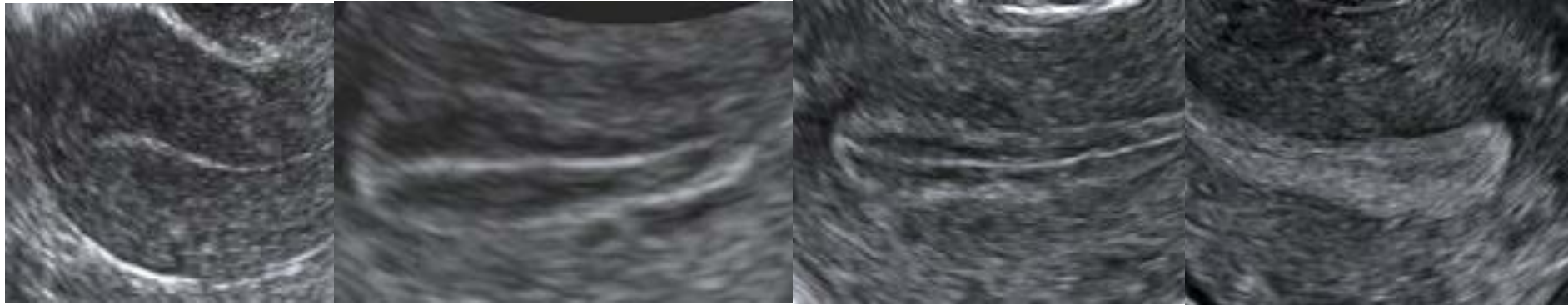
Normal ultrasound findings

- Differ between women before and after menopause
- Change throughout the menstrual cycle

Normal myometrium before menopause



The endometrium changes throughout the menstrual cycle



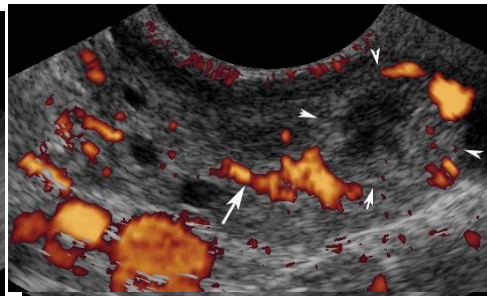
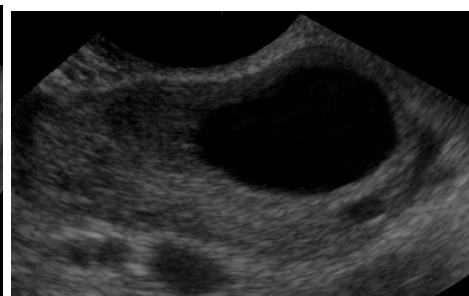
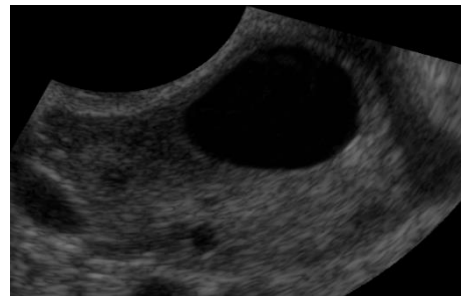
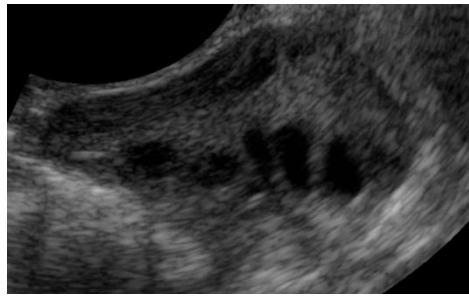
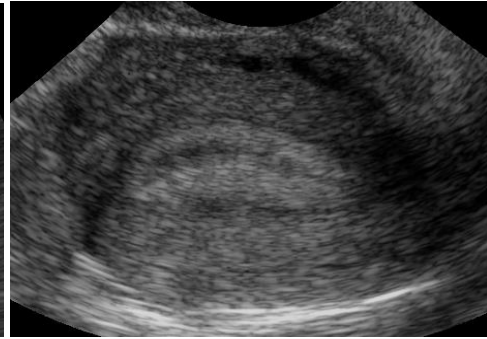
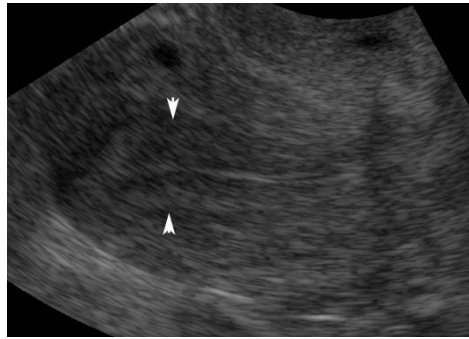
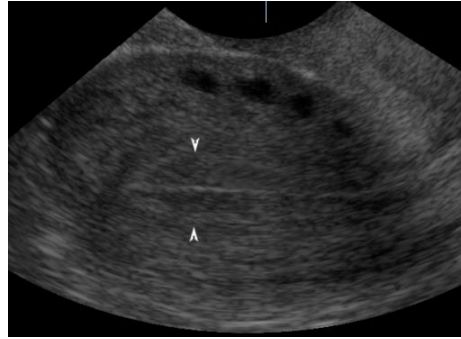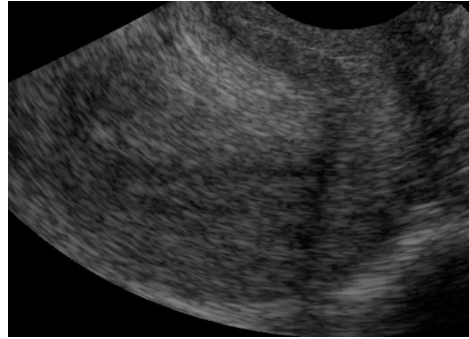Shortly after
menstruation

Proliferative phase

Proliferative phase

Secretory phase

Changes during menstrual cycle



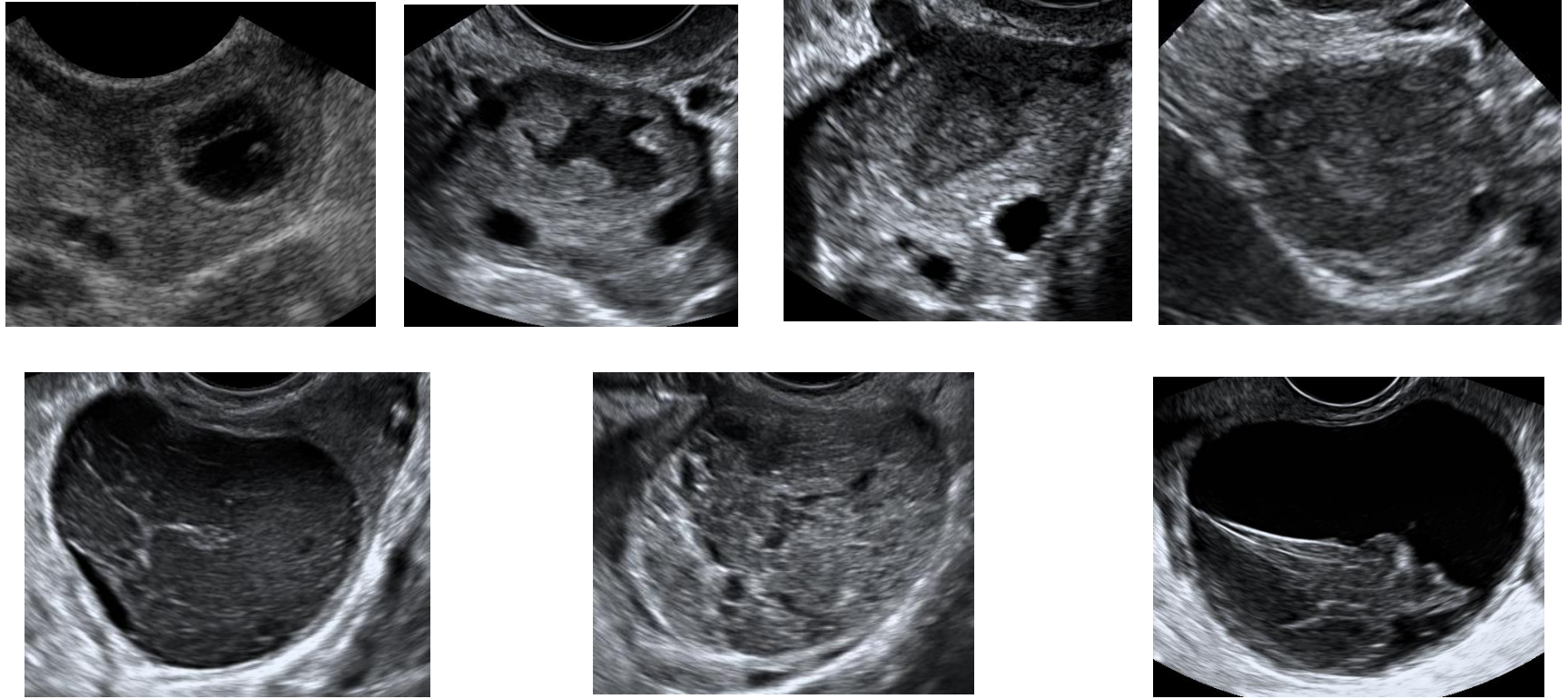
Shortly after
menstruation

Proliferative phase
3 days before ovulation

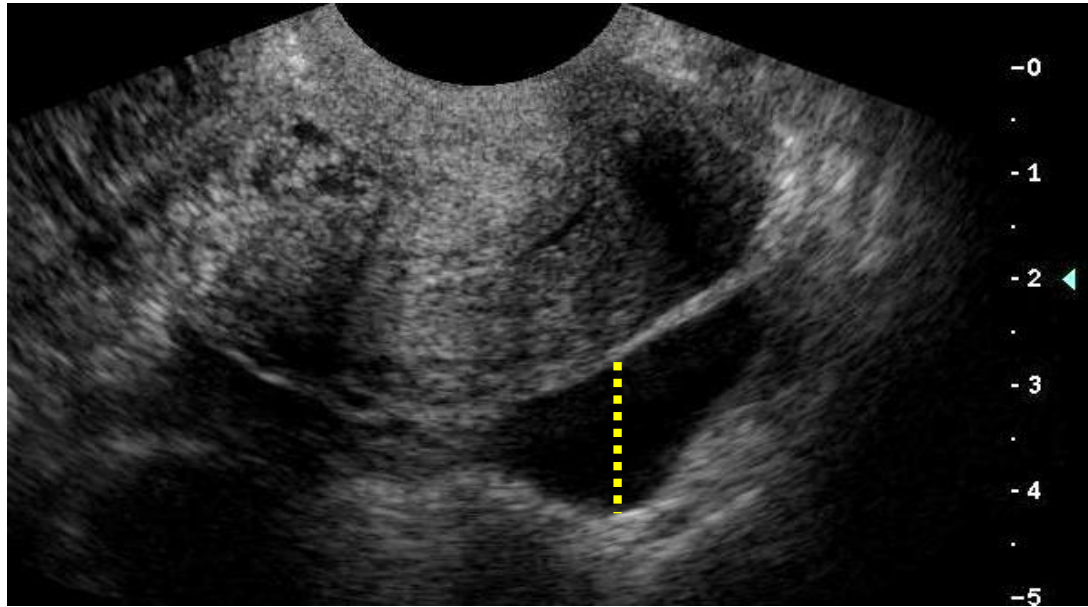
Proliferative phase
1 day before ovulation

Secretory phase
6 days after ovulation

A corpus luteum may look different



Some fluid in the pouch of Douglas is **NORMAL** before menopause



How big is a normal ovary in a woman of fertile age?

Very variable

- **Median 7 ml**
- **Range 2-17 ml**
- **(Range 1-20 ml)**

303 women 20-39 years old with regular menstrual cycles, cd 4-8

What is a normal number of antral follicles before menopause?

Text books

6-7 follicles/ovary

Jokubkiene et al

Median 11 follicles (2-10 mm)

/ovary

Range 1-36

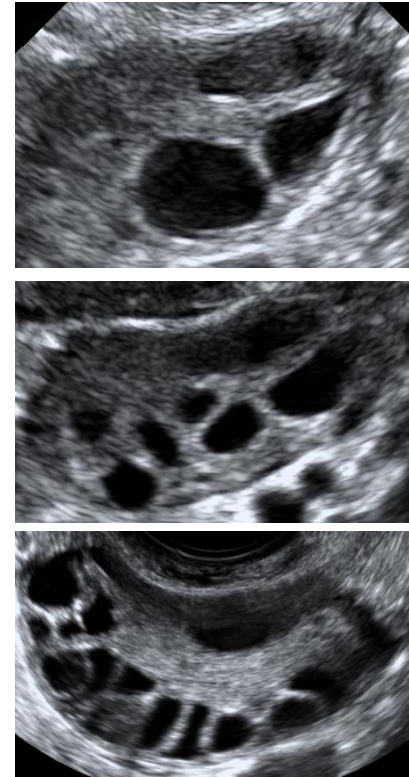
10th-90th percentile 4-20

57% had

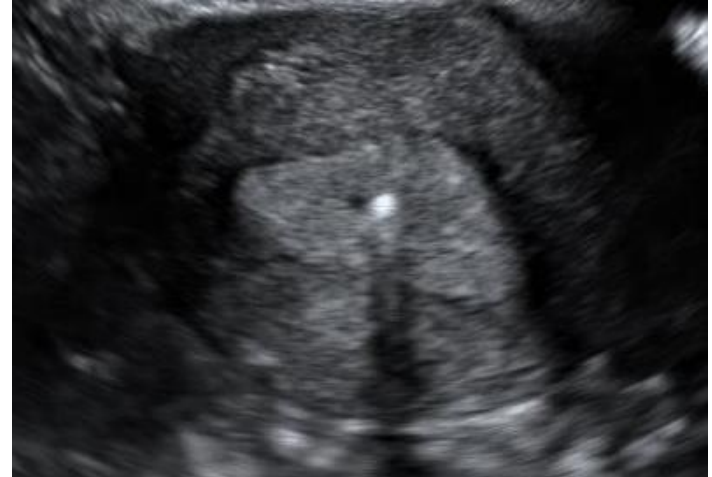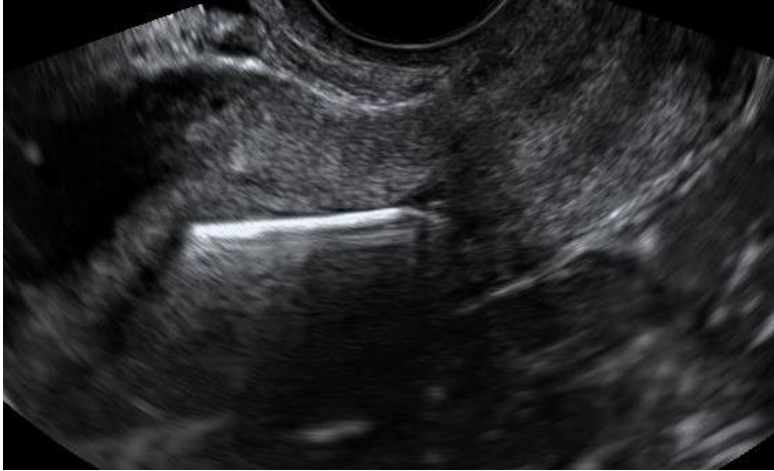≥ 12 follicles/ovary, i.e. PCO*

***PCO : ≥ 12 follicles/ovary**

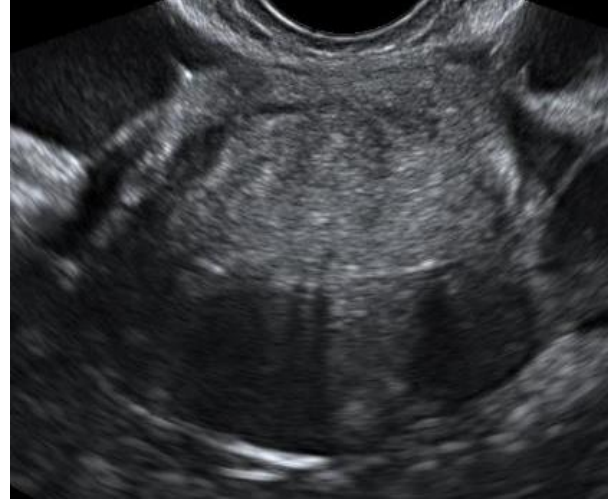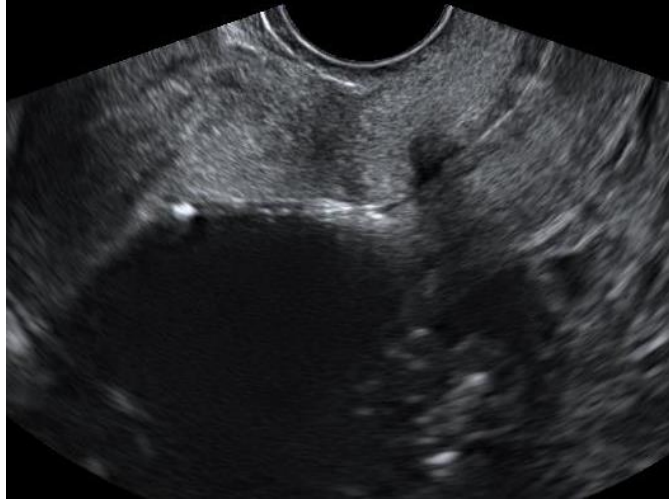or ovary ≥ 10 ml (Rotterdam)



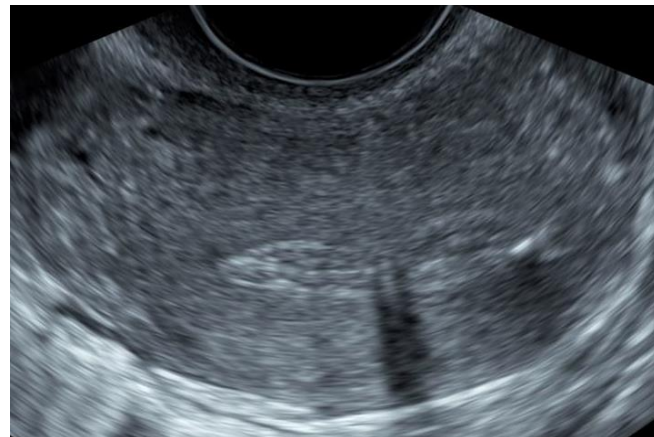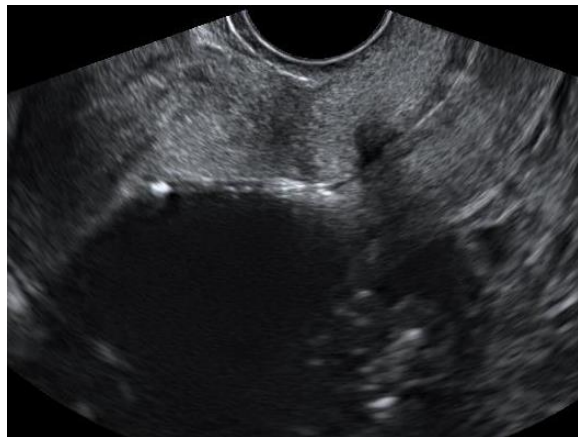Correct position of copper IUD



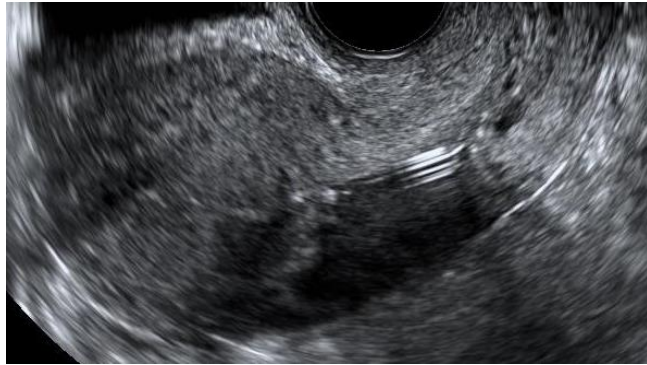
Correct position of gestagen IUD



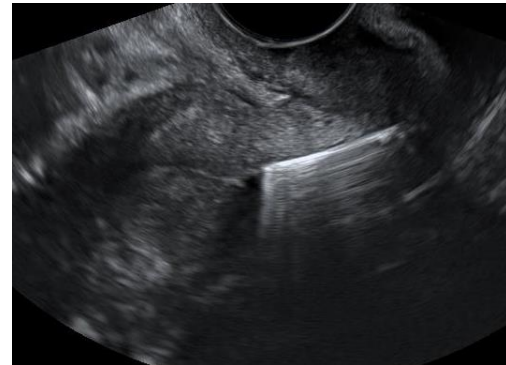
Correct position of gestagen IUD



Incorrect position of IUD

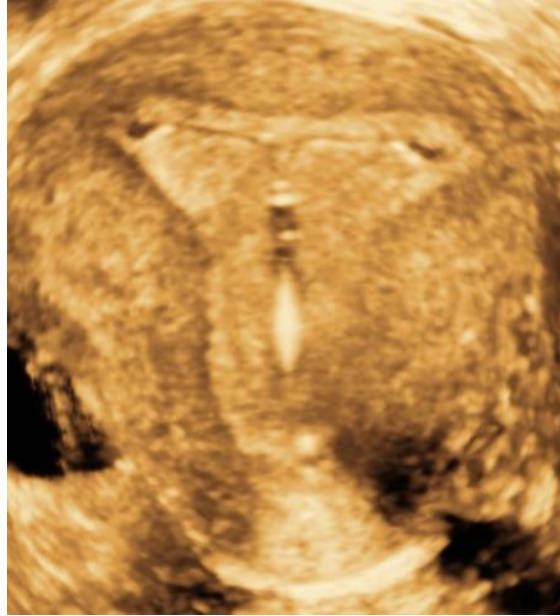

Too low

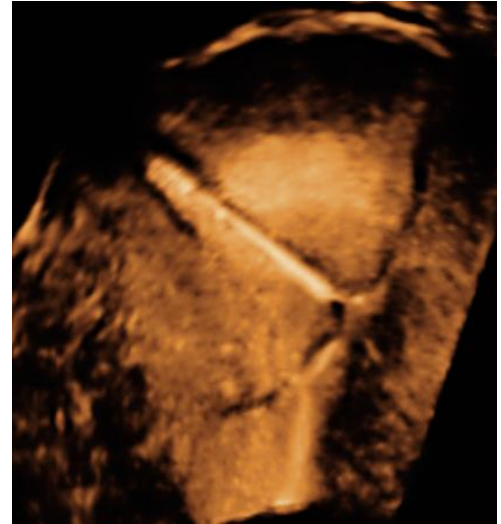
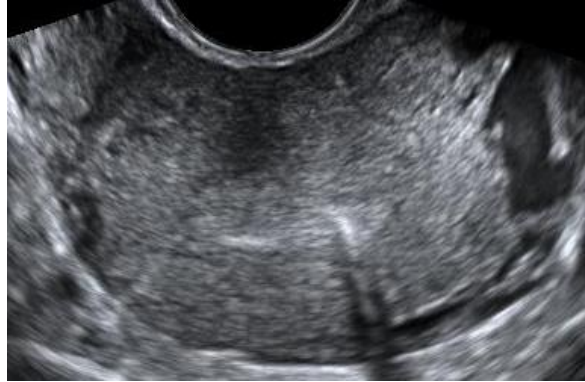
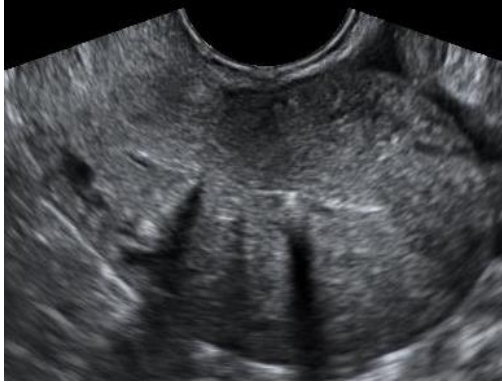Too low

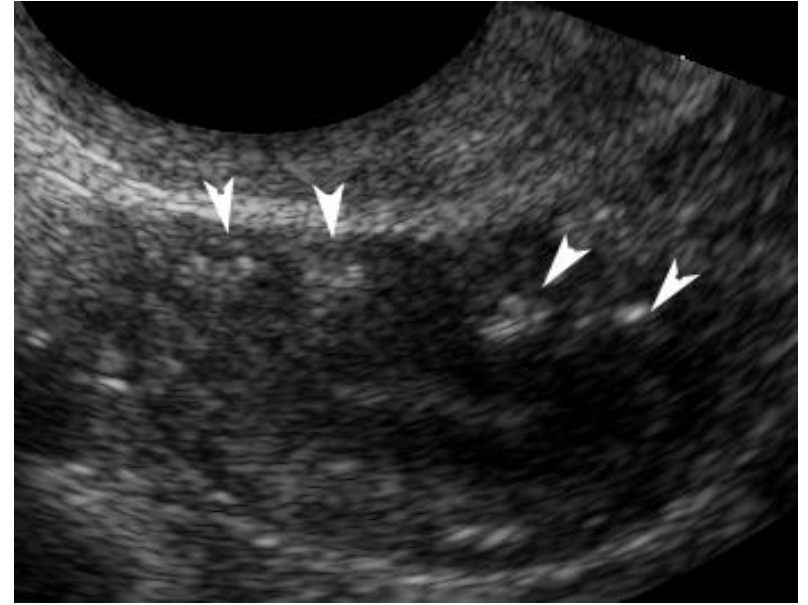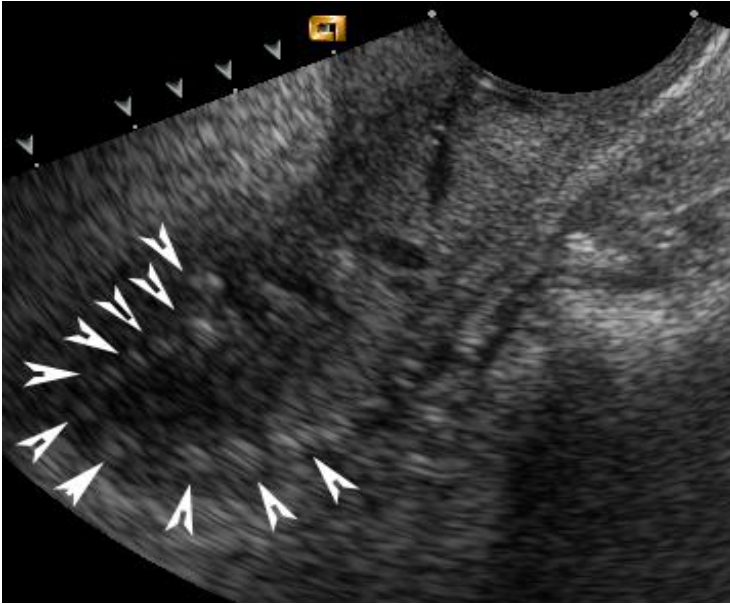
Three-dimensional (3D)ultrasound



Incorrect position of IUD

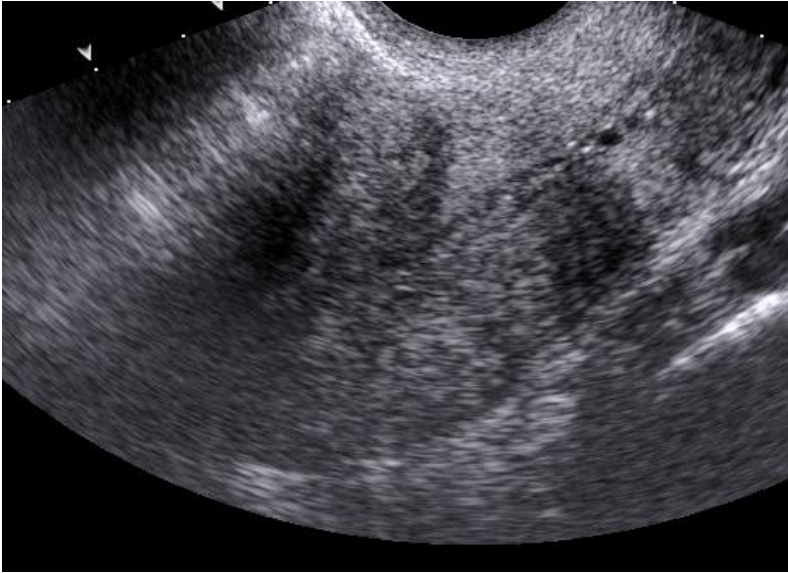

Normal ultrasound findings in postmenopausal women



Uterus with calcifications

The endometrium in postmenopausal women

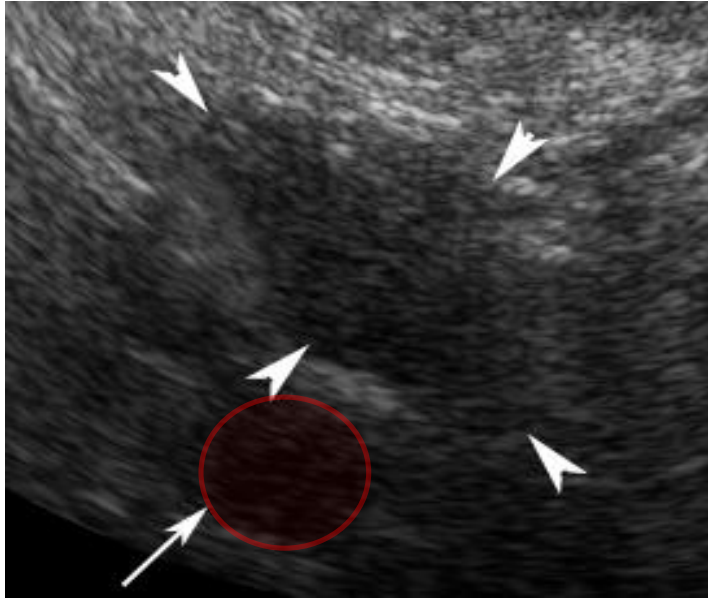


Uterus

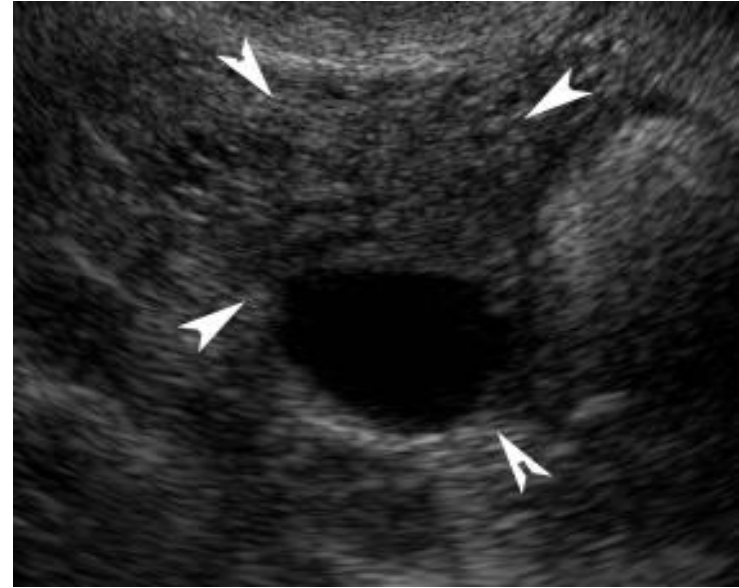**Median endometrial thickness 3 mm
10th and 90th percentile: 2 – 5 mm**

**Endometrium >5 mm is
NOT necessarily pathological**

Normal ultrasound findings in postmenopausal women



Ovary



Ovary with "cyst"

How big is a normal ovary in a postmenopausal woman?

- **Median 1x1x2 cm**
- **Median volume 1 ml**
 - **range: 0.4 - 4 ml**

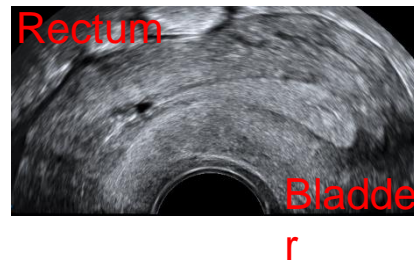
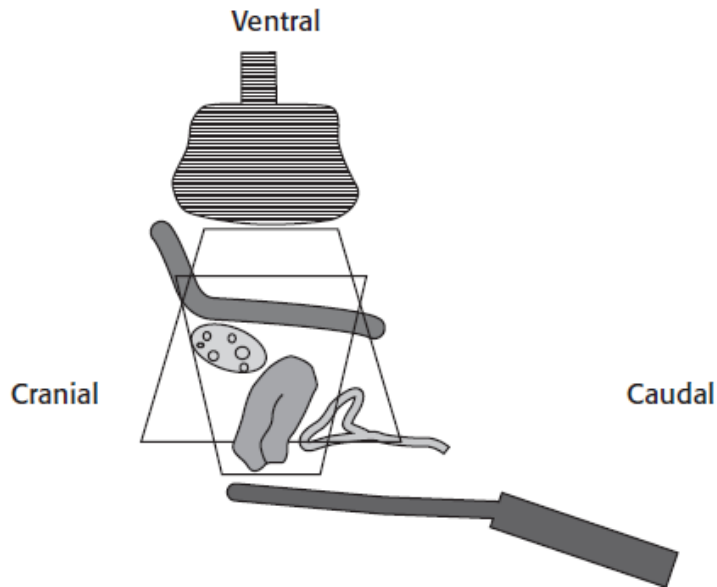
144 asymptomatic postmenopausal women 45 to 64 years old

Key points

THE BASIS for gynecological ultrasound

- **Orientate yourself in the image**
- **Optimize your image**
- **Always use a systematic scanning technique**
 - From here you move on by practising, reading books and articles, and attending more advanced ultrasound courses

Argument for showing vaginal longitudinal scans with footprint down and bladder to the right





ISUOG Basic Training by [ISUOG](https://www.isuog.org) is licensed under a [Creative Commons Attribution-NonCommercial-NoDerivatives 4.0 International License](https://creativecommons.org/licenses/by-nc-nd/4.0/).

Based on a work at <https://www.isuog.org/education/basic-training.html>.

Permissions beyond the scope of this license may be available at <https://www.isuog.org/>