



## 20th World Congress on Ultrasound in Obstetrics and Gynecology

10–14 October 2010  
Prague, Czech Republic

# Final Program

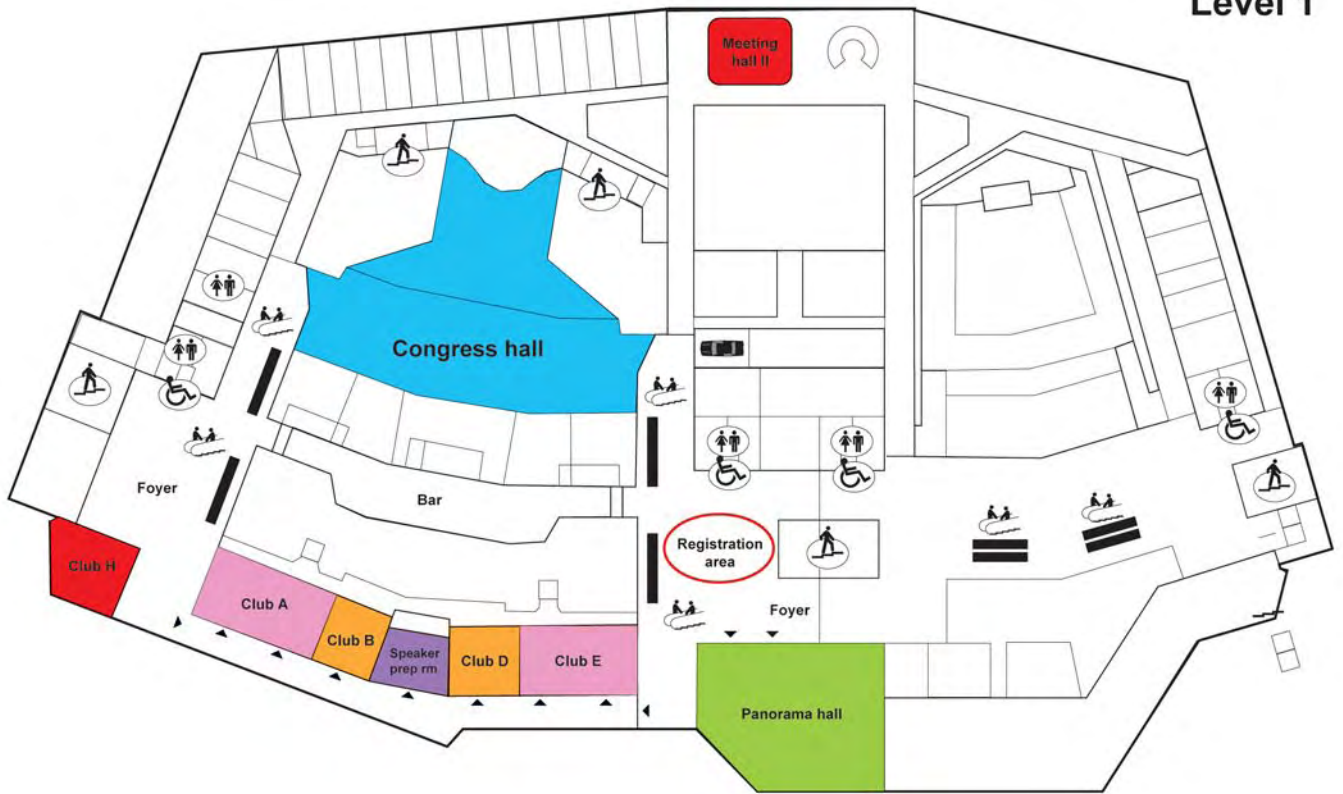
24 European CME credits (ECMEC)

Organised by: The International  
Society of Ultrasound in  
Obstetrics and Gynecology  
E: [congress@isuog.org](mailto:congress@isuog.org)  
T: +44 (0)20 7471 9955

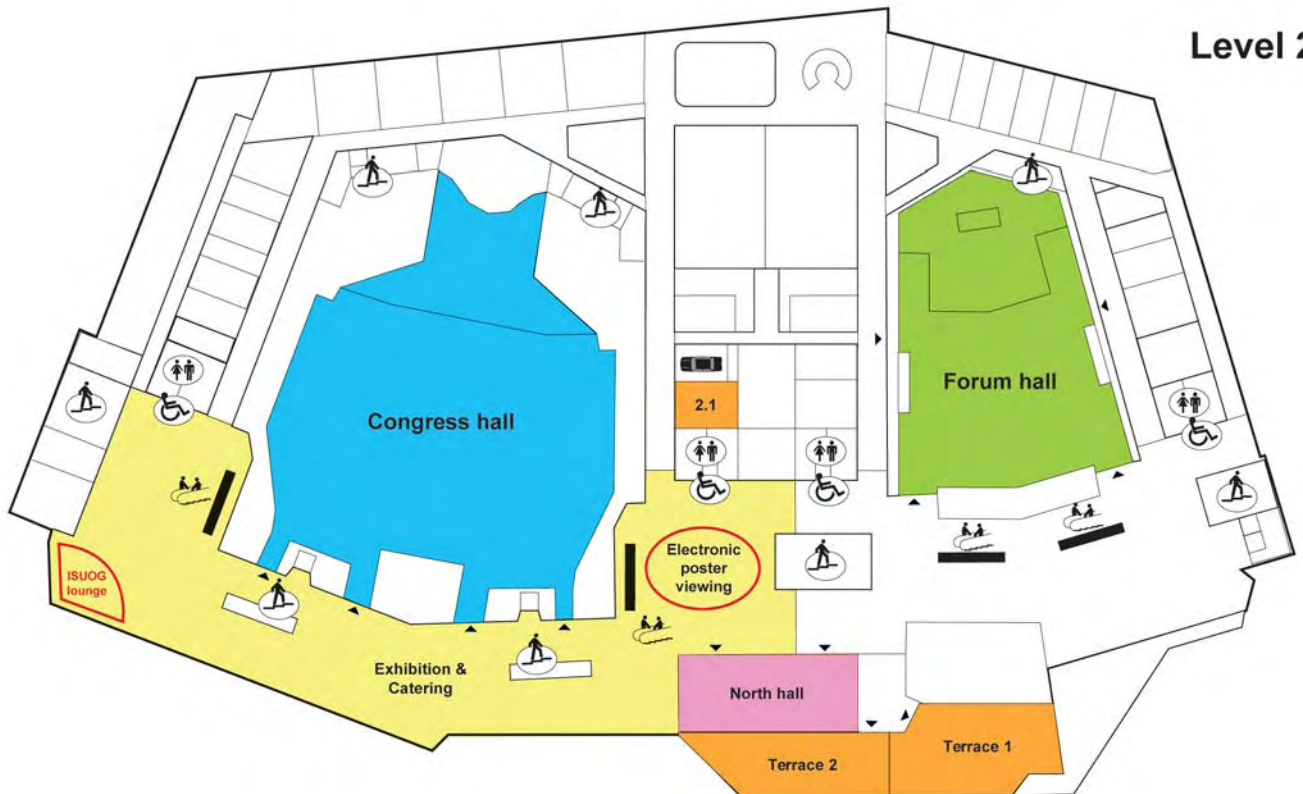
 **isuog**.org

# Venue floor plans

Level 1



Level 2



Entrance to the Prague Congress Centre is on Level 0, Door 4



\* Courses, workshops, OP's, 'All you want to know' sessions

## Organising Committees

### ISUOG President

- G. Pilu, Italy

### Congress Chairs

- P. Calda, Czech Republic
- K. Maršál, Sweden

### Local Organising Committee, Czech Republic

- M. Břešťák
- L. Krofta
- K. Švabík
- V. Tomek
- R. Vlček

### Local Advisory Board, Czech Republic

- E. Čech
- D. Cibula
- P. Eliáš
- D. Fischerová
- K. Hodík
- J. Marek
- J. Mašata
- J. Šantavý
- D. Smetanová
- J. Sonek
- P. Vlašín
- Z. Žižka

### ISUOG Meeting Planning Committee

- A. Gagnon, Canada (Chair)
- A. Baschat, USA
- P. Calda, Czech Republic
- J. Copel, USA
- K. Hecher, Germany
- T. Lau, China
- K. Maršál, Sweden
- G. Pilu, Italy
- L. Platt, USA
- A. Tabor, Denmark
- G. Yeo, Singapore

### Scientific Committee

- A. Baschat, USA (Chair)
- B. Benacerraf, USA
- C. Bilardo, Netherlands
- T. Bourne, UK
- D. Fischerova, Czech Republic
- E. Gratacós, Spain
- A. Papageorgiou, UK
- S. Yagel, Israel

### ISUOG Secretariat, UK

- S. Johnson, UK
- D. Long, Event Manager

### Contact

Unit 4 Blythe Mews,  
Blythe Road,  
London W14 0HW  
T: +44 (0)20 7471 9955  
F: +44 (0)20 7471 9959  
E: [info@isuog.org](mailto:info@isuog.org)  
W: [www.isuog.org](http://www.isuog.org)

# Welcome message

It is a pleasure and honour for us to celebrate ISUOG's milestone 20th World Congress on Ultrasound in Obstetrics and Gynecology here in Prague. The Scientific Committee is proud to offer you an exciting scientific program incorporating more than 1000 accepted abstracts and a modified format to reflect the lively continuing scientific discussion and co-operation amongst ISUOG members.


The main scientific program is expanding this year to include three parallel sessions, with debates and live scan demonstrations by leading world experts incorporated. The educational content of the program is further enhanced this year with special interest workshops taking place every day covering subspecialty areas and our expanded 'All you want to know' program. A state-of-the-art 'OnDemand Portal' will be launched at the Congress, giving you the opportunity to view webcasts of lectures the day after they have taken place. These will also be available online after the Congress, via the ISUOG website. We envisage that this will make more elements of the scientific program available to ISUOG members across the globe, as well as allowing you to 'catch-up' on any sessions you may have missed. Electronic and short oral presentations (oral posters) will be displayed throughout the Congress on E-poster stations, so you can view these during program breaks, as well as attending question and answer sessions with authors.

In addition to the scientific program, there are many opportunities to discover the beauties of Prague, and the nearby attractions such as Český Krumlov or Kutná Hora. The Congress party on Tuesday 12 October will be held in the unique and aristocratic atmosphere of the Žofín Palace, situated in central Prague, on an island in the river Vltava, where you can enjoy a seated buffet dinner and dancing into the night. Also, do not miss a special performance by Prague's famous Black Light Theatre, as part of our opening ceremony on Sunday.

We would like to take this opportunity to thank you for your enthusiasm in preparing your scientific contributions and for your support of the 2010 Congress. On behalf of ISUOG, and the Scientific Committee, we are honoured to welcome you all to the heart of Europe; destination Prague, and will do our best to make your stay memorable.



Pavel Calda  
Congress Chair



Karel Maršál  
Congress Chair

# Contents

<b>Critical dates and times</b>	2
<b>Social program</b>	2
<b>Program (general)</b>	
Chairperson, speaker and poster presenter guidelines	4
Invited speaker and free communication presenter declarations	5
Program orientation	6
CME accreditation	6
Program at a glance	8
Short oral presentations (oral posters) at a glance	10
'All you ever wanted to know' sessions at a glance	11
<b>Program (in detail)</b>	
Pre-Congress courses – Sunday 10 October 2010	13
Special lecture biographies	14
Program – Sunday 10 October 2010	15
Program – Monday 11 October 2010	17
Short oral presentations (oral posters) – Monday 11 October 2010	24
Electronic posters – Monday 11 October 2010	28
Program – Tuesday 12 October 2010	34
Short oral presentations (oral posters) – Tuesday 12 October 2010	42
Electronic posters – Tuesday 12 October 2010	46
Program – Wednesday 13 October 2010	52
Short oral presentations (oral posters) – Wednesday 13 October 2010	58
Electronic posters – Wednesday 13 October 2010	62
Program – Thursday 14 October 2010	67
Short oral presentations (oral posters) – Thursday 14 October 2010	70
Electronic posters – Thursday 14 October 2010	74
<b>Industry</b>	
Sponsors' activities	78
Exhibition floor plan and list of exhibitors	81
Exhibitor profiles	82
<b>ISUOG committee meetings</b>	88
<b>General information</b>	Inside back

# Critical dates and times

## Registration opening hours

Sunday 10 October 2010	07:00–20:00
Monday 11 October 2010	07:00–18:15
Tuesday 12 October 2010	07:15–17:30
Wednesday 13 October 2010	07:15–17:30
Thursday 14 October 2010	07:15–14:00

The registration area is located on the level 1 foyer of the centre.

## Exhibition opening hours

Sunday 10 October 2010	18:00–21:00
Monday 11 October 2010	09:00–17:00
Tuesday 12 October 2010	09:00–17:00
Wednesday 13 October 2010	09:00–17:00

The exhibition is located in the level 2 foyer of the centre

## Speakers' preparation room opening hours

Sunday 10 October 2010	07:30–17:00
Monday 11 October 2010	07:30–17:30
Tuesday 12 October 2010	07:30–17:30
Wednesday 13 October 2010	07:30–17:30
Thursday 14 October 2010	07:30–14:00

The speakers' preparation room is located in Club C on level 1 of the venue. Speakers **MUST** check in their presentation at the speakers' preparation room at least two hours prior to the commencement of the session in which they are due to present and, preferably, the day before their presentation. **Please note there will be no lap top plug in facilities** in the lecture halls. Please refer to page 4 for details.

## Scientific program hours

Please refer to the program for the exact location and timings of each session.

Sessions will take place during the following times:

Sunday 10 October 2010	14:00–17:30
<i>(followed by a performance from the Black Light Theatre and welcome reception)</i>	
Monday 11 October 2010	09:00–17:30
Tuesday 12 October 2010	09:00–17:30
Wednesday 13 October 2010	09:00–17:30
Thursday 14 October 2010	08:30–13:30

All short oral presentations (oral posters) and poster slides will be available for viewing all day on our electronic poster pods located on the second floor foyer of the PCC.

Short oral presentations (oral posters) and electronic poster Q&A will be presented in chaired discussion sessions daily at the following times –

Monday 10 October 2010	10:00–10:55 and 15:00–16:00
Tuesday 11 October	10:00–10:55 and 15:00–16:00
Wednesday 16 September 2009	10:00–10:55 and 15:00–16:00
Thursday 17 September 2009	08:30–09:25 and 11:00–11.40

## ISUOG Annual General Meeting (AGM)

All fully paid delegates are ISUOG members for 2011. Please attend the ISUOG Annual General Meeting (AGM) to find out more.

### Sunday 10 October 2010

15:40: Congress Hall, Prague Convention Centre

For details of scheduled ISUOG Committee meetings, please refer to page 88 of this brochure.

# Social program

## Welcome reception, Sunday 10 October

Please book tickets for any of the functions below at the registration desk. Tickets are subject to availability and will be offered on a first-come, first-served basis.

## Opening session and welcome reception, Sunday 10 October

All registered delegates, accompanying persons and exhibitors are invited to attend the special program starting at 16:30 in the Congress hall. Additional tickets can be purchased at the registration desk for €30 per person.

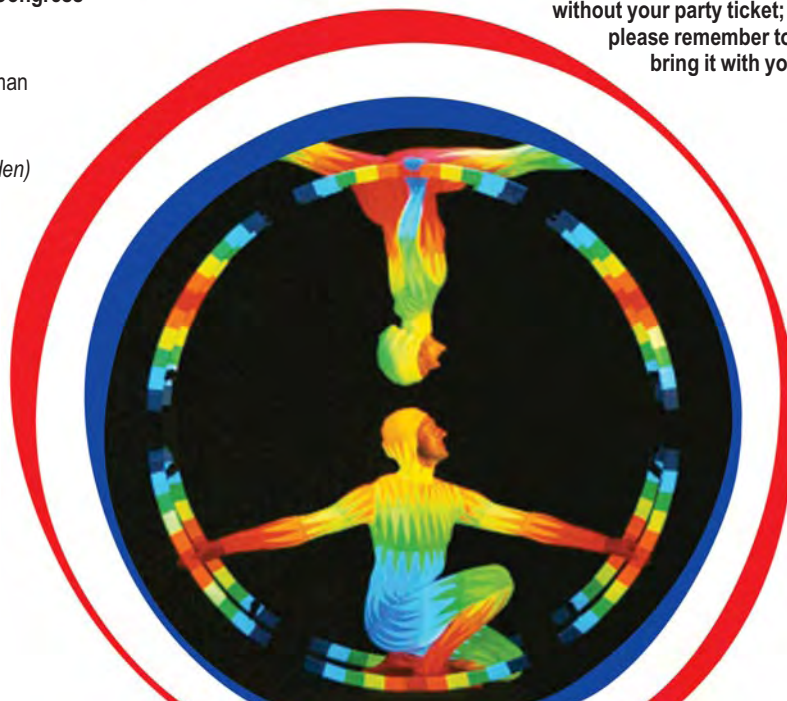**Please note you will not be allowed entry without your Congress badge or ticket.**

- 16:30 Handover of ISUOG Presidency
- 16:35 Presentation of the Gold Medal to Charles Kleinman *J. Copel (USA)*
- 16:40 Gold Medal lecture *C. Kleinman (USA)*
- 17:00 Doppler and the stars of Prague *K. Maršál (Sweden)*
- 17:20 Special lecture: Developmental stages in human embryos and morphologic sequence of human head development *J. Jirasek (Czech Republic)*
- 17:30 Interval drinks: Level 1 foyer/bar
- 18:00 **Black Light Theatre performance**  
The opening ceremony culminates in a performance of the unique Black Light Theatre company. This theatre originates in Prague and uses dance, mime and acrobatics. Don't miss a special display for ISUOG.
- 18:30 Welcome reception: Level 2 foyer and exhibition
- 21:00 Close

## Congress party, Tuesday 12 October

- Time:* 19:30–Midnight
- Venue:* Žofin Palace
- Cost per person:* €75 (includes: VAT, drinks, sit down buffet, dancing)
- Dress:* Evening attire

All delegates, exhibitors and accompanying persons are welcome to our party at the beautiful Žofin Palace, set on an island in the Vltava river. **Tickets must be purchased in advance and are available onsite at the registration desk. Places are strictly limited and are offered on a first come, first served basis. Please note you will not be allowed entry without your party ticket; please remember to bring it with you.**



# Social program

## Accompanying person's program

Cost per person: €200

The accompanying persons program includes:

- Congress Welcome Reception (Sunday 10 October)
- Admission to the Congress exhibition and catering areas
- Lonely Planet city guidebook
- A choice of the following tours:
  - **Kutná Hora:**  
Monday 11 October 2010 (full day, 8 hours)  
This full day tour leads you to this UNESCO World Heritage Site.
  - OR
  - **Křivoklát Castle and Nižbor Glassworks:**  
Tuesday 12 October 2010 (full day, 8 hours)  
This full-day tour visits the 12th century Křivoklát Castle, tucked away in pinewoods along the Berounka river valley.

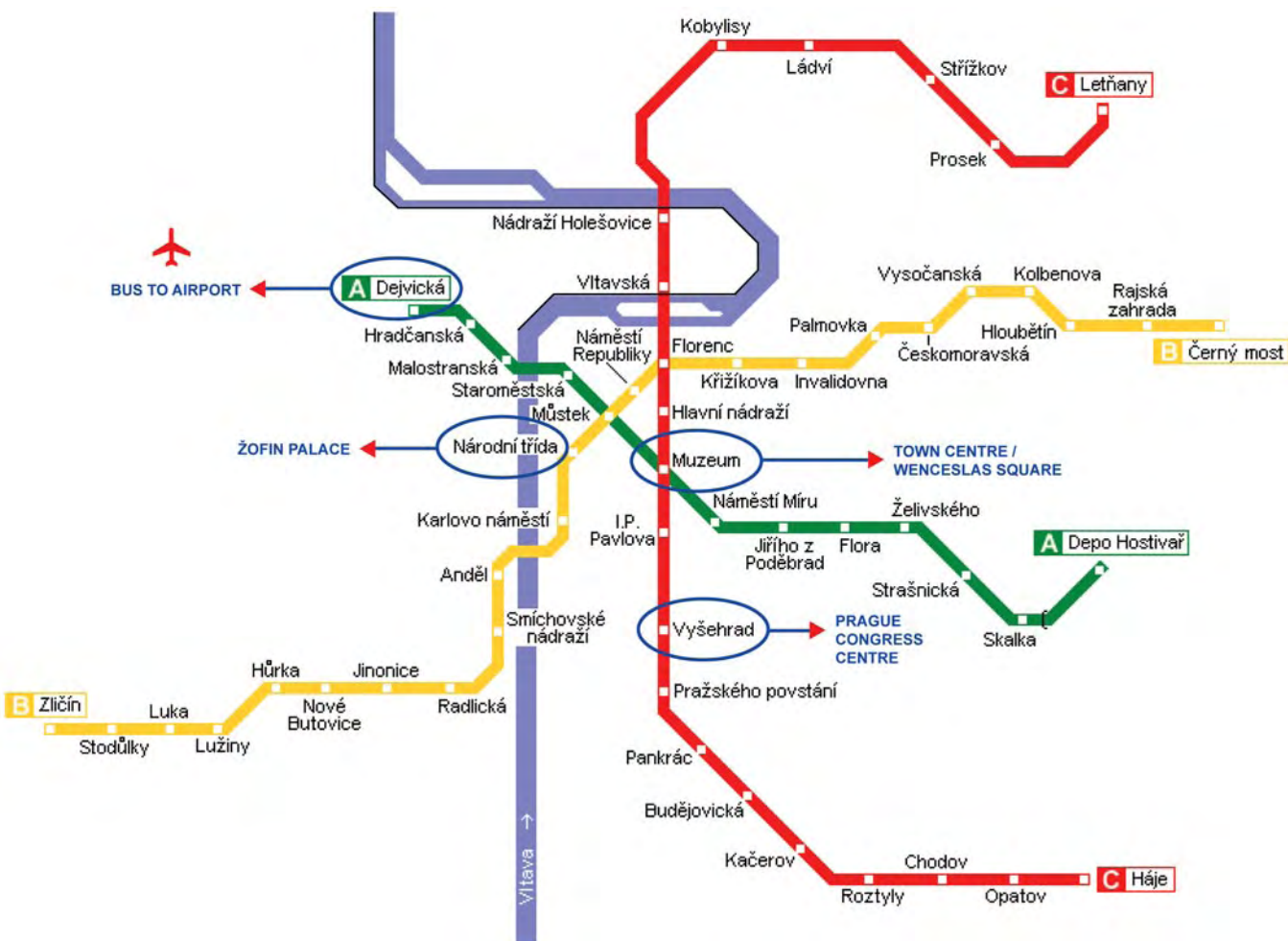
Plus two of the following tours

- **Prague informative:**  
Monday 11 October, 09:00–13:00  
OR Wednesday 13 October, 13:00–17:00  
This tour offers a general impression of the 'Golden City' by walk and visiting several important sites.
- **Prague Castle:**  
Monday 11 October, 12:00–15:00  
This half-day sightseeing tour to Prague Castle – the seat of the Czech President.

- **Scientific Prague:**  
Monday 11 October, 13:00–17:00  
This four hour walk will give you opportunity to get a brief look back at the lives of some interesting personalities from many fields of science connected to Prague.
- **Art Nouveau Prague:**  
Tuesday 12 October, 09:00–12:00  
OR Wednesday 13 October, 12:00–15:00  
This tour invites you to discover the works of the great Czech artist Alfons Mucha (1860–1939).
- **Sova's Mille Gallery, Kampa and Prague's Jesulae:**  
Tuesday 12 October, 10:00–14:00  
This half-day trip will take you to Kampa, one of the most charming spots in Old Prague.
- **Old town informative:**  
Tuesday 12 October, 14:00–17:00  
This tour will take you to the ancient heart of the city, the Old Town which was settled more than 1000 years ago.
- **Břevnov Monastery:**  
Wednesday 13 October, 10:00–14:00  
Břevnov Monastery – the seat of the Benedictine Arch Abbey of St. Benedict and St. Marketa.

Please visit the registration desk onsite with any queries. We hope you enjoy discovering Prague! It is easy to explore the city using the Prague metro. See map below and general information (inside back cover) for further details.

## Prague metro map



# Chairperson, speaker and poster presenter guidelines

## Essential information

If you are chairing or speaking in a session, or presenting a short oral presentation (Oral Poster) or Poster, it is essential that you refer to the guidelines below. Please note that there may be several sections which are relevant to your activities. If you have any questions, please address them to the staff in the speakers' preparation room (Club C level 1).

Our presentation system is networked to all session halls and presentations are uploaded through a software interface to ensure quality. OC, OP and P presentations should have been uploaded to this system online prior to the Congress. All session halls are equipped with the necessary technical requirements and back-up systems. **Please note that personal laptops may not be used in the session halls. All presentations must be uploaded in the speakers' preparation room.** Mac users and those with complex video can be accommodated.

**All oral sessions will be recorded by ISUOG** and made available for viewing (but not download) to delegates and ISUOG members on the new congress web portal. All speakers are asked to complete a release form for this and we thank you for supporting this new service to our members. Please note that publication embargoes can be applied if necessary. The portal will be demonstrated at the ISUOG stand and on the E-poster viewing stations at the Congress. Please address any queries to the technical staff in the speakers' preparation room.

## General notes

- Please meet at the front of the session hall 15 minutes before the start of the session to introduce yourselves, and allow the chairperson to confirm the format for the session.
- All presentations must be in English. Please ensure that you speak slowly and clearly throughout. This will assist audience members who do not have English as their first language.
- Discussion time has been allocated to each session so please look at the program closely for details.
- **The program schedule is extremely tight, so all speakers must adhere to the time allocated to them. Should a speaker overrun, chairpersons are instructed to interrupt and request that the speaker stop. Please be considerate of other speakers if you are asked to conclude your talk and please do so promptly.**
- It is increasingly difficult to prevent individuals from recording sessions. All delegates have been requested not to do this, but ISUOG can take no responsibility for third party recordings. **We request that speakers who specifically object to audio/video recording of their presentations state this before their lecture.**
- At the closing ceremony the scientific committee will announce the best presentations within subject categories, the Young Investigator prize winner and the Alfred Kratochwil award for best 3D presentation. Chairpersons are asked to assist in the selection process by scoring presentations.

## Chairpersons only

- There will be a chairpersons' briefing on Sunday 10 October at 12:30 in the Club rooms (level 1) to confirm session formats and demonstrate the presentation management tool. The briefing will last no longer than 30 minutes and lunch will be served. Your role is crucial to our Congress success and we are grateful for your attendance.
- It is your responsibility to ensure strict adherence to presentation times as listed in the program and to direct and

moderate discussion. There will be a countdown system in place in the main session halls to assist you with this.

- Should a speaker not arrive for his/her presentation, please fill in the additional time with discussion or, provided all other speakers are present, please move forward with the program. However please try not to deviate dramatically from the advertised program because delegates will rely on precise timing as they move across sessions.
- At the start of the session, please ask the audience to turn off all mobile phones and pagers. Please also remind the audience that the recording of sessions is not permitted. ISUOG will record all lectures and make them available online.
- There will be a host/hostess assigned to the session hall who will assist with any requirements you may have for the running of the session. A technician from the audio-visual team will also be available.
- There will be standard microphones within each hall for discussions. Delegates will need to wait behind the microphones to ask their questions. Please direct the audience at the start of the session as to how questions will be managed, to ensure the best use of time.
- Please note that delegates will not be permitted to stand at the back of the hall due to fire regulations.

## Invited and OC presentations

- All speakers must report to the speakers' preparation room at least four hours prior to the commencement of the session in which they are due to present and, preferably the day before their presentation. Speakers can then check their presentation with the audio-visual staff prior to the presentation being sent to the lecture hall.
- Presentations from personal laptops are not permitted in the session halls or breakout sessions; all presentations must be checked in at the speaker preparation room.
- If you are presenting an oral communication (OC) you should not present the background to your particular study or data set. This can be repetitive if several related studies are to be presented, and will be covered separately within the session if considered necessary. Time is short, so please keep your talk concise and focus only on your new data.

## Short oral presentations (Oral Posters – OP) and Posters (P)

- Authors should have emailed their single PowerPoint slides in advance of the Congress. The Organisers cannot guarantee that OP or P presentations can be included if they are not received in advance.
- OP and P slides will be available for viewing from Monday 11 to Thursday 14 October 2010 on the electronic viewing stations in the level 2 foyer. Authors can be contacted through this system.
- You will have been previously informed of the day of your presentation in your abstract acceptance letter. Poster (P) authors should be available to answer questions at the specified time (please refer to the program if you are unsure).
- OP presenters may report to the speaker preparation room the day before their presentation to check their presentation or can check directly on the viewing stations in level 2 foyer.
- Presenters should arrive at the relevant session hall at least 10 minutes prior to the listed start time.

# List of invited speakers

A. Abuhamad (USA)	S. Eik-Nes (Norway)	W. Lee (USA)	L. Salomon (France)
Z. Alfirovic (UK)	E. Epstein (Sweden)	C. Lees (UK)	K. Salvesen (Norway)
L. Allan (UK)	C. Exacoustos (Italy)	F.P.G. Leone (Italy)	L. Savelli (Italy)
R. Axt-Flidner (Germany)	E. Ferrazzi (Italy)	L. Lewi (Belgium)	W. Sepulveda (Chile)
A. Baschat (USA)	F. Figueras (Spain)	G. Lingman (Sweden)	T. Shipp (USA)
B. Benacerraf (USA)	D. Fischerova (Czech Republic)	S. Lipitz (Israel)	J. Sonek (USA)
C. Berg (Germany)	A. Gagnon (Canada)	C. Lombardi (Italy)	A. Steensma (Netherlands)
M. Bij de Vaate (Netherlands)	U. Gembruch (Germany)	G. Malinger (Israel)	K. Svabik (Czech Republic)
C. Bilardo (Netherlands)	T. Ghi (Italy)	K. Maršál (Sweden)	A. Tabor (Denmark)
H. Blaas (Norway)	L. Gindes (Israel)	S. Marsh (USA)	G. Ter Haar (UK)
C. Bottomley (UK)	S. Goldstein (USA)	J. Masata (Czech Republic)	A. Testa (Italy)
T. Bourne (UK)	E. Gratacos (Spain)	E. Merz (Germany)	D. Timmerman (Belgium)
C. Brezinka (Austria)	S. Gudmundsson (Sweden)	M. Momtaz (Egypt)	I.E. Timor-Tritsch (USA)
H. Brölmann (Netherlands)	S. Guerriero (Italy)	A. Ngu (Australia)	A. Toi (Canada)
P. Calda (Czech Republic)	L. Guibaud (France)	D. Nyberg (USA)	B. Tutschek (Switzerland)
S. Campbell (UK)	K. Hecher (Germany)	D. Paladini (Italy)	L. Valentin (Sweden)
J. Carvalho (UK)	E. Hernandez-Andrade (Mexico)	A. Papageorghiou (UK)	T. Van den Bosch (Belgium)
R. Chaoui (Germany)	K. Hodík (Czech Republic)	A. Pexsters (Belgium)	C. Van Holsbeke (Belgium)
D. Cibula (Czech Republic)	J. Jirasek (Czech Republic)	G. Pilu (Italy)	Y. Ville (France)
M. Claudon (France)	A. Johnson (USA)	L. Platt (USA)	R. Vlk (Czech Republic)
G. Condous (Australia)	K. Kagan (Germany)	D. Prayer (Austria)	M. Wielgos (Poland)
J. Copel (USA)	K. Kalache (Germany)	F. Prefumo (Italy)	J. Wladimiroff (UK)
F. Crispi (Spain)	E. Kirk (UK)	N. Raine-Fenning (UK)	S. Yagel (Israel)
J. Deprest (Belgium)	L. Krofta (Czech Republic)	R. Romero (USA)	I. Zador (USA)
H.P. Dietz (Australia)	T.K. Lau (China)	J. Rychik (USA)	M. Zikan (Czech Republic)

# Speaker declarations

The following declarations of interest have been received:

B. Benacerraf	All presentations will include discussion of commercial products or services
H. Cho	Support by Medison Research and Development Center, Seoul, Korea (OP20.03)
J. Copel	Travel support from Siemens and Philips Research support and equipment discounts from Philips
H. Dietz	Equipment loan from GE Kretz Medizintechnik B&K have provided an equipment loan (P26.07) GE Medical (equipment loan) (OP14.07, OP26.02) Provided consultant services to AMS (manufacturers of the Perigee implant) Equipment loans from GE (manufacturers of Voluson ultrasound systems) (OP26.09)
E. Ferrazzi	All presentations will include discussion of commercial products or services
H. Fukunishi	InSightec Ltd. Clinical trial (P11.05)
T. Ghi	The following presentation will include discussion of commercial products or services; Workshop: 3D ultrasound in labor.
W. Lee	Consultant for GE Healthcare, Philips Ultrasound and Siemens Medical with limited research support. (OC26.03, P19.08, OP27.01) Unpaid consultant for Tom Tec
D. Paladini	Lectures and courses produced for GE (OP18.04, OP25.06)
G. Pilu	Unpaid consultant for GE Healthcare
L. Platt	Consultant for GE Medical Systems and Philips Medical Systems with research support from both
N. Raine-Fenning	The following presentations will include discussion of commercial products or services; Factors influencing outcome after IVF (including uterine anomalies), Live scan demonstration: how to assess ovarian reserve, Workshop: Fertility: assessing the ovarian reserve and the uterus.
J. Schlütter	FCMB Aps supports the project financially by analyzing all the blood samples for fetal cells (P04.05)
A. Shmueli	Hamutal Meiri is an employee of Diagnostic Technology, who manufacture PP13 ELISA kit (P14.14)
J. Steinhard	Scientific cooperation with Toshiba Medical Systems Europe (OP08.02)
F. Viñals	GE Healthcare Clinical evaluation of ultrasound system (OP09.06, OP25.05, OP25.07, OP25.08, P08.05, P25.08)

# Program orientation

- The **program at a glance** gives you an outline to each day's events including session titles and times, and refreshment breaks.
- **'All you ever wanted to know'** sessions are not part of the main delegate program. An entry ticket is required which can be purchased at the registration desk (€25 per session), spaces strictly limited. The program for daily sessions is listed prior to the main program pages.
- The **program pages** give you the detailed chronological listing of events – please note that most sessions run in parallel so you will need to read through sessions of similar time to decide which best suits your needs.
- **Workshops** are new to our program and are offered in response to delegate requests for more didactic sessions and educational content. Live scans are included where appropriate. Sessions are part of the main program and run on a first come first serve basis, according to room capacities.
- All presentations which are supported by free communication abstracts have an OC (oral communication), OP (short oral presentation – oral poster) or P (poster) number listed next to them; you can use this to refer to the abstract in the abstract book or on the electronic viewing stations in the level 2 foyer.
- In all oral communication, short oral presentation (oral posters) and electronic poster presentation listings, the presenting author name is underlined.
- All short presentation and poster titles are listed in the pages immediately following the day of oral sessions. Short oral presentations (oral posters, OP numbers) are listed first and posters (P numbers) second.
- All short oral presentations (oral posters) and poster presentations are available for viewing throughout the congress on electronic poster viewing stations in the level 2 foyer.
- **All OC and OP presentations, invited talks and workshops will be recorded** and made available to delegates on the new ISUOG congress web portal. The portal will be demonstrated on the viewing stations and at the ISUOG stand. **Delegates are not permitted to make individual recordings of lectures.**
- Some sessions and workshops include 'live scan demonstrations': these are live updates on the latest techniques and technologies in the field, which support the scientific data in the same subject area.
- All oral presentations (OC/OP) will be judged within their subject categories by the session chairpersons and ISUOG Scientific Committee. The Young Investigator prize, the Alfred Kratochwil award for the best 3D paper and best presentations will be announced at the closing session and formally acknowledged in the *Ultrasound in Obstetrics & Gynecology* journal.
- **Electronic posters:** A question and answer session has been organised for each electronic poster (P) session. All authors are asked to be present during the relevant session (listed at the appropriate times in the program pages) to answer questions from the floor.
- The exhibition hall opens at 09:00 each day. All refreshment breaks are located within the exhibition area (Monday to Wednesday). On Thursday refreshments will be served in the level 1 foyer and bar.

## Accreditation and CME credit

### Up to 27 European CME credits (ECMEC)

ISUOG is accredited by the European Accreditation Council for Continuing Medical Education (EACCME) to provide the following CME activity for medical specialists. The EACCME is an institution of the European Union of Medical Specialists (UEMS), [www.uems.net](http://www.uems.net).

The '20th World Congress on Ultrasound in Obstetrics and Gynecology' is designated for a maximum of (or 'for up to') 27 hours of European external CME credits. Each medical specialist should claim only those hours of credit that he/she actually spent in the educational activity.

EACCME credits are recognised by the American Medical Association towards the Physician's Recognition Award (PRA). To convert EACCME credit to AMA PRA category 1 credit, contact the AMA.

24 ECME credits are available for the Congress

3 ECME credits are available for the Pre-Congress courses

### CME attendance certificates









In order to receive your certificate of attendance for the congress, you must complete the CME evaluation form (found in your delegate bag) and return it to the registration desk. Please make sure that you complete the form at the time of each session, in order to give us accurate feedback. Certificates will be available from Wednesday 13 October 2010.



Full paying delegates at the 20th World Congress are members of ISUOG for 2011 and benefit immediately from member only access to the Society's website resources, including *Ultrasound in Obstetrics and Gynecology* (UOG).

Except for trainees and sonographers, delegate members also receive a monthly print copy of the Journal. **If you are happy to enjoy your Journal online, or are concerned about the environmental impact of print materials, you can opt out of receiving your print copy. Please visit us at the ISUOG lounge in the exhibition area and let us know or email [info@isuog.org](mailto:info@isuog.org).**

## Membership for 2011 includes:

-  Annual subscription to UOG
-  Member only access to the Society's official website and educational material
-  Web lectures & webcasts from ISUOG courses and other events
-  Access to our **new ISUOG Congress Web Portal\***
-  Regular e-newsletters
-  ISUOG support of teaching programs
-  ISUOG Book Club: 20% discount on Wiley-Blackwell books
-  Reduced fees to ISUOG educational courses, ISUOG Scientific Meetings

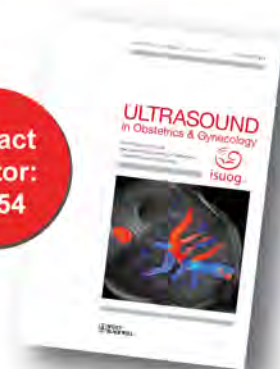AND the...

## 21st World Congress on Ultrasound in Obstetrics and Gynecology



18–22 September 2011, Los Angeles, USA

Impact  
Factor:  
3.154



## \*NEW for 2010/11: Congress Web Portal

All ISUOG congress sessions will now be available to view online during and after the Congress through our new Congress Web Portal.

The Portal can be accessed on site at the e-poster viewing stations in the **Level 2 foyer** and at the **ISUOG lounge**. Members can activate their personal access to the Portal through the members only website. See ISUOG staff at the lounge to find out more.

# Program at a glance

## Sunday 10 October 2010

07:00–20:00	Registration in Level 1 foyer			07:00–20:00
	Congress hall	Club A	Club E	
08:00–13:00		Pre-Congress course: 11–14 week scan	Pre-Congress course: Pelvic floor ultrasound	08:00–13:00
14:00–16:00	Welcome Top 5 abstracts Stuart Campbell lecture	Alfred Kratochwil lecture ISUOG AGM		14:00–16:00
16:00–16:30	Coffee break			16:00–16:30
16:30–17:30	Gold Medal lecture	Special lectures		16:30–17:30
17:30–18:00	Interval drinks			17:30–18:00
18:00–18:30	Performance by the Black Light Theatre company			18:00–18:30
18:30–21:00	Welcome reception			18:30–21:00

## Monday 11 October 2010

	Congress hall	Forum hall	Panorama hall	North hall	Club A	Club E	
07:45–08:30			'All you ever wanted to know' sessions*				07:45–08:30
09:00–10:00	Live scan Congenital heart disease	Short term outcome in fetal growth restriction	Early pregnancy				09:00–10:00
10:00–10:40		Short oral presentation sessions (oral posters)					10:00–10:40
		OP01	OP02	OP03	OP04	OP05	
10:40–10:55		Electronic poster Q&A					10:40–10:55
		P01	P02	P03	P04	P05	
10:30–11:00	COFFEE AND ELECTRONIC POSTER VIEWING						10:30–11:00
11:00–12:30	Live scan Advanced fetal echocardiography: atrial isomerism (heterolaxy)	Identifying risk in monochorionic twin pregnancy Live scan	Ultrasound and the acute gynecology patient		ISUOG Outreach		11:00–12:30
12:30–14:00	LUNCH, ELECTRONIC POSTER VIEWING, SPONSOR ACTIVITIES						12:30–14:00
	Philips satellite symposium						
14:00–15:00	Live scan First trimester	Twin-twin transfusion syndrome	Abnormal uterine bleeding				14:00–15:00
15:00–15:40		Short oral presentation sessions (oral posters)					15:00–15:40
		OP06	OP07	OP08	OP09	OP10	
15:40–16:00		Electronic poster Q&A					15:40–16:00
		P06	P07	P08	P09	P10	
15:40–16:10	COFFEE AND ELECTRONIC POSTER VIEWING						15:40–16:10
16:00–17:30	Live scan Advanced fetal neurosonography	Live scan Practical new tools in fetal echocardiography	Early pregnancy complications		Live scan Doing it safely		16:00–17:30
17:50–18:35	'All you ever wanted to know' sessions*						17:50–18:35

## Tuesday 12 October 2010

	Congress hall	Forum hall	Panorama hall	North hall	Club A	Club E	
07:45–08:30			'All you ever wanted to know' sessions*				07:45–08:30
09:00–10:00	Live scan Fetal cardiac function	The assessment of pelvic pain	New imaging techniques				09:00–10:00
10:00–10:40		Short oral presentation sessions (oral posters)					10:00–10:40
		OP11	OP12	OP13	OP14	OP15	
10:40–10:55		Electronic poster Q&A					10:40–10:55
		P11	P12	P13	P14	P15	
10:30–11:00	COFFEE AND ELECTRONIC POSTER VIEWING						10:30–11:00
11:00–12:30	CNS imaging in early pregnancy Live scan	Reproductive medicine	Obstetric management				11:00–12:30
12:30–14:00	LUNCH, ELECTRONIC POSTER VIEWING, SPONSOR ACTIVITIES						12:30–14:00
	Siemens satellite symposium	Medison satellite symposium					
14:00–15:00	Live scan Multiple pregnancy	Using ultrasound to assess urogynecology patients	Preterm labour				14:00–15:00
15:00–15:40		Short oral presentation sessions (oral posters)					15:00–15:40
		OP16	OP17	OP18	OP19	OP20	
15:40–16:00		Electronic poster Q&A					15:40–16:00
		P16	P17	P18	P19	P20	
15:40–16:10	COFFEE AND ELECTRONIC POSTER VIEWING						15:40–16:10
16:00–17:30	Live scan Molecular vs ultrasound screening for T21	Live scan Fertility: assessing ovarian reserve and the uterus	Doppler in screening	Borderline findings			16:00–17:30
19:30–00:00	Congress party at the Zofin Palace						19:30–00:00

# Program at a glance

## Wednesday 13 October 2010

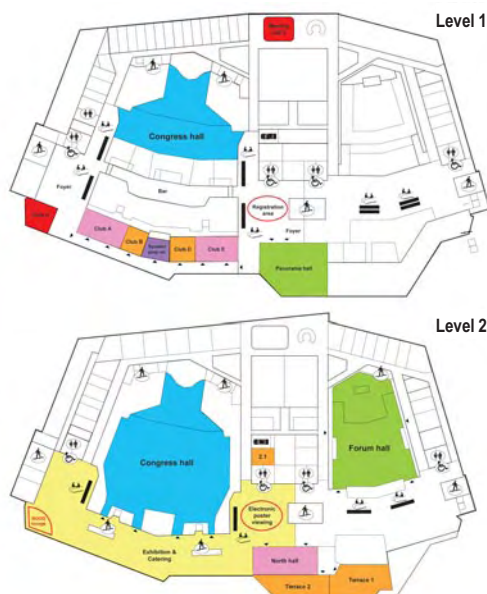	Congress hall	Forum hall	Panorama hall	North hall	Club A	Club E	
07:45–08:30				'All you ever wanted to know' sessions*			07:45–08:30
09:00–10:00	Live scan	Diagnosis and management of ovarian pathology	In-utero interventions				09:00–10:00
	Maternal fetal doppler						
10:00–10:40		Short oral presentation sessions (oral posters)					10:00–10:40
		OP21	OP22	OP23	OP24	OP25	
10:40–10:55		Electronic poster Q&A					10:40–10:55
		P21	P22	P23	P24	P25	
10:30–11:00	COFFEE AND ELECTRONIC POSTER VIEWING						10:30–11:00
11:00–12:30	Live scan	Scanning asymptomatic women: cancer screening	Ultrasound in labour				11:00–12:30
	Fetal surveillance						
12:30–14:00	LUNCH, ELECTRONIC POSTER VIEWING, SPONSOR ACTIVITIES						12:30–14:00
	GE satellite symposium						
14:00–15:00	Live scan	Mathematical models and new second stage tests to assess the ovary					14:00–15:00
	Long term outcome in fetal growth restriction						
15:00–15:40		Short oral presentation sessions (oral posters)					15:00–15:40
		OP26	OP27	OP28	OP29	OP30	
15:40–16:00		Electronic poster Q&A					15:40–16:00
		P26	P27	P28		P30	
15:40–16:10	COFFEE AND ELECTRONIC POSTER VIEWING						15:40–16:10
16:00–17:30	The spectrum of 3D/4D ultrasound in prenatal diagnosis	Use of ultrasound in gynecological oncology	How fetal conditions affect the heart				16:00–17:30
	Live scan						
17:50–18:35				'All you ever wanted to know' sessions*			17:50–18:35

## Thursday 14 October 2010

	Congress hall	Forum hall	Club A	Club B	Club D	Club E	
07:45–08:30			'All you ever wanted to know' sessions*				07:45–08:30
08:30–09:10		Short oral presentation sessions (oral posters)					08:30–09:10
		OP31	OP32	OP33		OP34	
09:10–09:25		Electronic poster Q&A					09:10–09:25
		P31	P32	P33		P34	
09:30–10:30	Live scan	The post-menopausal endometrium and cervical pathology					09:30–10:30
	Second trimester scan						
10:30–11:30	COFFEE AND ELECTRONIC POSTER VIEWING						10:30–11:30
11:00–11:40		Short oral presentation sessions (oral posters)					11:00–11:40
		OP35	OP36	OP37	OP38	OP39	
11:40–13:10	Cardiac function in specific conditions	Imaging in the oncology patient: staging, recurrence & interventions					11:40–13:10
	Live scan						
13:10–13:30	Closing plenary						13:10–13:30
13:30	FAREWELL DRINKS, LUNCH AND CONGRESS CLOSE						13:30

### Key:

- 'All you want to know' sessions\*
- Electronic poster session
- Gynecology oral session
- Live scan
- Obstetric oral session
- Plenary session
- Pre-congress course
- Satellite symposium
- Short oral presentation sessions (oral posters)
- Social
- Workshop session



Please see full size plan inside front cover

### Key:

- Exhibition, catering
- Main session hall (obstetrics)
- Parallel session halls (obs & gyn)
- Breakouts
- Speaker prep room
- ISUOG meeting rooms
- Sponsor hospitality

Catering breaks (Mon–Wed) will be served in the exhibition area. Thursday catering will be served in the level 1 foyer and buffet bar.

\* All you ever wanted to know sessions must be pre-booked and cost €25 per session, see page 11 for details.

# Posters at a glance

All short oral presentations (oral posters) and posters are available for viewing all day on the electronic poster pods in the level 2 foyer.

Day		Poster session	Time	Hall
Monday	OP	OP01: IUGR I: diagnosing and managing fetal growth restriction	10:00–10:40 Short oral presentation sessions (oral posters)	Forum hall
	OP	OP02: Early pregnancy I		Panorama hall
	OP	OP03: Fetal heart I: screening for congenital heart disease		North hall
	OP	OP04: First trimester I: screening for aneuploidy		Club A
	OP	OP05: CNS I: fetal brain MRI		Club E
	P	P01: IUGR I: outcome in placental dysfunction	10:40–10:55 Poster Q&A	Forum hall
	P	P02: Early pregnancy I		Panorama hall
	P	P03: Fetal heart I: fetal cardiac anomalies		North hall
	P	P04: First trimester I: aneuploidy and other complications		Club A
	P	P05: CNS I: fetal brain MRI		Club E
	OP	OP06: Multiple pregnancy I: twin–twin transfusion syndrome	15:00–15:40 Short oral presentation sessions (oral posters)	Forum hall
	OP	OP07: Abnormal uterine bleeding		Panorama hall
	OP	OP08: Fetal heart II: new techniques to assess cardiac function		North hall
	OP	OP09: Screening for trisomy 21		Club A
	OP	OP10: Imaging technologies I		Club E
	P	P06: Multiple pregnancy I: monochorionic twins	15:40–16:00 Poster Q&A	Forum hall
	P	P07: Abnormal uterine bleeding		Panorama hall
	P	P08: Fetal heart II: 3D/4D & STIC		North hall
P	P09: Unusual syndromes	Club A		
P	P10: Imaging technologies I	Club E		
Tuesday	OP	OP11: Pelvic pain	10:00–10:40 Short oral presentation sessions (oral posters)	Forum hall
	OP	OP12: Fetal heart III: circulation and rhythm in congenital heart disease		Panorama hall
	OP	OP13: Preterm labour		North hall
	OP	OP14: Adverse outcome of pregnancy and pelvic floor		Club A
	OP	OP15: CNS II: fetal brain anomalies		Club E
	P	P11: Pelvic pain and reproductive medicine	10:40–10:55 Poster Q&A	Forum hall
	P	P12: Fetal heart III: fetal cardiac function		Panorama hall
	P	P13: Preterm labour		North hall
	P	P14: Adverse outcome of pregnancy and pelvic floor		Club A
	P	P15: CNS II: fetal brain anomalies		Club E
	OP	OP16: Reproductive medicine	15:00–15:40 Short oral presentation sessions (oral posters)	Forum hall
	OP	OP17: First trimester II: improving quality of screening for aneuploidy		Panorama hall
	OP	OP18: Fetal anomalies I: fetal face and chest assessments		North hall
	OP	OP19: Multiple pregnancy II		Club A
	OP	OP20: Imaging technologies II		Club E
	P	P16: Early pregnancy II	15:40–16:00 Poster Q&A	Forum hall
	P	P17: First trimester II: aneuploidy and anomalies		Panorama hall
	P	P18: Fetal anomalies I: fetal face and chest assessment		North hall
P	P19: Multiple pregnancy II	Club A		
P	P20: Imaging technologies II	Club E		
Wednesday	OP	OP21: Managing ovarian masses	10:00–10:40 Short oral presentation sessions (oral posters)	Forum hall
	OP	OP22: Fetal heart IV: 3D/4D ultrasound		Panorama hall
	OP	OP23: First trimester III: anomalies		North hall
	OP	OP24: Maternal fetal Doppler I		Club A
	OP	OP25: CNS III: 3D ultrasound in fetal brain anomalies		Club E
	P	P21: Managing ovarian masses	10:40–10:55 Poster Q&A	Forum hall
	P	P22: Fetal heart IV		Panorama hall
	P	P23: Incomplete splitting in multiple pregnancy		North hall
	P	P24: Maternal fetal Doppler		Club A
	P	P25: CNS III: 3D ultrasound in fetal brain anomalies		Club E
	OP	OP26: Pelvic floor	15:00–15:40 Short oral presentation sessions (oral posters)	Forum hall
	OP	OP27: Fetal therapy		Panorama hall
	OP	OP28: Fetal anomalies II: second and third trimester		North hall
	OP	OP29: IUGR II		Club A
	OP	OP30: Placenta pathologies and uterine scar		Club E
	P	P26: Pelvic floor	15:40–16:00 Poster Q&A	Forum hall
	P	P27: In-utero interventions		Panorama hall
	P	P28: Fetal anomalies II: second and third trimester		North hall
P	P29: There are no abstracts assigned to this poster session			
P	P30: Placenta pathologies and uterine scar	Club E		

# Posters at a glance

Day		Poster session	Discussion time	Hall
Thursday	OP	OP31: Imaging in the oncology patient	08:30–09:10 Short oral presentation sessions (oral posters)	Forum hall
	OP	OP32: Induction of labour: ultrasound during labour and postpartum		Club A
	OP	OP33: Fetal anomalies III: fetal abdomen		Club B
	OP	OP34: First trimester IV: growth and predicting pregnancy outcome		Club E
	P	P31: Imaging in the oncology patient	09:10–09:25 Poster Q&A	Forum hall
	P	P32: Induction and ultrasound in labour		Club A
	P	P33: Fetal anomalies III: fetal abdomen		Club B
	P	P34: First trimester IV: fetal abnormalities		Club E
	OP	OP35: Scanning asymptomatic women	11:00–11:40 Short oral presentation sessions (oral posters)	Forum hall
	OP	OP36: Fetal heart V: cardiac and vascular anomalies		Club A
	OP	OP37: Maternal fetal Doppler II		Club B
	OP	OP38: Fetal size		Club D
	OP	OP39: IUGR III: fetal programming in placental dysfunction		Club E

# 'All you ever wanted to know' sessions

**Please note; entry to these sessions is NOT included in the congress registration fee. Tickets for each session cost €25** and can still be booked at the registration desk if places are available. You will receive a ticket as proof of your registration and will need this ticket for entry to the session.

Day	Time	Professor	Session title	Room
Monday	07:45 – 08:30	R. Chaoui (Germany)	Systematic approach to the early fetal anomaly scan	Panorama hall
		J. Carvalho (UK)	First trimester fetal echocardiography	North hall
	08:30 – 17:50	E. Gratacos (Spain)	Selective IUGR in monochorionic twins	Club A
		G. Condous (Australia)	Managing early pregnancy complications	Club E
	17:50 – 18:35	B. Tutschek (Switzerland)	Fetal cardiac function, including automated assessment	Club A
		H. Dietz (Australia)	Levator trauma	Club E
Tuesday	07:45 – 08:30	A. Abuhamad (USA)	Fetal cardiac anatomy	Panorama hall
		L. Platt (USA)	Getting the most out of 3D volumes	North hall
	08:30 – 17:50	D. Prayer (Austria)	New achievements in fetal MRI	Club A
		N. Raine-Fenning (UK)	Ultrasound in reproductive medicine	Club E
Wednesday	07:45 – 08:30	S. Yagel (Israel)	Abnormalities of the venous system	Panorama hall
		B. Benacerraf (USA)	Fetal face anomalies, 2D and 3D	North hall
		C. Brezinka (Austria)	When to use Doppler and when not to	Club A
	17:50 – 18:35	A. Testa (Italy)	Assessing cervical pathology	Club E
		Y. Ville (France)	Sonography in prenatal CMV infection	North hall
		J. Deprest (Belgium)	Treatment of fetal diaphragmatic hernia	Club A
		D. Fischerova (Czech Republic)	How to scan the entire abdomen and pelvis	Club E
Thursday	07:45 – 08:30	A. Baschat (USA)	Current issues in IUGR management	Club A
		C. Berg (Germany)	Diagnosis of heterotaxy	Club B
		T. Van den Bosch (Belgium)	Evaluating the endometrium	Club D
		G. Pilu (Italy)	Fetal syndromes	Club E



# The International Society of Ultrasound in Obstetrics and Gynecology

Invites you to attend the Annual General Meeting (AGM)

**Sunday 10 October 2010**





**15:40**

**Congress Hall, Prague Congress Centre**

All fully paid delegates at ISUOG's 20th World Congress in Prague are members of ISUOG in 2011\* and are encouraged to attend the AGM for an update on ISUOG activities. Agenda and accompanying documents are available at [www.isuog.org/membership/AGM](http://www.isuog.org/membership/AGM).




\*Membership includes a monthly print copy of UOG delivered to your preferred mailing address. If you would rather enjoy your journal online only, please visit the ISUOG stand to opt out of your print journal.

**Visit the ISUOG Lounge in the exhibition area anytime to find out more about the Society and its activities:**

-  **ISUOG membership, online resources, courses and events**
-  **Submitting and publishing in Ultrasound in Obstetrics and Gynecology (UOG)**
-  **Accessing UOG online**
-  **NEW Congress web portal**



### Special events on the ISUOG Stand:

-  **Meet the Publisher:** representatives from the publisher Wiley-Blackwell will be on the ISUOG stand at all times.
-  **Meet an Editor:** ISUOG's managing Editor Sarah Hatcher and/or UOG's Editors will be on the stand to answer author queries.
-  **Membership Clinic:** ISUOG's membership officer, Anna Lewis, will be available to demonstrate ISUOG's online resources and answer your membership queries.

	Monday 11 October	Tuesday 12 October	Wednesday 13 October
09:00 - 17:00 (all day)	MEET THE PUBLISHER		
	MEET AN EDITOR		
10:30 - 11:30	MEMBERSHIP & WEBSITE CLINIC		
12:30 - 14:00			MEET AN EDITOR
13:00 - 14:00	MEMBERSHIP & WEBSITE CLINIC		
15:30 - 16:30	MEMBERSHIP & WEBSITE CLINIC	MEET AN EDITOR	



# Program – Sunday 10 October 2010

## Pre-Congress courses

### 08:30–13:30 Pre-Congress course: 11–14 week scan Club A

Chair: *O. Kagan (Germany)*

- 08:30 Invasive and non invasive diagnosis of chromosomal abnormalities  
*T. Lau (China)*
- 09:15 Increased nuchal translucency of normal karotype  
*K. Bilardo (Netherlands)*
- 10:00 Update on screening for chromosomal abnormalities  
*O. Kagan (Germany)*

### 10:45 Coffee

- 11:15 Screening for neural tube and cardiac defects  
*R. Chaoui (Germany)*
- 12:15 Screening for pre-eclampsia  
*K. Nicolaides (United Kingdom)*  
**Please note: this lecture will be presented via a remote link**

### 08:30–13:10 Pre-Congress course: Pelvic floor ultrasound Club E

Chair: *H. Dietz (Australia)*

- 08:30 Introduction and anterior compartment  
*H. Dietz (Australia)*
- 09:00 Q&A
- 09:10 Posterior compartment  
*A. Steensma (Netherlands)*
- 09:40 Q&A
- 09:50 Slings and meshes  
*K. Svabik (Czech Republic)*
- 10:20 Q&A

### 10:30 Coffee

- 11:00 Levator trauma  
*H. Dietz (Australia)*
- 11:30 Q&A
- 11:40 Live scan demonstrations and discussion

This course is kindly supported by



GE imagination at work

### 13:30 Closing and lunch (course delegates only)

An additional 3 ECMEC credits are available for the Pre-Congress courses. Please see page 6 for further information.

# Special lecture biographies



## Jan Jirasek

Jan Jirasek was born in 1929 Pardubice, Czech Republic into a medical family, with both his father and grandfather practicing as doctors. He attended the Medical School at Charles University, Prague, graduating in 1953, and took up his first position as Assistant Professor of the Department of Embryology at Charles University. He then moved on to become Head of the Laboratory for Embryology and Reproductive Medicine at the Institute for the Care of Mother and Child, also in Prague. Between 1968 and 1987 he held a number of prominent positions in universities and medical schools in America, working with experts such as R.J. Gorlin, J.J. Sciarra, J. L. Simpson and S. Elias. Since 2006 he has held the position of First Visiting Professor of the Perinatal Reproductive Branch of NIH Detroit, Michigan, USA, and works closely with Professor R. Romero.



## Karim Kalache

Karim Kalache is Professor and Vice Chairman of the Department of Obstetrics at the Charité University Hospital in Berlin. He finalized his Maternal-Fetal Medicine fellowship at University College London in 1999. In 2001 he joined the Perinatology Research Branch in Detroit, Michigan. He was appointed Senior Lecturer at the University of Southampton 1996 and full Professor in Obstetrics at the Charité University Hospital in 2008. Dr. Kalache is a Level-III DEGUM member. He consults for numerous peer-reviewed OB/GYN journals and often lectures at medical institutions and various maternal-fetal medicine societies in Germany and abroad. He is married to his colleague Katrin and they have three exceeding energetic sons.



## Charles Kleinman

Dr. Charles S. Kleinman was born, raised and educated in New York City until the final year of his Postgraduate Fellowship Training, when he left Cornell University Medical College to complete his training in pediatric cardiology at the Cardiovascular Research Institute at the University of California, San Francisco. Thereafter he joined the faculty of the Yale University School of Medicine, where, 1986, he became Professor of Pediatrics, Obstetrics and Gynecology and Diagnostic Imaging. During his years at Yale he was encouraged to combine his clinical interest in cardiac ultrasound with fetal cardiovascular development, thus to participate in the development of the new field, Clinical Fetal Cardiology. In 2000–2002 he became the Director of Cardiology at the Nemours Cardiac Center in Orlando, Florida, and has spent the past 8 years as Professor of Pediatrics in Obstetrics and Gynecology at the Columbia University School of Physicians & Surgeons. Dr. Kleinman has been fortunate to work with numerous illustrious partners in multidisciplinary and multi-institutional efforts to improve our understanding and the medical care of fetuses and neonates with congenital heart disease.



## Wesley Lee

Wesley Lee, M.D. is a Clinical Professor of OBGYN at Oakland University William Beaumont School of Medicine in Michigan (USA). He has authored scientific articles and book chapters pertaining to high-risk pregnancy, prenatal diagnosis, 3D/4D ultrasonography, and fetal MR. He is an Associate Investigator with the Perinatology Research Branch of the Eunice Kennedy Shriver National Institute of Child Health and Human Development and also serves as a Scientific Advisor to the World Health Organization. Dr. Lee has chaired Task Forces that developed practice guidelines for fetal cardiac screening (AIUM, ISUOG) and fetal echocardiography (AIUM, ACOG, SMFM, ACR). Other activities include: Chair, ISUOG Clinical Standards Committee (2005-2010), Editorial Board member for Ultrasound in Obstetrics and Gynecology, and Deputy Editor for the Journal of Ultrasound in Medicine.



## Karel Maršál

Karel Maršál was born in Prague, Czechoslovakia, where he also got his undergraduate education at the Medical Faculty of Charles University. Since 1968 he lives in Sweden, where he fulfilled his training in obstetrics and gynecology, started his research in obstetric ultrasound and became Professor of Obstetrics and Gynecology at Lund University. He was president of ISUOG and Chairman of the ISUOG Scientific Committee and co-organizer of two World Congresses on Obstetric and Gynecological Ultrasound (Stockholm and Prague). He is the past Board member of several national and international societies within obstetrics, perinatology and diagnostic ultrasound, e.g. WFUMB, EFSUMB. Primary areas of research interest: Obstetric ultrasound, Doppler ultrasound, Safety of diagnostic ultrasound, Fetal physiology, Perinatology, Clinical obstetrics, Perinatal epidemiology.



# Program – Sunday 10 October 2010

<b>14:00–15:30</b>	<b>Opening session (with Top 5 abstracts)</b>	<b>Congress hall</b>
	<i>Chairs: K. Maršál (Sweden); A. Baschat (United States)</i>	
14:00	Welcome from the ISUOG President <i>G. Pilu (Italy)</i>	
14:05	Welcome from the Congress President <i>P. Calda (Czech Republic)</i>	
14:10	<b>Stuart Campbell lecture:</b> The emerging role of ultrasound for optimized patient care in the second stage of labor <i>K. Kalache (Germany)</i>	
	<b>Top 5 abstracts</b>	
14:30	Ultrasound evaluation of the Caesarean scar: relation between a niche and postmenstrual spotting <i>H. van der Slikke; M. Bij de Vaate; H. Brölmann; L. van der Voet; S. Veersema; J. Bartholomew; J. Huime (Netherlands)</i>	OC01.01
14:36	Discussion	
14:40	The effect of metformin on the uteroplacental circulation in comparison with aspirin in pregnant women with polycystic ovary syndrome <i>A. Jamal; F. Milani; P. Shabani; A. Aleyasin (Islamic Republic of Iran)</i>	OC01.02
14:46	Discussion	
14:50	Ultrasound in diagnosis of new and recurrent borderline ovarian tumors <i>D. Fischerova<sup>1</sup>; D. Franchi<sup>2</sup>; A. Testa<sup>2</sup>; L. Valentin<sup>3</sup>; L. Savelli<sup>2</sup>; A. Lissoni<sup>2</sup>; R. Fruscio<sup>2</sup>; C. Van Holsbeke<sup>4</sup>; E. De Jonge<sup>4</sup>; S. Van Huffel<sup>4</sup>; T. Bourne<sup>4,5</sup>; B. Van Calster<sup>4</sup>; F. Amant<sup>4</sup>; D. Timmerman<sup>4</sup></i> <sup>1</sup> (Czech Republic); <sup>2</sup> (Italy); <sup>3</sup> (Sweden); <sup>4</sup> (Belgium); <sup>5</sup> (United Kingdom)	OC01.03
14:56	Discussion	
15:00	<sup>^</sup> Analysis of brain structure by MRI and neurodevelopment in preterm born infants with and without IUGR at 12–18 months of age <i>M. Sanz-Cortes; N. Padilla; C. Falcon; N. Bargallo; F. Figueras; F. Botet; A. Arranz; E. Gratacós (Spain)</i>	OC01.04 and OC01.05
15:06	Discussion	
15:10	Axonal loss and cognitive outcome at five years in term small-for-gestational age infants with normal umbilical artery <i>D. Oros; S. Valle; H. Tuquet; V. Pueyo; N. Güerri; P. Ventura (Spain)</i>	OC01.06
15:16	Discussion	
15:20	<b>Alfred Kratochwil lecture:</b> Great expectations: the future of innovation in fetal imaging <i>W. Lee (United States)</i>	
<b>15:40–16:10</b>	<b>ISUOG Annual General Meeting</b>	<b>Congress hall</b>
	<i>Chair: G. Pilu (Italy)</i> Report on ISUOG membership and activities: UOG, education, ISUOG Outreach	
<b>16:10–16:30</b>	<b>Coffee</b>	<b>Level 1 foyer</b>
	Our afternoon program and theatre production is open to all delegates, accompanying persons and exhibitors	
<b>16:30–17:30</b>	<b>Opening ceremony and lectures (all welcome)</b>	<b>Congress hall</b>
	<i>Chairs: A. Tabor (Denmark); P. Calda (Czech Republic)</i>	
16:30	Handover of ISUOG Presidency to Professor Ann Tabor	
16:35	Presentation of the Gold Medal to Charlie Kleinman <i>J. Cope (United States)</i>	
16:40	Gold Medal lecture <i>C. Kleinman (United States)</i>	
17:00	Special lecture: Doppler and the stars of Prague <i>K. Maršál (Sweden)</i>	
17:20	Special lecture: Developmental stages in human embryos and morphologic sequence of human head development <i>J. Jirasek (Czech Republic)</i>	
<b>17:35–18:00</b>	<b>Interval drink</b>	<b>Level 1 foyer</b>
<b>18:00–18:30</b>	<b>Black Light Theatre company</b>	<b>Congress hall</b>
<b>18:30–21:00</b>	<b>Welcome reception</b>	<b>Exhibition area</b>

<sup>^</sup> This abstract has been shortlisted as a finalist for the Alfred Kratochwil 3D abstract award. The winner will be announced at the closing ceremony.

# Outreach Workshop

## Outreach Workshop

Monday 11 October 11:00am - 12:30pm, Club A

This session is open to all and free of charge. Come and learn about ISUOG's international Outreach work and share your ideas.

- Maternal mortality in the developing world and the role of ultrasound (Dr. A. Abuhamad)
- Join in discussion groups: prioritising, funding and evaluating Outreach.

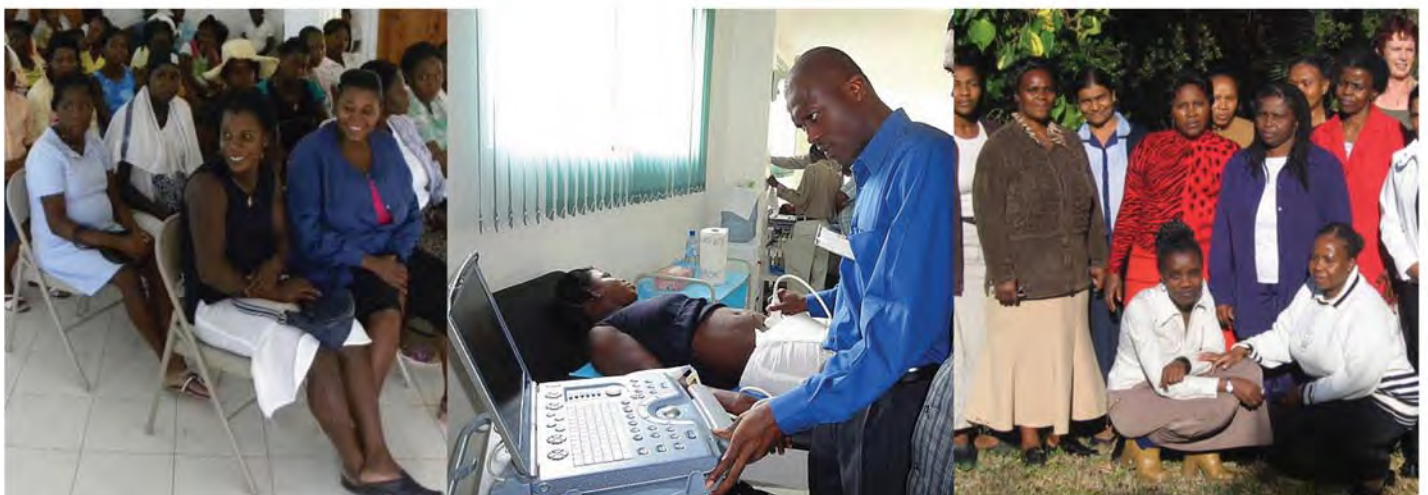

The ISUOG Outreach program provides intensive hands-on training in ultrasound, supported by essential theoretical knowledge, in underserved regions of the world.

Each ISUOG Outreach training program is preceded by a comprehensive needs assessment of participants, and is therefore targeted specifically to trainee needs.

Trainees should leave with the knowledge and skills necessary to diagnose and avoid the most common obstetric emergencies. Pre- and post-tests will monitor trainee progress and are used to plan future visits and comprehensive educational materials are provided to reinforce the theoretical components of teaching and to cover ultrasound system use.

Contact with trainers is maintained between visits, and the Outreach team always aims to make at least three training visits to each location.



# Program – Monday 11 October 2010

07:45–08:30 'All you ever wanted to know' breakfast sessions must be pre-booked at the registration desk. See page 11 for details

09:00–10:00	Congenital heart disease	Congress hall
	<i>Chairs: R. Chaoui (Germany); L. Allan (United Kingdom)</i>	
09:00	Overview <i>R. Chaoui (Germany)</i>	
09:05	Live scan demonstration: 2D/3D anatomy of the fetal heart (supported by Philips*) <i>B. Tutschek (Switzerland)</i>	
09:20	^ Impact of live 4D ultrasound volume rate on recognition of fetal cardiac structures in reformatted 2D views <i>J. Deng; R. Yates; C. Demetrescu; D. Pellerin (United Kingdom)</i>	OC02.01
09:25	Discussion	
09:28	New insight of using spatiotemporal image correlation in prenatal screening of fetal conotruncal defects <i>B. Zhao; Z. Xie (China)</i>	OC02.02
09:33	Discussion	
09:36	^ Fetal interrupted aortic arch: 2D-4D echocardiography, associations and outcome <i>V. De Robertis; G. Rembouskos; G. Campobasso; A. Tempesta; N. Volpe; P. Volpe (Italy)</i>	OC02.03
09:41	Discussion	
09:44	ARSA incidence and correlation with other strong markers of Down syndrome in 116 trisomy 21 fetuses assessed in a tertiary referral center <i>D. Paladini; G. Sglavo; G. Pastore; A. Masucci; C. Nappi (Italy)</i>	OC02.04
09:49	Discussion	
09:52	Chromosomal anomalies in isolated fetal aberrant right subclavian artery <i>O. Gómez; J. Martínez; A. Olivella; M. Bennasar; B. Puerto; E. Gratacós (Spain)</i>	OC02.05
09:57	Discussion	

09:00–10:00	Short-term outcome in fetal growth restriction	Forum hall
	<i>Chairs: A. Baschat (United States); A. Papageorghiou (United Kingdom)</i>	
09:00	Overview <i>A. Baschat (United States)</i>	
09:05	Assessment of a modified fetal myocardial performance index and radial ventricular synchrony by tissue Doppler imaging in growth-restricted fetuses <i>R. Schmitz; J. Heinig; L. Kiesel; J. Steinhard (Germany)</i>	OC03.01 and OC03.02
09:10	Discussion	
09:13	Cardiac dysfunction is present in small-for-gestational age fetuses with normal umbilical artery Doppler <i>F. Crispi; M. Comas; R. Cruz-Martinez; J. Martinez; E. Eixarch; F. Figueras; E. Gratacós (Spain)</i>	OC03.03
09:18	Discussion	
09:21	Natriuretic peptide levels in severe IUGR fetuses <i>B. Franz; S. Spahn; R. Gallinat (Germany)</i>	OC03.04
09:26	Discussion	
09:29	Effects of antenatal identification on perinatal outcomes in small for gestational age infants delivered after 34 weeks' gestation <i>N. Fratelli; A. Valcamonico; F. Prefumo; G. Pagani; T. Guarneri; T. Frusca (Italy)</i>	OC03.05
09:34	Discussion	
09:37	Amnioinfusion and tocolysis before 26 weeks gestation for extremely severe fetal-growth restriction with oligohydramnios and long-term follow-up <i>Y. Takahashi; S. Iwagaki; R. Nishihara; T. Iwasa; K. Kigoshi; I. Kawabata (Japan)</i>	OC03.06
09:42	Discussion	
09:45	Prediction of emergency cesarean section for fetal distress after labor induction in term small-for-gestational-age fetuses with Doppler signs of brain sparing <i>R. Cruz-Martinez; F. Figueras; D. Oros; E. Hernandez-Andrade; E. Gratacós (Spain)</i>	OC03.07
09:50	Discussion	

09:00–10:00	Early pregnancy	Panorama hall
	<i>Chairs: E. Kirk (United Kingdom); S Goldstein (United States)</i>	
09:00	Early embryonic development and pregnancy <i>H Blass (Norway)</i>	
09:15	^ Comparing singleton and twin embryo volumes <i>S. Sur; J. Clewes; N. Raine-Fenning (United Kingdom)</i>	OC04.01
09:20	Discussion	

\* Scientific content of live scan sessions is defined by ISUOG. Ultrasound systems and technical support are provided by sponsors.

^ This abstract has been shortlisted as a finalist for the Alfred Kratochwil 3D abstract award. The winner will be announced at the closing ceremony.

# Program – Monday 11 October 2010

09:23	Intra- and inter-observer reproducibility of first trimester measurements between 6 and 9 weeks gestation <i>A. Pexsters<sup>1</sup>; J. Luts<sup>1</sup>; D. Van Schoubroeck<sup>1</sup>; C. Bottomley<sup>2</sup>; B. Van Calster<sup>1</sup>; S. Van Huffel<sup>1</sup>; Y. Abdallah<sup>2</sup>; T. D'Hooghe<sup>1</sup>; C. Lees<sup>2</sup>; D. Timmerman<sup>1</sup>; T. Bourne<sup>1,2</sup></i> <i><sup>1</sup>(Belgium); <sup>2</sup>(United Kingdom)</i>	OC04.02
09:28	Discussion	
09:31	Risk factors for tubal versus non-tubal ectopic pregnancies: a multicentre case series <i>H. May-Miller<sup>1</sup>; C. Bottomley<sup>2</sup>; E. Kirk<sup>1</sup>; K. Hayes<sup>1</sup>; C. Stalder<sup>1</sup>; D. Timmerman<sup>2</sup>; T. Bourne<sup>1</sup></i> <i><sup>1</sup>(United Kingdom); <sup>2</sup>(Belgium)</i>	OC04.03
09:36	Discussion	
09:39	The influence of pre-pregnancy BMI and maternal weight gain in pregnancy on fetal size at 12 weeks: a cross-sectional analysis <i>Y. Abdallah<sup>1</sup>; A. Pexsters<sup>2</sup>; J. Luts<sup>2</sup>; O. Najj<sup>1</sup>; I. Guelinckx<sup>2</sup>; R. Devlieger<sup>2</sup>; E. Kirk<sup>1</sup>; R. Husicka<sup>1</sup>; C. Bottomley<sup>1</sup>; C. Lees<sup>1</sup>; D. Timmerman<sup>2</sup>; T. Bourne<sup>1,2</sup></i> <i><sup>1</sup>(United Kingdom); <sup>2</sup>(Belgium)</i>	OC04.04
09:44	Discussion	
09:47	A longitudinal assessment of gestation sac growth in pregnancies subsequently shown to be viable and non-viable <i>A. Pexsters<sup>1</sup>; A. Daemen<sup>1</sup>; C. Bottomley<sup>2</sup>; Y. Abdallah<sup>2</sup>; O. Najj<sup>2</sup>; N. Raine-Fenning<sup>2</sup>; B. De Moor<sup>1</sup>; T. D'Hooghe<sup>1</sup>; D. Timmerman<sup>1</sup>; T. Bourne<sup>1,2</sup></i> <i><sup>1</sup>(Belgium); <sup>2</sup>(United Kingdom)</i>	OC04.05
09:52	Discussion	
09:55	Summary <i>E. Kirk (United Kingdom)</i>	

## 10:00–10:40 Short oral presentation (OP) sessions

### 10:40–10:55 Posters (P): author questions

10:00	<b>OP01: IUGR I: diagnosing and managing fetal growth restriction</b>	Forum hall
10:40	<b>P01: IUGR I: outcome in placental dysfunction</b> <i>Chairs: E. Hernandez-Andrade (Mexico); C. Lees (United Kingdom)</i>	
10:00	<b>OP02: Early pregnancy I</b>	Panorama hall
10:40	<b>P02: Early pregnancy I</b> <i>Chairs: G. Condous (Australia); A. Pexsters (Belgium)</i>	
10:00	<b>OP03: Fetal heart I: screening for congenital heart disease</b>	North hall
10:40	<b>P03: Fetal heart I: fetal cardiac anomalies</b> <i>Chairs: J. Copel (United States); C. Berg (Germany)</i>	
10:00	<b>OP04: First trimester I: screening for aneuploidy</b>	Club A
10:40	<b>P04: First trimester I: aneuploidy and other complications</b> <i>Chairs: C. Bilardo (Netherlands); T. Lau (China)</i>	
10:00	<b>OP05: CNS I: fetal brain MRI</b>	Club E
10:40	<b>P05: CNS I: fetal brain MRI</b> <i>Chairs: S. Yagel (Israel); A. Toi (Canada)</i>	

## 10:30–11:00 Coffee and electronic poster viewing Exhibition area

## 11:00–12:30 Workshop: advanced fetal echocardiography: atrial isomerism (heterotaxy) Congress hall

	<i>Chairs: J. Carvalho (United Kingdom); C. Berg (Germany)</i>	
11:00	Live scan demonstration: isomerism: sequential analysis in practice (supported by Medison*) <i>J. Carvalho (United Kingdom)</i>	
11:15	Right atrial isomerism: common cardiac abnormalities and ultrasound cases <i>L. Allan (United Kingdom)</i>	
11:30	Left atrial isomerism: common cardiac abnormalities and ultrasound cases <i>J. Carvalho (United Kingdom)</i>	
11:45	Early diagnosis and arrhythmias <i>U. Gembruch (Germany)</i>	
12:00	3D/4D echo of venous connections <i>S. Yagel (Israel)</i>	
12:15	Panel discussion	

## 11:00–12:30 Workshop: identifying risk in monochorionic twin pregnancy Forum hall

	<i>Chairs: Y. Ville (France); J. Deprest (Belgium)</i>	
11:00	Early prediction of twin-twin transfusion syndrome <i>L. Lewi</i>	

# Program – Monday 11 October 2010

11:15	Twin-twin transfusion syndrome: diagnosis and management <i>K. Hecher (Germany)</i>
11:30	Twin-anemia-polycythemia sequence: diagnosis and management <i>J. Deprest (Belgium)</i>
11:45	Discordant growth in monochorionic twins: diagnosis and management <i>E. Gratacós (Spain)</i>
12:00	Live scan (supported by Toshiba*) <i>Y. Ville (France)</i>
12:20	Discussion

## 11:00–12:30 Workshop: ISUOG Outreach

Club A

	<i>Chair: A. Abuhamad (United States)</i>
11:00	Introduction <i>A. Abuhamad (United States)</i>
11:05	Maternal mortality in the developing world and the role of ultrasound <i>A. Abuhamad (United States)</i>
11:20	Ultrasound Outreach: challenges and opportunities <i>S. Marsh (United States)</i>
11:35	Workshop group discussions: sustainable outreach: prioritising, funding and evaluating <i>Groups led by: A. Abuhamad (United States), S. Eik-Nes (Norway), A. Tabor (Denmark), D. Paladini (Italy), S. Marsh (United States)</i>
12:10	Presentation of workshop findings

## 11:00–12:30 Ultrasound and the acute gynecology patient

Panorama hall

	<i>Chairs: T. Bourne (United Kingdom); C. Exacoustos (Italy)</i>	
11:00	Applying mathematical models to different patient populations and in different countries – when is a PUL not a PUL? <i>E. Kirk (United Kingdom)</i>	
11:20	Reducing the follow-up required in women with a failing pregnancy of unknown location <i>W. Hoo<sup>1</sup>; C. Bottomley<sup>1</sup>; B. Van Calster<sup>2</sup>; Y. Abdallah<sup>1</sup>; O. Naji<sup>1</sup>; C. Stalder<sup>1</sup>; S. Ahmed<sup>1</sup>; D. Gould<sup>1</sup>; S. Hollamby<sup>1</sup>; E. Kirk<sup>1</sup>; D. Timmerman<sup>2</sup>; T. Bourne<sup>1,2</sup></i> <sup>1</sup> (United Kingdom); <sup>2</sup> (Belgium)	OC05.01
11:25	Discussion	
11:28	Surgical treatment of first trimester cervical ectopic pregnancies <i>J. Ben-Nagi; D. Mavrellos; J. Naftalin; J. Ross; D. Jurkovic (United Kingdom)</i>	OC05.02
11:33	Discussion	
11:36	Caesarean scar pregnancy: diagnosis and ultrasound-guided methotrexate treatment <i>L. Wang; H. Xu; J. Wang; X. Gao; Q. Lin; Q. Cui; Z. Yuan; X. Chen (China)</i>	OC05.03
11:41	Discussion	
11:44	Does symptomatology at presentation correlate with successful expectant management of first trimester miscarriage? <i>I. Casikar<sup>1</sup>; C. Lu<sup>2</sup>; J. Riemke<sup>1</sup>; S. Reid<sup>1</sup>; D. Alhamdan<sup>1</sup>; T. Bignardi<sup>1</sup>; M. Mongelli<sup>1</sup>; G. Condous<sup>1</sup></i> <sup>1</sup> (Australia); <sup>2</sup> (United Kingdom)	OC05.04
11:49	Discussion	
11:52	Endometrial volume measurements by transvaginal 3-dimensional ultrasound for the prediction of outcome in the pregnancies of unknown location <i>T. Bignardi; D. Alhamdan; M. Mongelli; G. Condous (Australia)</i>	OC05.05
11:57	Discussion	
12:00	Why are some ectopic pregnancies characterized as pregnancies of unknown location at initial transvaginal ultrasound scan? 3D volumetric TVS of ectopic pregnancy mass <i>D. Alhamdan; M. Mongelli; I. Casikar; T. Bignardi; S. Reid; J. Riemke; G. Condous (Australia)</i>	OC05.06
12:05	Discussion	
12:08	Gestation sac shape, sub-chorionic haematoma and vaginal bleeding as predictors of viability in intrauterine pregnancies of uncertain viability <i>O. Naji<sup>1</sup>; Y. Abdallah<sup>1</sup>; A. Daemen<sup>2</sup>; A. Pexsters<sup>2</sup>; C. Stalder<sup>1</sup>; C. Bottomley<sup>1</sup>; E. Kirk<sup>1</sup>; N. Raine-Fenning<sup>1</sup>; C. Lees<sup>1</sup>; D. Timmerman<sup>2</sup>; T. Bourne<sup>1,2</sup></i> <sup>1</sup> (United Kingdom); <sup>2</sup> (Belgium)	OC05.07
12:13	Discussion	
12:16	Outcome of the 1st trimester of intrauterine pregnancies of uncertain viability (IPUVIs) <i>J. Riemke<sup>1</sup>; C. Lu<sup>2</sup>; T. Bignardi<sup>1</sup>; I. Casikar<sup>1</sup>; D. Alhamdan<sup>1</sup>; S. Reid<sup>1</sup>; M. Mongelli<sup>1</sup>; D. Fauchon<sup>1</sup>; R. Benzie<sup>1</sup>; G. Condous<sup>1</sup></i> <sup>1</sup> (Australia); <sup>2</sup> (United Kingdom)	OC05.08
12:21	Discussion	
12:24	Summary <i>T. Bourne (United Kingdom)</i>	

\* Scientific content of live scan sessions is defined by ISUOG. Ultrasound systems and technical support are provided by sponsors.



## Satellite Symposium

organized by Philips Healthcare

### “Revolutions in Ultrasound Technology for Revelations in Patient Care”

Monday 11 October 2010, 12:45 – 13:45

Location: Congress Hall

Chairman:

Prof. K. Kalache, Charite University Hospital, Berlin, D

### PureWave in Gynecology – Seeing is believing

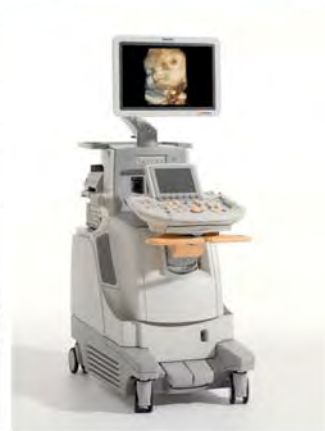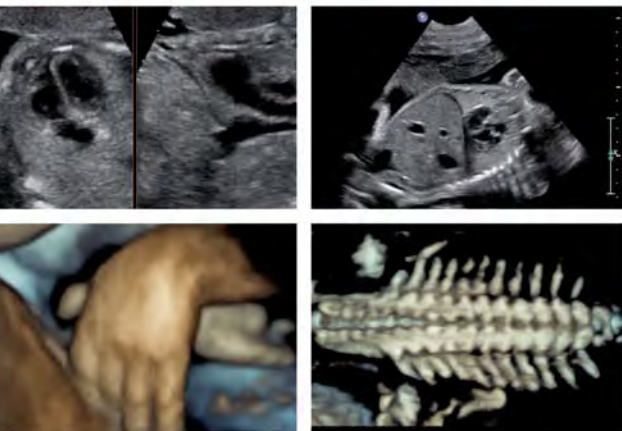
Dr. E. Epstein, Karolinska University Hospital, Stockholm, S

### Putting iU22 xMATRIX Technology & PureWave Transducers to the test

Dr. B. Tutschek, Inselspital University Hospital, Bern, CH

### The fetal heart and new ways to explore it with the iU22 xMATRIX

Dr. W. Lee, W. Beaumont Hospital, Royal Oak, USA



# Revolutions in Ultrasound Technology for Revelations in Patient Care

The new Philips iU22 **X**MATRIX ultrasound system is a revolutionary imaging system that will forever change the way you view ultrasound as a clinical tool. Now you can see more clearly, explore more fully, and resolve more thoroughly. Now you can be sure.

Come and join us at the Satellite Symposium to hear more about our revolutionary xMATRIX solution and PureWave Technology – and make sure you visit us at our booth.

**PHILIPS**  
sense and simplicity

# Program – Monday 11 October 2010

12:30	Lunch and volunteer recruitment	
12:30–14:00	Lunch and electronic poster viewing	Exhibition area
12:45–13:45	<b>Philips satellite symposium**</b>	<b>Congress hall</b>
	Revolutions in ultrasound technology for revelations in patient care	
14:00–15:00	<b>First trimester</b>	<b>Congress hall</b>
	Chairs: <i>A. Tabor (Denmark); J. Sonek (United States)</i>	
14:00	Overview <i>A. Tabor (Denmark)</i>	
14:05	Live scan demonstration: the first trimester scan (supported by Medison*) <i>C. Bilardo (Netherlands)</i>	
14:20	PAPP-A and free $\beta$ -hCG measured before 10+0 weeks is associated with adverse pregnancy outcomes <i>I. Kirkegaard; T. Henriksen; N. Uldbjerg (Denmark)</i>	OC06.01
14:25	Discussion	
14:28	The 'evanescent pelvic translucency': a major finding of anal atresia in the first trimester <i>J. Bault<sup>1</sup>; B. Benoit<sup>2</sup>; L. Loeuillet<sup>1</sup>; M. Moulis<sup>1</sup>; R. Achiron<sup>3</sup></i> <sup>1</sup> (France); <sup>2</sup> (Monaco); <sup>3</sup> (Israel)	OC06.02
14:33	Discussion	
14:36	Shortening fraction of the right ventricle (SFRV) – a potential ultrasound marker of trisomy 21 between 11 and 13+6 weeks' gestation <i>P. Calda<sup>1</sup>; M. Brestak<sup>1</sup>; V. Tomek<sup>1</sup>; D. McKenna<sup>2</sup>; J. Sonek<sup>2</sup></i> <sup>1</sup> (Czech Republic); <sup>2</sup> (United States)	OC06.03
14:41	Discussion	
14:44	The underlying variability in first trimester individual risk for Down syndrome <i>J. Stirnemann; J. Bernard; Y. Ville (France)</i>	OC06.04
14:49	Discussion	
14:52	Increased nuchal translucency and normal karyotype: perinatal and pediatric outcome at 2 years of age <i>R. Mula; A. Goncá; M. Arigita; M. Bennàsar; F. Botet; A. Borrell; E. Gratacós (Spain)</i>	OC06.05
14:57	Discussion	
14:00–15:00	<b>Twin–twin transfusion syndrome</b>	<b>Forum hall</b>
	Chairs: <i>A. Gagnon (Canada); J. Deprest (Belgium)</i>	
14:00	Overview <i>A. Gagnon (Canada)</i>	
14:05	Stage I twin-twin transfusion syndrome: to laser or not to laser Argument for: <i>Y. Ville (France)</i> Argument against: <i>A. Johnson (United States)</i>	
14:20	Myocardial deformation analysis using Vector Velocity Imaging in twin–twin transfusion syndrome: differences in myocardial mechanics between donor and recipient <i>S. Zeng; Z. Tian; M. Bebbington; M. Johnson; J. Rychik (United States)</i>	OC07.01
14:25	Discussion	
14:28	Fetoscopic laser surgery for twin-twin transfusion syndrome after 26 weeks of gestation <i>D. Valsky<sup>1,2</sup>; E. Eixarch<sup>1</sup>; I. Gonzalez<sup>1</sup>; F. Crispit<sup>1</sup>; R. Cruz-Martinez<sup>1</sup>; M. Sanz-Cortes<sup>1</sup>; M. Illa<sup>1</sup>; J. Martinez<sup>1</sup>; E. Gratacós<sup>1</sup></i> <sup>1</sup> (Spain); <sup>2</sup> (Israel)	OC07.02
14:33	Discussion	
14:36	Learning curve for fetoscopic laser ablation therapy in severe twin–twin transfusion syndrome <i>R. Papanna<sup>1</sup>; L. Mann<sup>1</sup>; D. Biau<sup>2</sup>; K. Moise Jr<sup>1</sup>; A. Johnson<sup>1</sup></i> <sup>1</sup> (United States); <sup>2</sup> (France)	OC07.03
14:41	Discussion	
14:44	Pattern of cardiovascular disease regression following fetoscopic selective laser photocoagulation for twin–twin transfusion syndrome <i>J. Rychik; M. Bebbington; M. Johnson; S. Zeng; Z. Tian (United States)</i>	OC07.04
14:49	Discussion	
14:52	Incidence and clinical implications of unintended septostomy after fetoscopic laser therapy for twin–twin transfusion syndrome <i>R. Cruz-Martinez<sup>1</sup>; T. Van Mieghem<sup>2</sup>; L. Lew<sup>2</sup>; E. Eixarch<sup>1</sup>; J. Deprest<sup>2</sup>; E. Gratacós<sup>1</sup></i> <sup>1</sup> (Spain); <sup>2</sup> (Belgium)	OC07.05
14:57	Discussion	

\* Scientific content of live scan sessions is defined by ISUOG. Ultrasound systems and technical support are provided by sponsors.

\*\* Luncheon satellite symposia are brought to you by our sponsors and are not part of the ISUOG CME program. ISUOG takes no responsibility for scientific or clinical content.

# Program – Monday 11 October 2010

<b>14:00–15:00</b>		<b>Abnormal uterine bleeding</b>	<b>Panorama hall</b>
		<i>Chairs: H. Brölman (Netherlands); E. Ferrazzi (Italy)</i>	
14:00		Establishing universal terms and definitions to describe endometrial pathology <i>T. Van den Bosch (Belgium)</i>	
14:20		Discussion	
14:23		Differentiation of uterine pathology by transvaginal elastography: preliminary results <i>J. Veldman<sup>1</sup>; C. Van Holsbeke<sup>1</sup>; E. Werbrouck<sup>1</sup>; T. Bourne<sup>1,2</sup>; D. Timmerman<sup>1</sup></i> <i><sup>1</sup>(Belgium); <sup>2</sup>(United Kingdom)</i>	OC08.01
14:28		Discussion	
14:31		The role of transvaginal ultrasound during resectoscopic myomectomy <i>P. Casadio; T. Ghi; D. De Angelis; E. Spagnolo; L. Savelli; A. Youssef; M. Talamo; M. Rizzo; V. Milano; G. Pelusi (Italy)</i>	OC08.02
14:36		Discussion	
14:39		Comparison of the fundal transverse endometrial diameters using 3D rendered images for those with embedded and normally placed IUDs <i>T. Shipp; B. Bromley; B. Benacerraf (United States)</i>	OC08.03
14:44		Discussion	
14:47		Sonohysterography with constant infusion pressure in the assessment of myomas qualified to hysteroscopic myomectomy <i>A. Ludwin; I. Ludwin; P. Basta; A. Knafel; T. Banas; A. Basta (Poland)</i>	OC08.04 and OC08.05
14:52		Discussion	
14:55		Summary <i>H. Brölman (Netherlands)</i>	
<b>15:00–15:40</b>		<b>Short oral presentation (oral poster) sessions</b>	
<b>15:40–16:00</b>		<b>Electronic posters: author questions</b>	
15:00		<b>OP06: Multiple pregnancy I: twin–twin transfusion syndrome</b>	Forum hall
15:40		<b>P06: Multiple pregnancy I: monochorionic twins</b> <i>Chairs: A. Gagnon (Canada); K. Hodík (Czech Republic)</i>	
15:00		<b>OP07: Abnormal uterine bleeding</b>	Panorama hall
15:40		<b>P07: Abnormal uterine bleeding</b> <i>Chairs: E. Epstein (Sweden); T. Van den Bosch (Belgium)</i>	
15:00		<b>OP08: Fetal heart II: new techniques to assess cardiac function</b>	North hall
15:40		<b>P08: Fetal heart II: 3D/4D &amp; STIC</b> <i>Chairs: A. Abuhamad (United States); F. Crispi (Spain)</i>	
15:00		<b>OP09: Screening for trisomy 21</b>	Club A
15:40		<b>P09: Unusual syndromes</b> <i>Chairs: A. Tabor (Denmark); L. Krofta (Czech Republic)</i>	
15:00		<b>OP10: Imaging technologies I</b>	Club E
15:40		<b>P10: Imaging technologies I</b> <i>Chairs: E. Hernandez-Andrade (Mexico); I. Zador (United States)</i>	
<b>15:40–16:10</b>		<b>Coffee and electronic poster viewing</b>	<b>Exhibition area</b>
<b>16:00–17:30</b>		<b>Workshop: advanced fetal neurosonography</b>	<b>Congress hall</b>
		<i>Chairs: G. Pilu (Italy); I. Timor-Tritsch (United States)</i>	
16:00		Sonoembryology and early diagnosis of fetal anomalies <i>H. Blaas (Norway)</i>	
16:15		Cleavage abnormalities of the telencephalon: from holoprosencephaly to septo-optic dysplasia <i>K. Kalache (Germany)</i>	
16:30		Live scan demonstration: early 3D assessment of CNS (supported by Siemens*) <i>I. Timor-Tritsch (United States)</i>	
16:50		Posterior fossa abnormalities <i>L. Guibaud (France)</i>	
17:05		Normal and abnormal cortical development <i>G. Malinger (Israel)</i>	
17:20		Limitations of prenatal ultrasound – panel discussion	



# Program – Monday 11 October 2010

## 16:00–17:30 Workshop: practical new tools in fetal echocardiography Forum hall

- Chairs: D. Paladini (Italy); R. Chaoui (Germany)*
- 16:00 Live scan demonstration: tools used in fetal echo: abdominal, transvaginal, grey-scale, m-mode, colour Doppler and 3D (supported by Philips\*)  
*W. Lee (United States)*
- 16:20 Four-chamber view anomalies: 2D, colour and 3D  
*D. Paladini (Italy)*
- 16:35 Outflow tract anomalies: 2D, colour and 3D  
*R. Chaoui (Germany)*
- 16:50 Aortic arch anomalies: 2D, colour and 3D  
*R. Chaoui (Germany)*
- 17:05 The fetal venous system: 2D, colour and 3D cardiac and related syndromes: what is the leading sign? Outcome of fetal CHD: what are the fetal findings related to outcome?  
*B. Tutschek (Switzerland)*
- 17:20 Discussion

## 16:00–17:30 Workshop: early pregnancy complications Panorama hall

- Chairs: S. Goldstein (United States); T. Bourne (United Kingdom)*
- 16:00 Diagnosing and managing miscarriage  
*C. Bottomley (United Kingdom)*
- 16:20 Practical management strategies for PUL  
*E. Kirk (United Kingdom)*
- 16:40 Diagnosing and managing ectopic pregnancy  
*G. Condous (Australia)*
- 17:00 Case examples and just images  
*C. Bottomley (United Kingdom)*
- 17:08 Case examples and just images  
*G. Condous (Australia)*
- 17:16 Case examples and just images  
*E. Kirk (United Kingdom)*
- 17:24 Summary  
*T. Bourne (United Kingdom)*

## 16:00–17:30 Workshop: doing it safely Club A

- Chairs: K. Salvesen (Norway); M. Claudon (France)*
- 16:00 Live scan demonstration: physical mechanisms of ultrasound acoustic streaming (supported by Siemens\*)  
*G. Ter Haar (United Kingdom)*
- 16:20 MI and TI: machine settings in Europe and the US today  
*G. Ter Haar (United Kingdom)*
- 16:35 What does the user know? (supported by Siemens\*)  
*K. Maršál (Sweden)*
- 16:50 Live scan demonstration: what happens with MI/TI output when you alter machine settings? (supported by Siemens\*)  
*C. Lees (United Kingdom)*
- 17:10 WFUMB statement on Doppler at 11–14 weeks scan  
*M. Claudon*
- 17:20 Discussion

17:50–18:35 **'All you ever wanted to know' afternoon sessions must be pre-booked at the registration desk. See page 11 for details**

# Short oral presentations – Monday 11 October 2010

**Chaired short oral presentation (oral poster) sessions: 10:00–10:40**

**Viewing available all week on E-poster viewing stations located in the level 2 foyer**

## **OP01: IUGR I: diagnosing and managing fetal growth restriction**

*Chairs: E. Hernandez-Andrade (Mexico); C. Lees (United Kingdom)*

	Abstract number
	<b>Forum hall</b>
Association between lung and cerebral blood perfusion with the degree of placental insufficiency in early-onset intrauterine growth restricted fetuses <i>R. Cruz-Martinez (Spain)</i>	OP01.01
Splenic artery and the left portal vein Doppler flow velocimetry in growth-compromised fetuses <i>N. Vedmedovska (Latvia)</i>	OP01.02
Predictiveness of umbilical vein blood flow assessment at routine third-trimester scan for smallness-for-gestational age at birth <i>S. Fernández (Spain)</i>	OP01.03
Biochemical prenatal tests and uterine artery Doppler examination in prediction of PIH and IUGR in the third trimester of pregnancy <i>P. Sieroszewski (Poland)</i>	OP01.04
Sequence of changes in myocardial performance index, aortic isthmus, and ductus venosus Doppler in early-onset intrauterine growth restricted fetuses <i>R. Cruz-Martinez (Spain)</i>	OP01.05
Cardiovascular parameters in the prediction of mortality in early-onset intrauterine growth restriction <i>M. Cruz Lemini (Spain)</i>	OP01.06
Comparison of obstetrical and perinatal outcomes in gestations with an EFW below 10th percentile depending on admission or not to neonatal unit <i>E. Mazarico (Spain)</i>	OP01.07
Neonatal outcome in intrauterine growth restricted and small for gestational age fetuses <i>E. Cosmi (Italy)</i>	OP01.08
Perinatal outcomes in gestations with intrauterine growth restriction and small for gestational age foetuses, admitted to neonatal unit <i>M. Gómez Roig (Spain)</i>	OP01.09
Intrauterine growth restriction, small for gestational age and postnatal growth at twelve and twenty four months of life <i>L. García De Miguel (Spain)</i>	OP01.10

## **OP02: Early pregnancy I**

*Chairs: G. Condous (Australia); A. Pexsters (Belgium)*

	Abstract number
	<b>Panorama hall</b>
New model to predict viability at the end of the 1st trimester for IPUVIs after a single visit to an EPU – preliminary results <i>J. Riemke (Australia)</i>	OP02.01
The K-P algorithm: a new 1st trimester growth model <i>M. Mongelli (Australia)</i>	OP02.02, OP02.03, OP02.04
3D Doppler ultrasonography in asymptomatic and symptomatic women after medical termination of pregnancy <i>M. Ghosh (United Kingdom)</i>	OP02.05
Retrospective study on molar pregnancy in a district general hospital over a period of two years <i>S. Sankaran (United Kingdom)</i>	OP02.06
Ectopic pregnancy: how accurate is ultrasound in the diagnosis <i>P. Ramanathan (United Kingdom)</i>	OP02.07
Can we avoid laparoscopy in most ectopic pregnancies? The experience of our Early Pregnancy Unit <i>D. Alhamdan (Australia)</i>	OP02.08
Variations in the standard of care of women with ectopic pregnancy <i>E. Kirk (United Kingdom)</i>	OP02.09
Prediction of pregnancy viability by means of scoring systems: towards a 'risk of miscarriage' index <i>C. Bottomley (United Kingdom)</i>	OP02.10
The effect of BMI on first trimester CRL growth: a longitudinal analysis <i>Y. Abdallah (United Kingdom)</i>	OP02.11
Can serum progesterone predict change in $\beta$ -hCG in women who present in early pregnancy? <i>J. Hamilton (United Kingdom)</i>	OP02.12

## **OP03: Fetal heart I: screening for congenital heart disease**

*Chairs: J. Copel (United States); C. Berg (Germany)*

	Abstract number
	<b>North hall</b>
Fetal cardiac axis and congenital heart defects in early gestation <i>E. Sinkovskaya (United States)</i>	OP03.01
First trimester cardiac morphology and diagnosis of cardiac defects using high-definition blood flow imaging mode <i>M. Bellotti (Italy)</i>	OP03.02
Cardiac structures at less than 16 weeks gestation are enlarged in the fetus with 1st trimester increased nuchal translucency <i>J. Rychik (United States)</i>	OP03.03
Detection of congenital heart defects in the first trimester: prospective study <i>M. Eleftheriades (Greece)</i>	OP03.04
Quality control of routine second trimester four chamber view: comparison of six strategies relying on minimally trained reviewers <i>J. Nizard (France)</i>	OP03.05

# Short oral presentations – Monday 11 October 2010

	Abstract number
Learning curve and factors influencing the feasibility of performing fetal echocardiography at the time of the first trimester scan <i>R. Abu-Rustum (Lebanon)</i>	OP03.06
Echocardiographic and sonographic markers of fetal Turner syndrome in second half of pregnancy <i>K. Janiak (Poland)</i>	OP03.07
Congenital cardiac lesions: prenatal readings vs. outcomes <i>N. Trivedi (United States)</i>	OP03.08
Right aortic arch (RAA) is a powerful marker for fetal cardiovascular anomaly screening <i>M. Kawataki (Japan)</i>	OP03.09
<b>OP04: First trimester I: screening for aneuploidy</b>	<b>Club A</b>
<i>Chairs: C. Bilardo (Netherlands); T. Lau (China)</i>	
Impact of a level shift downward in measurement of PAPP-A concentration on the screening performance of first-trimester screening for Down syndrome <i>P. van Heesch (Netherlands)</i>	OP04.01
First-trimester screening: do weight corrected free beta-HCG and PAPP-A values result in a significant higher detection rate of trisomy 21? <i>E. Merz (Germany)</i>	OP04.02
Pitfalls in modeling the individual risk of Down syndrome by age and nuchal translucency <i>J. Stirmann (France)</i>	OP04.03
<sup>A</sup> First-trimester assessment of the nasal bones using the retranasal triangle view: a three-dimensional sonographic study <i>M. Adiego (Spain)</i>	OP04.04
Public 1st and 2nd trimester prenatal screening to all women: participation and satisfaction in a Danish region <i>O. Petersen (Denmark)</i>	OP04.05
Implementation of first trimester screening in a population with a prior screening strategy – population based cohort study <i>P. Calda (Czech Republic)</i>	OP04.06
Simplified protocol of nuchal translucency measurement: is it effective? <i>S. Kim (South Korea)</i>	OP04.07
Prenatal screening for Down syndrome: predictive value according to the different strategies implemented <i>C. Comas (Spain)</i>	OP04.08
Gender distribution in fetuses undergoing invasive testing due to a high risk of Down syndrome <i>C. Winther (Denmark)</i>	OP04.09
Karyotype and outcome of fetuses diagnosed with cystic hygroma in the first trimester: retrospective multicenter study in South Korea <i>S. Lee (South Korea)</i>	OP04.10
<b>OP05: CNS I: fetal brain MRI</b>	<b>Club E</b>
<i>Chairs: S. Yagel (Israel); A. Toi (Canada)</i>	
The value of prenatal ultrasound and MR imaging in the assessment of congenital primary CMV infection <i>S. Lipitz (Israel)</i>	OP05.01
The importance of specialized, international internet consultations for diagnosis of brain anomalies <i>G. Malinger (Israel)</i>	OP05.02
Congenital toxoplasmosis: prenatal imaging as demonstrated by neurosonography and MRI <i>G. Malinger (Israel)</i>	OP05.03
Evaluation of the curvature of fetal corpus callosum using MRI <i>R. Hershkovitz (Israel)</i>	OP05.04
Validity and reliability of fetal brain MRI in ventricular volume measurement <i>P. Nowak (Brazil)</i>	OP05.05
Advanced fetal 3D MR imaging in callosal agenesis <i>G. Kaspran (Austria)</i>	OP05.06
Isolated borderline ventriculomegaly: correlation between antenatal and postnatal MRI and perinatal outcome <i>G. Tonni (Italy)</i>	OP05.07
The value of fetal magnetic resonance imaging and 3D sonography in the determination of the upper pole of the spina bifida at third trimester <i>S. Buyukkurt (Turkey)</i>	OP05.08
Prenatal diagnosis of middle ear hypoplasia in 2 cases of Treacher Collins syndrome and OAV spectrum using magnetic resonance imaging <i>E. Katorza (France)</i>	OP05.09

# Short oral presentations – Monday 11 October 2010

**Chaired short oral presentation (oral poster) sessions: 15:00–15:40**

**Viewing available all week on E-poster viewing stations located in the level 2 foyer**

Abstract number

## **OP06: Multiple pregnancy I: twin–twin transfusion syndrome**

**Forum hall**

*Chairs: A. Gagnon (Canada); K. Hodík (Czech Republic)*

A systematic review of first trimester nuchal translucency for the prediction of twin-to-twin transfusion syndrome

OP06.01

*F. Prefumo (Italy)*

Development of survival rates after intrauterine laser therapy for severe mid-trimester twin–twin transfusion syndrome: experience with 600 cases

OP06.02

*W. Diehl (Germany)*

The impact of access diameter at fetoscopic laser treatment of twin-twin transfusion syndrome

OP06.03

*S. Petersen (Australia)*

Fetoscopic entry technique at laser therapy for twin-twin transfusion syndrome affects rates of amniorrhexis and preterm birth before 32 weeks

OP06.04

*S. Petersen (Australia)*

Fetal weight and the outcome of twin-to-twin transfusion syndrome following fetoscopic laser surgery

OP06.05

*H. Sago (Japan)*

Assessment of fetal cardiac function in monochorionic diamniotic twin pregnancy by myocardial performance index

OP06.06

*J. Kuran (Poland)*

Cardiac function assessed by myocardial performance index fails to distinguish clear patterns between twin–twin transfusion syndrome and selective intrauterine growth restriction

OP06.07

*E. Eixarch (Spain)*

Effects of preload (UVF) on ductus venosus PI and MPI index in twin-twin transfusion syndrome

OP06.08

*M. Yamamoto (Chile)*

Impact of selective laser photocoagulation for twin–twin transfusion syndrome on myocardial deformation: strain and strain rate in the donor and recipient

OP06.09

*J. Rychik (United States)*

Selective cord coagulation in complicated monochorionic pregnancies: a single center experience

OP06.10

*M. Lanna (Italy)*

## **OP07: Abnormal uterine bleeding**

**Panorama hall**

*Chairs: E. Epstein (Sweden); T. Van den Bosch (Belgium)*

Diagnostic accuracy of sonohysterography with endometrial sampling in patients with AUB

OP07.01

*F. Leone (Italy)*

The added value of fluid instillation sonography in women with a total endometrial thickness  $\leq$  5mm at transvaginal ultrasound

OP07.02

*T. Van den Bosch (Belgium)*

3D-transvaginal sonography by VCI analysis to differentiate endometrial polyp and hyperplasia in pre-menopausal women

OP07.03

*F. Leone (Italy)*

The value of fluid instillation sonography in women under 40 years of age

OP07.04

*J. Veldman (Belgium)*

Three-dimensional ultrasound versus office hysteroscopy in assessment of pain and bleeding with intrauterine contraceptive device

OP07.05

*M. Aboulghar (Egypt)*

The influence of Mirena® position on the bleeding pattern after Mirena® insertion?

OP07.06

*D. Van Schoubroeck (Belgium)*

Hysteroscopic myomectomy for menorrhagia: efficacy and prognostic factors at a minimum of one year follow up

OP07.07

*T. Aojanepong (United Kingdom)*

Diagnostic value of 2D and 3D ultrasonography in the detection of intrauterine lesions

OP07.08

*B. Erdodi (Hungary)*

Initial clinical study of ultrasound-guided percutaneous microwave ablation of adenomyosis

OP07.09

*J. Zhang (China)*

Focused ultrasound surgery for conservative fibroids treatment

OP07.10

*H. Marret (France)*

## **OP08: Fetal heart II: new techniques to assess cardiac function**

**North hall**

*Chairs: A. Abuhamad (United States); F. Crispi (Spain)*

Assessment of fetal myocardial dynamics by using myocardial tissue Doppler velocity gradient

OP08.01

*B. Zhao (China)*

Assessment of fetal atrio-ventricular time intervals by tissue Doppler imaging in a transversal four-chamber-view

OP08.02

*J. Steinhard (Germany)*

Is it possible to obtain right ventricle MPI in one measure? The right ventricle MPI with 4DUS in healthy fetuses and pathological cases

OP08.03

*B. Messing (Israel)*

Propriety of the left and right myocardial performance index for cardiac function in normal fetuses

OP08.04

*J. Lee (South Korea)*

Fetal left myocardial performance (Tei) index: improving reproducibility using wall motion filter setting and peak of valve clicks

OP08.05

*N. Meriki (Australia)*

# Short oral presentations – Monday 11 October 2010

	Abstract number
Reproducibility of component time intervals measured by fetal pulse Doppler echocardiography for the fetal modified myocardial performance index <i>N. Meriki (Australia)</i>	OP08.06
The modified fetal myocardial performance (Tei) index in gestational diabetic mothers <i>N. Meriki (Australia)</i>	OP08.07
Speckle tracking imaging: a new 2D tool for the assessment of fetal cardiac function <i>R. Achiron (Israel)</i>	OP08.08
Quantification of regional atrial cardiac function of the fetal heart with velocity vector imaging <i>J. Steinhard (Germany)</i>	OP08.09
<b>OP09: Screening for trisomy 21</b>	<b>Club A</b>
<i>Chairs: A. Tabor (Denmark); L. Krofta (Czech Republic)</i>	
An association between uterine leiomyomas and the biochemical screening test results in the first and second trimester of pregnancy: a pilot study <i>P. Sieroszewski (Poland)</i>	OP09.01
How flat is the profile, measured with the MNM angle, in second and third trimester trisomy 21 fetuses? <i>E. de Jong-Pleij (Netherlands)</i>	OP09.02
Does fetal position in the second trimester fetuses affect nuchal fold values? <i>V. Holschbach (Germany)</i>	OP09.03
PT is 2/3 of NBL, this easy to use ratio is significant higher in trisomy 21 fetuses in the second and third trimester <i>E. de Jong-Pleij (Netherlands)</i>	OP09.04
Prenatal prediction of Down syndrome using prenatal thickness on second trimester ultrasound <i>T. Ozcan (United States)</i>	OP09.05
Dimensions of the fetal facial profile in fetuses with absent nasal bone. Preliminary report <i>F. Viñals (Chile)</i>	OP09.06
Risk of Down syndrome in neonates with duodenal obstruction or atrioventricular septal defects: is there a racial difference? <i>E. Im (South Korea)</i>	OP09.07
Second trimester amniocentesis is not a risk factor for very low birth weight and extremely low birth weight <i>C. Cani (Italy)</i>	OP09.08
Use of 3D ultrasound in visualization and measurement of nasal bone length and prenatal thickness in normal second and third trimester fetuses <i>E. de Jong-Pleij (Netherlands)</i>	OP09.09
3D ultrasound imaging and reproducibility of nasal bone length, prenatal thickness and fronto-maxillary facial angle in normal second and third trimester fetuses <i>E. de Jong-Pleij (Netherlands)</i>	OP09.10
<b>OP10: Imaging technologies I</b>	<b>Club E</b>
<i>Chairs: E. Hernandez-Andrade (Mexico); I. Zador (United States)</i>	
<sup>^</sup> In vitro perfusion of placental lobules to investigate a relationship between erythrocyte concentration and quantitative 3D power Doppler angiography <i>N. Raine-Fenning (United Kingdom)</i>	OP10.01
Reproducibility of placental blood perfusion assessment evaluated by time-averaged maximum perfusion <i>J. Benavides (Mexico)</i>	OP10.02
Fetal femur volume measurement using fusion of multiple three-dimensional ultrasound image sets: a pilot study <i>C. Ioannou (United Kingdom)</i>	OP10.03
In vitro models for fetal lung volumes – comparison of accuracies between 3D-ultrasound and magnetic resonance imaging <i>S. Kehl (Germany)</i>	OP10.04
Prenatal exposure to Doppler ultrasound waves in mice: results at short and long term exposure <i>W. Clavelli (Argentina)</i>	OP10.05
Influence of second trimester placental volume, shell volume and intraplacental circulation on birth weight <i>B. Yazdi (Germany)</i>	OP10.06
Sonoembryology: 3D ultrasound in comparison with human embryo specimens imaged by microscopy magnetic resonance <i>R. Ximenes (Brazil)</i>	OP10.07
Evaluation of the reliability of data acquisition for 3D ultrasound and power Doppler angiography of the whole placenta at 12 and 20 weeks gestation <i>N. Raine-Fenning (United Kingdom)</i>	OP10.08
A novel semi-automated (SA) technique for 3D ultrasound measurement of placental volume <i>G. Stevenson (United Kingdom)</i>	OP10.09

<sup>^</sup> This abstract has been shortlisted as a finalist for the Alfred Kratochwil 3D abstract award. The winner will be announced at the closing ceremony.

# Posters – Monday 11 October 2010

Poster question and answer sessions: 10:40–10:55

Viewing available all week on E-poster viewing stations located in the level 2 foyer

Abstract number

## P01: IUGR I: outcome in placental dysfunction

Forum hall

Unexplained elevations in maternal serum alpha-fetoprotein and risk of adverse outcomes <i>N. Deole (United Kingdom)</i>	P01.01
Perinatal outcome after detection of a fetal short femur <i>C. Martinez Payo (Spain)</i>	P01.02
Myometrial blood flow analysis in pregnant women with IUGR <i>T. Waseda (Japan)</i>	P01.03
Cerebroplacental pulsatility ratio predicts perinatal outcome in IUGR fetuses <i>T. Nanthakomom (Thailand)</i>	P01.04
The value of middle cerebral artery – umbilical artery pulsatility index ratio in prediction of severe fetal growth restriction <i>C. Somprasit (Thailand)</i>	P01.05
The value of Doppler alterations in IUGR premature babies' neonatal outcome from preeclamptic women <i>E. Dede (Albania)</i>	P01.06
Perinatal outcome of term small for gestational age infants: the impact of antenatal oligohydramnios <i>T. Kong (South Korea)</i>	P01.07
Neonatal outcomes after induction of labour in singleton term fetal growth restricted pregnancies with umbilical artery doppler velocity pulsatility index >95th centile <i>H. Samarage (United Kingdom)</i>	P01.08

## P02: Early pregnancy I

Panorama hall

Three-dimensional evaluation of the dominant ovary in the pregnancies of unknown location <i>D. Alhamdan (Australia)</i>	P02.01
Do intrauterine pregnancies of uncertain viability becoming viable after the 1st TVS behave differently to initially viable intrauterine pregnancies? <i>J. Riemke (Australia)</i>	P02.02
Longitudinal growth of MSD and CRL in intrauterine pregnancies of uncertain viability (IPUV) and its relationship to gestation sac shape <i>Y. Abdallah (United Kingdom)</i>	P02.03
Comparing the validity of 2 techniques for the measurement of embryo volume <i>S. Sur (United Kingdom)</i>	P02.04
Can we safely predict non-intervention in an ectopic pregnancy population: a new logistic regression model <i>I. Casikar (Australia)</i>	P02.05
Decidua basalis in spontaneous early pregnancy loss <i>H. Wong (Australia)</i>	P02.06
New logistic regression model compared to the type of miscarriage alone for the prediction of successful expectant management of miscarriage <i>I. Casikar (Australia)</i>	P02.07
Color Doppler ultrasound diagnosis of cesarean scar pregnancy: a report of twelve cases <i>F. Xia (China)</i>	P02.08
Decidua basalis in the first trimester of normal pregnancy <i>H. Wong (Australia)</i>	P02.09
A case of first trimester placenta increta following lysis of intrauterine adhesions: diagnosis and conservative management <i>M. Blanchette Porter (United States)</i>	P02.10
Conservative management of a complicated heterotopic triplet pregnancy with a cornual monochorionic twin pair <i>I. Timor-Tritsch (United States)</i>	P02.11
Management of cornual ectopic pregnancy <i>M. Elsheikh (United Kingdom)</i>	P02.12
A case of missed abortion with an incidental finding of a borderline tumour in a 30-year-old woman <i>S. Helmy (Austria)</i>	P02.13
Theca lutein cysts associated with singleton hydrops fetalis diagnosed by antenatal sonography <i>E. Park (South Korea)</i>	P02.14
Recurrent ectopic pregnancy in the tubal remnant stump after ipsilateral total salpingectomy <i>K. Kang (South Korea)</i>	P02.15
Selective transarterial embolization of uterine arteriovenous malformation complicated in previous Cesarean section scar pregnancy <i>Y. Kim (South Korea)</i>	P02.16
Ectopic pregnancy within a cesarean delivery scar: a case report <i>L. Rios (Brazil)</i>	P02.17

# Posters – Monday 11 October 2010

	Abstract number
<b>P03: Fetal heart I: fetal cardiac anomalies</b>	<b>North hall</b>
Prenatal diagnosis and outcome of congenital absent pulmonary valve syndrome associated with tetralogy of Fallot: report of two cases <i>J. Eom (South Korea)</i>	P03.01
Diagnosis of Taussig-Bing anomaly of the fetus at 20+3 weeks of the pregnancy <i>V. Tuimala (Finland)</i>	P03.02
A case of isolated congenital ductus arteriosus aneurysm detected by fetal heart sonography at 38 weeks of gestation <i>S. Oh (South Korea)</i>	P03.03
Prenatally diagnosed left ventricular diverticulum with thoracic wall defect <i>Y. Roh (South Korea)</i>	P03.04
Prenatal diagnosis of a fetal abdominal aortic aneurysm <i>R. Has (Turkey)</i>	P03.05
Congenital aneurysm and ventricular diverticulum of the fetal heart: myocardial defects with unequal appearance <i>J. Ritgen (Germany)</i>	P03.06
Scimitar syndrome diagnosis in the second trimester: case report <i>J. Bault (France)</i>	P03.07
Prenatal diagnosis of persistent left superior vena cava with absent right superior vena cava <i>C. Mckenna (United States)</i>	P03.08
Prenatal diagnosis of restrictive foramen ovale: a case report <i>R. Abu-Rustum (Lebanon)</i>	P03.09
Total anomalous pulmonary venous drainage (TAPVD): two cases prenatally detected in a routine screening setting <i>K. Tsujimura (Japan)</i>	P03.10
Prenatal diagnosis of heterotaxy syndrome at 13+5 weeks of gestation: a case report <i>A. Gerede (Greece)</i>	P03.11
Prenatal diagnosis of left superior vena cava draining into left atrium with absent right superior vena cava: a case report <i>T. Kaji (Japan)</i>	P03.12
Idiopathic fetal giant right atrium: pre- and post-natal outcome <i>C. Enzensberger (Germany)</i>	P03.13
Diagnosis of severe Ebstein's anomaly at 14 weeks following increased NT <i>J. Har-Toov (Israel)</i>	P03.14
The role of fetal heart assessment during first trimester scan <i>D. Ilic (Serbia)</i>	P03.15
Prenatal diagnosis and clinical management of congenital heart defects: the value of a multidisciplinary approach in a tertiary care center <i>P. Rosati (Italy)</i>	P03.16
ToF in a series of 40 cases in a fetal cardiology center in Lodz in years 1994-2009 <i>K. Janiak (Poland)</i>	P03.17
Prenatal diagnosis of heterotaxy syndrome: an 11-year experience <i>N. Hamasaka (Japan)</i>	P03.18
<b>P04: First trimester I: aneuploidy and other complications</b>	<b>Club A</b>
Value of including other ultrasound markers different to nuchal translucency to detect fetal aneuploidy at 11+0 to 13+6 weeks <i>G. Rencoret (Chile)</i>	P04.01
Can single three-dimensional ultrasound volume of the fetal head be used for measurement both of the facial angle and the nuchal translucency? <i>V. Frisova (Czech Republic)</i>	P04.02
Frontomaxillary facial angle at 11+0 to 13+6 weeks in the Chinese population <i>T. Lau (China)</i>	P04.03
Characterizing the 'iliac lucency' in the first trimester <i>R. Abu-Rustum (Lebanon)</i>	P04.04
Physical exercise decreases the number of fetal cells in maternal blood <i>J. Schlütter (Denmark)</i>	P04.05
3D assessment of the nuchal translucency and the fetal anatomy in the first trimester of pregnancy <i>P. Hiridis (Greece)</i>	P04.06
Low molecular weight heparins and first trimester maternal PAPP-A and hCG levels, fetal nuchal translucency in the first trimester of pregnancy <i>E. Tarim (Turkey)</i>	P04.07
Resolving access limitation to first trimester Down syndrome screening: is 3D nuchal translucency measurement combined with biochemical markers valid? <i>S. Wavrant (Canada)</i>	P04.08
Why absent flow during the atrial contraction of the ductus venosus Doppler must be considered as a positive marker of Down syndrome? <i>C. Murta (Brazil)</i>	P04.09
Frontomaxillary facial angle in chromosomally normal South Korean population at 11+0 to 13+6 weeks <i>H. Lee (South Korea)</i>	P04.10
Fetal nasal bone length nomogram among the Filipino population <i>M. Asumen-Bullo (Philippines)</i>	P04.11

# Posters – Monday 11 October 2010

	Abstract number
Current status of prenatal diagnosis of beta-thalassemia in Egyptian patients: a preliminary report <i>A. Elsheikhah (Egypt)</i>	P04.12
Fetal outcome with umbilical cord cyst diagnosed during nuchal translucency examination <i>Y. Gilboa (Israel)</i>	P04.13
Predictive values of first trimester PAPP-A and free beta hCG in screening of preeclampsia <i>I. Kalelioglu (Turkey)</i>	P04.14
Correlations between trophoblast thickness and spontaneous abortion – statistical study <i>N. Cernea (Romania)</i>	P04.15
Outcome of single umbilical artery in the first trimester ultrasound <i>Y. Jimenez (Spain)</i>	P04.16
Is a subchorionic haematoma a risk factor for unfavorable pregnancy outcome? <i>P. Szkodziak (Poland)</i>	P04.17
First trimester placental volume, uterine arteries Doppler, and biochemical markers for the prediction of preeclampsia <i>G. Daskalakis (Greece)</i>	P04.18

## P05: CNS I: fetal brain MRI

	<b>Club E</b>
Presence of intracranial translucency in a case of large open spina bifida <i>H. Belosovicova (Czech Republic)</i>	P05.01
The congenital dorsal dermal sinus – antenatal detection with 2D/3D ultrasound and postnatal evaluation with MRI and CT <i>I. Suchet (Canada)</i>	P05.02
Massive fetal intracranial hemorrhage in association with umbilical artery thrombosis <i>F. Lenz (Germany)</i>	P05.03
Fetal cystic scalp lesion – dermoid cyst over the anterior fontanel <i>Z. Leibovitz (Israel)</i>	P05.04
Prenatal diagnosis of the dural sinus malformation <i>Y. Kamei (Japan)</i>	P05.05
Monochorionic twins discordant for acrania with twin-twin transfusion syndrome <i>M. Thompson (United Kingdom)</i>	P05.06
Antenatal and postnatal evolution of a large posterior encephalocele <i>A. Kesrouani (Lebanon)</i>	P05.07
A case of fetal oropharyngeal immature teratoma <i>Y. Kim (South Korea)</i>	P05.08
Arachnoid cyst of posterior fossa: a case report <i>L. Coutinho (Portugal)</i>	P05.09
Colpocephaly in non-identical twin following IVF-ET: a case report <i>Y. Kang (South Korea)</i>	P05.10
Three cases of agenesis of the corpus callosum <i>O. Jo (Japan)</i>	P05.11
A case of sirenomelia and anencephaly in a 16 week fetus <i>M. Theodora (Greece)</i>	P05.12
Acute intracranial hemorrhage in a case with acute fetal CMV infection at 22 gestational weeks <i>K. Heling (Germany)</i>	P05.13

## Poster question and answer sessions: 15:40–16:00

Viewing available all week on E-poster viewing stations located in the level 2 foyer

## P06: Multiple pregnancy I: monochorionic twins

	Abstract number
Discordant nuchal translucency thickness in monochorionic twins may be an early finding of TTTS <i>K. Yamasaki (Japan)</i>	<b>Forum hall</b> P06.01
The values of prenatal surveillances of ultrasonography in twin pregnancies with amniotic fluid discordance <i>H. Wang (China)</i>	P06.02
Inter-twin crown – rump length discrepancy in monochorionic twins is an early feature of selective growth restriction rather than TTTS <i>A. Memmo (Italy)</i>	P06.03
Cerebral Doppler assessment in twin-twin transfusion syndrome <i>E. Antolin (Spain)</i>	P06.04
Hemodynamics of fetuses after fetoscopic laser surgery with twin-twin transfusion syndrome <i>M. Horiya (Japan)</i>	P06.05
Successive twin-twin transfusion syndrome developed in monochorionic triamniotic pregnancy <i>M. Yamamoto (Chile)</i>	P06.06
Twin-twin transfusion syndrome: perinatal outcome following amniodrainage management <i>N. Papantoniou (Greece)</i>	P06.07



# Posters – Monday 11 October 2010

	Abstract number
Twin-twin transfusion syndrome in Latin America: results from 5 centres in Brazil, Chile and Argentina <i>M. Yamamoto (Chile)</i>	P06.08
Fetoscopic laser treatment for twin-to-twin transfusion syndrome: preliminary results from a new Italian center <i>A. Fichera (Italy)</i>	P06.09
The first fetoscopic placental laser surgery for twin to twin transfusion syndrome in Egypt <i>M. Momtaz (Egypt)</i>	P06.10
TTTS followed by the recipient intrauterine fetal death and the donor right heart failure after selective fetoscopic laser photo-coagulation: a case report <i>K. Kiyoshi (Japan)</i>	P06.11
Monozygotic twin pregnancy discordant for partial trisomy 13 <i>R. Gerychova (Czech Republic)</i>	P06.12
Case report of alloimmunization in monochorionic diamniotic twins successfully treated with intrauterine transfusion of single twin <i>H. Tam Tam (United States)</i>	P06.13
Discordant livers' echogenicity at 16 weeks ultrasound examination followed by a single intrauterine fetal demise in monochorionic diamniotic twin pregnancy: report of 2 cases <i>P. Plekarski (Poland)</i>	P06.14

## P07: Abnormal uterine bleeding

	<b>Panorama hall</b>
Ultrasound guided transcervical surgery inside the endometrial cavity using simple laparoscopic equipment: a hysteroscopy controlled study <i>A. Ozcan (Turkey)</i>	P07.01
The surgical removal of residual trophoblastic tissue in case of enhanced myometrial vascularity with a peak systolic velocity > 50cm/sec <i>T. Van den Bosch (Belgium)</i>	P07.02
Primary malignant mixed müllerian tumors of the uterus: sonohysterographic and color Doppler findings with pathologic correlation <i>E. Lee (South Korea)</i>	P07.03
Diagnostic value of endometrial volume and vascular indices by 3D ultrasonography power Doppler angiography (3D-PDA) in patients with postmenopausal bleeding <i>A. Rossi (Italy)</i>	P07.04
Does the levonorgestral intrauterine system (LNG-IUS) reduce uterine myoma volume over time: a pilot study <i>M. Blanchette Porter (United States)</i>	P07.05
Comparison of saline infusion sonohysterography with unenhanced ultrasound in the diagnosis of uterine adenomyosis <i>M. Momtaz (Egypt)</i>	P07.06
Endometrium thickness – ultrasound criteria for functional juvenile uterine bleeding treatment <i>M. Poenaru (Romania)</i>	P07.07
Ultrasound evaluation of the uterine fibroids volume changes after uterine arteries embolization <i>P. Szkodziak (Poland)</i>	P07.08
Estimation of uterine dry weight from pre-operative 3-D uterine volume ultrasound evaluation in women undergoing total laparoscopic hysterectomy <i>M. Mongelli (Australia)</i>	P07.09
Evaluation of the woman with postmenopausal bleeding and abnormal endometrial thickness <i>S. Lacziko (Romania)</i>	P07.10
Placental polyps: a precursor of placenta accreta or a form of gestational trophoblastic neoplasia? <i>M. Thompson (United Kingdom)</i>	P07.11

## P08: Fetal heart II: 3D/4D & STIC

	<b>North hall</b>
An additional value of 4D ultrasound with STIC in prenatal diagnosis of isolated-TAPVD <i>K. Yoshikoshi (Japan)</i>	P08.01
STIC in the first trimester – a feasibility pilot study <i>T. Stampalija (Italy)</i>	P08.02
Detection of the '3VT view' using 3D ultrasound volumes acquired at the level of the '4CV' <i>L. Gindes (Israel)</i>	P08.03
Reproducibility of fetal heart volume by 3D sonography using the XI VOCAL method <i>P. Nowak (Brazil)</i>	P08.04
Cardiac screening based on 3D imaging of the fetal heart: feasibility and reproducibility for remote telemedicine consultation <i>F. Viñals (Chile)</i>	P08.05
Identification of the outflow tracts of the fetal heart in the first trimester using the method STIC: preliminary results <i>G. Lobo (Brazil)</i>	P08.06
Ectopia cordis: association with amniotic band syndrome in seven cases <i>D. Wood (United States)</i>	P08.07
Ultrasonographic diagnosis of dextrocardia in the first trimester <i>M. Theodora (Greece)</i>	P08.08
Aberrant right subclavian artery associated with cardiac malformation and 21 trisomy: prenatal diagnosis and case presentation <i>G. Iliev (Romania)</i>	P08.09

# Posters – Monday 11 October 2010

	Abstract number
A 10-year review of CHD from a single tertiary institution <i>A. Lee-Tannock (Australia)</i>	P08.10
Should all cases of suspected fetal cardiac abnormalities be referred to specialised cardiac echo clinic? <i>H. Mousa (United Kingdom)</i>	P08.11
Fetal and neonatal clinical evolution of isolated congenital heart disease and associated with major extracardiac malformations or genetic syndromes <i>P. Marantz (Argentina)</i>	P08.12
Aortic outflow hypoplasia with dilated left ventricle and severe mitral insufficiency: the mitral valve dysplasia syndrome <i>J. Rychik (United States)</i>	P08.13
Aberrant subclavian artery in chromosomally (including 22q11 microdeletion) normal and abnormal fetuses <i>G. Rembouskos (Italy)</i>	P08.14
Comparison of fetal atrioventricular valve area by multiplanar and render methods using STIC <i>L. Nardoza (Brazil)</i>	P08.15
Nomogram of fetal interventricular septum area by STIC <i>L. Nardoza (Brazil)</i>	P08.16
Reference range of fetal chest size by three-dimensional ultrasound using the multiplanar method <i>I. Britto (Brazil)</i>	P08.17
Relationship between lung area to chest size ratio in normal fetuses by three-dimensional ultrasound using the multiplanar method <i>I. Britto (Brazil)</i>	P08.18
<b>P09: Unusual syndromes</b>	<b>Club A</b>
Prenatal diagnosis of a familial Saethre-Chotzen syndrome <i>J. Gebb (United States)</i>	P09.01
Tetrasomy 9p with septated cystic hygroma, nonossified nasal bone, prominent midface, Dandy-Walker malformation, cardiac and limb anomalies <i>V. Catanzarite (United States)</i>	P09.02
Prenatal diagnosis of trisomy 5p: a case report <i>J. Unterscheider (Ireland)</i>	P09.03
Prenatal diagnosis of Pai syndrome <i>J. Ochoa (Argentina)</i>	P09.04
Prenatal diagnosis of a fetus with a CHARGE syndrome <i>R. Chaoui (Germany)</i>	P09.05
Prenatal sonographic findings in chromosome 18q deletion syndrome <i>S. Yagel (Israel)</i>	P09.06
Prenatal diagnosis of Klippel-Trenaunay syndrome: a case report <i>M. Brain Giannotti (Spain)</i>	P09.07
An uncommon presentation of trisomy 18 <i>M. Sobral (Portugal)</i>	P09.08
Berry shape vault in a Pallister-Hall fetus: a report <i>A. Insunza (Chile)</i>	P09.09
Bilateral upper amelia and extreme microcephaly mimicking anencephaly: a case of XK-aprosencephaly <i>A. Insunza (Chile)</i>	P09.10
Prenatal diagnosis of a case of congenital ichthyosis <i>C. Martínez-Payo (Spain)</i>	P09.11
Prenatal diagnosis of Jarcho-Levin syndrome and Arnold-Chiari malformation by 3D/4D ultrasound: case report <i>A. Akhmadshchin (Russian Federation)</i>	P09.12
Foetal akinesia deforming sequence: two different genetic syndromes <i>S. Franco (Portugal)</i>	P09.13
Dilated lateral ventricles and micrognathia by US examination in fetus with mosaic trisomy 9 <i>M. Angiolucci (Italy)</i>	P09.14
Cri-du-Chat syndrome presenting with brain anomalies: antenatal ultrasound and magnetic resonance imaging features <i>K. Hsu (Taiwan)</i>	P09.15
Placental cyst, a marker for trisomy 13? <i>D. Janga (United Kingdom)</i>	P09.16
The natural history and postnatal outcomes in fetuses with isolated choroid plexus cysts found at prenatal ultrasound scan in a single referral centre <i>E. Nekrasova (Russian Federation)</i>	P09.17
Risk of preterm delivery following late amniocentesis >24 weeks of gestation <i>J. Pardo (Israel)</i>	P09.18
Fetal loss and complications after genetic amniocentesis <i>M. Angiolucci (Italy)</i>	P09.19

	Abstract number
<b>P10: Imaging technologies I</b>	<b>Club E</b>
Comparative study on quantitative parameters of blood perfusion and microvessel density in placenta of rat model of preeclampsia evaluated with contrast enhanced ultrasound <i>C. Xinlin (China)</i>	P10.01
Placental weight, cord insertion, shape and cord coiling in pregnancies with gestational diabetes mellitus <i>S. Pathak (United Kingdom)</i>	P10.02
Display methods for placental blood flow: how to improve some way using ultrasonic techniques <i>R. Oyama (Japan)</i>	P10.03
Determinants of total vaginal length, thickness and width by computed tomography <i>S. Kim (South Korea)</i>	P10.04
Reference range of fetal lumbar and sacral vertebral bodies area using volume contrast imaging in the coronal plane three-dimensional ultrasonography at 20–34 weeks of pregnancy <i>L. Nardoza (Brazil)</i>	P10.05
Three-dimensional power Doppler ultrasound for the assessment of the fetal brain vascularization and blood flow in normal pregnancy <i>L. Nardoza (Brazil)</i>	P10.06
Ultrasonographic and magnetic resonance imaging detection of placenta accreta <i>K. Maeda (Japan)</i>	P10.07
Incidental finding of an abdominal pregnancy at 21 weeks of amenorrhea: from imaging to therapy <i>P. Bouhanna (France)</i>	P10.08
Oligohydroamnios – according to the cord <i>D. Bashiri (Israel)</i>	P10.09

# Program – Tuesday 12 October 2010

07:45–08:30 'All you ever wanted to know' breakfast sessions must be pre-booked at the registration desk. See page 11 for details

09:00–10:00	Fetal cardiac function	Congress hall
	<i>Chairs: E. Gratacós (Spain); U. Gembruch (Germany)</i>	
09:00	Overview <i>E. Gratacós (Spain)</i>	
09:05	Live scan demonstration: functional assessment of the fetal heart (supported by Siemens*) <i>F. Crispi (Spain)</i>	
09:20	Effect of increased placental vascular resistance on the aortic isthmus blood flow: an experimental study in a chronic fetal sheep model <i>G. Acharya<sup>1</sup>; M. Haapsamo<sup>2</sup>; T. Erkinaro<sup>2</sup>; E. Bruun<sup>2</sup>; J. Junno<sup>2</sup>; J. Rasanen<sup>2</sup></i> <i><sup>1</sup>(Norway); <sup>2</sup>(Finland)</i>	OC09.01
09:25	Discussion	
09:28	TAPSE: a new method of right heart performance evaluation in normal fetuses and pathologies measured with conventional or STIC M-mode <i>B. Messing; M. Lipschuetz; D. Valsky; H. Avnet; O. Shen; S. Cohen; S. Yagel (Israel)</i>	OC09.02, OC09.03 and OC09.04
09:33	Discussion	
09:36	A quantitative study of fetal diastolic ventricular function: establishing normal values of color M-mode propagation velocity <i>B. Zhao; H. Yuan; M. Pan; Y. Yang; P. Li; B. Wang; H. Xu; J. Lu; J. Shou (China)</i>	OC09.05
09:41	Discussion	
09:44	Semiautomatic endocardium deformation analysis to assess fetal cardiac function: clinical feasibility and comparison with tissue Doppler imaging <i>A. Perez-Moreno; F. Crispi; M. Comas; I. Amat-Roldan; E. Gratacós (Spain)</i>	OC09.06
09:49	Discussion	
09:52	Tissue Doppler: effect of ultrasound equipment on measuring fetal cardiac time intervals <i>J. Ritgen; R. Stressig; P. Kozlowski (Germany)</i>	OC09.07
09:57	Discussion	

09:00–10:00	The assessment of pelvic pain	Forum hall
	<i>Chairs: D. Timmerman (Belgium); S. Guerriero (Italy)</i>	
09:00	'Do all endometriomas have typical features?' / imaging rectovaginal nodules <i>C. Van Holsbeke (Belgium)</i>	
09:20	Rectal deep endometriosis: transrectal approach with transvaginal probe to assess the infiltration of rectal mucosa <i>C. Exacoustos; E. Zupi; B. Szabolcs; V. Romeo; C. Amoroso; M. Romanini; D. Arduini (Italy)</i>	OC10.01
09:30	Discussion	
09:33	Common transvaginal sonographic features of adnexal/ovarian torsion <i>S. Giunchi; M. Kuleva; L. Savelli; M. Pesaresi; T. Ghi; F. Guasina; G. Pelusi (Italy)</i>	OC10.02
09:38	Discussion	
09:41	Is pain during and after Mirena® insertion related to the flexion of the uterus and the final position of the Mirena®? <i>D. Van Schoubroeck; E. Werbrouck; J. Veldman; A. Hindryckx; L. Ameye; D. Timmerman (Belgium)</i>	OC10.03
09:46	Discussion	
09:49	Can we predict pouch of Douglas obliteration and posterior compartment deep infiltrative endometriosis using sonovaginography in women undergoing laparoscopy for chronic pelvic pain? <i>S. Reid; M. Mongelli; J. Riemke; T. Bignardi; I. Casikar; D. Alhamdan; G. Reid; G. Condous (Australia)</i>	OC10.04 and OC10.05
09:54	Discussion	
09:57	Summary <i>D. Timmerman (Belgium)</i>	

09:00–10:00	New imaging techniques	Panorama hall
	<i>Chairs: L. Platt (United States); D. Prayer (Austria)</i>	
09:00	Overview <i>L. Platt (United States)</i>	
09:10	MR imaging of the placenta in an IUGR rat-model <i>A. Sabine; B. Deloison; S. Nathalie; C. Charles-Andre; C. Olivier; S. Aimot; N. Siauve; D. Balvay; R. Thiam; C. Cuenod; Y. Ville; O. Clement; L. Salomon (France)</i>	OC11.01 and OC11.02
09:15	Discussion	
09:18	Fetal oxygenation during maternal hyperoxia as estimated by BOLD MRI. Initial results <i>A. Sørensen<sup>1</sup>; M. Pedersen<sup>1</sup>; B. Staussbøl-Grøn<sup>1</sup>; O. Christiansen<sup>1</sup>; G. Lingman<sup>2</sup>; N. Uldbjerg<sup>1</sup></i> <i><sup>1</sup>(Denmark); <sup>2</sup>(Sweden)</i>	OC11.03
09:23	Discussion	

# Program – Tuesday 12 October 2010

09:26	The usefulness of MRI in the diagnosis of fetal lung maturity <i>Y. Oka; T. Waseda; S. Makinoda (Japan)</i>	OC11.04
09:31	Discussion	
09:34	Surface area measurement using rendered three-dimensional ultrasound imaging: an in vitro phantom study <i>C. Ioannou; I. Sarris; M. Yaqub; A. Noble; K. Javaid; A. Papageorghiou (United Kingdom)</i>	OC11.05
09:39	Discussion	
09:42	Imaging the fetus at first trimester: a solution to improve resolution <i>C. Lombardi (Italy)</i>	OC11.06
09:47	Discussion	
09:50	<sup>^</sup> <sup>#</sup> Embryonic brain ventricle development and volumetry in virtual reality <i>M. Rousian; A. Koning; P. Van der Spek; N. Exalto; E. Steegers (Netherlands)</i>	OC11.07
09:55	Discussion	

## 10:00–10:40 Short oral presentation (oral poster) sessions

### 10:40–10:55 Electronic posters: author questions

10:00	<b>OP11: Pelvic pain</b>	Forum hall
10:40	<b>P11: Pelvic pain and reproductive medicine</b> <i>Chairs: G. Condous (Australia); M. Bij de Vaate (Netherlands)</i>	
10:00	<b>OP12: Fetal heart III: circulation and rhythm in congenital heart disease</b>	Panorama hall
10:40	<b>P12: Fetal heart III: fetal cardiac function</b> <i>Chairs: U. Gembruch (Germany); J. Carvalho (United Kingdom)</i>	
10:00	<b>OP13: Preterm labour</b>	North hall
10:40	<b>P13: Preterm labour</b> <i>Chairs: R. Romero (United States); P. Calda (Czech Republic)</i>	
10:00	<b>OP14: Adverse outcome of pregnancy and pelvic floor</b>	Club A
10:40	<b>P14: Adverse outcome of pregnancy and pelvic floor</b> <i>Chairs: K. Kalache (Germany); K. Svabik (Czech Republic)</i>	
10:00	<b>OP15: CNS II: fetal brain anomalies</b>	Club E
10:40	<b>P15: CNS II: fetal brain anomalies</b> <i>Chairs: G. Malinger (Israel); H. Blaas (Norway)</i>	

### 10:30–11:00 Coffee and electronic poster viewing

Exhibition area

## 11:00–12:30 CNS imaging in early pregnancy

Congress hall

	<i>Chairs: G. Pilu (Italy); I. Timor-Tritsch (United States)</i>	
11:00	Suspicion of spina bifida at the 11–14 weeks scan <i>R. Chaoui<sup>1</sup>; B. Benoit<sup>2</sup>; K. Heling<sup>1</sup>; K. Nicolaidis<sup>2</sup> <sup>1</sup>(Germany); <sup>2</sup>(United Kingdom); <sup>3</sup>(Monaco)</i>	OC12.01
11:05	Discussion	
11:08	Spina bifida detection at 11–14 weeks: systematic analysis of technical factors associated with false-positive and false-negative image interpretation <i>I. Solt; M. Kim; J. Acuna; A. Adeniji; C. Morales; S. Rotmensch (United States)</i>	OC12.02
11:13	Discussion	
11:16	Visualization of the fourth ventricle in first trimester fetuses with a normal spine versus spina bifida <i>J. Acuna; I. Solt; A. Adeniji; J. Mirocha; M. Kim; S. Rotmensch (United States)</i>	OC12.03
11:21	Discussion	
11:24	Efficiency and repeatability of recently described markers of early neurosonogram <i>D. Iliescu; A. Comanescu; S. Tudorache; L. Novac; R. Capitanescu; M. Manolea; A. Martin; G. Adam; L. Dijmarescu; N. Cernea (Romania)</i>	OC12.04
11:29	Discussion	
11:32	Visualization and measurement of the cisterna magna and maximal posterior fossa translucency for spina bifida screening at 11–13 weeks gestation <i>I. Solt; M. Kim; A. Adeniji; J. Acuna; J. Mirocha; S. Rotmensch (United States)</i>	OC12.05
11:37	Discussion	
11:40	Embryonic growth and development of the cerebellum using three-dimensional ultrasound <i>M. Rousian; I. Groenenberg; N. Exalto; E. Steegers (Netherlands)</i>	OC12.06
11:45	Discussion	
11:48	Early (15–20 week) ultrasound findings in type-2 cobblestone cortex lissencephaly <i>A. Toi; K. Fong; D. Chitayat; P. Shannon; S. Blaser (Canada)</i>	OC12.07
11:53	Discussion	
11:56	Absence of intracranial translucency on first trimester screen as a predictor of open neural tube defects <i>A. Shah; D. Lewis; N. Vohra (United States)</i>	OC12.08

<sup>#</sup> This presentation is eligible for the Young Investigator award (to be presented at the closing ceremony).


<sup>^</sup> This abstract has been shortlisted as a finalist for the Alfred Kratochwil 3D abstract award. The winner will be announced at the closing ceremony.

# Program – Tuesday 12 October 2010

12:01	Discussion
12:04	Summary <i>G. Pilu (Italy)</i>
12:14	Live scan demonstration: intracranial translucency (supported by Toshiba*) <i>R. Chaoui (Germany)</i>

11:00–12:30		Reproductive medicine	Forum hall
		<i>Chairs: S. Campbell (United Kingdom); S. Goldstein (United States)</i>	
11:00	Should all infertility patients have an ultrasound scan before treatment? <i>F. Lamazou (France)</i>		
11:15	Discussion		
11:18	Ultrasonographically controlled access to peritoneal cavity in gynaecology <i>A. Sobek; O. Koutna; T. Cepelak; A. Sobek (Czech Republic)</i>		OC13.01
11:23	Discussion		
11:26	Prediction of IVF outcome at different cut-off levels of antral follicle count in a prospective cohort of 1012 women <i>K. Jayaprakasan; Y. Chan; R. Islam; Z. Haoula; S. Sur; S. Deb; J. Clewes; N. Raine-Fenning (United Kingdom)</i>		OC13.02
11:31	Discussion		
11:34	Assessment of endometrial and subendometrial blood flow in women undergoing frozen embryo replacement and its relationship to conception <i>A. Nandi; K. Jayaprakasan; J. Clewes; N. Raine-Fenning (United Kingdom)</i>		OC13.03
11:39	Discussion		
11:42	Association between early first-trimester CRL measurement of a live embryo and adverse pregnancy outcome in IVF patients <i>A. Ben-Haroush; I. Meizner; N. Melamed; E. Hadar; R. Masiach; B. Fisch (Israel)</i>		OC13.04
11:47	Discussion		
11:50	Impact of uterine anomalies upon pregnancy in women conceiving following assisted reproduction treatment <i>Y. Chan; K. Jayaprakasan; S. Sur; S. Deb; J. Clewes; N. Raine-Fenning (United Kingdom)</i>		OC13.05
11:55	Discussion		
11:58	Pregnancy rate after automated three-dimensional coded contrast imaging hysterosalpingo-contrast sonography <i>A. Di Giovanni; C. Exacoustos; V. Romeo; B. Szabolcs; E. Vaquero; E. Zupi; D. Arduini (Italy)</i>		OC13.06
12:03	Discussion		
12:06	Factors influencing outcome after IVF (including uterine anomalies) <i>N. Raine-Fenning (United Kingdom)</i>		
12:21	# Classification of Mullerian duct anomalies using three dimensional ultrasound and reproductive outcomes after in vitro fertilization <i>A. Kim; J. Han; C. Eunmi; J. Kim; H. Seok; S. Lyu; T. Yoon (Republic of Korea)</i>		OC13.07
12:26	Discussion		
12:29	Summary <i>N. Raine-Fenning (United Kingdom)</i>		

11:00–12:30		Obstetric management	Panorama hall
		<i>Chairs: A. Ngu (Australia); Z. Alfirevic (United Kingdom)</i>	
11:00	Overview <i>Z. Alfirevic (United Kingdom)</i>		
11:05	Obstetrical sonography: tricks of the trade <i>A. Abuhamad (United States)</i>		
11:25	Sonographic characteristics of the uterus within 6 weeks following Cesarean section <i>E. Dosedla<sup>1</sup>; P. Calda<sup>2</sup></i> <i><sup>1</sup>(Slovakia); <sup>2</sup>(Czech Republic)</i>		OC14.01
11:30	Discussion		
11:33	The practice of abdominal ultrasound in cases of severe or life-threatening post-partum haemorrhage: evaluation in 137 patients in a French tertiary care center <i>O. Morel; R. Lousquy; C. Malartic; E. Gayat; Y. Fargeaudou; P. Soyer; E. Barranger (France)</i>		OC14.02
11:38	Discussion		
11:41	First trimester transvaginal ultrasound of the isthmus in patients with prior Caesarean: is it a scar that we see? <i>J. Stirnemann; N. Saidji; L. Salomon; J. Bernard; Y. Ville (France)</i>		OC14.03
11:46	Discussion		
11:49	The role of maternal and additional fetal variables in fetal weight estimation near term: implications and accuracy <i>P. Mustoni<sup>1</sup>; V. Mantegazza<sup>1</sup>; S. Rigano<sup>1</sup>; S. Di Francesco<sup>1</sup>; S. Fiore<sup>1</sup>; C. Boria<sup>2</sup>; E. Ferrazzi<sup>1</sup></i> <i><sup>1</sup>(Italy); <sup>2</sup>(United Kingdom)</i>		OC14.04
11:54	Discussion		



What is the  
next dimension  
in Ultrasound?

## Mastering acoustics. Expanding clinical insight.

For today's challenging imaging cases, you need powerful tools and the most advanced technologies. The ACUSON S2000™ ultrasound system isn't just a step up, it's a giant leap forward. The first in our new S Class product family, the ACUSON S2000 system leverages Siemens' acoustic mastery to expand ultrasound beyond its traditional role. With unprecedented image quality, knowledge-based workflow efficiencies and highly tuned ergonomics, the ACUSON S2000 system delivers the broadest range of innovative clinical applications possible. The future of ultrasound is now. [www.siemens.com/ultrasound](http://www.siemens.com/ultrasound)

Answers for life.

**SIEMENS**

# Program – Tuesday 12 October 2010

11:57	Sonographic prediction of fetal macrosomia: the effect of model and threshold used <i>N. Melamed; A. Ben-Haroush; Y. Yogev; R. Mashiach; I. Meizner (Israel)</i>	OC14.05
12:02	Discussion	
12:05	NO donors and volume expansion added to antihypertensive therapy in gestational hypertension decreases systemic vascular resistance and complications <i>G. Novelli; B. Vasapallo; G. Gagliardi; D. Manfellotto; H. Valensise (Italy)</i>	OC14.06
12:10	Discussion	
12:13	Cervical length and maternal factors in prediction of duration of labor and mode of delivery <i>M. Marinkovic; Z. Mikovic; N. Karadzov; B. Pazin; D. Mojovic (Serbia)</i>	OC14.07
12:18	Discussion	
12:21	The infrapubic fetal occiput: an objective sign of imminent vaginal delivery <i>E. Contro; M. Nobile; T. Ghi; G. Pilu (Italy)</i>	OC14.08
12:26	Discussion	

**12:30–14:00 Lunch and electronic poster viewing** **Exhibition area**

**12:45–13:45 Siemens satellite symposium\*\*** **Congress hall**

Prenatal diagnosis of vascular anomalies of the soft tissue

**12:45–13:45 Medison satellite symposium\*\*** **Forum hall**

New frontiers in 3D/4D ultrasound

**14:00–15:00 Multiple Pregnancy** **Congress hall**

*Chairs: K. Hecher (Germany); L. Lewi (Belgium)*

14:00	Overview <i>L. Lewi (Belgium)</i>	
14:05	Live scan demonstration: scanning twins (supported by Medison*) <i>W. Sepulveda (Chile)</i>	
14:20	Prenatal determination of placental cord insertion site in monochorionic and dichorionic twin gestations: a predictor of growth discordance? <i>F. Breathnach; F. McAuliffe; M. Geary; S. Daly; J. Higgins; J. Dorman; J. Morrison; G. Burke; S. Higgins; S. Carroll; F. Malone (Ireland)</i>	OC15.01
14:25	Discussion	
14:28	Twin pregnancy: screening test for spontaneous preterm delivery and preeclampsia during the second trimester of pregnancy <i>M. Parra-Cordero; M. Rodríguez; R. Díaz; G. Rencoret; E. Valdés; H. Muñoz (Chile)</i>	OC15.02
14:33	Discussion	
14:36	Intratwin weight discordance and the prediction of successful vaginal twin birth: the ESPRIT study <i>F. Breathnach; F. McAuliffe; M. Geary; S. Daly; J. Higgins; J. Dorman; J. Morrison; G. Burke; S. Higgins; S. Carroll; F. Malone (Ireland)</i>	OC15.03
14:41	Discussion	
14:44	Vascular development and responses in twins: influence of monochorionicity, inter-twin transfusion and fetal therapy <i>H. Gardiner<sup>1</sup>; H. Matsui<sup>1</sup>; K. Hecher<sup>2</sup>; A. Diemert<sup>2</sup>; M. Taylor<sup>1</sup>; S. Greenwald<sup>1</sup>; A. Barlas<sup>1</sup>; J. Preece<sup>1</sup>; F. Gordon<sup>1</sup></i> <sup>1</sup> (United Kingdom); <sup>2</sup> (Germany)	OC15.04
14:49	Discussion	
14:52	Results of cord coagulation and section with laser in a clinical series of 17 monoamniotic pregnancies as compared with conventional cord occlusion <i>M. Martínez-Serrano; E. Eixarch; M. Sanz-Cortes; F. Crispi; R. Cruz-Martinez; J. Martinez; E. Gratacós (Spain)</i>	OC15.05
14:57	Discussion	

**14:00–15:00 Using ultrasound to assess urogynecology patients** **Forum hall**

*Chairs: H. Dietz (Australia); J. Masata (Czech Republic)*

14:00	The correlation between ultrasound findings of the pelvic floor, patient symptoms and pathology <i>J. Deprest (Belgium)</i>	
14:20	<sup>^</sup> Association between transperineal ultrasound findings and anal incontinence in a follow-up study of anal sphincter tears <i>D. Valsky; S. Cohen; M. Lipschuetz; B. Messing; R. Drai-Hassid; D. Hochner-Celnikier; S. Yagel (Israel)</i>	OC16.01
14:25	Discussion	
14:28	Avulsion of the puborectalis muscle causes asymmetry of the levator hiatus <i>H. Dietz; R. Bhalla; V. Chantarasorn; K. Shek (Australia)</i>	OC16.02
14:33	Discussion	

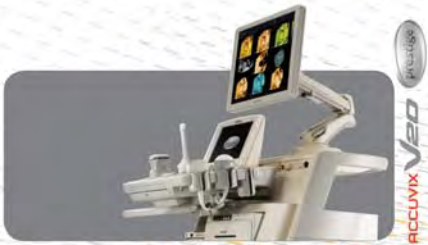\* Scientific content of live scan sessions is defined by ISUOG. Ultrasound systems and technical support are provided by sponsors.

\*\* Lunchtime satellite symposia are brought to you by our sponsors and are not part of the ISUOG CME program. ISUOG takes no responsibility for scientific or clinical content.

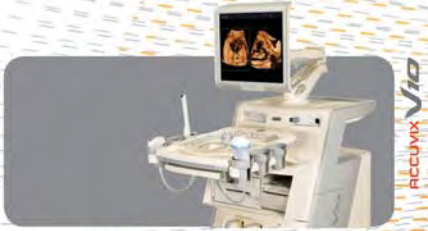<sup>^</sup> This abstract has been shortlisted as a finalist for the Alfred Kratochwil 3D abstract award. The winner will be announced at the closing ceremony.



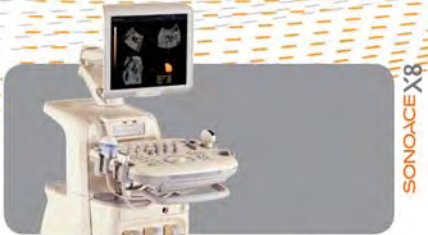see it all  
**MEDISON**  
25th anniversary



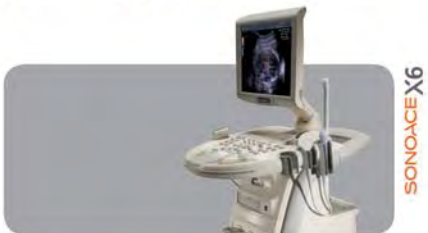ACCUVIX Neo



ACCUVIX Vio



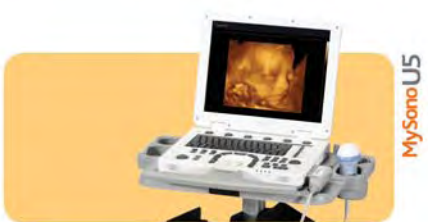SONOACE X8



SONOACE X6



SONOACE X4



MySono U5



NEW

SONOACE R3



SONOACE X1

Revolutionary challenge continues -

# The Ultimate Ultrasound Company

MEDISON, is a global medical solutions company creating solutions for everything from technological development to multi-modality products. We have been a leading name in diagnostic ultrasound since our foundation in 1985 and we have remained at the forefront of research and development in diagnostic 3D/4D technology for 25 years. Since revolutionizing the industry with the introduction of the first commercial 3D/4D ultrasound device, we continue to innovate technologies that have made 3D/4D ultrasound an indispensable diagnostic tool for clinicians the world over. Today we continue to pioneer revolutionary ultrasound technologies from small portable systems to the ultimate diagnostic 3D/4D ultrasound imaging systems.

During this our 25th Anniversary year we continue to seek to improve the wellbeing of people the world over.

*MEDISON ultrasound,  
leading with innovation and ingenuity.*



Platinum sponsor  
**ISUOG 2010**



20th World Congress on Ultrasound  
in Obstetrics and Gynecology  
10 - 14 October 2010, Prague, Czech Republic

Visit us at **MEDISON booth #8**

[www.medison.com](http://www.medison.com) | [marketing5@medison.com](mailto:marketing5@medison.com)

# Program – Tuesday 12 October 2010

14:36	3D perineal ultrasound: correlation of persisting pelvic floor disorders and hiatal measurements immediately after the first delivery <i>A. Falkert; A. Willmann; E. Endress; P. Meint; B. Seelbach-Goebel (Germany)</i>	OC16.03
14:41	Discussion	
14:44	Levator ani injury diagnosed by 3DTUS 6-12 months postpartum is associated with clinical complaints <i>A. Bord; S. Yagel; L. Shick-Naveh; M. Lipschuetz; R. Drai-Hassid; B. Messing; D. Valsky (Israel)</i>	OC16.04
14:49	Discussion	
14:52	Summary <i>H. Dietz (Australia)</i>	

## 14:00–15:00 Preterm labour Panorama hall

	<i>Chairs: R. Romero (United States); C. Brezinka (Austria)</i>	
14:00	Preterm delivery <i>Z. Alfrevic (United Kingdom)</i>	
14:20	Risk assessment for early spontaneous preterm delivery combining markers from the first and second trimester of pregnancy <i>M. Parra-Cordero; D. Pedraza; G. Rencoret; H. Muñoz; R. Terra; E. Valdes (Chile)</i>	OC17.01
14:25	Discussion	
14:28	Cervical bacterial colonization and cervical length in women with threatening preterm labor <i>D. Bomba-Opon; K. Kosinska-Kaczynska; P. Kosinski; M. Wielgos; R. Bartkowiak (Poland)</i>	OC17.02
14:33	Discussion	
14:36	A new method for prediction of preterm birth: fetal zone enlargement <i>O. Turan; S. Turan; E. Funai; I. Buhimschi; C. Harman; J. Copel; A. Baschat (United States)</i>	OC17.03
14:41	Discussion	
14:44	Transvaginal ultrasonography in asymptomatic high risk women with a short cervical length in the previous pregnancy <i>J. Crane; D. Hutchens (Canada)</i>	OC17.04
14:49	Discussion	
14:52	Cervical gland area as an ultrasonographic marker for predicting preterm delivery in high risk pregnant women <i>V. Marsoosi; M. Mashhadian; S. Ziaee; M. Asghari (Islamic Republic of Iran)</i>	OC17.05
14:57	Discussion	

## 15:00–15:40 Short oral presentation (oral poster) sessions

### 15:40–16:00 Electronic posters: author questions

15:00	<b>OP16: Reproductive medicine</b>	Forum hall
15:40	<b>P16: Early pregnancy II</b> <i>Chairs: N. Raine-Fenning (United Kingdom); S. Guerriero (Italy)</i>	
15:00	<b>OP17: First trimester II: improving quality of screening for aneuploidy</b>	Panorama hall
15:40	<b>P17: First trimester II: aneuploidy and anomalies</b> <i>Chairs: A. Tabor (Denmark); F. Prefumo (Italy)</i>	
15:00	<b>OP18: Fetal anomalies I: fetal face and chest assessments</b>	North hall
15:40	<b>P18: Fetal anomalies I: fetal face and chest assessment</b> <i>Chairs: B. Benacerraf (United States); E. Merz (Germany)</i>	
15:00	<b>OP19: Multiple pregnancy II</b>	Club A
15:40	<b>P19: Multiple pregnancy II</b> <i>Chairs: A. Gagnon (Canada); L. Salomon (France)</i>	
15:00	<b>OP20: Imaging technologies II</b>	Club E
15:40	<b>P20: Imaging technologies II</b> <i>Chairs: D. Prayer (Austria); I. Zador (United States)</i>	

## 15:40–16:10 Coffee and electronic poster viewing Exhibition area

## 16:00–17:30 Workshop: molecular vs. ultrasound screening for T21 Congress hall

	<i>Chairs: S. Yagel (Israel); T. Lau (China)</i>	
16:00	Live scan demonstration: the second trimester genetic sonogram (supported by Philips*) <i>D. Nyberg (United States)</i>	
16:20	Fetal cells and fetal DNA in maternal blood: past, present and future <i>T. Lau (China)</i>	
16:35	Maternal serum testing for fetal RNA-SNP and fetal DNA methylation and massively parallel sequencing for direct detection of T21 <i>S. Yagel (Israel)</i>	
16:50	Ultrasound screening for trisomy 21 in the first trimester <i>K. Kagan (Germany)</i>	

# Program – Tuesday 12 October 2010

17:05 The second trimester genetic sonogram  
*B. Benacerraf (United States)*

17:20 Panel discussion

## 16:00–17:30 Workshop: fertility: assessing the ovarian reserve and the uterus Forum hall

*Chairs: N. Raine-Fenning (United Kingdom); S. Goldstein (United States)*

16:00 Live scan demonstration: how to assess ovarian reserve – ultrasound, FSH or AMH? (supported by GE\*)  
*N. Raine-Fenning (United Kingdom)*

16:20 Do mural fibroids or hydrosalpinges matter in fertility patients?  
*C. Exacoustos (Italy)*

16:40 Evaluating the uterus with 3D ultrasound in the fertility clinic  
*K. Jayaprakasan (United Kingdom)*

17:00 Case discussion and images  
*N. Raine-Fenning (United Kingdom); A. Coomrasamy (United Kingdom); J. Levaillant (France)*

17:10 Case discussion and images  
*C. Exacoustos (Italy)*

17:20 Summary  
*N. Raine-Fenning (United Kingdom)*

## 16:00–17:30 Workshop: Doppler in screening Panorama hall

*Chairs: K. Maršál (Sweden); S. Eik-Nes (Norway)*

**Debate: First trimester is best for uterine Doppler based PET/FGFR risk predictions**

16:00 Argument for:  
*A. Baschat (United States); A. Papageorghiou (United Kingdom)*

16:10 Argument against:  
*C. Lees (United Kingdom); C. Brezinka (Austria)*

16:20 Chair summary and short responses

16:25 Chair and audience questions

16:30 Vote

16:35 Pitfalls in the assessment of umbilical artery Doppler  
*S. Campbell (United Kingdom)*

16:50 Discussion

16:55 Latest meta analysis on umbilical artery Doppler  
*Z. Alfirevic (United Kingdom)*

17:10 Discussion

17:15 Can uterine artery Doppler help in predicting prenatal outcome when the umbilical artery is known?  
*S. Gudmundsson (Sweden)*

17:30 Discussion

## 16:00–17:30 Workshop: borderline findings North hall

*Chairs: D. Paladini (Italy); A. Abuhamad (United States)*

16:00 CNS: Blake's vs. vermian hypoplasia, a recently born conflict  
*D. Paladini (Italy)*

16:15 CNS: agenesis of the corpus callosum, a prognostic dilemma  
*A. Abuhamad (United States)*

16:30 Heart: minor cardiac findings (LSVC, ARSA, VSD, RAA) and karyotyping  
*J. Cope (United States)*

16:45 Heart: microdeletion 22q11: brilliant diagnosis and then?  
*R. Chaoui (Germany)*

17:00 Borderline lateral ventricles: work-up and counseling  
*A. Abuhamad (United States)*

17:15 First trimester: enlarged NT and normal karyotype – a detailed analysis of the 5–10% 'abnormal outcome cases'  
*C. Bilardo (Netherlands)*

# Short oral presentations – Tuesday 12 October 2010

**Chaired short oral presentation (oral poster) sessions: 10:00–10:40**

**Viewing available all week on E-poster viewing stations located in the level 2 foyer**

	Abstract number
<b>OP11: Pelvic pain</b>	<b>Forum hall</b>
<i>Chairs: G. Condous (Australia); M. Bij de Vaate (Netherlands)</i>	
Standardization of three dimensional ultrasonographic evaluation for the assessment of deep infiltrating endometriosis <i>S. Guerriero (Italy)</i>	OP11.01
Symptomatic women with endometriosis: beyond the ovaries <i>L. Hereter (Spain)</i>	OP11.02
Prediction of the need for morcellation at total laparoscopic hysterectomy (TLH) from pre-operative 3D volumetric ultrasound-estimated uterine weight and parity <i>M. Mongelli (Australia)</i>	OP11.03
Clinical, ultrasonographic and histological characteristics of ovarian torsion necessitating oophorectomy: unexpected identification of preserved ovarian function <i>V. Asfour (United Kingdom)</i>	OP11.04
'Muscle thickness' symptom in case of external genital endometriosis <i>E. Fedorova (Russian Federation)</i>	OP11.05
Role of 3D power Doppler in early diagnosis of massive ovarian edema due to incomplete torsion of a simple ovarian cyst <i>H. Gaafar (Egypt)</i>	OP11.06
A case of ultrasound guided hysteroscopic retrieval of a deep myometrial imbedded copper collar from the horizontal arm of an intrauterine device <i>M. Blanchette Porter (United States)</i>	OP11.07
Anterior abdominal wall haematoma diagnosed with ultrasound in a patient admitted with acute shortness of breath <i>M. Theodora (Greece)</i>	OP11.08
<b>OP12: Fetal heart III: circulation and rhythm in congenital heart disease</b>	<b>Panorama hall</b>
<i>Chairs: U. Gembruch (Germany); J. Carvalho (United Kingdom)</i>	
The change of umbilical artery and middle cerebral artery pulsatility index in fetuses with congenital heart diseases of septal defect <i>G. Lv (China)</i>	OP12.01
Hypoplastic left heart syndrome, restrictive interatrial communication and fetal pulmonary venous flow patterns <i>R. Axt-Fliehdner (Germany)</i>	OP12.02
Fetal cardiac ventricle volumetry in the second half of gestation assessed by 4D ultrasound using STIC <i>G. Lobo (Brazil)</i>	OP12.03
Primary assessment of fetal ventricular volume and systolic function using real-time and full volume three-dimensional echocardiography <i>Y. Yang (China)</i>	OP12.04
Full-volume three-dimensional echocardiographic assessment of ventricular volume in healthy human fetuses <i>B. Zhao (China)</i>	OP12.05, OP12.06
Velocity vector imaging of longitudinal function, strain and strain rate in the right ventricle of the fetus with hypoplastic left heart syndrome <i>C. Saunders (United States)</i>	OP12.07
Fetal main pulmonary artery pulsed wave Doppler investigation: an easy and reliable way to assess fetal cardiac rhythm <i>H. Park (South Korea)</i>	OP12.08
Early recognition of arrhythmias using maternal abdominal fetal electrocardiography <i>L. Simpson (United States)</i>	OP12.09
Diagnosing fetal long QT syndrome using tissue Doppler imaging (TDI), preliminary report <i>S. Clur (Netherlands)</i>	OP12.10
<b>OP13: Preterm labour</b>	<b>North hall</b>
<i>Chairs: R. Romero (United States); P. Calda (Czech Republic)</i>	
Measurement of cervical volume by 3-dimensional ultrasound at a gestational age of 18–22 weeks <i>M Habraken (Netherlands)</i>	OP13.01
Correlation between cervico-isthmic (cervist) distance in first trimester and second trimester cervical length in an unselected population <i>L. Salomon (France)</i>	OP13.02
Outcome of patients with short cervico-isthmic distance (cervist) at first trimester <i>L. Salomon (France)</i>	OP13.03
Mid-trimester amniotic sludge and preterm delivery in asymptomatic women <i>E. Himaya (Canada)</i>	OP13.04
Is mid-gestational cervical length measurement as sensitive prediction factor of preterm delivery in IVF as in spontaneous singleton pregnancies? <i>I. Szymusik (Poland)</i>	OP13.05
Can cervical length discriminate between low and high risk of preterm delivery in women with threatened preterm labour? <i>C. Wulff (Denmark)</i>	OP13.06
Cervical length at preterm labor admission for the prediction of adverse perinatal outcome in term born fetuses <i>D. Oros (Spain)</i>	OP13.07

# Short oral presentations – Tuesday 12 October 2010

	Abstract number
Fetal membranes: is vaginal ultrasound useful in establishing diagnosis of membranes rupture? <i>E. Domali (Greece)</i>	OP13.08
The change of cervical length after cerclage does not influence pregnancy outcome <i>K. Song (South Korea)</i>	OP13.09
An ultrasound transverse diameter of fetal thymus as a marker of the histological chorioamnionitis <i>M. Kacerovsky (Czech Republic)</i>	OP13.10
<b>OP14: Adverse outcome of pregnancy and pelvic floor</b>	<b>Club A</b>
<i>Chairs: K. Kalache (Germany); K. Svabik (Czech Republic)</i>	
Low serum PAPP-A values in early pregnancy and adverse pregnancy outcome <i>D. Huang (Switzerland)</i>	OP14.01
Low PAPP-A levels in the first trimester of pregnancy and adverse perinatal outcome. A preliminary study <i>N. Haratz (United States)</i>	OP14.02
Single umbilical artery as an independent risk factor for pregnancy outcome <i>C. Berceanu (Romania)</i>	OP14.03
Vasa previa: is there a role for cervical length measurement? Review of cases of antenatal management <i>V. Romero (United States)</i>	OP14.04
Evaluation of prognostic factors in pregnancies complicated by idiopathic polyhydramnios <i>S. Pri-Paz (United States)</i>	OP14.05
Characteristics of the pelvic floor during pregnancy by three-dimensional ultrasound <i>H. Jeong (South Korea)</i>	OP14.06
Does the Epi-No device prevent levator trauma? A randomised controlled trial <i>H. Dietz (Australia)</i>	OP14.07
Transperineal 4D ultrasound imaging of the levator ani during labour <i>A. Steensma (Netherlands)</i>	OP14.08
Obstetric levator ani and anal sphincter tears visualized with 4D/3D transanal and translabial ultrasound in the delivery room and at follow-up <i>A. Ömö (Sweden)</i>	OP14.09
<b>OP15: CNS II: fetal brain anomalies</b>	<b>Club E</b>
<i>Chairs: G. Malinge (Israel); H. Blaas (Norway)</i>	
Schizencephaly: the result of a vascular disruption sequence that first becomes apparent in the second trimester <i>D. Howe (United Kingdom)</i>	OP15.01
Interobserver agreement and diagnostic performance of intracranial translucency in the detection of open neural tube defect at the 11–13+6 week scan <i>K. Fong (Canada)</i>	OP15.02
Fetal 'isolated' ventriculomegaly: results of a long term prospective prenatal/postnatal cohort <i>J. Bello-Muñoz (Spain)</i>	OP15.03
Changing diagnosis and outcome in spina bifida: results of 30 years experience of a single third-level center <i>L. Masini (Italy)</i>	OP15.04
GA-adjusted ventricle measurement in relation to fetal gender and cephalometry <i>L. Salomon (France)</i>	OP15.05
Increasing of fetal intraorbital optic nerve diameter during pregnancy: evaluation by sonography <i>E. Bertucci (Italy)</i>	OP15.06
Can syndromic macrocephaly be diagnosed in utero? <i>G. Malinge (Israel)</i>	OP15.07
Intrauterine fetal brain damage in preeclamptic animal model: hemodynamic and histologic changes <i>B. Pellicer (Spain)</i>	OP15.08
Feasibility of intracerebral translucency measurement at the time of the first trimester scan <i>R. Abu-Rustum (Lebanon)</i>	OP15.09
Examining the vermis: a better and easier way <i>S. Yagel (Israel)</i>	OP15.10
Cisterna magna measurements in normal fetuses in relation to gestational age and other covariables <i>L. Salomon (France)</i>	OP15.11

# Short oral presentations – Tuesday 12 October 2010

**Chaired short oral presentation (oral poster) sessions: 15:00–15:40**

**Viewing available all week on E-poster viewing stations located in the level 2 foyer**

Abstract number

## OP16: Reproductive medicine

Forum hall

*Chairs: N. Raine-Fenning (United Kingdom); S. Guerriero (Italy)*

3D-SIS in differential diagnosis of septate, bicornuate and arcuate uterus; the comparative study of accuracy with 2D-TVS, 3D-TVS and 2D-SIS OP16.01

*A. Ludwin (Poland)*

^ Assessing the reliability and validity of 3D crown–rump length measurements OP16.02

*S. Sur (United Kingdom)*

Ultrasound endometrial pattern in the day of hCG administration correlates with progesterone level and IVF outcome OP16.03

*D. Albu (Romania)*

Adenomyosis: three dimensional sonographic findings of the junctional zone in infertile patients OP16.04

*C. Exacoustos (Italy)*

Spatial temporal image correlation using high definition flow: a new method for analyzing ovarian vascularization OP16.05

*M. Kudla (Poland)*

Pretreatment ultrasonographic score of antral follicle count and ovarian volume for prediction of pregnancy in IVF cycles OP16.06

*I. Meizner (Israel)*

Objective follicle monitoring and accurate result communication from referring physicians in an IVF program OP16.07

*M. Murtinger (Austria)*

Müllerian anomalies diagnosed by saline contrast sonohysterography – prevalence in a general population OP16.08

*E. Dreisler (Denmark)*

Three-dimensional ultrasound evaluation of Essure® microinserts: proper placement and complications OP16.09

*I. Suchet (Canada)*

3D omniview sonography in the pre-assisted reproductive medicine programme OP16.10

*L. Rosignoli (Italy)*

## OP17: First trimester II: improving quality of screening for aneuploidy

Panorama hall

*Chairs: A. Tabor (Denmark); F. Prefumo (Italy)*

Likelihood ratio based quality control for NT measurement at first trimester OP17.01

*L. Salomon (France)*

Transvaginal probe as a uterine manipulator in transabdominal chorionic villus sampling in cases with difficult access to the trophoblast OP17.02

*E. Bertucci (Italy)*

Scanning women with high body mass index, an emerging dilemma OP17.03

*D. Janga (United Kingdom)*

Variability of ultrasound measurements with different machine/probe combinations assessed using a phantom: implications for NT screening OP17.04

*T. Chudleigh (United Kingdom)*

Semi-automated adjusted measurement of nuchal translucency: feasibility, reproducibility, and benefits OP17.05

*O. Morel (France)*

Self-assessment in ultrasound scanning of the nuchal translucency and crown–rump length during the first trimester OP17.06

*G. Haddad (France)*

The effect of variance in nuchal translucency measurements on trisomy 21 test results for first-trimester combined and integrated screening OP17.07

*J. Robinson (United States)*

Three methods of auditing the nuchal translucency component of a routine combined screening service OP17.08

*T. Chudleigh (United Kingdom)*

Use of CUSUM method in nuchal translucency audit OP17.09

*J. Sabria (Spain)*

Level of sonographer agreement of two methods of auditing nuchal translucency images OP17.10

*T. Chudleigh (United Kingdom)*

## OP18: Fetal anomalies I: fetal face and chest assessments

North hall

*Chairs: B. Benacerraf (United States); E. Merz (Germany)*

Sonographic estimation of fetal head circumference – how accurate are we? OP18.01

*I. Meizner (Israel)*

The utility of three dimensional non-orthogonal curvilinear planes in the evaluation of cranio-facial anomalies OP18.02

*A. Khurana (India)*

The X face appraisal, a template for the fetal profile OP18.03

*E. de Jong-Pleij (Netherlands)*

Degree of micrognathia by inferior facial angle differentiates primary mandibular dysostoses from secondary involvement OP18.04

*D. Paladini (Italy)*

Reference line for recognizing retrognathia is not applicable to 3D corrected profile images OP18.05

*E. de Jong-Pleij (Netherlands)*

Additional value of sagittal CDUS images for the differential diagnosis of fetal cleft lip and palate OP18.06

*J. Cho (South Korea)*

# Short oral presentations – Tuesday 12 October 2010

	Abstract number
Isolated cleft lips: interest of 'Cupid's bow' <i>J. Develay-Morice (France)</i>	OP18.07
Predicting neonatal outcome in 40 fetuses with congenital cystic adenomatoid malformation using fetal lung volumes <i>R. Ruano (Brazil)</i>	OP18.08
Prenatal diagnosis of pleural effusion (chylothorax) – 5-year experience of a single center <i>R. Ruano (Brazil)</i>	OP18.09
Outcome and management of antenatally diagnosed fetal pleural effusions <i>P. Yeh (United Kingdom)</i>	OP18.10
<b>OP19: Multiple pregnancy II</b>	<b>Club A</b>
<i>Chairs: A. Gagnon (Canada); L. Salomon (France)</i>	
Pregnancy complication and perinatal outcome in spontaneous and assisted reproductive technologies twin pregnancies <i>E. Cosmi (Italy)</i>	OP19.01, OP19.02
Accuracy of first trimester markers for determination of chorionicity in twins <i>T. Dias (United Kingdom)</i>	OP19.03
Twin pregnancies with 'lambda' sign on ultrasound examination may not rule out monochorionic diamniotic twins <i>Y. Kitadai (Japan)</i>	OP19.04
Monochorionic monoamniotic twin pregnancies with two yolk sacs may not be a rare finding: a report of two cases <i>T. Murakoshi (Japan)</i>	OP19.05
How accurate are we in determining the placental cord insertion site in multiple gestations? <i>L. Romine (United States)</i>	OP19.06
Cervical length changes and the risk of preterm delivery in twin pregnancies <i>M. Kuleva (Italy)</i>	OP19.07
Effect of prophylactic progesterone on incidence of preterm labour in spontaneous twin pregnancy, randomized controlled study <i>A. Elsheikhah (Egypt)</i>	OP19.08
Spontaneous version of fetal presentation in twin pregnancies during third trimester <i>J. Park (South Korea)</i>	OP19.09
Can we trust in sonographic diagnosis of discordancy (>20% in EFW)? <i>M. Yamamoto (Chile)</i>	OP19.10
Management of twin reversed arterial perfusion sequence: a single center experience <i>S. Faiola (Italy)</i>	OP19.11
<b>OP20: Imaging technologies II</b>	<b>Club E</b>
<i>Chairs: D. Prayer (Austria); I. Zador (United States)</i>	
Variability of ultrasound measurements with different machine/probe combinations assessed using a phantom: implications for dating <i>T. Chudleigh (United Kingdom)</i>	OP20.01
Variability of ultrasound measurements with different machine/probe combinations assessed using a phantom <i>T. Chudleigh (United Kingdom)</i>	OP20.02
Comparison of nuchal translucency measurements using 3D Auto biometry package-NT, 2D and 3D ultrasound <i>H. Cho (South Korea)</i>	OP20.03
Fetal MRI to evaluate ventriculomegaly: what does MRI improve? <i>R. Ximenes (Brazil)</i>	OP20.04
Fetal volume measurement at gestational age of 11+0–13+6 weeks by three-dimensional ultrasound <i>F. Van Deursen (Netherlands)</i>	OP20.05
Contribution of fetal magnetic resonance imaging in the evaluation of fetal craniofacial anomalies <i>V. Frisova (Czech Republic)</i>	OP20.06
Comparison between transabdominal ultrasound with high resolution probe versus MRI for fetal cerebral morphological evaluation <i>M. Bellotti (Italy)</i>	OP20.07
Chemical shift imaging of the fetal liver <i>D. Prayer (Austria)</i>	OP20.08
Reproducibility of fetal upper-arm and thigh volume by three-dimensional ultrasonography using XI VOCAL method <i>L. Nardoza (Brazil)</i>	OP20.09

# Posters – Tuesday 12 October 2010

Poster question and answer sessions: 10:40–10:55

Viewing available all week on E-poster viewing stations located in the level 2 foyer

## P11: Pelvic pain and reproductive medicine

	Abstract number
Preimplantation diagnosis of monogenic diseases in GENNET <i>D. Smetanova (Czech Republic)</i>	P11.01
The appearance of the endometrium at saline contrast sonohysterography in the luteal phase <i>L. Jokubkiene (Sweden)</i>	P11.02
Diagnostic accuracy of transvaginal sonography in infertile patients with endometrial polyp <i>M. Nik Nejadi (Islamic Republic of Iran)</i>	P11.03
Correlation of ultrasound examination and hysteroscopy in patients after instrumental revision of uterine cavity after delivery <i>L. Hrazdirova (Czech Republic)</i>	P11.04
Clinical efficacy of MRgFUS in treatment of adenomyosis: 12 month follow-up <i>H. Fukunishi (Japan)</i>	P11.05
Adenomyosis: an underestimated pathology <i>L. Hereter (Spain)</i>	P11.06
Ultrasonographic detection of IUD cylinder reverberation as a 'best' landmark of the position of a levonorgestrel intrauterine device? <i>Z. Puzigaća (Serbia)</i>	P11.07
Three-dimensional ultrasound in diagnosis of septate uterus in patients with suspected congenital uterine anomalies <i>M. Pascual (Spain)</i>	P11.08
The value of transvaginal three-dimensional and color Doppler ultrasound in the evaluation of polycystic ovary syndrome <i>T. Shi (China)</i>	P11.09
3D power Doppler sonography in the evaluation of tubal patency <i>C. Phoon (Singapore)</i>	P11.10
Ovarian volume variability: a prospective reliability study that reveals difficulty in ovarian volume measurement <i>A. Insunza (Chile)</i>	P11.11
A case of an unusual presentation of the ovarian hyperstimulation syndrome <i>I. Mikyskova (Czech Republic)</i>	P11.12
Translabial 3D ultrasound in the diagnosis of congenital adrenal hyperplasia <i>E. Domali (Greece)</i>	P11.13
Suprapubic pain <i>L. Hereter (Spain)</i>	P11.14
Dysmenorrhoea and endometriosis in a 14 year old girl – a rare report <i>M. Bernardo (Portugal)</i>	P11.15

## P12: Fetal heart III: fetal cardiac function

	Abstract number
Reference ranges for fetal myocardial velocities and performance index using tissue Doppler at 24–41 weeks of gestation <i>F. Crispi (Spain)</i>	P12.01
Reference ranges for the Mod-MPI (modified myocardial performance index) in normal fetuses within an Australian population using the previously published technique and a new peak valve click selection technique <i>N. Meriki (Australia)</i>	P12.02
eFLOW in fetal echocardiography: a tool to enhance visualisation of the aortic arch <i>R. Napolitano (United Kingdom)</i>	P12.03
Diagnostic of tetralogy of fallot during the first trimester <i>P. Bouhanna (France)</i>	P12.04
The characteristics of congenital heart disease in twin pregnancy <i>L. Hui (China)</i>	P12.05
Indications for fetal echocardiography and diagnosis of congenital heart disease in Chosun University Hospital 1997 to 2008 <i>S. Choi (South Korea)</i>	P12.06
The prevalence of fetal cardiac defects among 'high risk' screened pregnant population <i>H. Mousa (United Kingdom)</i>	P12.07
Ductus venosus and umbilical vein flows in fetuses with atrial flutter and atrial fibrillation <i>A. Hamela-Olkowska (Poland)</i>	P12.08
Fetal cardiac function assessed by myocardial performance index in normal pregnancy <i>L. Guariglia (Italy)</i>	P12.09
Relationship between fetal chest size and biometric parameters by three-dimensional ultrasound using the multiplanar method <i>I. Britto (Brazil)</i>	P12.10
Prenatal serial echocardiograms in the management of fetuses at risk for congenital heart block: our experience <i>G. Nazzaro (Italy)</i>	P12.11
Heart stroke volume and cardiac output by 4D US using STIC in normal fetuses <i>L. Nardoza (Brazil)</i>	P12.12



	Abstract number
<b>P13: Preterm labour</b>	<b>North hall</b>
The effect of betamethasone on fetal movement, biophysical profile and fetal circulation in preterm fetuses <i>P. Pooransari (Islamic Republic of Iran)</i>	P13.01
Tissue elastography of uterine cervix – prediction of preterm delivery? <i>R. Schmitz (Germany)</i>	P13.02
Sequential cervical length measurement in determining cerclage in women with prior preterm birth or late abortion <i>H. Zhang (China)</i>	P13.03
Rescue cerclage: outcomes and predictors of success <i>A. Fuks (United States)</i>	P13.04
Reinforcing cervical cerclage following a failed 1st attempt <i>G. Daskalakis (Greece)</i>	P13.05
Non-invasive prediction of clinical infection in women with preterm labor: a model based on the ultrasound and laboratory parameters <i>S. Lee (South Korea)</i>	P13.06
The significance of fetal fibronectin in the early diagnosis for premature labor <i>H. Ding (China)</i>	P13.07
Serum markers for prediction of preterm delivery in threatened preterm labor <i>M. Kim (South Korea)</i>	P13.08
<b>P14: Adverse outcome of pregnancy and pelvic floor</b>	<b>Club A</b>
Two year outcomes following the institution of modified ADIPS ultrasound guidelines for diabetes in pregnancy <i>W. Giles (Australia)</i>	P14.01
Placental multiple chorionic cysts in maternal scleroderma <i>T. Shimada (Japan)</i>	P14.02
Ultrasound evaluation of systemic lupus erythematosus pregnancies <i>G. Lobo (Brazil)</i>	P14.03
Correlations between middle cerebral artery velocimetry and non stress test evaluation for the decision of Cesarean section after 41 weeks gestation <i>M. Poenaru (Romania)</i>	P14.04
Obstetric outcome associated with amniotic sheets <i>X. Zhang (Singapore)</i>	P14.05
The significance of umbilical cord insertion in term singleton pregnancies <i>H. Abu Subeih (Ireland)</i>	P14.06
The relationship of intrapartum amniotic fluid index and perinatal outcomes <i>K. Ulker (Turkey)</i>	P14.07
Rare localization of ectopic gravidity in the second trimester of pregnancy diagnosed by ultrasound <i>M. Bogavac (Serbia)</i>	P14.08
Cervico-isthmic pregnancy resulting in a live 26 week birth <i>D. Voges (Australia)</i>	P14.09
Atypical case of uterine rupture <i>N. Vecek (Croatia)</i>	P14.10
Effect of metformin therapy on fetal growth in women with pregestational diagnosis of polycystic ovary syndrome <i>P. Rosati (Italy)</i>	P14.11
First trimester maternal serum PAPP-A levels and macrosomia <i>E. Tarim (Turkey)</i>	P14.12
Private vs public obstetrical ultrasound in Lebanon <i>A. Kesrouani (Lebanon)</i>	P14.13
Towards economic assessment of screening for preeclampsia <i>A. Shmueli (Israel)</i>	P14.14
Elevated fetal DNA levels in maternal blood in the 14th week: a case report <i>R. Vlk (Czech Republic)</i>	P14.15
The early detection of placental protein 13 mRNA in maternal circulation does not predict later onset of preeclampsia <i>I. Hromadnikova (Czech Republic)</i>	P14.16
Change in the size of uterine myoma during pregnancy and its association with maternal BMI <i>H. Jeong (South Korea)</i>	P14.17
Fetal renal insufficiency following valsartan and trastuzumab in pregnancy: three case reports with different intrauterine course and outcome <i>J. Ritgen (Germany)</i>	P14.18
Diagnosis of primary megaureter with the aid of 3D ultrasonography: a case report <i>K. Ulker (Turkey)</i>	P14.19
Prenatal diagnosis of a large axillary cystic lymphangioma <i>S. Nam (South Korea)</i>	P14.20

# Posters – Tuesday 12 October 2010

	Abstract number
<b>P15: CNS II: fetal brain anomalies</b>	<b>Club E</b>
The development of spina bifida in a rat model <i>H. Wong (Australia)</i>	P15.01
First embryonic movements are executed rhythmically <i>J. de Vries (Netherlands)</i>	P15.02
Early visualization and measurement of the pericallosal artery: an indirect sign of the development of the corpus callosum <i>M. Pati (Italy)</i>	P15.03
Brain imaging in fetuses with hypoplastic left heart syndrome <i>M. Bebbington (United States)</i>	P15.04
Midtrimester diagnosis of Joubert syndrome by three-dimensional evaluation of fetal vermis <i>M. Caron (Canada)</i>	P15.05
To determine clinical features of corpus callosum agenesis, dysgenesis in conjunction with extraparenchymal interhemispheric cyst and neural migrations disorders <i>M. Herrera (Colombia)</i>	P15.06
Prenatally diagnosed central nervous system anomalies: a ten year experience <i>K. Karri (United Kingdom)</i>	P15.07
The risk of fetal abnormalities in pregnancies with acute parvovirus B19 infection <i>D. Nowakowska (Poland)</i>	P15.08
Prenatal diagnosis and postnatal outcomes in fetuses with vein of Galen malformation <i>E. Nekrasova (Russian Federation)</i>	P15.09
Congenital hydrocephalus in Saudi Arabia, prevalence, middle cerebral artery Doppler, and outcome <i>B. Sallout (Saudi Arabia)</i>	P15.10
Holoprosencephaly at prenatal ultrasound: different etiologies for the same ultrasound finding <i>W. Clavelli (Argentina)</i>	P15.11
Association between prenatal sonographic findings and neuromotor postnatal outcomes in 53 cases of open spina bifida <i>L. Nardoza (Brazil)</i>	P15.12
Comparison between ultrasound and MRI findings in fetuses with suspected brain anomalies <i>C. Hsieh (Taiwan)</i>	P15.13
Measurements of the posterior fossa on fetal MRI in open and closed neural tube defects <i>D. Prayer (Austria)</i>	P15.14
Antenatal sonographic diagnosis in fetus of periventricular leukomalacia <i>C. Xinlin (China)</i>	P15.15
Borderline ventriculomegalies diagnosed until the 2nd trimester of pregnancy: short- and long-term outcomes <i>L. Orosz (Hungary)</i>	P15.16
Normal intracranial translucency at 11–13+6 weeks in the Chinese population <i>C. Hsiao (Taiwan)</i>	P15.17

## Poster question and answer sessions: 15:40–16:00

Viewing available all week on E-poster viewing stations located in the level 2 foyer

	Abstract number
<b>P16: Early pregnancy II</b>	<b>Forum hall</b>
Comparing tubal and non-tubal ectopic pregnancies: a multicentre case series <i>C. Bottomley (United Kingdom)</i>	P16.01
How reliable is subjective impression in predicting pregnancy of unknown location outcome at 48 hours? Does this correlate with certainty of diagnosis? <i>S. Reid (Australia)</i>	P16.02
Developing an embryo volume nomogram to predict first trimester miscarriage <i>S. Sur (United Kingdom)</i>	P16.03
The influence of symptoms, uncertainty of dates and previous miscarriage on gestation sac growth <i>A. Pexsters (Belgium)</i>	P16.04
The use of a new logistic regression model for the prediction of successful expectant management of first trimester miscarriage: development and validation <i>I. Casikar (Australia)</i>	P16.05
Doppler artery parameters are not useful for the clinical management of retain product of conception <i>Y. Goldberg (Israel)</i>	P16.06
Conservative management of ectopic pregnancy: the pre-treatment serum human chorionic gonadotrophin (hCG) ratio <i>D. Alhamdan (Australia)</i>	P16.07
Is vascularization flow index useful in monitoring methotrexate treatment of ectopic pregnancies? <i>P. Szkodziak (Poland)</i>	P16.08
Sonographic appearance of a retroperitoneal ectopic pregnancy treated by robot assisted laparoscopy with temporary occlusion of the blood supply <i>E. Epstein (Sweden)</i>	P16.09

# Posters – Tuesday 12 October 2010

	Abstract number
Cornual pregnancy undiagnosed until 13 weeks gestation. A case report <i>G. Nazzaro (Italy)</i>	P16.10
Diagnosis and management of ectopic molar Caesarean scar pregnancy <i>N. Potdar (United Kingdom)</i>	P16.11
Management of cervical pregnancy <i>M. Elsheikh (United Kingdom)</i>	P16.12
Expectant management of interstitial pregnancy: a case report <i>M. Taylor-Clarke (United Kingdom)</i>	P16.13
Scar pregnancy: a diagnostic and management enigma <i>M. Taylor-Clarke (United Kingdom)</i>	P16.14
Combinated management of heterotopic Cesarean scar pregnancy <i>A. Rossi (Italy)</i>	P16.15
The efficiency and the limits of the ultrasound examination in pregnancy associated with an ovarian tumor <i>S. Lacziko (Romania)</i>	P16.16
Combined treatment of KCI and methotrexate in cervical pregnancy at 12 weeks gestational age: a case report <i>Y. Kim (South Korea)</i>	P16.17
Chlamydia trachomatis in fallopian tubes of women undergoing laparoscopy for ultrasound diagnosed ectopic pregnancy <i>D. Alhamdan (Australia)</i>	P16.18
Intrauterine pregnancy of uncertain viability: what influences outcome of the first trimester? <i>J. Riemke (Australia)</i>	P16.19
Cesarean scar pregnancy: diagnosis and ultrasound-guided methotrexate treatment <i>W. Longxia (China)</i>	P16.20

## P17: First trimester II: aneuploidy and anomalies

	<b>Panorama hall</b>
Yield of invasive diagnostic procedures by indications <i>M. Baumann (Switzerland)</i>	P17.01
Using chromosomal markers at the 11–13+6 weeks scan – our experience <i>A. Comanescu (Romania)</i>	P17.02
First trimester biochemical screening combined with fetal nuchal translucency, nasal bone and maternal age for Down syndrome in singleton pregnancies <i>K. Natasa (Serbia)</i>	P17.03
The evolution of indications for amniocentesis - four years experience after introduction of skrining programme <i>P. Wegrzyn (Poland)</i>	P17.04
Terminations because of fetal anomalies beyond week 11+6 in a Danish population screened in 1st and 2nd trimester <i>O. Petersen (Denmark)</i>	P17.05
Screening for trisomies and fetal anomalies in the second trimester after first trimester genetic scan. What are the benefits? <i>S. Tudorache (Romania)</i>	P17.06
Combined 1st trimester screening effectiveness according to FMF recommendations and corresponding frequency of invasive procedures <i>O. Solovyov (Ukraine)</i>	P17.07
Implementation of one-stop-clinic for risk assessment of chromosomal abnormalities in the Czech Republic (OSCAR) <i>I. Dhaifalah (Czech Republic)</i>	P17.08
The frequency of chromosomal abnormalities among fetuses with increased nuchal translucency: an 8 year experience in one cytogenetic clinic <i>K. Kim (South Korea)</i>	P17.09
Internal audit of the first trimester screening programme <i>H. Neumannova (Czech Republic)</i>	P17.10
First trimester screening for chromosomal abnormalities by fetal nuchal translucency in a Brazilian population <i>E. Fonseca (Brazil)</i>	P17.11
Nuchal translucency for detection of chromosomal abnormalities: a single center experience of 10 years in Brazil <i>C. Murta (Brazil)</i>	P17.12
Impact of the valuation of the secondary echographic markers in the intermediate- risks for first trimester screening of trisomy 21 <i>C. Martínez-Payo (Spain)</i>	P17.13
Absent flow during the atrial contraction in the ductus venosus Doppler: normal or abnormal? <i>C. Murta (Brazil)</i>	P17.14

## P18: Fetal anomalies I: fetal face and chest assessment

	<b>North hall</b>
A case of complex ocular choristomas with abnormal prenatal ultrasonographical findings <i>A. Fukuyama (Japan)</i>	P18.01
Prenatal ultrasonographic diagnosis of congenital hereditary cataracts in a dizygotic twin <i>K. Lee (South Korea)</i>	P18.02
Epiglottis–uvula distance: to be sure about soft palate integrity <i>J. Develay-Morice (France)</i>	P18.03
Prenatal ultrasound evaluation of the fetus with cheilognathopalatoschisis <i>D. Deva (Romania)</i>	P18.04

# Posters – Tuesday 12 October 2010

	Abstract number
Nasal polyp in the fetus – 3D ultrasound a useful tool <i>K. Beckmann (Germany)</i>	P18.05
A Brazilian reference for normal fetal nasal bone length at 18 to 34 weeks' gestation <i>E. Fonseca (Brazil)</i>	P18.06
Prenatal diagnosis of dacryocystocele <i>S. Wenling (China)</i>	P18.07
Fetal external ear observation on standard sections and the best time of ultrasound <i>M. Yang (China)</i>	P18.08
Comparison of second trimester ear length measured by two-dimensional and three-dimensional ultrasound. Preliminary results <i>G. Lobo (Brazil)</i>	P18.09
Hyperechogenic solid masses of lungs: prenatal diagnosis and outcome <i>P. Hanulikova (Czech Republic)</i>	P18.10
Unilateral pulmonary agenesis: prenatal imaging and outcome in three cases <i>A. Kennedy (United States)</i>	P18.11
Congenital high airway obstruction syndrome and duodenal atresia: an unusual combination <i>J. Coletta (United States)</i>	P18.12
Spontaneous resolution of fetal pleural effusion <i>E. Dunn (Ireland)</i>	P18.13
Prenatal ultrasonographic findings of a fetal dorsal giant congenital nevus <i>G. Nazzaro (Italy)</i>	P18.14
A case of thoracic kidney, prenatally diagnosed by ultrasonography <i>S. Lee (South Korea)</i>	P18.15
One case of mixed gonadal dysgenesis <i>J. Duyos (Spain)</i>	P18.16
The role of placental location assessment in the prediction of fetal gender <i>S. The (Australia)</i>	P18.17
<b>P19: Multiple pregnancy II</b>	<b>Club A</b>
Second trimester gestational age assessment in twins: validation of singleton biometry charts <i>T. Dias (United Kingdom)</i>	P19.01
Uterine artery Doppler in twin pregnancies and the incidence of preeclampsia <i>E. Maroni (Italy)</i>	P19.02
Fetal venous Doppler velocimetry in twin pregnancies with placental insufficiency <i>R. Nomura (Brazil)</i>	P19.03
Longitudinal measurements of pulsatility indices in the middle cerebral and umbilical artery in monochorionic diamniotic twins <i>P. Klaritsch (Belgium)</i>	P19.04
Obstetric and perinatal outcomes in triplet pregnancies in relation to chorionicity <i>C. Zanardini (Italy)</i>	P19.05
Analysis of a cohort of women with twin pregnancy and shortened cervix <i>W. Giles (Australia)</i>	P19.06
Cervical length changes and the risk of preterm delivery in triplet pregnancies <i>A. Youssef (Italy)</i>	P19.07
Ultrasound-indicated cervical cerclage in triplets: does it make a difference? <i>V. Moragianni (United States)</i>	P19.08
Cervical length changes in twin and triplet pregnancies <i>M. Nanni (Italy)</i>	P19.09
Spontaneous degeneration of a hydatidiform mole in a twin pregnancy with coexisting fetus <i>F. Lenz (Germany)</i>	P19.10
Twin pregnancy with a complete hydatidiform mole and co-existent fetus <i>V. Marsoosi (Islamic Republic of Iran)</i>	P19.11
Management of abnormal foetus in multiple pregnancies <i>D. Smetanova (Czech Republic)</i>	P19.12
Monoamniotic twin discordant for meningoencephalocele managed conservatively with good outcome: case report and review of the literature <i>E. Sleurs (Belgium)</i>	P19.13
Twin pregnancy complicated by single intrauterine death. Report of twenty cases <i>O. Mircea (Romania)</i>	P19.14
Clinical report on the cases of the heterotopic pregnancies treated by selective fetal reduction procedure <i>H. Cho (South Korea)</i>	P19.15
Heterotopic cervical pregnancy – conservative treatment: a case report <i>A. Hudec (Czech Republic)</i>	P19.16
Quadruple pregnancy after double embryo transfer <i>C. Murta (Brazil)</i>	P19.17

# Posters – Tuesday 12 October 2010

	Abstract number
<b>P20: Imaging technologies II</b>	<b>Club E</b>
Fetal MRI as an adjunct to ultrasound examination in selected cases: a UK tertiary fetal medicine unit experience <i>U. Agarwal (United Kingdom)</i>	P20.01
Fetal magnetic resonance imaging – reasons for referral <i>E. Whitby (United Kingdom)</i>	P20.02
Co-relation of magnetic resonance imaging with antenatal ultrasound findings, and the effect on management, in the evaluation of the fetal abdomen <i>S. Gandhi (United Kingdom)</i>	P20.03
Comparative study of congenital anomalies evaluated by two-dimensional and three-dimensional sonography <i>A. Carmo (Brazil)</i>	P20.04
Placental weight, cord insertion, shape and cord coiling in hypertensive disorders of pregnancy <i>S. Pathak (United Kingdom)</i>	P20.05
The use of oblique planes in assessing fetal cleft palate in stored 3D ultrasound volumes of fetal face <i>H. Wong (Australia)</i>	P20.06
Interhemispheric variant of holoprosencephaly (MIH) or syntelencephaly: the role of fetal brain MRI in differential diagnosis <i>R. Ximenes (Brazil)</i>	P20.07
Monochorionic twin pregnancy complicated by concordant CHAOS, truncus arteriosus and VSD <i>A. Carlin (Australia)</i>	P20.08
Mesenchymal tumor of the liver and placental mesenchymal dysplasia in a patient with pregnancy induced hypertension: a rare case report <i>A. Ceran (Poland)</i>	P20.09
Posterior reversible encephalopathy occurring late postpartum <i>H. Lee (South Korea)</i>	P20.10
Fetal teratoma – the role of fetal MRI to plan the management of the patient <i>E. Whitby (United Kingdom)</i>	P20.11
Prenatal diagnosis of congenital aphakia <i>S. Stojic (Serbia)</i>	P20.12
A case of congenital depression of the neonatal skull unassociated with birth trauma <i>J. Shin (South Korea)</i>	P20.13

# Program – Wednesday 13 October 2010

07:45–08:30 'All you ever wanted to know' afternoon sessions must be pre-booked at the registration desk. See page 11 for details

09:00–10:00 Maternal fetal Doppler		Congress hall
	<i>Chairs: S. Eik-Nes (Norway); P. Calda (Czech Republic)</i>	
09:00	Overview <i>S. Eik-Nes (Norway)</i>	
09:05	Live scan demonstration: optimising maternal fetal Doppler (supported by Philips*) <i>A. Papageorghiu (United Kingdom)</i>	
09:20	Tissue Doppler imaging: the effect of maternal diabetes on fetal cardiac kinetics <i>J. Ritgen; P. Kozłowski; R. Stressig (Germany)</i>	OC18.01
09:25	Discussion	
09:28	High-amplitude inspiratory movement in the fetus obstructs the inferior vena cava enhancing upper body gas transport <i>M. Nyberg; S. Johnsen; T. Kiserud (Norway)</i>	OC18.02
09:33	Discussion	
09:36	The development of hepatic arterial and venous blood flow patterns in macrosomic fetuses <i>C. Ebbing<sup>1</sup>; S. Rasmussen<sup>1</sup>; K. Godfrey<sup>2</sup>; M. Hanson<sup>2</sup>; T. Kiserud<sup>1</sup>(Norway); <sup>2</sup>(United Kingdom)</i>	OC18.03
09:41	Discussion	
09:44	Direct measurement of blood flow into the intervillous space and its relationship with uterine artery waveform and the small for gestational age baby <i>S. Collins; J. Birks; A. Papageorghiu; L. Impey (United Kingdom)</i>	OC18.04 and OC18.05
09:49	Discussion	
09:52	Maternal cardiac systolic and diastolic function in term pre-eclampsia <i>K. Melchiorre; I. Watt-Coote; A. Papageorghiu; G. Sutherland; B. Thilaganathan (United Kingdom)</i>	OC18.06
09:57	Discussion	

09:00–10:00 Diagnosis and management of ovarian pathology		Forum hall
	<i>Chairs: D. Timmerman (Belgium); B. Benacerraf (United States)</i>	
09:00	Sonographic features of specific subgroups of adnexal masses <i>L. Savelli (Italy)</i>	
09:20	Additional value of CA-125 to ultrasound for predicting specific diagnosis of benign adnexal cysts in premenopausal women <i>J. Alcazar<sup>1</sup>; S. Guerriero<sup>2</sup>; C. Laparte<sup>1</sup>; S. Ajossa<sup>2</sup>; J. Minguez<sup>1</sup>; M. Angiolucci<sup>2</sup>; M. Garcia Manero<sup>1</sup>; G. Melis<sup>2</sup><sup>1</sup>(Spain); <sup>2</sup>(Italy)</i>	OC19.01
09:25	Discussion	
09:28	<sup>^</sup> Intra- and inter-observer agreement in the assessment of three-dimensional ultrasound volumes of adnexal masses using IOTA criteria <i>P. Sladkevicius; L. Valentin (Sweden)</i>	OC19.02
09:33	Discussion	
09:36	Contrast-enhanced sonography in the preoperative diagnosis of ovarian tumors considered difficult to classify by ultrasound examiners <i>L. Veyer; H. Marret; A. Bleuzen; E. Simon; L. Ouldamer; G. Body; F. Tranquart (France)</i>	OC19.03
09:41	Discussion	
09:44	Diagnostic performance of transvaginal gray-scale ultrasound for specific diagnosis of common benign ovarian cysts related to menopausal status <i>J. Alcazar<sup>1</sup>; S. Guerriero<sup>2</sup>; C. Laparte<sup>1</sup>; S. Ajossa<sup>2</sup>; A. Ruiz Zambrana<sup>1</sup>; G. Melis<sup>2</sup><sup>1</sup>(Spain); <sup>2</sup>(Italy)</i>	OC19.04
09:49	Discussion	
09:52	Summary <i>B. Benacerraf (United States)</i>	

09:00–10:00 In-utero interventions		Panorama hall
	<i>Chairs: Y. Ville (France); A. Tabor (Denmark)</i>	
09:00	Overview <i>Y. Ville (France)</i>	
09:05	What is the real loss rate from invasive testing? <i>A. Tabor (Denmark)</i>	
09:20	Inferring risk factors for limb amputation in extremity amniotic band. Results from an experimental ultrasound and Doppler ovine model <i>J. Bello-Muñoz; F. Soldado; G. Villagomez Martinez; J. Peiró; E. Carreras Moratonas; L. Cabero (Spain)</i>	OC20.01
09:25	Discussion	

# Program – Wednesday 13 October 2010

09:28	Evaluation of intrapulmonary Doppler in prediction of morbidity in fetuses with congenital diaphragmatic hernia treated with fetal endoscopic tracheal occlusion <i>R. Cruz-Martinez; O. Moreno-Alvarez; J. Martinez; B. Puerto; E. Hernandez-Andrade; E. Gratacós (Spain)</i>	OC20.02
09:33	Discussion	
09:36	Sonographic findings before and after maternal administration of hyperimmune globulin in women with fetal cytomegalovirus infection <i>N. Gussetti; S. Visentin; R. Manara; V. Citton; E. Salviato; E. Cosmi (Italy)</i>	OC20.03
09:41	Discussion	
09:44	Maternal obesity and fetal loss rates from prenatal invasive procedures <i>A. Odibo; A. Cahill; G. Macones; J. Crane (United States)</i>	OC20.04
09:49	Discussion	
09:52	Childhood cardiac function following severe fetal red cell isoimmunization <i>J. Dickinson; J. Sharpe; T. Warner; E. Nathan; L. D'Orsogna (Australia)</i>	OC20.05
09:57	Discussion	

## 10:00–10:40 Short oral presentation (oral poster) sessions

### 10:40–10:55 Electronic posters: author questions

10:00	<b>OP21: Managing ovarian masses</b>	Forum hall
10:40	<b>P21: Managing ovarian masses</b> <i>Chairs: C. Van Holsbeke (Belgium); L. Valentin (Sweden)</i>	
10:00	<b>OP22: Fetal heart IV: 3D/4D ultrasound</b>	Panorama hall
10:40	<b>P22: Fetal heart IV</b> <i>Chairs: J. Carvalho (United Kingdom); J. Copel (United States)</i>	
10:00	<b>OP23: First trimester III: anomalies</b>	North hall
10:40	<b>P23: Incomplete splitting in multiple pregnancy</b> <i>Chairs: J. Sonek (United States); K. Kagan (Germany)</i>	
10:00	<b>OP24: Maternal fetal Doppler I</b>	Club A
10:40	<b>P24: Maternal fetal Doppler</b> <i>Chairs: S. Gudmundsson (Sweden); F. Figueras (Spain)</i>	
10:00	<b>OP25: CNS III: 3D ultrasound in fetal brain anomalies</b>	Club E
10:40	<b>P25: CNS III: 3D ultrasound in fetal brain anomalies</b> <i>Chairs: G. Pilu (Italy); G. Malinge (Israel)</i>	

## 10:30–11:00 Coffee and electronic poster viewing Exhibition area

## 11:00–12:30 Workshop: fetal surveillance Congress hall

	<i>Chairs: K. Hecher (Germany); C. Bilardo (Netherlands)</i>
11:00	Doppler monitoring <i>C. Bilardo (Netherlands)</i>
11:15	Biophysical monitoring <i>L. Platt (United States)</i>
11:30	Live scan demonstration: the monitoring scan (supported by Siemens*) <i>C. Lees (United Kingdom)</i>
11:50	Monitoring interval and intervention for specific conditions <i>A. Baschat (United States)</i>
12:05	Panel discussion

## 11:00–12:30 Scanning asymptomatic women – cancer screening Forum hall

	<i>Chairs: L. Valentin (Sweden); T. Van den Bosch (Belgium)</i>	
11:00	The current state of the UKTOCS trial: CA 125 or ultrasound for ovarian cancer screening – or nothing? <i>S. Campbell (United Kingdom)</i>	
11:15	Screening for uterine tumours <i>T. Van den Bosch (Belgium)</i>	
11:30	How to manage 'chance findings' of pelvic pathology <i>L. Valentin (Sweden)</i>	
11:45	Expectant management for sonographically benign cysts in asymptomatic premenopausal women: long term follow-up study <i>J. Alcazar<sup>1</sup>; B. Olartecoechea<sup>1</sup>; S. Guerrero<sup>2</sup>; S. Ajossa<sup>2</sup>; G. Melis<sup>2</sup>; M. Jurado<sup>1</sup> (Spain); <sup>2</sup>(Italy)</i>	OC21.01
11:50	Discussion	
11:53	Incidence and regression of functional ovarian cysts <i>M. Pascual; B. Graupera; L. Hereter; C. Pedrero; M. Fernandez-Cid; A. Rotili (Spain)</i>	OC21.02

\* Scientific content of live scan sessions is defined by ISUOG. Ultrasound systems and technical support are provided by sponsors.

# Program – Wednesday 13 October 2010

11:58	Discussion	
12:01	Natural history of asymptomatic endometrial polyps in postmenopausal women: a 10-year follow-up study <i>F. Leone; C. Marciante; C. Lanzani; E. Ferrazzi (Italy)</i>	OC21.03
12:06	Discussion	
12:09	Endometrial thickness and the prevalence of endometrial carcinoma in asymptomatic postmenopausal patients, a systematic review of the literature <i>M. Breijer; J. Peeters; B. Opmeer; B. Mol; A. Timmermans (Netherlands)</i>	OC21.04
12:14	Discussion	
12:17	Saline contrast sonohysterography with liquid-based endometrial cytology in post-menopausal patients <i>F. Leone; C. Marciante; A. Crepaldi; F. Pagano; M. Antonacci; G. Tosi; G. Vago; E. Ferrazzi (Italy)</i>	OC21.05
12:22	Discussion	
12:25	Summary <i>L. Valentin (Sweden)</i>	

## 11:00–12:30 Workshop: ultrasound in labour Panorama hall

*Chairs: T. Ghi (Italy); K. Salvesen (Norway)*

11:00	An update on mechanical complications of labour <i>G. Pilu (Italy)</i>
11:20	Ultrasound in the second stage <i>K. Kalache (Germany)</i>
11:40	3D ultrasound in the second stage <i>T. Ghi (Italy)</i>
12:00	Ultrasound in peripartum complications <i>K. Salvesen (Norway)</i>
12:20	Discussion

## 12:30–14:00 Lunch and electronic poster viewing Exhibition area

## 12:45–13:45 GE satellite symposium\*\* Congress hall

All about quality

## 14:00–15:00 Long term outcome in fetal growth restriction Congress hall

*Chairs: K. Maršál (Sweden); K. Hecher (Germany)*

14:00	Overview <i>K. Maršál (Sweden)</i>	
14:05	Live scan demonstration: central fetal haemodynamics (supported by Toshiba*) <i>C. Brezinka (Austria)</i>	
14:20	Neurobehavioral outcome of early-onset growth restricted fetuses with and without brain sparing <i>F. Figueras; R. Cruz-Martinez; M. Sanz-Cortes; N. Padilla; F. Botet; A. Arranz; C. Carmen; E. Gratacós (Spain)</i>	OC22.01
14:25	Discussion	
14:28	Combination of the aortic isthmus with ductus venosus improves the prediction of neurological damage in early-onset intrauterine growth restricted fetuses <i>R. Cruz-Martinez; F. Figueras; V. Tenorio; D. Valsky; A. Arranz; F. Crispi; E. Hernandez-Andrade; E. Gratacós (Spain)</i>	OC22.02
14:33	Discussion	
14:36	Cognitive function following intrauterine growth restriction and very preterm birth <i>E. Morsing; M. Åsard; D. Ley; K. Stjernqvist; K. Marsal; J. Brodzki (Sweden)</i>	OC22.03
14:41	Discussion	
14:44	Cardiovascular remodeling in children who suffered growth restriction in utero <i>F. Crispi<sup>1</sup>; B. Bijmens<sup>1</sup>; F. Figueras<sup>1</sup>; J. Bartrons<sup>1</sup>; E. Eixarch<sup>1</sup>; F. Le Noble<sup>2</sup>; A. Ahmed<sup>3</sup>; E. Gratacós<sup>1</sup></i> <sup>1</sup> (Spain); <sup>2</sup> (Germany); <sup>3</sup> (United Kingdom)	OC22.04
14:49	Discussion	
14:52	# Vascular properties and vascular function at early school age following IUGR with abnormal fetal blood flow and very preterm birth <i>E. Morsing; K. Marsal; J. Brodzki (Sweden)</i>	OC22.05
14:57	Discussion	

## 14:00–15:00 Mathematical models and new second stage tests to assess the ovary Forum hall

*Chairs: T. Bourne (United Kingdom); L. Savelli (Italy)*

14:00	Overview of the IOTA project and next steps <i>D. Timmerman (Belgium)</i>
-------	--

\* Scientific content of live scan sessions is defined by ISUOG. Ultrasound systems and technical support are provided by sponsors.

\*\* Lunchtime satellite symposia are brought to you by our sponsors and are not part of the ISUOG CME program. ISUOG takes no responsibility for scientific or clinical content.

# This presentation is eligible for the Young Investigator award (to be presented at the closing ceremony).



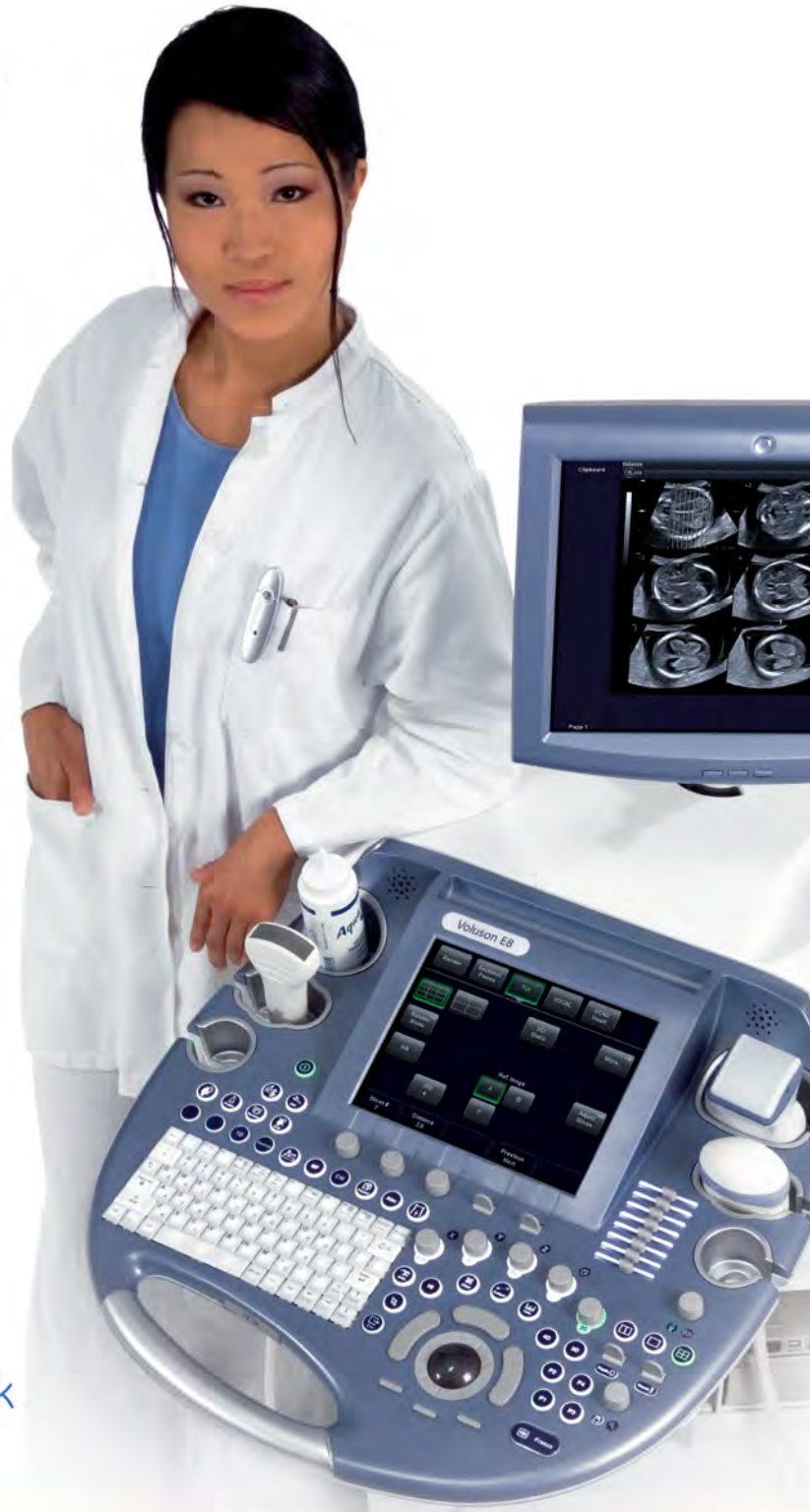GE Healthcare

# Ultrasound is our Baby.

## VOLUSON E8 EXPERT BT 10'

- Fetal examination Expert tools
- First trimester anatomical quality imaging
- Matrix and High Frequency Volume transducers
- Sono-NT - Automated NT Measurement Package
- Speckle Reduction Imaging specific to different organs

For more information  
please visit: [www.gehealthcare.com](http://www.gehealthcare.com)



GE imagination at work

# Program – Wednesday 13 October 2010

14:20	New logistic regression model to predict ovarian malignancy in cases for which simple ultrasound rules are not applicable <i>L. Ameye<sup>1</sup>; D. Fischerova<sup>2</sup>; L. Valentin<sup>3</sup>; E. Epstein<sup>3</sup>; F. Leone<sup>4</sup>; G. Melis<sup>4</sup>; S. Guerriero<sup>4</sup>; C. Van Holsbeke<sup>1</sup>; J. Veldman<sup>1</sup>; L. Savelli<sup>4</sup>; R. Fruscio<sup>4</sup>; A. Lissoni<sup>4</sup>; A. Testa<sup>4</sup>; I. Vergote<sup>1</sup>; S. Van Huffel<sup>1</sup>; B. Van Calster<sup>1</sup>; D. Timmerman<sup>1</sup></i> <i><sup>1</sup>(Belgium); <sup>2</sup>(Czech Republic); <sup>3</sup>(Sweden); <sup>4</sup>(Italy)</i>	OC23.01
14:25	Discussion	
14:28	Which histologies limit the ability of CA-125 to characterize adnexal masses? An observational study of 3511 patients <i>B. Van Calster<sup>1</sup>; C. Van Holsbeke<sup>1</sup>; J. Zhang<sup>2</sup>; D. Jurkovic<sup>3</sup>; A. Lissoni<sup>4</sup>; L. Valentin<sup>5</sup>; A. Testa<sup>4</sup>; A. Czekierdowski<sup>6</sup>; D. Fischerova<sup>7</sup>; G. Van de Putte<sup>1</sup>; I. Vergote<sup>1</sup>; S. Van Huffel<sup>1</sup>; T. Bourne<sup>1,3</sup>; D. Timmerman<sup>1</sup></i> <i><sup>1</sup>(Belgium); <sup>2</sup>(China); <sup>3</sup>(United Kingdom); <sup>4</sup>(Italy); <sup>5</sup>(Sweden); <sup>6</sup>(Poland); <sup>7</sup>(Czech Republic)</i>	OC23.02
14:33	Discussion	
14:36	Accuracy of diagnostic parameters used for contrasted sonography of ovarian masses <i>A. Fleischer; A. Lyshchik; D. Fishman (United States)</i>	OC23.03
14:41	Discussion	
14:44	Which adnexal masses are difficult to classify as benign or malignant with prediction models? <i>B. Van Calster<sup>1</sup>; A. Czekierdowski<sup>2</sup>; R. Fruscio<sup>3</sup>; G. Melis<sup>3</sup>; S. Guerriero<sup>3</sup>; L. Savelli<sup>3</sup>; C. Van Holsbeke<sup>1</sup>; W. Ombelet<sup>1</sup>; S. Van Huffel<sup>1</sup>; I. Vergote<sup>1</sup>; L. Valentin<sup>4</sup>; T. Bourne<sup>1,5</sup>; D. Timmerman<sup>1</sup></i> <i><sup>1</sup>(Belgium); <sup>2</sup>(Poland); <sup>3</sup>(Italy); <sup>4</sup>(Sweden); <sup>5</sup>(United Kingdom)</i>	OC23.04
14:49	Discussion	
14:52	Summary <i>T. Bourne (United Kingdom)</i>	

## 15:00–15:40 Short oral presentation (oral poster) sessions

### 15:40–16:00 Electronic posters: author questions

15:00	<b>OP26: Pelvic floor</b>	Forum hall
15:40	<b>P26: Pelvic floor</b> <i>Chairs: J. Deprest (Belgium); S. Yagel (Israel)</i>	
15:00	<b>OP27: Fetal therapy</b>	Panorama hall
15:40	<b>P27: In utero interventions</b> <i>Chairs: Y. Ville (France); G. Lingman (Sweden)</i>	
15:00	<b>OP28: Fetal anomalies II: second and third trimester</b>	North hall
15:40	<b>P28: Fetal anomalies II: second and third trimester</b> <i>Chairs: T. Shipp (United States); B. Tutschek (Switzerland)</i>	
15:00	<b>OP29: IUGR II</b> <i>Chairs: A. Papageorghiou (United Kingdom); F. Figueras (Spain)</i>	Club A
15:00	<b>OP30: Placenta pathologies and uterine scar</b>	Club E
15:40	<b>P30: Placenta pathologies and uterine scar</b> <i>Chairs: S. Campbell (United Kingdom); S. Lipitz (Israel)</i>	

### 15:40–16:10 Coffee and electronic poster viewing Exhibition area

## 16:00–17:30 Workshop: the spectrum of 3D/4D ultrasound in prenatal diagnosis Congress hall

	<i>Chairs: H. Blaas (Norway); L. Platt (United States)</i>	
16:00	The use of 3D to calculate volumes <i>H. Blaas (Norway)</i>	
16:10	3D of the fetal skeleton <i>L. Gindes (Israel)</i>	
16:25	Fetal volumetry in clinical practice <i>W. Lee (United States)</i>	
16:40	3D/4D ultrasound of the face and palate <i>E. Merz (Germany)</i>	
16:55	3D ultrasound of the fetal brain <i>I. Timor-Tritsch (United States)</i>	
17:15	Live scan demonstration (supported by Medison*) <i>L. Platt (United States)</i>	

# Program – Wednesday 13 October 2010

## 16:00–17:30 Workshop: use of ultrasound in gynecological oncology Forum hall

- Chairs: D. Cibula (Czech Republic); E. Epstein (Sweden)*
- 16:00 Local staging of cervical carcinoma  
*D. Fischerova (Czech Republic)*
- 16:15 Live scan demonstration (supported by Philips\*)  
*D. Fischerova (Czech Republic)*
- 16:25 Evaluating the presence of metastasis and recurrence in ovarian cancer  
*A. Testa (Italy)*
- 16:40 Live scan demonstration (supported by Philips\*)  
*D. Fischerova (Czech Republic)*
- 16:50 Assessing cervical and myometrial invasion in endometrial cancer  
*L. Savelli (Italy)*
- 17:05 Live scan demonstration (supported by Philips\*)  
*D. Fischerova (Czech Republic)*
- 17:15 Summary and panel discussion  
*D. Cibula (Czech Republic)*

## 16:00–17:30 Workshop: how fetal conditions affect the heart Panorama hall

- Chairs: J. Carvalho (United Kingdom); Y. Ville (France)*
- 16:00 Techniques in assessing fetal heart function  
*S. Yagel (Israel)*
- 16:20 IUGR  
*E. Gratacós (Spain)*
- 16:35 TTTS  
*J. Rychik (United States)*
- 16:50 CDH  
*J. Carvalho (United Kingdom)*
- 17:05 Parvovirus infection  
*Y. Ville (France)*

17:50–18:35 'All you ever wanted to know' afternoon sessions must be pre-booked at the registration desk. See page 11 for details



# Short oral presentations – Wednesday 13 October 2010

**Chaired short oral presentation (oral poster) sessions: 10:00–10:40**

**Viewing available all week on E-poster viewing stations located in the level 2 foyer**

	Abstract number
<b>OP21: Managing ovarian masses</b>	<b>Forum hall</b>
<i>Chairs: C. Van Holsbeke (Belgium); L. Valentin (Sweden)</i>	
Ultrasound-guided interventional therapy of recurrent ovarian chocolate cysts <i>X. Dong (China)</i>	OP21.01
<sup>^</sup> Three-dimensional power Doppler angiography as a third step technique for differential diagnosis of adnexal masses: a prospective multicenter study <i>J. Alcazar (Spain)</i>	OP21.02
Inversion image analysis and Doppler: a novel technique to differentiate between malignant and benign ovarian masses during ultrasound examination <i>E. Domali (Greece)</i>	OP21.03
Ultrasound evaluation of pelvic masses using pelvic masses score system <i>A. Rossi (Italy)</i>	OP21.04
Sonographic follow-up of unilocular >5cm and multilocular ovarian cysts <7cm in post-menopausal women: preliminary results <i>F. Leone (Italy)</i>	OP21.05
Diagnostic performance of transvaginal power Doppler ultrasound for predicting malignancy of adnexal masses in symptomatic and asymptomatic women <i>J. Alcazar (Spain)</i>	OP21.06
Gray-scale ultrasound and Ca-125 levels for diagnosing ovarian cancer in more than 1700 women <i>S. Guerriero (Italy)</i>	OP21.07
The value of pre-operative ultrasound in triaging women with adnexal pathology for advanced laparoscopic surgery <i>D. Alhamdan (Australia)</i>	OP21.08
<b>OP22: Fetal heart IV: 3D/4D ultrasound</b>	<b>Panorama hall</b>
<i>Chairs: J. Carvalho (United Kingdom); J. Copel (United States)</i>	
Diagnosis of the complicated heart defect from STIC volumes <i>J. Dangel (Poland)</i>	OP22.01
Comparison of diagnostic ability of fetal echocardiography with and without 3D/4D US <i>S. Yagel (Israel)</i>	OP22.02
4D angiogram in particular cardio-thoracic arterial anomalies <i>L. Gindes (Israel)</i>	OP22.03
Effectiveness of 4D-STIC echocardiography for conotruncal anomalies diagnosis <i>M. Bennasar (Spain)</i>	OP22.04
Training non-expert sonographers to obtain STIC volumes and perform comprehensive fetal echocardiography using 3D/4D US applications <i>S. Yagel (Israel)</i>	OP22.05
Nomogram of fetal atrioventricular valves area measured with STIC <i>P. Nowak (Brazil)</i>	OP22.06 and OP22.07
A quantitative study of the spatial angles among cardiac chambers and great vessels in the normal fetuses by spatiotemporal image correlation <i>Z. Xie (China)</i>	OP22.08
Simultaneous real-time imaging of the 4-chamber view and left ventricular outflow tract using the xPlane imaging capabilities of a matrix array transducer <i>K. Leung (China)</i>	OP22.09
<b>OP23: First trimester III: anomalies</b>	<b>North hall</b>
<i>Chairs: J. Sonek (United States); K. Kagan (Germany)</i>	
Trends in the timing and rate of diagnosis of major congenital anomalies after introduction of the routine first trimester screen <i>P. Dar (United States)</i>	OP23.01
Early detection of major cardiac defects in fetuses with thick NT <i>V. Gurumurthy (Singapore)</i>	OP23.02
Early prenatal diagnosis of major anomalies is associated with increased pregnancy termination <i>J. Gebb (United States)</i>	OP23.03
First trimester ultrasonography in detection of fetal anomalies <i>S. Sollazzi (Italy)</i>	OP23.04
Diagnosis and counseling of women with single umbilical artery should be confined to first-trimester <i>J. Szabó (Hungary)</i>	OP23.05
Fetal omphalocele at 11–14 weeks scan: limitations in prognostical assessment <i>A. Bergann (Germany)</i>	OP23.06
Evaluation of umbilical cord insertion site at 9–13 weeks of gestation could predict vasa previa as a screening for placental abnormalities <i>J. Hasegawa (Japan)</i>	OP23.07

# Short oral presentations – Wednesday 13 October 2010

	Abstract number
Early pregnancy differentiation of lethal and non-lethal skeletal dysplasias <i>A. Khalil (United Kingdom)</i>	OP23.08
Did first trimester screening can affirm kidneys agenesis or presence? <i>J. Develay-Morice (France)</i>	OP23.09
The petrous part of the temporal bone as demonstrated by transvaginal ultrasound between 14–16 weeks of gestation <i>M. Odeh (Israel)</i>	OP23.10
<b>OP24: Maternal fetal Doppler I</b>	<b>Club A</b>
<i>Chairs: S. Gudmundsson (Sweden); F. Figueras (Spain)</i>	
Ultrasonography evaluate the effects of maternal Valsalva maneuver on fetal breathing movement and haemodynamics <i>G. Lv (China)</i>	OP24.01
Fetal abdominal venous return to the right atrium <i>R. Hershkovitz (Israel)</i>	OP24.02
Venous liver blood flow and regulation of human fetal growth: evidence from macrosomic fetuses <i>J. Kessler (Norway)</i>	OP24.03
Time-related analysis of ductus venosus flow velocity waveforms in normal singleton pregnancies <i>D. Tachibana (Japan)</i>	OP24.04
Effects of indomethacin on central and peripheral fetal Doppler during the second and early third trimester: evidence of clinically insignificant qualitative changes <i>A. Kofinas (United States)</i>	OP24.05
Pregnancies complicated by altered flow velocity waveform of the umbilical artery at 20–25 weeks of gestation: perinatal and long-term outcomes <i>A. Curti (Italy)</i>	OP24.06
Prediction of moderate fetal anemia risk by longitudinal assessments of middle cerebral artery peak systolic velocity <i>M. Pětroš (Czech Republic)</i>	OP24.07
Influence of the pressure of acoustic probe on the fetal middle cerebral artery during the second and third trimester pregnancy <i>G. Lv (China)</i>	OP24.08
Time-averaged maximum perfusion: improvement of the fractional moving blood volume value using a 2D cine-loop <i>J. Benavides (Mexico)</i>	OP24.09
Placental activity during first trimester is increased in first pregnancies <i>I. Järvelä (Finland)</i>	OP24.10
<b>OP25: CNS III: 3D ultrasound in fetal brain anomalies</b>	<b>Club E</b>
<i>Chairs: G. Pilu (Italy); G. Malinger (Israel)</i>	
How accurate is the offline analysis of 3D volume datasets in the diagnosis of fetal brain abnormalities? <i>H. Mousa (United Kingdom)</i>	OP25.01
The use of the 3D-sonography in the visualization of corpus callosum at the anomaly scan at 22 gestational weeks: a prospective study <i>K. Heling (Germany)</i>	OP25.02
The usefulness of 3D ultrasonography in determining the level of open spina bifida in the second trimester <i>S. Buyukkurt (Turkey)</i>	OP25.03
Does proximity to the transducer influences accuracy of fetal lateral ventricle volume measurement by transabdominal 3D sonography compared to MRI? <i>P. Nowak (Brazil)</i>	OP25.04
Remote telemedicine consultation for fetal brain anomalies. Pilot study transferring 3D volume datasets and MRI sequences through the internet <i>F. Viñals (Chile)</i>	OP25.05
Cranial to cerebral hemisphere biometric ratios to objectively define brain atrophy in the fetus: a retrospective 3D study <i>D. Paladini (Italy)</i>	OP25.06
Prospective evaluation of 3D fetal neurosonography (3D CNS) and MRI as combined tools in fetuses with brain anomalies. Experience of a single center <i>F. Viñals (Chile)</i>	OP25.07
3D evaluation of normal and abnormal cavum septum pellucidum. Qualitative assessment and its suitability for differential diagnosis of CNS anomalies <i>F. Viñals (Chile)</i>	OP25.08
Assessment of fetal CNS and facial anatomy using 2D and 3D ultrasound examination by a beginner <i>F. Yang (China)</i>	OP25.09
Reproducibility of three-dimensional volume measurements in the evaluation of fetal lateral ventricles using VOCAL method <i>G. Lobo (Brazil)</i>	OP25.10

# Short oral presentations – Wednesday 13 October 2010

**Chaired short oral presentation (oral poster) sessions: 15:00–15:40**

**Viewing available all week on E-poster viewing stations located in the level 2 foyer**

Abstract number

## OP26: Pelvic floor

**Forum hall**

Chairs: *J. Deprest (Belgium); S. Yagel (Israel)*

How does the anal sphincter fare in women with avulsion defects?

OP26.01

*V. Eisenberg (Israel)*

^ Pelvic floor function and anatomy in patients with vesicovaginal fistula

OP26.02

*H. Dietz (Australia)*

Transperineal ultrasound and clinical examination for pelvic organ prolapse correlate better if both are performed in a one stop clinic

OP26.03

*M. Konstantinovic (Belgium)*

Reliability of three-dimensional ultrasound measurements of the levator ani hiatus using virtual reality

OP26.04

*A. Steensma (Netherlands)*

Does the 'ship in dock' theory hold water?

OP26.05

*H. Dietz (Australia)*

Is the Valsalva/Rest ratio for area the 'levator elasticity index'?

OP26.06

*V. Eisenberg (Israel)*

Reflex contraction of the levator ani and external perineal muscles in women symptomatic for pelvic floor disorders

OP26.07

*H. Dietz (Australia)*

Preoperative ultrasound measurements of genital hiatus are not different between patients with and without de novo recurrence after anterior vaginal repair

OP26.08

*M. Konstantinovic (Belgium)*

Mesh contraction: myth or reality?

OP26.09

*H. Dietz (Australia)*

Unexpectedly high levator avulsion rates in a tertiary referral urogynecological service

OP26.10

*V. Eisenberg (Israel)*

## OP27: Fetal therapy

**Panorama hall**

Chairs: *Y. Ville (France); G. Lingman (Sweden)*

Prenatal follow-up of fetal lung development after fetal tracheal occlusion

OP27.01 and OP27.02

*R. Ruano (Brazil)*

Fetal interventions for congenital cystic adenomatoid malformation: a single center experience

OP27.03

*S. Hayashi (Japan)*

Impact of a successful pleuro-amniotic shunt on cardiac function in fetuses with pleural effusion

OP27.04

*H. Won (South Korea)*

Hypoplastic left ventricle (HLHS): in utero evolution and treatment

OP27.05

*P. Marantz (Argentina)*

Megacystis: diagnosis, therapy and outcome

OP27.06

*A. Muller Brochut (Switzerland)*

Intrauterine transfusion of mesenchymal stem cells in two fetuses with fractures: follow-up to 3 and 4 years of age

OP27.07

*M. Yamamoto (Chile)*

Thrombocytopenia in neonates treated by repeated intrauterine transfusions

OP27.08

*R. Bartkowiak (Poland)*

Parvovirus B19 in pregnancy: possible consequence of vertical transmission

OP27.09

*C. Puccetti (Italy)*

Spontaneous resolution of constrictive amniotic band in lower limb may question the indication of in-utero intervention

OP27.10

*M. Yamamoto (Chile)*

## OP28: Fetal anomalies II: second and third trimester

**North hall**

Chairs: *T. Shipp (United States); B. Tutschek (Switzerland)*

Abnormal mineralization of the fetal skull: sonographic diagnosis and clinical implications

OP28.01

*S. Gabrielli (Italy)*

Antenatal diagnosis of skeletal anomalies: a review of 246 subsequent cases

OP28.02

*J. Weichert (Germany)*

Diagnosis of fetal skeletal anomalies: role of 3D US compared with 3D CT

OP28.03

*J. Bault (France)*

Role of fetal computed tomography with three-dimensional reconstruction and 3D ultrasound in a variant of the Caudal regression syndrome

OP28.04

*P. Nowak (Brazil)*

Series of sirenomelia cases in the short period of time

OP28.05

*M. Socha (Poland)*

Prenatal diagnosis of nonimmune hydrops fetalis: what do we tell the parents?

OP28.06

*S. Santo (United Kingdom)*

Lethal anomalies in fetuses – the role of perinatal palliative care

OP28.07

*J. Dangel (Poland)*

# Short oral presentations – Wednesday 13 October 2010

	Abstract number
Clinical significance of sub chorionic hematoma: comparison between diagnosis in the first and second trimester <i>R. HersHKovitz (Israel)</i>	OP28.08
Agreement between prenatal ultrasound and autopsy findings: a study of second trimester terminations of pregnancy due to fetal malformations <i>P. Sladkevicius (Sweden)</i>	OP28.09
Fetal body lymphatic malformation: ultrasound underestimates the extent of infiltration <i>R. Sohaey (United States)</i>	OP28.10
<b>OP29: IUGR II</b>	<b>Club A</b>
<i>Chairs: A. Papageorghiou (United Kingdom); F. Figueras (Spain)</i>	
Implementation of the cumulative sum technique for fetal ultrasound biometry quality control <i>J. Kurmanavicius (Switzerland)</i>	OP29.01
Placental weight, cord insertion, shape and cord coiling in pregnancies with birth weight less than the 10th percentile <i>S. Pathak (United Kingdom)</i>	OP29.02
The evaluation of placental volume and placental bed blood flow dynamic by real-time 3D ultrasonography <i>W. Gou (China)</i>	OP29.03
3-Dimensional power Doppler angiography of placenta in normal and growth restricted fetuses <i>A. Rossi (Italy)</i>	OP29.04
Renal blood perfusion measured by fractional moving blood volume and spectral Doppler pulsatility index in fetuses with intrauterine growth restriction <i>R. Cruz-Martinez (Spain)</i>	OP29.05
Umbilical artery PI and fetal abdominal circumference in gastroschisis <i>C. Lees (United Kingdom)</i>	OP29.06
Maternal cardiac systolic and diastolic function in preterm fetal growth restriction <i>K. Melchiorre (United Kingdom)</i>	OP29.07
Effect of different charts for PEG diagnosis of neonatal morbidity <i>A. Insunza (Chile)</i>	OP29.08
Managing restricted babies – tough job <i>S. Tudorache (Romania)</i>	OP29.09
Neurodevelopmental outcome in term SGA and FGR pregnancies <i>T. Arcangeli (United Kingdom)</i>	OP29.10
<b>OP30: Placenta pathologies and uterine scar</b>	<b>Club E</b>
<i>Chairs: S. Campbell (United Kingdom); S. Lipitz (Israel)</i>	
Embryo and umbilical cord located in the lower part of the gestational sac at the first trimester associate with development of the placenta previa <i>T. Mimura (Japan)</i>	OP30.01
3D/4D sonographic imaging and pregnancy outcome in amniotic band syndrome <i>C. Berceanu (Romania)</i>	OP30.02
Screening for placenta accreta by ultrasound in the first trimester <i>J. Stimemann (France)</i>	OP30.03
Sonographic assessment of the extent of placenta accreta <i>H. Wong (Australia)</i>	OP30.04
Clinical and sonographic parameters at mid-trimester to predict the risk of primary Cesarean delivery in nulliparas <i>E. Jeong (South Korea)</i>	OP30.05
How to scan the uterus early after Cesarean section <i>E. Dosedla (Slovakia)</i>	OP30.06
Three-dimensional ultrasound of the uterus and the uterine cavity after normal vaginal delivery <i>J. Belachew (Sweden)</i>	OP30.07
Sonographic detection of uterine scar location following Cesarean section among pregnant women <i>O. Markovitch (Israel)</i>	OP30.08
Long term follow-up from a randomized trial comparing one- and two-layer closure technique in Caesarean section <i>K. Wøjedmann (Denmark)</i>	OP30.09
Association between the appearance of hysterotomy scars at ultrasound examination of non-pregnant women and the outcome of subsequent pregnancies <i>O. Vikhareva Osser (Sweden)</i>	OP30.10

# Posters – Wednesday 13 October 2010

Poster question and answer sessions: 10:40–10:55

Viewing available all week on E-poster viewing stations located in the level 2 foyer

## P21: Managing ovarian masses

CA-125 versus power Doppler as second step technique for predicting ovarian cancer in a large cohort of women with adnexal masses

S. Guerriero (Italy)

Ultrasound findings in postmenopausal women with adnexal masses

J. Dotlic (Serbia)

Advantage of three-dimensional ultrasound in the differential diagnosis of benign and malignant breast tumors

J. Quan (China)

Sonographic predictors of ovarian malignancy

B. Benacerraf (United States)

Resistance index is the strongest ultrasonic variable in predicting malignancy of ovarian masses

A. Babinszki (Hungary)

Transvaginal sonographic markers of tuboovarian abscess

J. Chung (South Korea)

## P22: Fetal heart IV

Efficacy and length of routine transabdominal fetal heart scanning at the time of NT measurement

D. Nemescu (Romania)

Recognition of fetal cardiac abnormalities by sonographers: still frames vs. fast cine vs. slow cine

N. Trivedi (United States)

Implementation of extended 2nd trimester cardiac screening at a Danish university hospital

O. Petersen (Denmark)

Premature constriction of the ductus arteriosus in both fetuses of dizygotic twin pregnancy following maternal non-steroidal anti-inflammatory drugs application

A. Hamela-Olkowska (Poland)

Idiopathic constriction of fetal ductus arteriosus: three cases and review of the literature

C. Enzensberger (Germany)

Correlation of ejection fraction by planimetry and Doppler of middle cerebral artery with fetal supraventricular tachycardia treated by sotalol in third trimester

J. Otero (Colombia)

Dual Doppler technique for the measurement of P-R interval in fetuses at risk for congenital heart-block

G. Nazzaro (Italy)

Diagnosis of congenital heart block: what kind of markers?

R. Natale (Italy)

Evaluation of normal fetal atrio-ventricular septal dimensions from 11–34 weeks gestation

M. Ben-Ami (Israel)

Diameter of supracardiac veins with gestation

K. Kim (South Korea)

## P23: Incomplete splitting in multiple pregnancy

Prenatal care of conjoined twin: series of cases

P. Nowak (Brazil)

Conjoined twins was diagnosed by transvaginal ultrasonography at 9 weeks gestation: a case report

A. Kun (Hungary)

Prenatal diagnosis of monocephalic bifacial tetraophthalmic diprosopus (conjoined twin)

I. Dhaifalah (Czech Republic)

The study of the acardiac twins sequence with the placenta vascular casts

C. Xinlin (China)

First trimester diagnosis of ischiopagus conjoined twins in a triplet pregnancy

Y. Song (South Korea)

Triplet acardiac at twenty weeks

K. Kostyukov (Russian Federation)

The antenatal sonographic diagnosis of two cases of twins reversed arterial perfusion sequence with heart vestige

X. Chen (China)

Unusual case of parasitic sacral conjoined twin

M. Okumura (Brazil)

Epigastric heteropagus: a case report

S. Buyukkurt (Turkey)

Second trimester diagnosis of dicephalic thoracoomphalopagus conjoined twins via transabdominal 3D sonography

N. Kim (South Korea)

Abstract number

**Forum hall**

P21.01

P21.02

P21.03

P21.04

P21.05

P21.06

**Panorama hall**

P22.01

P22.02

P22.03

P22.04

P22.05

P22.06

P22.07

P22.08

P22.09

P22.10

**North hall**

P23.01

P23.02

P23.03

P23.04

P23.05

P23.06

P23.07

P23.08

P23.09

P23.10



# Posters – Wednesday 13 October 2010

	Abstract number
Prenatal detection of conjoined twins (thoracopagus) in the 1st trimester: report of the case <i>C. Gagaev (Russian Federation)</i>	P23.11
Fetal skeletal malformations among pump twins in monochorionic gestations complicated by TRAP sequence <i>K. Fuchs (United States)</i>	P23.12
Laser coagulation in triplet pregnancy with acardiac fetus: a case report <i>C. Flores Acosta (Mexico)</i>	P23.13
<b>P24: Maternal fetal Doppler</b>	<b>Club A</b>
Learning curve for Doppler calculation of fetal modified myocardial performance index <i>R. Cruz-Martinez (Spain)</i>	P24.01
Reproducibility of fetal renal blood perfusion as measured by fractional moving blood volume using power Doppler ultrasound <i>M. Cruz Lemini (Spain)</i>	P24.02
Fetal anemia with normal Doppler velocimetry in the middle cerebral artery <i>J. Unterscheider (Ireland)</i>	P24.03
Relationship of fetal hemoglobin concentration to umbilical vein blood flow <i>S. Lacziko (Romania)</i>	P24.04
Improvement in prenatal evaluation of malformed fetus by use of color Doppler <i>N. Vecek (Croatia)</i>	P24.05
Correlation between OGTT and Doppler velocimetry in pregnancy complicated with gestational diabetes <i>S. Lacziko (Romania)</i>	P24.06
Doppler findings in intrapartum fetal distress <i>L. Eslamian (Islamic Republic of Iran)</i>	P24.07
Correlation of fetal Doppler flow and perinatal outcomes in patient with pre-eclampsia <i>A. Chanthasenanont (Thailand)</i>	P24.08
Prognostic value of the combinations of Doppler examination and biophysical tests in evaluation of the risk of adverse neonatal outcome <i>D. Nowakowska (Poland)</i>	P24.09
Cerebroplacental Doppler Index in severe preeclampsia <i>C. Flores Acosta (Mexico)</i>	P24.10
Computerized cardiocography and Doppler velocimetry in fetuses exposed to antiepileptic drugs <i>R. Nomura (Brazil)</i>	P24.11
In vitro Doppler measurements of flow (ml/min) depends on angle and diameter <i>M. Yamamoto (Chile)</i>	P24.12
Color Doppler ultrasound of spiral artery blood flow assessment in women with antiphospholipid syndrome <i>S. Wozniak (Poland)</i>	P24.13
Influence of persistence on assessment of placental time-averaged maximum perfusion in healthy fetuses <i>J. Benavides (Mexico)</i>	P24.14
Early ultrasound diagnosis of vasa praevia and succenturiate placenta <i>L. Ples (Romania)</i>	P24.15
Contribution of three dimensional Doppler imaging before embolization of placental chorioangiomas <i>G. Haddad (France)</i>	P24.16
Clinical significance of color Doppler sonography of Aa. uterinae during pregnancy <i>S. Lulaj (Albania)</i>	P24.17
Centralization and U turn of uterine arteries demonstrated by three dimensional power Doppler flow are new imaging signs for diagnosis of complete uterine inversion <i>E. Zohav (Israel)</i>	P24.18
Uterine artery pseudoaneurysm, ultrasound diagnosis and treatment <i>W. Clavelli (Argentina)</i>	P24.19
<b>P25: CNS III: 3D ultrasound in fetal brain anomalies</b>	<b>Club E</b>
Obstetric characteristics and pregnancy outcome of fetuses affected with either isolated central nervous system malformations or isolated chromosomal abnormalities at term <i>D. Bashiri (Israel)</i>	P25.01
Expectant management of pregnancies complicated by anencephaly <i>J. Unterscheider (Ireland)</i>	P25.02
Perinatal management of meningomyelocele and encephalocele in a tertiary referral centre <i>J. Unterscheider (Ireland)</i>	P25.03
Prenatal detection and management of 15 fetuses with encephalocele in a tertiary referral center <i>D. Hartge (Germany)</i>	P25.04
Comparison between three-dimensional sonographic method VOCAL and fetal MRI in fetal lateral ventricle volume measurements <i>L. Nardoza (Brazil)</i>	P25.05
3D standardized volume acquisition for the diagnosis of neural tube defects <i>P. Bouhanna (France)</i>	P25.06

# Posters – Wednesday 13 October 2010

	Abstract number
Corpus calosum abnormalities: 2D versus 3D multiplanar versus 3D-VCI <i>C. Ionescu (Romania)</i>	P25.07
3D analysis and volume navigation through the normal fetal diencephalon and its related anatomic structures <i>F. Viñals (Chile)</i>	P25.08
Reproducibility of three-dimensional power Doppler for the assessment of the fetal brain blood flow in the anterior cerebral artery territory <i>G. Lobo (Brazil)</i>	P25.09
Use of three-dimensional (3D) sonography to assess the true midsagittal plane of fetal spine <i>T. Lau (China)</i>	P25.10
Digitally enhanced three-dimensional ultrasound in suspected fetal central nervous system anomalies <i>J. Bello-Muñoz (Spain)</i>	P25.11
Inter-observer reproducibility of the offline measurement of fetal head biometry using 3D volume datasets <i>H. Mousa (United Kingdom)</i>	P25.12
Case report of spinal dysraphism with lemon and banana signs in the second trimester and normal intracranial translucency in the first trimester <i>M. Hynek (Czech Republic)</i>	P25.13
Three-dimensional transvaginal ultrasound diagnosis of open spina bifida at 13+2 weeks of gestation with an absent intracranial translucency <i>E. Pavlova (Bulgaria)</i>	P25.14
Intracranial translucency (IT) at 11+0 to 13+6 weeks in Chinese population <i>T. Lau (China)</i>	P25.15
Intracranial translucency (IT) reference range for Chilean population at the 11–13+6 weeks scan <i>G. Rencoret (Chile)</i>	P25.16
Intracranial translucency and open spina bifida <i>F. Bretelle (France)</i>	P25.17
Interest of choroid plexus at first trimester in diagnosis of spina bifida <i>J. Develay-Morice (France)</i>	P25.18

## Poster question and answer sessions: 15:40–16:00

Viewing available all week on E-poster viewing stations located in the level 2 foyer

### P26: Pelvic floor

	Abstract number
Three-dimensional transperineal ultrasound imaging of the anal sphincter in nulliparous women <i>A. Steensma (Netherlands)</i>	<b>Forum hall</b> P26.01
Correlation of ultrasound evidence of levator ani trauma with clinical functional testing of pelvic floor muscles <i>D. Valsky (Israel)</i>	P26.02
Ultrasonographic imaging of the lower urinary tract. The effect of the transoburator tension free vaginal tape <i>M. Eleftheriades (Greece)</i>	P26.03
Three-dimensional transperineal ultrasound imaging of anal sphincter injuries after surgical primary repair <i>A. Steensma (Netherlands)</i>	P26.04
Two time points ultrasound assessment of mesh retraction after vaginal implantation <i>K. Svabik (Czech Republic)</i>	P26.05
Changes in genital hiatus after sacrocolpopexy <i>M. Konstantinovic (Belgium)</i>	P26.06
Can the rectovaginal septum be visualised by transvaginal 3D ultrasound? <i>H. Dietz (Australia)</i>	P26.07
The urethral lumen on 3D transperineal ultrasound volumes - does it mean anything? <i>V. Eisenberg (Israel)</i>	P26.08
The role of transvaginal echography of urethrovesical segment in surgical correction of stress incontinence <i>P. Victoria (Russian Federation)</i>	P26.09
The role of 2D and 3D transvaginal sonography on the diagnosis of enterovaginal fistula <i>D. Prete (Brazil)</i>	P26.10
Ultrasound evaluation of endometrial cavity with high frequency linear transducers in patients with non-reducible genital prolapse: a case report <i>K. Rezende (Brazil)</i>	P26.11

### P27: In utero interventions

	Abstract number
The evaluation of seven fetal cases with head-neck tumor and thus need for the EXIT procedure <i>S. Buyukkurt (Turkey)</i>	<b>Panorama hall</b> P27.01
Antenatal treatment of fetal goitrous hypothyroidism <i>C. Stewart (South Africa)</i>	P27.02
Prognostic factors in congenital diaphragmatic defects: US and MRI <i>E. Antolin (Spain)</i>	P27.03
Resolution of hidrops in congenital cystic adenomatoid malformation of the lung after percutaneous sclerotherapy <i>C. Flores Acosta (Mexico)</i>	P27.04

# Posters – Wednesday 13 October 2010

	Abstract number
Intrauterine aspiration of a large intrathoracic cystic mass in a fetus presenting with ascites <i>C. Batukan (Turkey)</i>	P27.05
Successful intrauterine medical treatment of nonimmune hydrops fetalis caused by fetal tachyarrhythmia <i>M. Vizer (Hungary)</i>	P27.06
Intrauterine intrafunicular treatment of nonimmune hydrops fetalis caused by fetal cardiomyopathy <i>M. Vizer (Hungary)</i>	P27.07
Non-immune fetal ascites with lower urinary tract obstruction and placenta praevia: case report <i>I. Kucerova (Czech Republic)</i>	P27.08
Prenatal diagnosis of type II sacrococcygeal teratoma and its management in utero using percutaneous radiofrequency ablation: case report <i>J. Kim (South Korea)</i>	P27.09
Successful fetal therapy for massive fetal sacrococcygeal teratoma using radio frequency ablation <i>G. Ryan (Canada)</i>	P27.10
Amnioinfusion during second trimester <i>C. Celentano (Italy)</i>	P27.11
Identifying fetuses at risk of pulmonary hypoplasia with three dimensional ultrasonography and role of amnioinfusion in the management <i>G. Nazzaro (Italy)</i>	P27.12
Transabdominal amnioinfusion does not improve perinatal outcome in uncomplicated term pregnancies with oligohydramnios <i>H. Ahn (South Korea)</i>	P27.13
Arterial embolization in arterial venous shunt: about our experience in the management of placental chorioangiomas with fetal hydrops <i>G. Haddad (France)</i>	P27.14
Inadvertent intra-arterial administration during intraumbilical transfusion as a cause of severe bradycardia and fetal hypoxia <i>Z. Zizka (Czech Republic)</i>	P27.15

## P28: Fetal anomalies II: second and third trimester

	<b>North hall</b>
Prenatal diagnosis of fibular hemimelia <i>Y. Fan (Portugal)</i>	P28.01
A case report of antenatal ultrasonographic detection of fibular hemimelia <i>E. Pschirrer (United States)</i>	P28.02
A case of congenital lymphangiomas of the right lower limb <i>J. Shin (South Korea)</i>	P28.03
Prenatal screen the abnormal flexed direction of knee joints using the parallel moving examination <i>M. Qian (China)</i>	P28.04
Prenatal sonographic features in fetuses with severe long bone shortening during the third trimester <i>F. Strigini (Italy)</i>	P28.05
Prenatal ultrasound diagnosis of Schinzel phocomelia syndrome <i>M. Momtaz (Egypt)</i>	P28.06
Short and bent femur in skeletal dysplasias: insights inferred from a fetus with femoral hypoplasia-unusual facies syndrome <i>C. Chen (Taiwan)</i>	P28.07
Limb reduction defect in-utero: a case report and literature review <i>D. Janga (United Kingdom)</i>	P28.08
Atelosteogenesis, type 2 <i>I. Magdi (Egypt)</i>	P28.09
The application of 3D and 3D multislice ultrasound in analysis of fetal body stalk anomaly <i>A. Jurisic (Serbia)</i>	P28.10
Fetal sacrococcygeal teratoma: prognostic factors and outcome <i>D. Nowakowska (Poland)</i>	P28.11
Intrauterine spontaneous rupture of a sacrococcygeal teratoma diagnosed by amniocentesis <i>G. Lobo (Brazil)</i>	P28.12
Specialist scanning in secondary care <i>R. Thompson (United Kingdom)</i>	P28.13
Correlation between ultrasound diagnosis and autopsy findings of fetal malformations in second trimester terminations of pregnancy <i>A. Vimercati (Italy)</i>	P28.14
Parents reaction at diagnosis of fetal anomalies <i>A. Kesrouani (Lebanon)</i>	P28.15
Attitudes of women to termination of pregnancy for fetal abnormality <i>C. Stewart (South Africa)</i>	P28.16
Ultrasound imaging in the diagnosis and management of placenta chorioangiomas <i>H. Di (China)</i>	P28.17
Gestational age determination at the 18–22 weeks scan <i>C. Martínez-Payo (Spain)</i>	P28.18

# Posters – Wednesday 13 October 2010

Abstract number

## P29: There is no P29 session scheduled

### P30: Placenta pathologies and uterine scar

	<b>Club E</b>
Abnormal placentation - prospects of ultrasound diagnosis <i>O. Eremina (Russian Federation)</i>	P30.01
Placenta-specific microRNAs in maternal circulation in normal pregnancies and those with placental insufficiency related complications <i>I. Hromadnikova (Czech Republic)</i>	P30.02
Ultrasonographic findings of placenta lacunae and lack of clear zone were frequently observed in placenta previa compared with normal placenta <i>S. Takahashi (Japan)</i>	P30.03
The role of ultrasonography and color Doppler imaging in antenatal diagnosis of placenta accreta in high-risk patients <i>O. Hoxhaj (Albania)</i>	P30.04
Diagnosis of placenta accreta in early pregnancy: case report and review of literature <i>F. Moretti (Canada)</i>	P30.05
Complex placental image: evolution and diagnosis <i>A. Kesrouani (Lebanon)</i>	P30.06
Placenta accreta diagnosed 6 months after early abortion with curettage <i>G. Lobo (Brazil)</i>	P30.07
Conservative management of morbidly adherent placenta and subsequent successful pregnancy outcome: a case report <i>J. Unterscheider (Ireland)</i>	P30.08
Bladder varices: source of confusion for placenta accreta spectrum <i>A. Kennedy (United States)</i>	P30.09
Translabial ultrasound: an alternative ultrasonographic approach in the assessment of placenta previa and cervix incompetence <i>E. Domali (Greece)</i>	P30.10
Correlation between the amount of hemorrhage during a vaginal delivery and the length from the placental edge to the external os in cases with low-lying placenta <i>M. Nakamura (Japan)</i>	P30.11
First trimester 3D diagnosis of parapagus diprosopus dibrachius dipus twins with craniorachischisis totalis <i>K. Ulker (Turkey)</i>	P30.12
A large amniocoele with protruded umbilical cord diagnosed by 3D ultrasound <i>S. Kim (South Korea)</i>	P30.13
Prenatal diagnosis of right lower extremity congenital fibrosarcoma <i>O. Pata (Turkey)</i>	P30.14
Prenatal diagnosis of cervical teratoma and antenatal assessment of airway obstruction <i>C. Flores Acosta (Mexico)</i>	P30.15
Hipercoiling of the umbilical cord associated with the fetal death <i>C. Murta (Brazil)</i>	P30.16
A case of mesenchymal diaplasi <i>K. Miura (Japan)</i>	P30.17
Prenatal diagnosis of left posterolateral congenital diaphragmatic hernia with ileal loops – antepartum management and postpartum therapy <i>R. Radulescu-Botica (Romania)</i>	P30.18
Prenatal diagnosis of isolated acephaly: a case report <i>G. Sepulveda Gonzalez (Mexico)</i>	P30.19
2D and 3D ultrasound for antenatal diagnosis of congenital ichthyosis <i>A. Kesrouani (Lebanon)</i>	P30.20
Acute hepatitis A on the first trimester fetal development: are we facing a new ultrasound sign of this disease on the fetus? <i>R. Cassis-Martinez (Ecuador)</i>	P30.21
Spontaneously resolving primary fetal hydrothorax <i>N. Burke (Ireland)</i>	P30.22

# Program – Thursday 14 October 2010

07:45–08:30 'All you ever wanted to know' afternoon sessions must be pre-booked at the registration desk. See page 11 for details

<b>08:30–09:10</b>	<b>Short oral presentation (oral poster) sessions</b>	
<b>09:10–09:25</b>	<b>Electronic posters: author questions</b>	
08:30	<b>OP31: Imaging in the oncology patient</b>	Forum hall
09:10	<b>P31: Imaging in the oncology patient</b> <i>Chairs: E. Epstein (Sweden); M. Zikan (Czech Republic)</i>	
08:30	<b>OP32: Induction of labour: ultrasound during labour and postpartum</b>	Club A
09:10	<b>P32: Induction and ultrasound in labour</b> <i>Chairs: K. Salvesen (Norway); M. Wielgos (Poland)</i>	
08:30	<b>OP33: Fetal anomalies III: fetal abdomen</b>	Club B
09:10	<b>P33: Fetal anomalies III: fetal abdomen</b> <i>Chairs: S. Eik-Nes (Norway); M. Momtaz (Egypt)</i>	
08:30	<b>OP34: First trimester IV: growth and predicting pregnancy outcome</b>	Club E
09:10	<b>P35: First trimester IV: fetal abnormalities</b> <i>Chairs: H. Blaas (Norway); R. Axt-Fliedner (Germany)</i>	
<b>09:30–10:30</b>	<b>Second trimester scan</b>	<b>Congress hall</b>
	<i>Chairs: D. Nyberg (United States); R. Vlk (Czech Republic)</i>	
09:30	Overview <i>D. Nyberg (United States)</i>	
09:35	Live scan demonstration: 3D fetal face (supported by Medison*) <i>K. Kalache (Germany)</i>	
09:50	Identification of fetal abnormalities in the third trimester after a second trimester detailed structural fetal survey <i>T. Shipp; B. Bromley; B. Benacerraf (United States)</i>	OC24.01
09:55	Discussion	
09:58	The impact of three-dimensional ultrasound and fetal magnetic resonance on diagnosis of facial clefts <i>V. Frisova; J. Borsky; M. Kyncl; B. Prosova; L. Mrazkova; M. Rocek (Czech Republic)</i>	OC24.02
10:03	Discussion	
10:06	Maxillary protrusion in fetuses with facial clefts, measured with the MNM angle <i>E. de Jong-Pleij; L. Pistorius; L. Ribbert; E. Tromp; C. Bilardo (Netherlands)</i>	OC24.03
10:11	Discussion	
10:14	3-Dimensional ultrasound demonstration of fetal anal canal and sphincter <i>L. Gindes; A. Weissmann-Brenner; B. Weisz; K. Tzadikvitch Geffen; M. Zajicek; R. Achiron (Israel)</i>	OC24.04
10:19	Discussion	
10:22	Increased concentration of tubular parameters in the amniotic fluid of male fetuses in the 2nd trimester of pregnancy <i>R. Schild<sup>1</sup>; B. Meurer<sup>2</sup>; N. Hart<sup>1</sup>; A. Tzschoppe<sup>1</sup>; J. Dötsch<sup>1</sup></i> <sup>1</sup> (Germany); <sup>2</sup> (Switzerland)	OC24.05
10:27	Discussion	
<b>09:30–10:30</b>	<b>The post-menopausal endometrium and cervical pathology</b>	<b>Forum hall</b>
	<i>Chairs: G. Condous (Australia); F. Leone (Italy)</i>	
09:30	The management of postmenopausal bleeding and influence of HRT, tamoxifen and SERMS <i>E. Epstein (Sweden)</i>	
09:50	Mathematical models for predicting endometrial malignancy in women with postmenopausal bleeding and sonographic endometrial thickness >4.5mm <i>G. Opolskiene; P. Sladkevicius; L. Valentin (Sweden)</i>	OC25.01
09:55	Discussion	
09:58	Estimating probability of cancer in patients with postmenopausal bleeding prior to ultrasonography. Validation and refinement of a prognostic model <i>M. Breijer<sup>1</sup>; A. Timmermans<sup>1</sup>; H. Van Doorn<sup>1</sup>; L. Valentin<sup>2</sup>; T. Van den Bosch<sup>3</sup>; B. Mol<sup>1</sup>; B. Opmeer<sup>1</sup></i> <sup>1</sup> (Netherlands); <sup>2</sup> (Sweden); <sup>3</sup> (Belgium)	OC25.02
10:03	Discussion	
10:06	Assessment of myometrial invasion in endometrial cancer by transvaginal sonography and frozen section <i>L. Savelli; A. Testa; M. Mabrouk; L. Zannoni; F. Mascioli; M. Ludovisi; R. Seracchioli; G. Zannoni; V. Vellone; S. Venturoli (Italy)</i>	OC25.03
10:11	Discussion	
10:14	<sup>^</sup> Three dimensional ultrasound to assess the chemotherapy response of locally advanced cervical cancer <i>G. Perniola; C. Exacoustos; M. Graziano; C. Achilli; F. Bellati; I. Palaia; D. Arduini; P. Benedetti Panici (Italy)</i>	OC25.04
10:19	Discussion	

\* Scientific content of live scan sessions is defined by ISUOG. Ultrasound systems and technical support are provided by sponsors.

<sup>^</sup> This abstract has been shortlisted as a finalist for the Alfred Kratochwil 3D abstract award. The winner will be announced at the closing ceremony.

# Program – Thursday 14 October 2010

10:22	Summary <i>G. Condous (Australia)</i>	
10:30–11:00	Coffee and electronic poster viewing	Exhibition area
11:00–11:40	Short oral presentation (oral poster) sessions	
11:00	<b>OP35: Scanning asymptomatic women</b> <i>Chairs: S. Campbell (United Kingdom); C. Exacoustos (Italy)</i>	Forum hall
11:00	<b>OP36: Fetal heart V: cardiac and vascular anomalies</b> <i>Chairs: A. Baschat (United States); F. Crispi (Spain)</i>	Club A
11:00	<b>OP37: Maternal fetal Doppler II</b> <i>Chairs: S. Gudmundsson (Sweden); E. Hernandez-Andrade (Mexico)</i>	Club B
11:00	<b>OP38: Fetal size</b> <i>Chairs: W. Lee (United States); A. Ngu (Australia)</i>	Club D
11:00	<b>OP39: IUGR III: fetal programming in placental dysfunction</b> <i>Chairs: C. Brezinka (Austria); K. Maršál (Sweden)</i>	Club E
11:40–13:10	Cardiac function in specific conditions	Congress hall
	<i>Chairs: C. Lombardi (Italy); J. Wladimiroff (United Kingdom)</i>	
11:40	Overview <i>J. Wladimiroff (United Kingdom)</i>	
11:50	<sup>^</sup> # Fetal cardiac output: measurement by four dimensional power Doppler and artificial neural networks. Results from a sheep model <i>J. Bello-Muñoz; J. Peiró; P. Oliveros Orozco; F. Soldado; E. Carreras Moratonas; L. Cabero (Spain)</i>	OC26.01
11:55	Discussion	
11:58	Maternal hyperglycemia affects first trimester fetal cardiac function in normal hearts <i>S. Turan; O. Turan; A. Desai; J. Miller; C. Harman; A. Baschat (United States)</i>	OC26.02
12:03	Discussion	
12:06	# Bioinformatic analysis of genes regulating myocardiocyte contractile function in a rabbit model of cardiac dysfunction due to intrauterine growth restriction <i>E. Eixarch; I. Torre; M. Illa; I. Iruretagoyena; I. Amat-Roldan; F. Crispi; F. Figueras; F. Garcia; J. Dopazo; E. Gratacós (Spain)</i>	OC26.03
12:11	Discussion	
12:14	Cardiac function between 11 and 35 weeks' gestation and nuchal translucency thickness in trisomy 21 fetuses <i>S. Clur; J. Ottenkamp; C. Bilardo (Netherlands)</i>	OC26.04
12:19	Discussion	
12:22	Assessment of longitudinal myocardial function of the right ventricle in fetuses with congestive heart failure using tissue Doppler imaging <i>E. Sinkovskaya; S. Horton; E. Berkley; A. Abuhamad (United States)</i>	OC26.05
12:27	Discussion	
12:30	Fetal circulatory dynamics in presence of simple TGA <i>J. Blanc<sup>1</sup>; J. Fouron<sup>1</sup>; M. Raboisson<sup>1</sup>; I. Huggon<sup>4</sup>; S. Sonesson<sup>2</sup>; F. Proulx<sup>3</sup>; A. Bozio<sup>3</sup>; Y. Villes<sup>3</sup>; R. Gendron<sup>1</sup></i> <sup>1</sup> (Canada); <sup>2</sup> (Sweden); <sup>3</sup> (France); <sup>4</sup> (United Kingdom)	OC26.06
12:35	Discussion	
12:38	Doppler evaluation in fetuses with right ventricular prevalence: a contribution to the diagnosis of coarctation of aorta <i>M. Bellotti; V. Bee; S. Migliaccio; E. Matarazzo; C. De Gasperi; G. Rognoni (Italy)</i>	OC26.07
12:43	Discussion	
12:46	Live scan demonstration: first trimester fetal assessment and cardiac function (supported by Siemens*) <i>U. Gembruch (Germany)</i>	
11:40–13:10	Imaging in the oncology patient: staging, recurrence and interventions	Forum hall
	<i>Chairs: A. Testa (Italy); D. Fischerova (Czech Republic)</i>	
11:40	Imaging and tailored therapy in gynaecological oncology <i>D. Cibula (Czech Republic)</i>	
11:55	Patient selection and technique of ultrasound guided interventions in oncology patients <i>M. Zikan (Czech Republic)</i>	
12:10	Ultrasound features of metastases in the ovary depending on the origin of the primary tumor <i>S. Guerriero<sup>1</sup>; J. Alcazar<sup>2</sup>; M. Ariu<sup>1</sup>; C. Laparte<sup>2</sup>; S. Ajossa<sup>1</sup>; M. Angiolucci<sup>1</sup>; M. Pilloni<sup>1</sup>; M. Garcia-Manero<sup>2</sup>; J. Miguez<sup>2</sup>; G. Melis<sup>1</sup></i> <sup>1</sup> (Italy); <sup>2</sup> (Spain)	OC27.01
12:15	Discussion	

\* Scientific content of live scan sessions is defined by ISUOG. Ultrasound systems and technical support are provided by sponsors.

# This presentation is eligible for the Young Investigator award (to be presented at the closing ceremony).

<sup>^</sup> This abstract has been shortlisted as a finalist for the Alfred Kratochwil 3D abstract award. The winner will be announced at the closing ceremony.

# Program – Thursday 14 October 2010

12:18	Sonographic characteristics of squamous cell cancer and adenocarcinoma of the uterine cervix <i>E. Epstein<sup>1</sup>; A. Di Legge<sup>2</sup>; A. Måsbäck<sup>1</sup>; P. Lindqvist<sup>1</sup>; P. Kannisto<sup>1</sup>; A. Testa<sup>2</sup></i> <sup>1</sup> (Sweden); <sup>2</sup> (Italy)	OC27.02
12:23	Discussion	
12:26	Conservative management and ultrasonographic longitudinal follow-up of borderline ovarian tumors recurrences after fertility sparing surgery <i>D. Franchi; A. Testa; S. Boveri; N. Colombo; D. Radice; M. Sideri (Italy)</i>	OC27.03
12:31	Discussion	
12:34	Ultrasound evaluation in preoperative assessment of extension of disease and prediction of optimal cytoreduction in ovarian cancer: a prospective trial <i>A. Testa; M. Ludovisi; M. Malaggesi; A. Di Legge; F. Mascilini; M. Durante; I. Vercillo; B. Virgilio; G. Scambia; G. Ferrandina (Italy)</i>	OC27.04
12:39	Discussion	
12:42	Uterine sarcomas: clinical and sonographic characteristics <i>S. Giunchi; A. Testa; T. Ghi; L. Savelli; M. Pesaresi; F. Mascilini; M. Giordano; G. Pelusi (Italy)</i>	OC27.05
12:47	Discussion	
12:50	Ultrasound features of rare primary malignant ovarian tumors <i>S. Guerriero<sup>1</sup>; J. Alcazar<sup>2</sup>; M. Ariu<sup>1</sup>; A. Ruiz-Zambrana<sup>2</sup>; S. Ajossa<sup>1</sup>; M. Angiolucci<sup>1</sup>; S. Piras<sup>1</sup>; M. Garcia-Manero<sup>2</sup>; J. Miguez<sup>2</sup>; G. Melis<sup>2</sup></i> <sup>1</sup> (Italy); <sup>2</sup> (Spain)	OC27.06
12:55	Discussion	
12:58	New horizons about the diagnosis of breast masses by SonoLiverR CAP imaging analysis software <i>J. Quan (China)</i>	OC27.07
13:03	Discussion	
13:06	Summary <i>A. Testa (Italy)</i>	

## 13:10–13:30 Closing and plenary

Congress hall

13:10	Presentation of Young Investigator award Presentation of Alfred Kratochwil award Best presentation awards
13:25	Welcome to LA!

## 13:30– 14:00 Farewell drinks and light lunch

Level 1 foyer



# Short oral presentations – Thursday 14 October 2010

**Chaired short oral presentation (oral poster) sessions: 08:30–09:10**

**Viewing available all week on E-poster viewing stations located in the level 2 foyer**

Abstract number

## **OP31: Imaging in the oncology patient**

**Forum hall**

*Chairs: E. Epstein (Sweden); M. Zikan (Czech Republic)*

Duration of time for volume calculation using different slices of the XI VOCALTM three-dimensional ultrasound volumetric method in an in vitro setting OP31.01

*M. Vizer (Hungary)*

Follow up in patients treated with conservative surgery for ovarian borderline tumors: role of transvaginal ultrasound OP31.02

*C. Exacoustos (Italy)*

The evaluation of concomitant chemo-radiotherapy response in advanced cervical carcinoma by using transvaginal ultrasonography OP31.03

*G. Ancuta (Romania)*

Ultrasound imaging compared to a multivariate predictive algorithm combining HE4 and CA 125 (ROMA®) in the pre-operative assessment of adnexal masses: preliminary results OP31.04

*D. Franchi (Italy)*

The accuracy and validity of the XI VOCALTM three-dimensional ultrasound volumetric measurement using an in vitro model OP31.05

*S. Bózsá (Hungary)*

Ultrasound characteristics of non-genital abdomino-pelvic tumors OP31.06

*M. Zikan (Czech Republic)*

Prognostic value of transvaginal ultrasound for the evaluation of volume of tumour in cervical carcinoma OP31.07

*G. Ancuta (Romania)*

Pelvic relapse in patients treated for epithelial ovarian cancer. The role of transvaginal sonography OP31.08

*G. Perniola (Italy)*

Fetal microchimerism in gynecologic malignancies OP31.09

*I. Hromadnikova (Czech Republic)*

## **OP32: Induction of labour: ultrasound during labour and postpartum**

**Club A**

*Chairs: K. Salvesen (Norway); M. Wielgos (Poland)*

Ultrasonographical measurement of obstetric conjugate length OP32.01

*T. Ozaki (Japan)*

The use of 3D ultrasound for the prediction of success of vaginal birth prior to instrumental delivery OP32.02

*U. Agarwal (United Kingdom)*

Transvaginal cervical length as predictor of the latency period in patients with premature rupture of membranes and expectant management OP32.03

*G. Sepulveda Gonzalez (Mexico)*

Preinduction transvaginal ultrasonographic cervical assessment in predicting of successful labour induction OP32.04

*S. Pitukijronnakorn (Thailand)*

Evaluation of Bishop score, length, volume and gray-scale histogram of the cervix as predictors of successful induction OP32.05

*J. Kim (South Korea)*

Comparing the prognostic values of the Bishop system with an ultrasound assessment of a cervix to predict labor induction OP32.06

*P. Sieroszewski (Poland)*

Comparison of ultrasound methods assessing fetal head descent during labour OP32.07

*E. Torkildsen (Norway)*

Agreement between 2D and 3D acquisitions assessing fetal head descent OP32.08

*E. Torkildsen (Norway)*

Sequential three-dimensional sonographic studies of postpartum uterine involution OP32.09

*T. Wataganara (Thailand)*

## **OP33: Fetal anomalies III: fetal abdomen**

**Club B**

*Chairs: S. Eik-Nes (Norway); M. Momtaz (Egypt)*

Effect of harmonic imaging, SRI-II, CRI, FFC and coded excitation B-mode features on fetal bowel echogenicity, studied by computerized image analysis OP33.01

*Z. Leibovitz (Israel)*

Fetal and neonatal outcome of isolated fetal hyperechogenic bowel OP33.02

*N. Deole (United Kingdom)*

Ultrasound evaluation of bowel complication in fetuses with gastroschisis OP33.03

*P. Nowak (Brazil)*

Fetal portosystemic venous shunt from diagnosis to counseling OP33.04

*R. Achiron (Israel)*

The prenatal diagnosis of isolated varix of the fetal intra-abdominal umbilical vein: iatrogenic prematurity is not obligatory OP33.05

*R. Rabinowitz (Israel)*

Ultrasonography as a prenatal screening method of fetal choledochal cyst OP33.06

*S. Lee (South Korea)*



# Short oral presentations – Thursday 14 October 2010

	Abstract number
Evaluation and outcome of prenatal non visualization of gallbladder <i>S. Yagel (Israel)</i>	OP33.07
Prenatal diagnosis of renal duplex systems. Ultrasonographic features and postnatal outcomes <i>M. Adiego (Spain)</i>	OP33.08
Echogenic kidneys in the fetus: correlation with postnatal outcome <i>J. Byrne (United States)</i>	OP33.09
<b>OP34: First trimester IV: growth and predicting pregnancy outcome</b>	<b>Club E</b>
<i>Chairs: H. Blaas (Norway); R. Axt-Fliedner (Germany)</i>	
Estimation of onset of pregnancy: crown– rump length, last menstrual period or both? <i>J. Stimmann (France)</i>	OP34.01
Upright crown– rump length – a novelty approach towards improving accuracy of dating the pregnancy in the late first trimester <i>M. Hynek (Czech Republic)</i>	OP34.02
Early dating of the pregnancy: 8–10.6 weeks better than 11–13.6? <i>E. Meler (Spain)</i>	OP34.03
First-trimester crown– rump length dating chart based on a large sample of exactly dated pregnancies after assisted reproductive technologies <i>M. Hynek (Czech Republic)</i>	OP34.04
<sup>A</sup> Comparison of inter- and intraobserver agreement and reproducibility between three different types of fetal and placenta volume measurement techniques (XI VOCAL™, VOCAL™ and multiplanar), and the validity in the in vitro setting <i>K. Leung (China)</i>	OP34.05
Use of placental, gestational sac and fetal volumetry by three-dimensional ultrasound in the first trimester for the prediction of fetal homozygous $\alpha^0$ -thalassemia <i>K. Leung (China)</i>	OP34.06
Placental volume and vascularization by 3-dimensional ultrasound and 3-dimensional power Doppler in the first trimester and the detection of pregnancy induced hypertension or intrauterine growth restriction <i>M. Odeh (Israel)</i>	OP34.07
First trimester uterine artery Doppler, placental volume and ductus venosus blood flow as predictors of second trimester fetal growth <i>Y. Derbala (Egypt)</i>	OP34.08
Association between first-trimester fetal growth restriction and small for gestational age deliveries <i>A. Odibo (United States)</i>	OP34.09
CRL at 11–14 weeks' gestation and risk of LGA neonate <i>J. Pardo (Israel)</i>	OP34.10
Knowledge of first trimester NT measurement at birth is used to predict LGA and macrosomia at term <i>A. Weissmann-Brenner (Israel)</i>	OP34.11

## Chaired short oral presentation (oral poster) sessions: 11:00–11:40

### Viewing available all week on E-poster viewing stations located in the level 2 foyer

	Abstract number
<b>OP35: Scanning asymptomatic women</b>	<b>Forum hall</b>
<i>Chairs: S. Campbell (United Kingdom); C. Exacoustos (Italy)</i>	
The normal width of the uterine cavity: does it vary with age, gravidity and parity? <i>T. Shipp (United States)</i>	OP35.01
Transvaginal color Doppler ultrasound in early diagnosis of ovarian cancer <i>M. Pascual (Spain)</i>	OP35.02
Use of three-dimensional transvaginal ultrasonography as a second opinion in the follow-up of intrauterine devices in the primary health care system <i>F. Guerra (Chile)</i>	OP35.03
2D- and 3D-ultrasound in the visualization of different levonorgestrel-releasing intrauterine systems and copper intrauterine devices <i>D. Van Schoubroeck (Belgium)</i>	OP35.04
Characterization of pelvic organs by Doppler waveform shape <i>R. Hershkovitz (Israel)</i>	OP35.05
Saline sonohisterosalpingography as the main method of endometrial thickness assessment in HRT after menopause <i>L. Ples (Romania)</i>	OP35.06
A case of meigs syndrome in young woman <i>M. Annappa (United Kingdom)</i>	OP35.07
Diagnosis of an echinococcal ovarian cyst by three-dimensional transvaginal ultrasound and volume contrast imaging <i>D. Markov (Bulgaria)</i>	OP35.08

<sup>A</sup> This abstract has been shortlisted as a finalist for the Alfred Kratochwil 3D abstract award. The winner will be announced at the closing ceremony.

# Short oral presentations – Thursday 14 October 2010

Abstract number

## OP36: Fetal heart V: cardiac and vascular anomalies

Club A

Chairs: A. Baschat (United States); F. Crispi (Spain)

- Association between chromosomal anomalies and isolated muscular ventricular septal defects  
*O. Pata (Turkey)* OP36.01
- Fetal hypoplastic thymus size measured by sonography is related to conotruncal cardiac defects or intrauterine infection  
*G. Lv (China)* OP36.02
- Review of the natural history of tetralogy of Fallot with absent pulmonary valve syndrome: does prenatal diagnosis imply increased risk?  
*Y. Mivelaz (Canada)* OP36.03
- Perinatal outcome after prenatal diagnosis of Ebstein's anomaly  
*J. Martinez (Spain)* OP36.04
- Isolated intra-abdominal umbilical vein (IAUV) varix in 163 fetuses: antenatal management and postnatal outcomes  
*D. Wood (United States)* OP36.05
- This is the first report of the spontaneous occlusion of ductus venosus in prenatal  
*Y. Kotani (Japan)* OP36.06
- Absence of ductus venosus: associated anomalies and heart failure in relation to the extra-or-intrahepatic umbilical venous drainage  
*A. Borrás (Spain)* OP36.07
- Intrathoracic herniation of the liver is associated with predominant left heart hypoplasia in human fetuses with left diaphragmatic hernia  
*R. Stressig (Germany)* OP36.08
- Altered fetal cardiac function in fetuses with congenital cystic adenomatoid malformation  
*M. Kim (South Korea)* OP36.09
- Early prenatal detection and successful transcatheter embolization of congenital arteriovenous malformation  
*H. Jicinska (Czech Republic)* OP36.10

## OP37: Maternal fetal Doppler II

Club B

Chairs: S. Gudmundsson (Sweden); E. Hernandez-Andrade (Mexico)

- First trimester maternal serum PP13 as screening test for preeclampsia and small gestational age  
*M. Parra-Cordero (Chile)* OP37.01
- Optimal timing for blood pressure assessment during the 11–13 week scan  
*R. Napolitano (United Kingdom)* OP37.02
- Sensitivity of the lower, mean and higher uterine artery first trimester Doppler pulsatility index in screening for pre-eclampsia  
*R. Napolitano (United Kingdom)* OP37.03
- Sensitivity of the higher, lower and mean second trimester uterine artery Doppler resistance index in screening for pre-eclampsia  
*R. Napolitano (United Kingdom)* OP37.04
- Increased uterine arteries resistance after 34 weeks and pregnancy outcome  
*E. Maroni (Italy)* OP37.05
- A new non-invasive method for measuring uterine vascular resistance and its relationship to uterine artery Doppler indices: a longitudinal study  
*K. Flo (Norway)* OP37.06
- Differences and similarities in cardiovascular profile of chronic hypertensive and late preeclamptic patients at 24 weeks gestation  
*B. Vasapollo (Italy)* OP37.07
- Echocardiographic evaluation of cardiovascular adaptation in pregnancy  
*K. Melchiorre (United Kingdom)* OP37.08
- Changes in uterine artery Doppler velocimetry and pregnancy outcome in pregnant women with huge uterine myomas  
*K. Nam (South Korea)* OP37.09
- Ophthalmic artery Doppler in pregnant women with systemic lupus erythematosus  
*A. Diniz (Brazil)* OP37.10

## OP38: Fetal size

Club D

Chairs: W. Lee (United States); A. Ngu (Australia)

- Correlation of first trimester fetal crown–rump length and outcome of pregnancy and birth weight  
*H. Vafaei (Islamic Republic of Iran)* OP38.01
- Association between birth weight and second trimester 3D placental volumetry, intraplacental vascularization and amniotic fluid cytokines  
*B. Yazdi (Germany)* OP38.02
- Sonographer standardization of fetal biometry for improving quality and consistency in a prospective large multi-centre study  
*I. Sarris (United Kingdom)* OP38.03
- Estimation of birth weight by 3D middle thigh volume and standard 2D fetal biometry in Chinese population  
*F. Yang (China)* OP38.04
- Impact of maternal diseases – hypertension, pregestational diabetes and addictions – in birth weights should be considered in normal charts  
*A. Insunza (Chile)* OP38.05
- Is it time for customised growth charts for morbidly obese women in the developed world?  
*A. Schofield (United Kingdom)* OP38.06
- Fetal measurements and growth in pregestational diabetes mellitus  
*H. Mirghani (United Arab Emirates)* OP38.07

# Short oral presentations – Thursday 14 October 2010

	Abstract number
Ultrasound fetal weight estimation in type 1 diabetic pregnancies and its influence on the mode of delivery <i>I. Spalova (Czech Republic)</i>	OP38.08
Glucose challenge test between 130– 140 mg/dl; adding abdominal circumference measurement difference between 29–33 weeks may predict macrosomia <i>E. Tarim (Turkey)</i>	OP38.09
Abdominal adiposity in the first trimester predicts lipid metabolism in pregnancy <i>H. Jeong (South Korea)</i>	OP38.10
<b>OP39: IUGR III: fetal programming in placental dysfunction</b>	<b>Club E</b>
<i>Chairs: C. Brezinka (Austria); K. Maršál (Sweden)</i>	
Fetal brain metabolism assessed by MR spectroscopy and its association with neurodevelopmental outcome in small for gestational age fetuses <i>M. Sanz-Cortes (Spain)</i>	OP39.01
MRI cerebral fractal dimension analysis in preterm infants with and without intrauterine growth restriction <i>M. Sanz-Cortes (Spain)</i>	OP39.02
A new proposal of sonobiopsy of fetal brain using 3D power Doppler angiography (VOCAL) in normal and growth restricted fetuses <i>A. Rossi (Italy)</i>	OP39.03
Effects of chronic intrauterine hypoxia on intimal-media thickening and strain rate in abdominal aorta from adult male offspring rabbits <i>H. Lin (China)</i>	OP39.04
Is aortic intima media thickness in intrauterine growth restricted fetuses an early sign of atherosclerosis? <i>E. Cosmi (Italy)</i>	OP39.05, OP39.06
The Tei Index in FGR fetus <i>K. Ichizuka (Japan)</i>	OP39.07
Ultrastructural analysis of the sarcomere in relation with cardiac dysfunction in a rabbit model of intrauterine growth restriction <i>M. Illa (Spain)</i>	OP39.08
Fetal gender and fetal cardiac injury in pregnancies complicated by placental insufficiency before 34 weeks gestation <i>R. Nomura (Brazil)</i>	OP39.09
Comparative corporal composition at twelve and twenty-four months of life for babies with: intrauterine growth restriction, small for gestational age and appropriate for gestational age <i>N. Rodriguez (Spain)</i>	OP39.10
The significance of prenatal detection of fetal growth restriction by the assessment of fetal limb-volume using XI VOCALTM three-dimensional ultrasound volumetry <i>S. Bózsza (Hungary)</i>	OP39.11

# Posters – Thursday 14 October 2010

Poster question and answer sessions: 09:10–09:25

Viewing available all week on E-poster viewing stations located in the level 2 foyer

Abstract number

## P31: Imaging in the oncology patient

Forum hall

Ascites index – a new method of ultrasound evaluation of ascites volume in patients with ovarian cancer

P31.01

*P. Szkodziak (Poland)*

Comparison of four risk of malignancy indices in women with ovarian masses

P31.02

*S. Kim (South Korea)*

Appendiceal mucinous cystadenoma: a rare cause of a right lower quadrant mass

P31.03

*J. Correia (Portugal)*

A huge pyometra resulting lethal septic shock at drainage

P31.04

*C. An-Shine (Taiwan)*

Correlation between sonographic color pixel density or contrast-enhanced sonographic enhancement intensity and pathologic microvessel density of breast neoplasms

P31.05

*J. Quan (China)*

## P32: Induction and ultrasound in labour

Club A

Transperineal or transabdominal ultrasound assessing fetal head position

P32.01

*E. Torkildsen (Norway)*

3D ultrasound in monitoring the progression of labor: a reproducibility study

P32.02

*T. Ghi (Italy)*

Cervical glandular thickness assessed by 3D transvaginal ultrasound at 39 weeks gestation in relation with parity and time interval to delivery

P32.03

*S. Di Francesco (Italy)*

Prediction of postterm induction in VBAC: cervical length versus cervical volume

P32.04

*L. Young (South Korea)*

Cervical length in normal pregnant women between 20 and 34 weeks of gestation

P32.05

*A. Carmo (Brazil)*

Role of cervical length at 22–26 weeks as a predictor of Caesarean delivery in primiparous women at term: transvaginal ultrasound assessment

P32.06

*G. Ancuta (Romania)*

Sonographic cervical length measurement before labor induction in VBAC

P32.07

*M. Suh (South Korea)*

Single cervical length measurement at 36–38 weeks as a predictor of spontaneous onset of labor by 41 weeks

P32.08

*M. Park (South Korea)*

Cervical length and previous obstetric history

P32.09

*D. Petrovic (Serbia)*

Cervical length at mid-pregnancy and timing of elective repeat Cesarean delivery at term

P32.10

*H. Yoshimoto (Japan)*

Clinical and ultrasonographic management of post-term pregnancies: experience of a third level center

P32.11

*L. Guariglia (Italy)*

Interobserver repeatability of ultrasound 3D volume cervix in post-term pregnancies

P32.12

*L. Guariglia (Italy)*

Ultrasound fetal weight estimation in term singleton pregnancies

P32.13

*M. Echevarria (Spain)*

Quality control of standardized 3D acquisition for the examination of the fetal head and abdomen

P32.14

*T. Quibel (France)*

The impact of fetal weight estimation by ultrasonography in perinatal outcome of newborns with more than 3500g

P32.15

*L. Rezende (Brazil)*

Combined evaluation of angle of progression and head direction during pushing as a predictor of vaginal delivery by vacuum extraction

P32.16

*M. Pati (Italy)*

## P33: Fetal anomalies III: fetal abdomen

Club B

Prenatal diagnosis of hydrometrocolpos secondary to uterine didelphis

P33.01

*K. Kostyukov (Russian Federation)*

Imperforate hymen resulting in fetal pelvic mass causing urinary tract obstruction

P33.02

*J. Coletta (United States)*

Giant hydrometrocolpos and intrauterine demise at 34 weeks: what is the connection?

P33.03

*A. Kennedy (United States)*

Pitfalls of prenatal US diagnosis of congenital imperforated hymen

P33.04

*S. Stojic (Serbia)*

Clinical study on prenatal diagnosed ovarian cyst

P33.05

*H. Cho (South Korea)*

Prenatal diagnosis of nevus lipomatosus cutaneous superficialis of labia major in a female fetus: a case report

P33.06

*R. Mandel (Israel)*

# Posters – Thursday 14 October 2010

	Abstract number
Prenatally diagnosed vulvar fibroepithelial stomal polyp with association of uterine duplication and kidney anomalies: a case report <i>J. Dong Gyu (South Korea)</i>	P33.07
Urethral atresia: a rare cause of bladder outlet obstruction among female fetuses <i>K. Fuchs (United States)</i>	P33.08
3D multislice ultrasound in analysis of fetal urinary tract abnormalities <i>Z. Jurisic (Serbia)</i>	P33.09
Pelvis antero-posterior diameter of kidney in 2nd trimester as a powerful predictor for surgical management in pyelectasia <i>J. Kim (South Korea)</i>	P33.10
Does the time and severity of diagnosis of pyelectesis / hydronephrosis predictive of neonatal outcome <i>S. Singh (United States)</i>	P33.11
Antenatal detection of renal pelvis dilatation and its short term (6 months) postnatal outcome <i>S. Sivarajan (United Kingdom)</i>	P33.12
Characteristics and outcome of prenatally diagnosed fetal abdominal tumors <i>F. Amari (Germany)</i>	P33.13
The diagnosis of the fetal anterior abdominal wall abnormality by prenatal ultrasonography and the contrastive analysis with postnatal and odinopoeia result <i>M. Chen (China)</i>	P33.14
Gastroschisis - sonographic findings, perinatal management and postnatal outcome <i>U. Zollner (Germany)</i>	P33.15
'Giant' abdominal wall defects – is it possible to predict outcome? <i>J. Byrne (United States)</i>	P33.16
Gastroschisis and bladder herniation <i>J. Bault (France)</i>	P33.17
Evolution of sonographic findings in patent urachus with an allantoic cyst of the cord: third trimester development of pseudocysts and cord edema <i>V. Catanzarite (United States)</i>	P33.18
The prenatal sonographic features of iliojejunal atresia <i>G. Lee (South Korea)</i>	P33.19
The imaging spectrum of fetal anal atresia <i>A. Kennedy (United States)</i>	P33.20
Prenatal ultrasound findings of biliary atresia <i>K. Leung (China)</i>	P33.21
Prenatal diagnosis of fetal intrahepatic portosystemic shunt: a case report <i>O. Nieto (Spain)</i>	P33.22
Renal tubular dysgenesis: report of two cases <i>S. Nakayama (Japan)</i>	P33.23
<b>P34: First trimester IV: fetal abnormalities</b>	<b>Club E</b>
Ectopia cordis at 11w6d: a case report <i>R. Abu-Rustum (Lebanon)</i>	P34.01
Limb body wall defect: three different presentations with abdominal wall defects <i>E. Tarim (Turkey)</i>	P34.02
Incomplete pentalogy of Cantrell during first trimester of pregnancy: case report <i>A. Rossi (Italy)</i>	P34.03
Congenital hypophosphatasia associated with poorly ossified facial bone as the first ultrasound sign <i>H. Lee (South Korea)</i>	P34.04
Prenatal ultrasound detection of primary endocardial fibroelastosis in 12–13 weeks of gestation: a case report <i>T. Liliانا (Russian Federation)</i>	P34.05
Vesical puncturing for the first trimester Prune belly syndrome <i>J. Choi (South Korea)</i>	P34.06
Spontaneous reversal of cystic hygroma <i>S. Herbst (Brazil)</i>	P34.07
Developmental follow up of a female infant with recombinant Down syndrome <i>D. Strah (Slovenia)</i>	P34.08
Amniotic band syndrome versus pentalogy of Cantrell: correlation between ultrasound findings and anatomopathology report <i>L. Ferreira (Portugal)</i>	P34.09
Fetal cardiac anomaly screening in first trimester: a case report <i>G. Sepulveda Gonzalez (Mexico)</i>	P34.10
First trimester detection of OEIS syndrome: experience of two cases and their differential diagnosis <i>A. Monteagudo (United States)</i>	P34.11
Congenital diaphragmatic hernia detection during first trimester screening <i>G. Sepulveda Gonzalez (Mexico)</i>	P34.12




# Posters – Thursday 14 October 2010

	Abstract number
Sirenomelia apus: first trimester diagnosis with 2D-4D ultrasound imaging <i>E. Dosedla (Slovakia)</i>	P34.13
Brachmann-de Lange syndrome: antenatal diagnosis in two consecutive pregnancies due to rare gonadal mosaicism of NIPBL gene mutation <i>A. Schröder (Germany)</i>	P34.14
Partial and complete trisomy 16: sonographic appearance and natural history <i>E. Bornstein (United States)</i>	P34.15
Genetic ultrasonogram: considerations of detection rates in first and second trimester <i>D. Iliescu (Romania)</i>	P34.16
Fetal sex diagnosis in normal 11–14 weeks' scan setting. Is it as in the papers? <i>M. Yamamoto (Chile)</i>	P34.17
The role of early 3D/4D ultrasonography scan in the detection of mild ventriculomegaly and omphalocele in 32 cases of trisomy 18 <i>D. Deva (Romania)</i>	P34.18



## ISUOG Education 2010 / 2011, London, UK



-  **Congenital anomalies and fetal echocardiography**  
18–19 Feb 2011
-  **Doppler ultrasound in clinical obstetrics**  
1–2 Apr 2011
-  **Advanced gynecological ultrasound:  
Early pregnancy, reproductive medicine and benign gynecology**  
3–4 Jun 2011

**Reduced registration rates for ISUOG members**  
Register online at [www.isuog.org](http://www.isuog.org)





**21st World Congress on Ultrasound  
in Obstetrics and Gynecology**

**18 – 22 September 2011  
Los Angeles, USA**

## Critical dates

January 2011	Registration and Call for Papers opens
18 March 2011	Abstract submission and reduced rate registration deadline
	Exhibition / sponsorship discount deadline
18 July 2011	Early bird registration rate deadline
18 September 2011	Onsite registration opens

**Visit the [ISUOG](http://www.isuog.org) website for full details**

**HOLLYWOOD**

# Sponsors' activities

The following activities do not form part of the World Congress CME program; the World Congress and ISUOG are not responsible for the content of these sessions.

## Satellite symposia

Room	MONDAY 11 OCTOBER	TUESDAY 12 OCTOBER	WEDNESDAY 13 OCTOBER
Congress hall	<b>Philips Healthcare</b> Satellite symposium 12:45–13:45  <b>Revolutions in ultrasound technology for revelations in patient care</b> Chair: <i>K. Kalache (Germany)</i> PureWave in gynecology – seeing is believing <i>E. Epstein (Sweden)</i> Putting iU22 xMATRIX Technology & PureWave transducers to the test <i>B. Tutschek (Switzerland)</i> The fetal heart and new ways to explore it with the iU22 xMATRIX <i>W. Lee (United States)</i>	<b>Siemens AG</b> Satellite symposium 12:45–13:45  <b>Prenatal diagnosis of vascular anomalies of the soft tissue</b> Chair: <i>P. Calda (Czech Republic)</i> Prenatal diagnosis of vascular anomalies of the soft tissue <i>L. Guibaud (France)</i>	<b>GE Healthcare</b> Satellite symposium 12:45–13:45  <b>All about Quality</b> Early Pregnancy + automatic measurement of NT <i>B. Benoit (France)</i> Cardiovascular Imaging in OB <i>D. Paladini (Italy)</i> 3D fetal neuroscan made simple <i>I. Timor-Tritsch (United States)</i>
		<b>Medison</b> Satellite symposium 12:45–13:45  <b>New frontiers in obstetric 3D/4D ultrasound</b> 12:45–13:00 What is new at Medison? <i>W. van de Vooren (Netherlands)</i> 13:00–13:15 Automatic mid sagittal plane detection <i>J. Calvo (Spain)</i> 13:15–13:30 The usefulness of volume NT <i>H. Won (Korea)</i> 13:30–13:45 Elastoscans of cervix: implications timing of delivery <i>M. Swiatkowska-Freund (Poland)</i>	
Forum hall			

## Satellite education area

WEDNESDAY 13 OCTOBER	
	<b>Medison</b> Satellite education area
Terrace 1	09:00–10:30 <b>Introduction to Elastoscans</b> Chair <i>J. Huime (Netherlands)</i> Principles of Elastoscans <i>W. van de Vooren (Netherlands)</i> Elastoscans in breast <i>V. Duda MD (Germany)</i> Elastoscans in uterine disorders <i>J. Huime (NL) J. Veldman (Belgium)</i> Elastoscans of cervix: implications for timing of delivery <i>M. Swiatkowska-Freund (Poland)</i>
	10:30–11:00 <b>Coffee break</b> 11:00–12:30 <b>1st trimester assessment</b> Chair <i>W. Sepulveda (Chile)</i> 1st trimester extended examination, live scan <i>W. Sepulveda (Chile)</i> Introduction to volume NT <i>W. van de Vooren (Netherlands)</i> The ideal mid sagittal plane <i>J. R. Calvo (Spain)</i> 2D NT or 3D NT? <i>V. Frisova (Czech Republic)</i> Volume NT <i>H.S. Won (Korea)</i>
	12:30–14:00 <b>Lunch break and PC Training: 1st trimester volume NT</b> Introduction to volume NT: PC version <i>J. Bartholomew (Netherlands)</i> Volume NT normal & pathology <i>V. Frisova (Czech Republic)</i>
	14:00–15:40 <b>PC Training: Applications for 3D MXI</b> Introduction to 3D MXI <i>J. Bartholomew (Netherlands)</i> Gynecology and 3D MXI <i>G. Condous (Australia)</i> 3D MXI in 1st Trimester <i>W. Sepulveda (Chile)</i> 3D MXI in 2nd and 3rd trimester <i>K. Kalache (Germany)</i>
	15:40–16:10 <b>Coffee break</b> 16:10–17:00 <b>Live scan demonstrations</b> 3D MXI Live <i>K. Kalache (Germany)</i>



# Sponsors' activities

Room	MONDAY 11 OCTOBER	TUESDAY 12 OCTOBER	WEDNESDAY 13 OCTOBER	THURSDAY 14 OCTOBER
Terrace 2	<b>GE Healthcare</b> <b>VolusonClub lounge</b> (don't forget your VolusonClub member card)			
Terrace 1	<b>Medison Hospitality suite</b> Outside the breaks and lunchtime the Medison hospitality suite will be open for self-learning PC training and Medison demonstrations. There is internet access in the suite and you will have time to relax in comfortable surroundings.		<b>Medison Satellite education area</b> See page 78 for details	<b>Medison Hospitality suite</b>
	10:30–11:00: Interactive training using uVote: fetal heart cases <i>R. Bataeva (United Kingdom)</i> 12:30–14:00 3D fetal heart: offline analysis with PC <i>R. Bataeva (United Kingdom)</i> 15:40–16:10 Fetal heart pathology: uVote interactive lecture <i>J. Carvalho (United Kingdom)</i>	10:30–11:00: 1st trimester case: uVote interactive lecture <i>W. Sepulveda (Chile)</i> 12:45–13:45 Medison satellite symposium: hospitality suite closed 15:40–16:10 1st trimester volume NT live scan: Accuvix V20 Prestige <i>V. Frisova (Czech Republic)</i>		10:30–11:00: 3D/4D ultrasound in the second trimester – live scan Accuvix V20 Prestige <i>A. Jurisic (Serbia)</i>
Club B	<b>GE Healthcare</b> Meet the expert sessions: 10:30–11:00: Fetal heart <i>K. Helling (Germany)</i> 12:30–14:00: Ultrasound examination of CNS <i>G. Piliu (Italy)</i> 15:40–16:10 Volume ultrasound – practical review with clinical examples <i>M. Wiechec (Poland)</i>	<b>GE Healthcare</b> Meet the expert sessions: 10:30–11:00: Three-dimensional anatomy of the midline cerebral structures <i>F. Vinals (Chile)</i> 12:30–14:00 Volume ultrasound for fetal medicine – tips & tricks <i>B. Benoit (France)</i> 15:40–16:10 Fetal heart <i>G. DeVore (United States)</i>	<b>Philips Healthcare</b> Live scan demonstrations. Please make an appointment on the Philips stand.	
Club D	<b>Siemens AG</b> Siemens will be offering live scanning demonstrations (including 3D scans), in their hospitality suite throughout the Congress. Please visit the Siemens stand on level 2, to make an appointment, or come along to our suite during coffee and lunch breaks.			
Room 2.1	<b>Aloka</b> 10:30–11:00 <i>G. Rizzo (Italy)</i> 15:40–16:10 ALOKA clinical specialists: How new technology brings real clinical outcomes – auto NT measurement, e-flow, high resolution probe for 1st trimester exams.	<b>Aloka</b> 10:30–11:00 <i>K. O. Kagan (Germany)</i> 15:40–16:10 <i>J. Carvalho (UK)</i>		



# ISUOG Education 2011

## Congenital anomalies & fetal echocardiography

**Course directors:** *Rabih Chaoui (Germany)*  
*Dario Paladini (Italy)*  
*Gianluigi Pilu (Italy)*  
*Basky Thilaganathan (UK)*



Royal College of  
Obstetricians and  
Gynaecologists

Setting standards to improve women's health

**Dates:**

**18–19 February 2011**

**Location:**

RCOG  
27 Sussex Place  
Regent's Park  
London  
NW1 4RG

**Fees:**

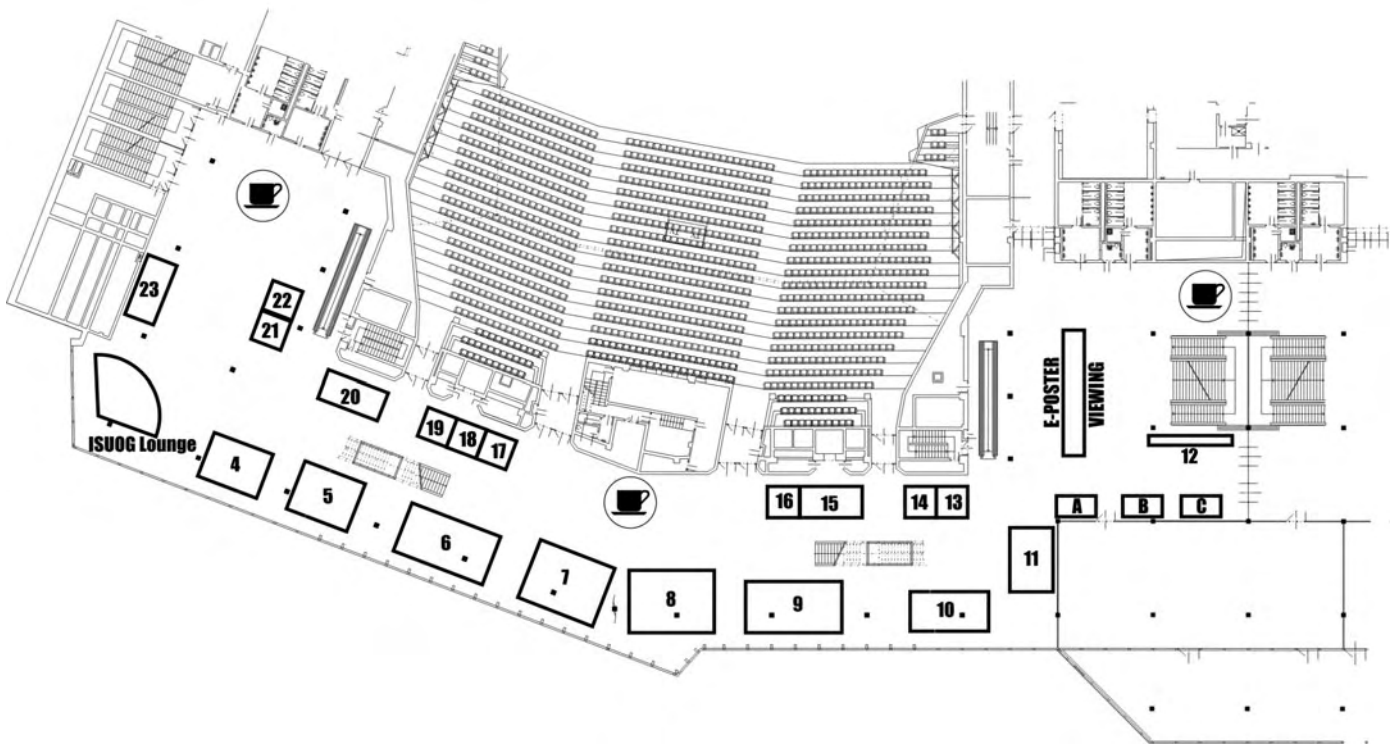
£270 (includes lunch and refreshments)  
10% discount for ISUOG & RCOG members

**CME:**

Credits will be applied for

**Contact:**

E: [congress@isuog.org](mailto:congress@isuog.org)  
T: +44 (0)20 7471 9955  
F: +44 (0)20 7471 9959



## Congress hall foyer, Level 2

### Exhibitor list

Company	Stand no.	Company	Stand no.
7th International Scientific Meeting, Macau	Table A	Karl Storz GmbH & Co. K.G.	19
Aloka Holding Europe A.g	10	Medison Europe	8
astraiia software gmbh	16	MIDES Handel	14
B•R•A•H•M•S GmbH	21	MT Technika Moscow	22
Chison Medical Imaging Co. Ltd	17	PerkinElmer	23
CIVCO Medical Solutions	13	Philips Healthcare	7
ContextVision AB	18	Shenzhen Mindray Bio-Medical Electronics Co. Ltd	15
Cook Medical	11	Siemens AG	9
Esaote Europe BV	4	Toshiba Medical Systems	5
Fetal Medicine Foundation USA	Table C	Wiley-Blackwell	ISUOG Lounge
Future Meetings	Table B	Wisepress Online Bookshop	12
GE Healthcare	6	Zonare Medical Systems GmbH	20
International Society of Ultrasound in Obstetrics and Gynecology	ISUOG Lounge		

Please note that the locations of exhibition stands are subject to change.

Please see detailed exhibitor profiles on pages 82–87 for more information about the companies listed.

# Exhibitor profiles

## 7th International Scientific Meeting, Macau

Table A

Rua de Xangai 175, Edif. ACM, 12 andar G, Macau

T: +853 2870 3858

F: +853 2870 3857

C: Dr Wong Keong, Congress Chairman / Ms Canny Ho,  
Conference Secretariat

E: [info@isuogmacau2011.com](mailto:info@isuogmacau2011.com)

W: [www.isuogmacau2011.com](http://www.isuogmacau2011.com)

The International Scientific Meeting (ISM) is an annual international conference, which is held outside of Europe or North America, under the auspices of ISUOG. ISUOG's international faculty come together to offer a high quality Education and Scientific program suitable for an international audience but with a carefully targeted regional focus. The meeting has previously been held in Singapore, Chile, Hong Kong, Russia, and, most recently, in Cairo. In February 2011, it will be in Macau and an exciting, interactive program has been prepared to stimulate exchanges on new techniques and technology. For details, please visit our website. Macau welcomes you!



## ALOKA Holding Europe AG

Stand no: 10

Steinhauserstrasse 74, 6300 Zug, Switzerland

T: +41 41 747 21 20

F: +41 41 747 21 21

C: Yvonne Lauper

E: [Int.sales@aloka-europe.com](mailto:Int.sales@aloka-europe.com)

W: [www.aloka-europe.com](http://www.aloka-europe.com)

ALOKA a world's leading pioneer of ultrasound systems for 60 years providing imaging solutions for Obstetrics / Gynaecology ultrasound. Please visit our exhibition booth no. 10 and our hospitality room 2.1 for live scanning sessions with the latest ProSound systems at ISUOG 2010 in Prague, Czech Republic. ALOKA is dedicated to excellence providing the systems needed to ensure the best quality of life for patients. ALOKA has its headquarters in Toyko, Japan and European in Zug, Switzerland.

## astrai software gmb

Stand no: 16

Occam Str. 20, 80802 München, Germany

T: + 49 89 127 1147 0

F: + 49 89 127 1147 17

C: Roland Denk, Katarzyna Tucka

E: [info@astrai.com](mailto:info@astrai.com)

W: [www.astrai.com](http://www.astrai.com)

**astrai software software for women's health** was developed with the help of Professor Kypros Nicolaidis and a team of internationally recognised specialists in Gynaecology and Obstetrics.

astrai software is a modular database application developed specifically for obstetricians and gynaecologists and has been kept up-to-date to the latest state-of-the-art.

Today, astrai has been translated into over 25 languages and installed in over 800 doctor's hospitals all over the world.

## B•R•A•H•M•S GmbH

Stand no: 21

Neuendorfer Str. 25, 16761 Hennigsdorf, Germany

T: + 49 3302 883 0

F: + 49 3302 883 100

C: Dr Gabriele Grunow

E: [brahms@brahms.de](mailto:brahms@brahms.de)

W: [www.brahms.de](http://www.brahms.de)

B•R•A•H•M•S GmbH specialises in innovative products which facilitate earlier diagnosis of diseases and better control of therapy, thus enabling doctors to provide more efficient and economic patient care. Major fields of activity are laboratory tests in prenatal screening, thyroid diseases, oncology, sepsis, and cardiology. The B•R•A•H•M•S analytical platform KRYPTOR is in routine use by the Fetal Medicine Foundation (FMF), UK since 1999, making the OSCAR concept of screening for chromosomal abnormalities possible.

## CHISON Medical Imaging Co.,Ltd

Stand no: 17

No. 9 Xin Hui Huan Road, New District, Wu Xi, CHINA, 214028

T: + 86 5108 5310 937

F: + 86 5108 5310 726

C: Chris Ji

E: [export@chison.com.cn](mailto:export@chison.com.cn)

W: [www.chison.com.cn](http://www.chison.com.cn)

CHISON is one of the world's leading manufacturers for ultrasound systems. It has specialized in the development & manufacturing of high quality ultrasound systems for over 14 years. It has also received CE certificate and FDA approval.

## CIVCO Medical Solutions

Stand no: 13

102 First Street South, Kalona, IA 52247, USA

T: + 1 800 445 6741

F: + 1 877 657 0336

C: Jannifer Tobin

E: [info@civco.com](mailto:info@civco.com)

W: [www.civco.com](http://www.civco.com)

With over 25 years of experience, CIVCO is the recognized global specialist in the design, manufacture and marketing of image-guided solutions for diagnostic and minimally invasive procedures. CIVCO partner's with leading OEMs to supply innovative products such as image-guided needle guidance systems, infection control covers, imaging supplies and positioning/stabilizing equipment.

# Exhibitor profiles

## ContextVision AB

Stand no: 18

Kungsgatan 50, 11135 Stockholm, Sweden

T: +46 8 750 3550

F: +46 8 750 5494

C: Mildred Stenberg

E: [info@contextvision.se](mailto:info@contextvision.se)

W: [www.contextvision.com](http://www.contextvision.com)

ContextVision is the leading independent developer in medical imaging enhancement, analysis and processing technologies, serving leading OEMs and distributors for 27 years.

ContextVision's embedded imaging software is relied upon daily by thousands of users around the globe. ContextVision's patented GOP algorithm allows unprecedented image quality to be achieved by simultaneously enhancing fine structure while reducing noise and speckle across MRI, X-Ray, Ultrasound, CT, and IR.

## Cook Medical

Stand no: 11

O'Halloran Road, National Technology Park, Limerick, Ireland

T: +353 (0)61 334440

F: +353 (0)61 334441

C: Laura McMahon

E: [lmcmahon@cook.ie](mailto:lmcmahon@cook.ie)

W: [www.cookmedical.com](http://www.cookmedical.com)

Since 1963, Cook Medical has been among the leaders in developing healthcare devices that have improved lives around the world. The Cook Medical Women's Health division specializes in the design, manufacture and sale of high-quality, minimally invasive products for obstetrics, gynecology and reproductive medicine.

Cook Medical – Developing simple solutions for women's health.

## Esaote Europe BV

Stand no: 4

Via di Caciolle 15, 50127 Firenze, Italy

T: +39 055 42291

F: +39 055 4229208

E: [international.sales@esaote.com](mailto:international.sales@esaote.com)

W: [www.esaote.com](http://www.esaote.com)

Esaote, the Europe-based Ultrasound Manufacturer is internationally recognized as one of the 'Top Ten' world's leading diagnostic imaging companies. Esaote is dedicated to constantly significant new diagnostic capabilities for the modern women's healthcare professional.

Come to the Esaote stand (4) to meet our complete product line-up, which provides 4D imaging on top of portability, and many other solutions to meet your expectations.

## Fetal Medicine Foundation USA

Table C

3751 Red Oak Court, Beavercreek, Ohio 45430, USA

T: +001 9372 086 084

F: +001 9372 084 268

C: Terry Stuerman

E: [tstuerman@mvh.org](mailto:tstuerman@mvh.org)

W: [www.fetalmedicine.com](http://www.fetalmedicine.com)

Founded in 1995 by Professor Kypros Nicolaides, the Fetal Medicine Foundation is a charitable organization at the forefront of research, education and training in fetal medicine. The foundation, with support from an international group of experts, has introduced an educational program that is available for free and online for the world. As of now over 25,000 healthcare professionals from 170 countries have taken the free 11–13 weeks scan course. Other free courses include Fetal Echocardiography, Cervical Assessment & Doppler Ultrasound.

## Future meetings:

Table B

Pick up information about future meetings and related events. ISUOG staff will also be available here on Thursday once the exhibition has closed to answer questions about membership or future events.



GE imagination at work

## GE Healthcare

Stand no: 6

Beethovenstrasse 239, D-42665 Solingen, Germany

T: +49 212 28020

F: +49 212 280228

W: [www.gehealthcare.com](http://www.gehealthcare.com)

GE healthcare has a vision of accelerating personalized medicine where earlier accurate diagnosis, enabling earlier therapeutic intervention provides more efficient and effective treatment outcomes, reducing healthcare costs. At this year's ISUOG congress we are presenting the latest 2010 of our well know Voluson line, including the new breakthrough release of the Voluson E8 and Voluson E6. Visit GE Healthcare at booth number 6, and if you are a VolusonClub member, we are awaiting your visit in Terrace 2, in the VolusonClub lounge (do not forget to bring your VolusonClub member card).

# Exhibitor profiles

## ISUOG

Unit 4 Blythe Mews, Blythe Road, London W14 0HW, UK

T: +44 (0) 20 7471 9955

F: +44 (0) 20 7471 9959

C: Anna Lewis

E: [info@isuog.org](mailto:info@isuog.org)

W: [www.isuog.org](http://www.isuog.org)

With more than 3,400 members in 100 countries the **International Society of Ultrasound in Obstetrics and Gynecology (ISUOG)** is the most important Society in this medical specialty. ISUOG encourages the exchange of research information and promotes and provides education. Members receive many benefits including the Journal, Ultrasound in Obstetrics and Gynecology, reduced fees to ISUOG Courses and Congress, online educational material such as Web Lectures and, **new for 2011, access to our Congress Web Portal and lectures from the Congress.** All full paying delegates in Prague will automatically be registered as members of ISUOG for 2011 and can immediately enjoy all our online benefits. Reduced rates to attend our 2011 World Congress in Los Angeles, USA (18–22 September 2011) also apply. Come and collect your LA free gift, or (for new members) a sample of our latest Journal. See our appointments schedule on page ?? and visit the ISUOG lounge to find out more!

## ISUOG lounge

## Karl Storz GmbH & Co. KG

Mittelstrasse 8, 78532 Tuttlingen, Germany

T: +49 7461 7080

F: +49 7461 7081 05




E: [info@karlstorz.de](mailto:info@karlstorz.de)

W: [www.karlstorz.de](http://www.karlstorz.de)




KARL STORZ is one of the world's leading suppliers of endoscopes for all fields of application. The family-owned company with its headquarters in Tuttlingen, Germany has 5300 employees worldwide. With a history that stretches back over 60 years, KARL STORZ is well-known for its innovative and high-quality products. Its range of products has been rounded off with the development of the integrated operating room OR1TM and by integrating the field of flexible endoscopy into the various specialties.

Stand no: 19

### Visit the ISUOG Lounge in the exhibition area anytime to find out more about the Society and its activities:

-  **ISUOG membership, online resources, courses and events**
-  **Submitting and publishing in Ultrasound in Obstetrics and Gynecology (UOG)**
-  **Accessing UOG online**
-  **NEW Congress web portal**

### Special events on the ISUOG Stand:

-  **Meet the Publisher:** representatives from the publisher Wiley-Blackwell will be on the ISUOG stand at all times.
-  **Meet an Editor:** ISUOG's managing Editor Sarah Hatcher and/or UOG's Editors will be on the stand to answer author queries.
-  **Membership Clinic:** ISUOG's membership officer, Anna Lewis, will be available to demonstrate ISUOG's online resources and answer your membership queries.



	Monday 11 October	Tuesday 12 October	Wednesday 13 October
09:00 - 17:00 (all day)	MEET THE PUBLISHER		
	MEET AN EDITOR		
10:30 - 11:30	MEMBERSHIP & WEBSITE CLINIC		
12:30 - 14:00			MEET AN EDITOR
13:00 - 14:00	MEMBERSHIP & WEBSITE CLINIC		
15:30 - 16:30	MEMBERSHIP & WEBSITE CLINIC	MEET AN EDITOR	
	MEET AN EDITOR		

# Exhibitor profiles



## Medison Europe

Parellaan 10, 2132WS, Hoofddorp, The Netherlands

T: +31 2356 49035

F: +31 2356 49039

C: C J van Dashorst

E: [marketing5@medison.com](mailto:marketing5@medison.com)

W: [www.medison.com](http://www.medison.com)

Stand no: 8

Medison is a global medical solutions company creating solutions for everything from technological development to multi-modality products. We have a leading name in diagnostic ultrasound since our foundation in 1985; we have remained at the forefront of research and development in diagnostic 3D/4D technology for 25 years. Since revolutionizing the industry with the introduction of the first commercial 3D/4D ultrasound device, we continue to innovate technologies that have made 3D/4D ultrasound an indispensable diagnostic tool for clinicians the world over. Today we continue to pioneer revolutionary ultrasound technologies from small portable systems to the ultimate diagnostic 3D/4D ultrasound imaging systems. During this our 25th Anniversary year we continue to seek to improve the wellbeing of people the world over. Medison, leading with innovation and ingenuity.

## MIDES

Weinholdstrasse 33, A – 8010 Graz, Austria

T: +43 316 42 65 00

F: +43 316 42 65 00 3

C: Hannes Fliesser

E: [us@mides.com](mailto:us@mides.com)

W: [www.mides.com](http://www.mides.com)

Stand no: 14

Ultrasound and tee-probe repair

Trading in ultrasound devices, CT/MRI

Huge range of exchange probes on stock

### News:

TEE CARE All in one: Cleaning and disinfection device for TEE-probes.

Software controlled disinfection process with exact documentation of process within a closed system.

ISO 9001:2000 certified

ISO 13485 in progress

## MT Technika Moscow

Ivanovskaya 19/21, RUS-127434 Moscow, Russia

T: +7 495 7440 035

F: +7 495 7302 132

C: Denis Kim

E: [kim@mttechnica.ru](mailto:kim@mttechnica.ru)

W: [www.mttechnica.ru/english](http://www.mttechnica.ru/english)

Stand no: 22

MT Technika is a well-established middle-sized trading company (founded 1993) with its headquarters in Moscow. Our main activity is the supply of medical equipment and devices (X-ray, MRI, CT, ultrasound diagnostic systems, ophthalmology, cardiology, ICU, Ob & Gyn, Dental, Physiotherapy etc.), along with technical service and maintenance to public and private customers in all regions of Russia, based on a wide network of local subsidiaries and partners.

Now we are entering terra nova – we are offering a self-developed educational program product for physicians. This promising product has already found a very positive echo in Russia, and we are pleased to present it now to the rest of the world.

## PerkinElmer Inc.

Mustionkatu 6, 20750 Turku, Finland

T: + 358 2 2678 484

F: + 358 2 2678 332

C: Camilla Abrahamsson

E: [Camilla.Abrahamsson@perkinelmer.com](mailto:Camilla.Abrahamsson@perkinelmer.com)

W: [www.perkinelmer.com](http://www.perkinelmer.com)

Stand no: 23

PerkinElmer is a global company focused on improving the health and safety of people and their environment.

The company supports all strategies for trisomy screening and will launch a new dual first trimester prenatal screening assay for use with maternal dried blood spot samples in 2010.

DELFLIA® Xpress PIGF supports 1st trimester prediction of pre-eclampsia. The assay permits users to take advantage of the web-based pre-eclampsia risk calculation service offered by Professor Cuckle.

Prenatal BoBs™ uses multiplexing bead technology for faster and more comprehensive prenatal diagnosis of genetic disorders.



# Exhibitor profiles

## PHILIPS

sense and simplicity

### Philips Healthcare

Hewlett-Packard Str. 2, 71034 Böblingen, Germany

T: +49 7031 463 2230

F: +49 7031 463 1552

C: Maria Buscemi

E: [maria.buscemi@philips.com](mailto:maria.buscemi@philips.com)

W: [www.philips.com/healthcare](http://www.philips.com/healthcare)

Philips is one of the world's leading healthcare technology companies. We are committed to understanding the technological and human needs of patients and caregivers and to delivering solutions that enable more confident diagnoses, more efficient delivery of care, and more positive user experiences. People focused. Healthcare simplified. Visit us at booth 7.

Stand no: 7

### Shenzhen Mindray Bio-Medical Electronics Co., Ltd.

Stand no: 15

T: +86 755 2658 2888

F: +86 755 2658 2680

E: [intl-market@mindray.com](mailto:intl-market@mindray.com)

W: [www.mindray.com](http://www.mindray.com)

Mindray is dedicated to providing the worldwide medical professionals with ultrasound systems with value added perform. We have always been developing products by combining patient-focused technologies and ease-to-use designs, which is only seen in more expensive alternatives. In the future we are committed to provide you rich series of new products needed to face with different clinical challenges.

## TOSHIBA

Leading Innovation >>>

EXPERIENCE  
APLIO MX NOW

TOSHIBA  
Leading Innovation >

Visit us at our booth and receive a "hearty" present.

Visit us at our booth and receive a "hearty" present.

Monday

11 October 2010

11:00 – 12:30

Forum Hall

**Identifying risk in monochorionic twin pregnancy**

Tuesday

12 October 2010

11:00 – 12:30

Congress Hall

**CNS imaging in early pregnancy**

Wednesday

13 October 2010

14:00 – 15:00

Congress Hall

**Long term outcome in fetal growth restriction**

[www.toshiba-medical.eu](http://www.toshiba-medical.eu)



ULTRASOUND CT MRI X-RAY SERVICES



# Exhibitor profiles

## SIEMENS

### Siemens AG

Stand no: 9

HCC 431, Henkestrasse 127, 91052 Erlangen, Germany

T: +49 9131 840 836

C: Ingrid Bast

W: [www.Siemens.com/healthcare](http://www.Siemens.com/healthcare)

Siemens Healthcare continuously innovates ultrasound technology and provides real solutions for clinicians in OB/GYN today.

Through its application-centric focus, this dedicated team of ultrasound professionals provides practical solutions that help improve clinical outcomes. Numerous innovative technologies enabled ultrasound to play an increasing role in obstetrics and gynecology. For instance, in obstetrics, ultrasound imaging has become the definitive method for monitoring fetal development, analyzing fetal anatomy and detecting abnormalities with 2D, 3D and 4D imaging.

## TOSHIBA

### Leading Innovation >>>

### Toshiba Medical Systems

Stand no: 5

Zilverstraat 1, 2718 Rpzooetermeet, The Netherlands

T: +31 79 368 9222

F: +31 79 368 9444

C: Jeroen Uijttenhout

E: [info@tmse.nl](mailto:info@tmse.nl)

W: [www.toshiba-medical.eu](http://www.toshiba-medical.eu)

As a world leader in diagnostic imaging, we provide you with ultrasound systems that offer outstanding clinical performance backed by a comprehensive array of unique, clinically validated technologies.

A full range of high-performance imaging functions allows you to visualize minute tissue details and vascular structures in 2D, 3D or 4D with precision for a faster and more accurate diagnosis. Seeing is believing. Visit our stand and ask for a demonstration, or check [www.toshiba-medical.eu](http://www.toshiba-medical.eu) for our contact details and more information.

Toshiba: Made for Patients, Made for You, Made for Life!



### Wiley Blackwell

ISUOG lounge

9600 Garsington Road, Oxford OX4 2DQ, UK

T: +44 (0)1865 476364

E: [pwright@wiley.com](mailto:pwright@wiley.com)

Make sure you visit the Ultrasound in Obstetrics & Gynecology (UOG) section of the ISUOG stand to claim your free UOG pen, or enter our iPad competition by signing up for the UOG newsletter. New members can collect their free sample copy of the latest issue of UOG.

UOG is the leading peer-reviewed journal on imaging within the field of obstetrics and gynecology, with a current Impact Factor of 3.154 (JCR® 2009).

### Wisepress Online Bookshop

Stand no: 12

The Old Lamp Works, 25 High Path, Merton Abbey, London SW19 2JL, UK

T: +44 20 8715 1812

F: +44 20 8715 1722

C: Nadia Ahmed – Bookshop Manager

E: [bookshop@wisepress.com](mailto:bookshop@wisepress.com)

W: [www.wisepress.com](http://www.wisepress.com)

Wisepress.com, Europe's leading conference bookseller, has a complete range of books and journals relevant to the themes of the meeting. Books can be purchased at the stand or, if you would rather not carry them, posted to you – Wisepress will deliver worldwide. In addition to attending 250 conference per year, Wisepress has a comprehensive medical and scientific bookshop online with great offers, some up to 40% off the publisher list prices.

### ZONARE Medical Systems GmbH

Stand no: 20

Henkestrasse 91, DE-91052, Erlangen, Germany

T: +49 9131 974 940

F: +49 9131 974 9410

C: Andrea Franke / Jim Lucas

E: [info@zonare.de](mailto:info@zonare.de)

W: [www.zonare.com](http://www.zonare.com)

ZONARE medical systems manufactures premium ultrasound systems that combine its proprietary technology with an innovative physical design. Zone Sonography™ technology, ZONARE's unique patented approach to ultrasound imaging, represents an entirely different way to echo data acquisition and image formation that results in faster data acquisition and unique image processing, enabling the Z.ONE platform to provide premium image quality, performance and features, as well as advanced image processing, capabilities without the limitations of conventional systems.

# ISUOG committee meetings

Date	Start time	End time	Meeting	Meeting Room
Saturday 9 October	08:30	18:00	ISUOG Board	Club H
Sunday 10 October	09:00	10:00	Meeting Planning Committee	Club H
Sunday 10 October	10:00	11:00	LA Local Organising Committee	Club H
Sunday 10 October	11:00	12:00	Scientific Committee	Meeting Hall II
Sunday 10 October	12:30	13:15	Session Chairs' Briefing	Club H
Sunday 10 October	15:30	16:00	<b>Annual General Meeting (ALL DELEGATES)</b>	Congress Hall
Monday 11 October	8:00	09:00	Gold Medal Committee	Club H
Monday 11 October	09:00	10:30	Outreach Committee	Meeting Hall II
Monday 11 October	10:00	10:30	Journal Watch Meeting	Club H
Monday 11 October	10:45	12:15	Education Committee	Meeting Hall II
Monday 11 October	10:30	12:00	Safety Committee	Club H
Monday 11 October	12:30	14:00	Editorial Board	Club H
Monday 11 October	14:30	15:30	Perinatal Doppler Focus Group	Club H
Monday 11 October	14:30	16:00	Clinical Standards Committee	Meeting Hall II
Monday 11 October	17:40	18:40	IPULA (Early Pregnancy) Group	Meeting Hall II
Tuesday 12 October	08:30	12:30	WFUMB meeting	Meeting Hall II
Tuesday 12 October	09:30	10:30	Web Editorial Board	Club H
Tuesday 12 October	11:00	12:00	Gynecology Special Interest Group	Club H
Tuesday 12 October	12:30	14:30	Journal Strategy Meeting	Club H
Tuesday 12 October	12:45	13:45	Gynecology Trainee Education Group	Meeting Hall II
Tuesday 12 October	14:00	15:00	Fetal Heart Special Interest Meeting	Meeting Hall II
Tuesday 12 October	15:00	16:00	Fetal MRI Focus Group	Club H
Wednesday 13 October	10:00	11:00	Scientific Committee	Club H
Wednesday 13 October	11:50	12:15	3D Focus Group	Meeting Hall II
Wednesday 13 October	12:30	14:00	Membership Development Committee	Club H
Wednesday 13 October	15:00	16:00	Exhibitors' Closing Meeting	Club H
Wednesday 13 October	17:40	18:40	IOTA Group	Meeting Hall II
Thursday 14 October	09:00	10:00	ISUOG Board (supplementary)	Club H
Thursday 14 October	10:30	11:30	IETA Group	Club H

Committee meetings are for committee members by invitation; if you are interested in joining one of the committees listed, please visit the ISUOG stand to register your interest.

# General information

## Cash machines

Czech banks are normally open 09:00–12:00 and 13:00–16:00 each weekday and Saturday. There is a branch of the Commercial Bank at the Prague Congress Centre which has cash machine facilities.

## Catering

Coffee and light lunches will be served in the exhibition area Sunday to Thursday. On Thursday, refreshments will be served in the level 1 foyer and buffet bar. Please join us farewell drinks and a Czech beer at the closing ceremony on Thursday afternoon!

## Certificates of attendance

Certificates of attendance will be available from the registration desk from Wednesday 13 October for all registered delegates who complete the CME questionnaire.

## Congress contact details

### Guarant

#### (registration and social enquiries)

Guarant International  
Opletalova 22  
110 00, Prague 1  
Czech Republic

Tel: +420 284 001 444  
Fax: +420 284 001 448  
Email: [isuog2010@guarant.cz](mailto:isuog2010@guarant.cz)

### ISUOG Secretariat

#### (scientific program, exhibition and sponsorship)

ISUOG  
Unit 4 Blythe Mews  
Blythe Road  
London W14 0HW  
United Kingdom

Tel: +44 (0) 20 7471 9955  
Fax: +44 (0) 20 7471 9959  
Email: [congress@isuog.org](mailto:congress@isuog.org)  
Website: [www.isuog.org](http://www.isuog.org)

## Disclaimer

All best endeavours will be made to present the program as printed. However ISUOG and its agents reserve the right to alter or cancel without prior notice, any of the arrangements, timetables, plans or other items relating directly or indirectly to the Congress for any reason beyond its reasonable control. ISUOG and its agents are not liable for any loss or inconvenience caused as a result of such alteration.

## Duplications/recordings

Photography, audio taping, video recording, digital taping or any other form of duplication is strictly prohibited in the session halls and poster areas, **except** with the express consent, in advance, of ISUOG and the speakers involved. Please note that all sessions are available to delegates after the Congress, through the member's web portal.

## First aid

Should you require assistance during the Congress hours, please contact the registration desk.

## Future meetings

Literature regarding future meetings of interest to participants is displayed in the exhibition area.

## ISUOG membership

All paid delegates are members of ISUOG for 2011, including subscriptions to UOG and access to the new Congress web portal. Visit the ISUOG lounge in the exhibition area for more information.

## Lost property

Please hand any lost property to the staff at the registration desk where it will be made available for collection. At the end of the Congress, any unclaimed items will be taken back to London by ISUOG. Any ticketed items left in the onsite cloakroom will be retained by the venue for one month after the event.

## Name badges

Please wear your name badge at all times, you will need this to gain admission to the sessions or exhibition area. Please note, our staff are instructed not to permit entry without your badge, so please be understanding if you are asked to return to the registration desk. Name badge holders have been colour coded as follows:

Full delegates	Clear
Board	Red
Invited faculty	Blue
Exhibitors	Yellow
Accompanying persons	Green
Staff	Deep red

#### Day delegates:

Sunday	Light blue ( <i>pre-Congress courses only</i> )
Sunday	Light green
Monday	Orange
Tuesday	Purple
Wednesday	Pink
Thursday	Clear

## Official language

The official language of the Congress is English. No translation facilities are available.

## Smoking policy

Smoking is not permitted in the building.

## Telephones

Mobile telephones work well within the venue and there is a coin-operated telephone on the ground floor of the venue.

## Travel

The Prague Congress Centre is situated right outside the metro stop Vyšehrad, on the red line. Please note that you need a valid ticket to enter the metro system, and could be fined if you enter without validating your ticket in the machines as you enter the metro. From the Vyšehrad stop, it is only two stops (approximately 10 minutes) to the town centre (alight at Muzeum on the red line). From here you can easily walk to the historic centre and river. **You can buy individual tickets per journey, for timed periods or an 'All Day' ticket, which offers unlimited travel. This costs approximately €4. There are also three-day (€14) or five-day (€21) tickets, which are valid for unlimited travel by one person on the metro system. Tickets can be purchased from automated ticket machines at the stations.**

ISUOG would like to thank the following industry partners  
for their support of the 20th World Congress:

**Diamond level**



GE imagination at work

**Platinum level**



**PHILIPS**  
sense and simplicity

**SIEMENS**

**Silver level**

**TOSHIBA**  
Leading Innovation >>>

**Bronze level**

**ALOKA**  
illuminate the change

20th World Congress on Ultrasound  
in Obstetrics and Gynecology



**Congress Secretariat**  
ISUOG\_CCL, c/o ISUOG  
Unit 4, Blythe Mews  
Blythe Road  
London W14 0HW, UK  
Tel: +44 (0) 20 7471 9955  
Fax: +44 (0) 20 7471 9959  
Email: [congress@isuog.org](mailto:congress@isuog.org)  
Website: [www.isuog.org](http://www.isuog.org)

**Accommodation and Registration  
Management**  
Guarant International  
Opletalova street 22  
110 00  
Prague 1  
Tel: +420 284 001 444  
Email: [isuog2010@guarant.cz](mailto:isuog2010@guarant.cz)

