

Cerebral biometry in fetal magnetic resonance imaging: new reference data

B. TILEA*†, C. ALBERTI‡§, C. ADAMSBAUM¶**, P. ARMOOGUM‡§, J. F. OURY†°, D. CABROL**#, G. SEBAG*†, G. KALIFA¶** and C. GAREL^{^*}

*AP-HP, Hôpital Robert Debré, Service d'Imagerie Pédiatrique, °AP-HP, Hôpital Robert Debré, Service de Gynécologie Obstétrique - Centre de Diagnostic Prénatal, ‡AP-HP, Hôpital Robert Debré, Unité d'Epidémiologie Clinique, ¶AP-HP, Hôpital Saint-Vincent-de-Paul, Service de Radiologie Pédiatrique, #AP-HP, Hôpital Saint-Vincent-de-Paul, Centre de Diagnostic Prénatal - Maternité de Port-Royal, [^]AP-HP, Hôpital d'Enfants Armand-Trousseau, Service de Radiologie Pédiatrique, †Université Paris VII Denis Diderot, §Inserm, CIE5 and **Université Paris V René Descartes, Paris, France

KEYWORDS: biometry; brain; charts; fetal biometry; fetus; magnetic resonance; MRI

ABSTRACT

Objectives To provide normal magnetic resonance imaging (MRI) reference biometric data of the fetal brain, to evaluate reproducibility and gender effect, to compare the two cerebral hemispheres and to compare MRI with ultrasonographic biometry, in a large cohort.

Methods Normal cerebral fetal MRI examinations were collected prospectively and several parameters were measured: the supratentorial space (bone and cerebral fronto-occipital and biparietal (BPD) diameters), the length of the corpus callosum (LCC), the surface area, height and anteroposterior diameter of the vermis, the transverse cerebellar diameter (TCD) and the anteroposterior diameter of the pons. We evaluated the interobserver reproducibility of measurements and the possible gender effect on measurements of bone BPD, TCD and LCC. We compared right and left hemispheres, right and left atria and ultrasound and MRI measurements.

Results The study included 589 fetuses, ranging from 26 to 40 weeks. Normal values (from 3rd to 97th percentile) are provided for each parameter. Interobserver agreement was excellent, with an intraclass correlation coefficient (ICC) > 0.75 for many parameters. The gender effect was evaluated in 372 cases and did not reveal any clinically meaningful difference. Comparison between the right and left cerebral hemispheres and between the right and left atria did not reveal any meaningful differences. Ultrasound and MRI measurements of BPD and TCD were compared in 94 cases and 48 cases, respectively, and the agreement was excellent (ICC = 0.85).

Conclusions We present new reproducible reference charts for cerebral MRI biometry at 26–40 weeks'

gestation, from a large cohort of fetuses. Copyright © 2009 ISUOG. Published by John Wiley & Sons, Ltd.

INTRODUCTION

Over the past 20 years, magnetic resonance imaging (MRI) has gained considerable importance in the evaluation of the fetal brain. Assessment of fetal biometry is of paramount importance in prenatal diagnosis and it is one way of reassuring that the brain has developed well. As ultrasound is a screening modality and is performed daily on very large populations of pregnant women, it has been possible to establish biometric standard reference data in very large cohorts of fetuses. MRI, in contrast, is a complementary tool and is usually performed following detection of abnormalities with ultrasound. Therefore, it is more difficult to determine normal biometric data for MRI and there are very few series reported in the literature^{1–4}; the largest published series includes 225 fetuses⁴.

The aims of this study were: to provide normal MRI reference biometric data of the fetal brain in a large cohort; to add the new parameter of biometry of the brain stem and to evaluate the size of the anterior and posterior pericerebral spaces; to evaluate the reproducibility of MRI biometry; to evaluate the effect of gender on cerebral biometry; to compare the biometry of the two cerebral hemispheres; and finally, to compare certain parameters measured with ultrasound and with MRI.

METHODS

We performed a systematic review of all cerebral fetal MRI examinations collected prospectively during the last

Correspondence to: Dr C. Garel, Service de Radiologie Pédiatrique, Hôpital d'Enfants Armand-Trousseau 26–28, Avenue du Docteur Arnold-Netter, 75012 Paris, France (e-mail: catherine.garel@trs.aphp.fr)

Accepted: 14 October 2008

7 years in the MRI database of two hospitals located in Paris, France (Robert Debré and Saint-Vincent-de-Paul hospitals). Inclusion criteria were: slices orthogonal to the fetal brain stem in the three planes of space and acquired with T2-weighted sequences; at least one plane acquired with T1-weighted sequences; absence of movement artifacts which would render the measurements inaccurate (measurements were obtained on T2-weighted coronal and sagittal slices so that patients with artifactual axial slices could be included); absence of intracranial abnormalities (extracranial abnormalities could be present); gestational age from 26 to 40 weeks, established according to first-trimester ultrasound examination; singleton pregnancy. The MRI examinations had been performed because of increased risk of cerebral pathology (including suspicion of infectious fetopathy, suspicion of cerebral abnormality on ultrasound, positive family history, club foot, cleft lip and/or palate, cerebral biometry at the lower limit of the norm on ultrasound, polyhydramnios, maternal disease (with possible consequences for fetal cerebral development) and decreased fetal movements).

Procedure

In one hospital (Hôpital Robert Debré), MRI was performed on a 1.5-Tesla unit (Intera Philips Medical Systems, Best, The Netherlands), 30–40 min after fetal sedation by maternal oral administration of flunitrazepam (1 mg). The fetal brain was examined using a phased-array abdominal coil, T1-weighted spin echo (SE), spectral presaturation inversion recovery (SPIR), fat-saturated sequences (697/14/2; flip angle, 90°; matrix, 256 × 256; field of view, 320 mm; rectangular field of view, 75%; section thickness, 4 mm; acquisition time, 2 min 56 s) and T2-weighted single-shot turbo SE sequences (24617/100/1; flip angle, 90°; turbo SE factor, 84; matrix, 256 × 256; field of view, 280 cm; section thickness, 3 mm; acquisition time, 24 s).

In the other hospital (Hôpital Saint-Vincent-de-Paul), MRI was performed on two different 1.5-Tesla units (Signa, GE Healthcare Technologies, Milwaukee, WI, USA and Avento Siemens, Erlangen, Germany), without fetal sedation. The fetal brain was examined using a phased-array abdominal coil. Sagittal, axial and frontal slices were acquired with half Fourier T2 fast gradient echo (FGRE) with inversion and with T1 FGRE with inversion. The GE parameters for single shot fast spin echo (SSFSE) sequences were: repetition time (TR), minimal; time to echo (TE), 240; field of view, 400 mm; section thickness/gap, 4 mm/0.4; matrix, 320 × 256; and for FGRE sequences they were: TE, minimal preparation time, 2500; flip angle, 40; field of view, 480 mm; section thickness/gap, 5 mm/1; matrix, 256 × 160. The Siemens parameters for half fourier acquisition single shot turbo spin echo (HASTE) sequences were: TR, 1860; TE, 116; section thickness/gap, 4mm/0.4; field of view, 300 mm; matrix, 384 × 250; and for T1 inversion recovery (T1 IR) sequences they were: TR, 4190; time for inversion (TI),

2500; TE, 5.2; section thickness/gap, 4 mm/0.4; field of view, 380; matrix, 320 × 255.

The biometric parameters that were measured included all those already reported in our previous study^{1,4}: cerebral fronto-occipital diameter (FOD), cerebral and bone biparietal diameters (BPD), length of the corpus callosum (LCC), transverse diameter of the cerebellum, height, anteroposterior diameter and surface area of the vermis and the right and left atrial diameters. The methodology used to acquire these measurements has already been detailed^{1,4}. The same radiologist (B.T.) performed all MRI measurements. The size of the brain was determined from the fetus's position in the uterus. To this list we added the following new parameters: bone FOD, measured on the midline sagittal slice as the distance between the internal tables of the frontal and the occipital bones (Figure 1a); right and left cerebral BPDs, measured on the same slice as the cerebral BPD, being the largest diameter of one cerebral hemisphere, from its lateral aspect to the internal aspect of the parietal lobe (Figure 1b); anteroposterior diameter of the brain stem, measured at the mid-height of the pons, on the midline sagittal slice, as the distance between the anterior and posterior aspects of the pons, perpendicular to the axis of the brain stem (Figure 1c); biparietal index, the ratio of the difference between bone and cerebral BPDs and bone BPD, evaluating the size of the lateral pericerebral space; fronto-occipital index, the ratio of the difference between bone and cerebral FODs and bone FOD, evaluating the size of the anterior and posterior pericerebral spaces; atrial index, the ratio of atrial diameter to ipsilateral BPD.

The reproducibility of measurements was evaluated by two radiologists (B.T. and C.G.) in a sample of 50 fetuses, chosen arbitrarily. Each radiologist was unaware of the results obtained by the other. For comparison between the two cerebral hemispheres and between ultrasound and MRI measurements, we compared measurements of right and left cerebral BPDs, right and left atrial diameters and right and left atrial indices. When ultrasound examination was performed within 7 days of MRI, sonographic and MRI measurements of bone BPD and transverse cerebellar diameter (TCD) were compared. We excluded all cases with ultrasound examination performed more than 7 days before or after MRI. Any possible gender effect was evaluated on measurements of bone BPD, TCD and LCC. Finally, postnatal clinical findings were evaluated by reviewing the patients' medical notes and in particular noting the head circumference and the results of a full clinical examination.

Statistical analysis

Quantitative variables are described as median (range) and qualitative variables as frequency (percentage). Estimates of intraclass correlation coefficients (ICCs) and Bland–Altman plots were used to explore agreement between the two radiologists, between the two cerebral hemispheres and between ultrasound and MRI

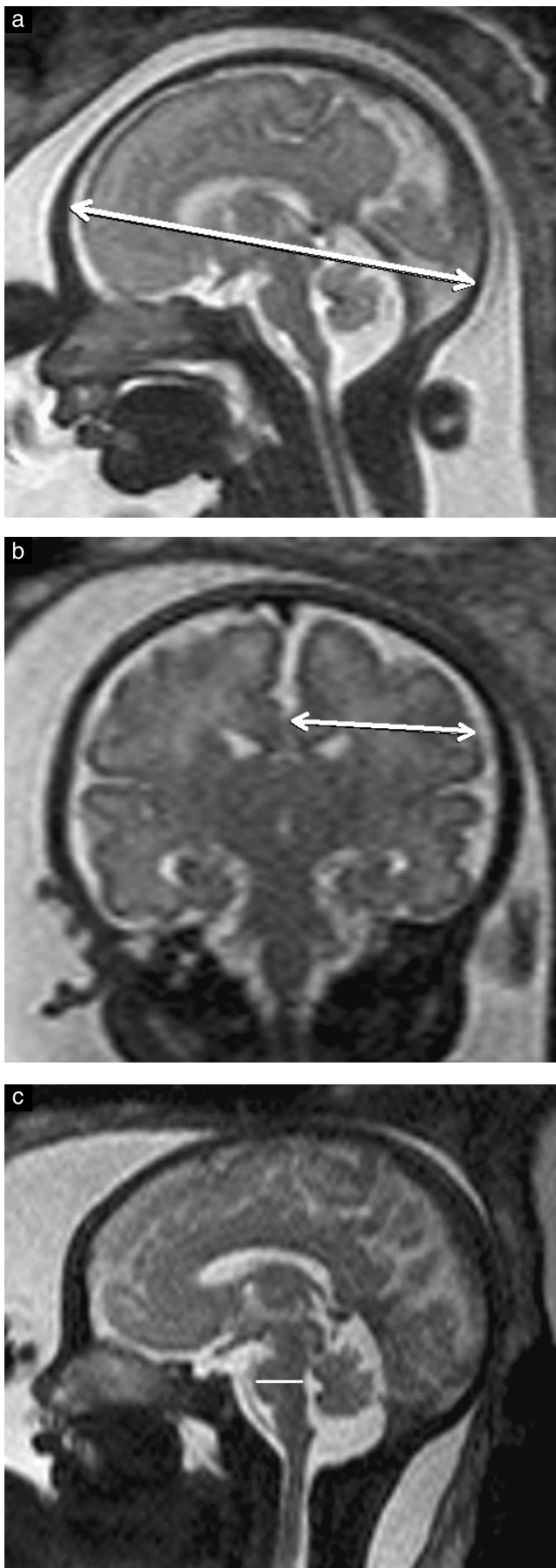


Figure 1 Midline sagittal T2-weighted magnetic resonance imaging slice, showing measurement of: bone fronto-occipital diameter (a); left cerebral biparietal diameter (b); and anteroposterior diameter of the pons (c).

measurements. Agreement was considered slight when $ICC \leq 0.2$, fair when $0.2 < ICC \leq 0.4$, moderate when $0.4 < ICC \leq 0.6$, substantial when $0.6 < ICC \leq 0.8$ and almost perfect (excellent) when $ICC > 0.8$.

Age-specific reference intervals for biometric parameters were estimated using the simplified parametric method described by Wright and Royston⁵. Briefly, a centile curve is estimated using the formula: $C_p = \mu_t + q_p \sigma_t$, where q_p is the corresponding centile of the standard Gaussian distribution, t is gestational age measured in days (based on first-trimester biometric ultrasound measurements) and μ_t and σ_t indicate the corresponding values of mean and SD for each curve at age t . Initial natural logarithmic transformation is applied if required to reduce positive skewness and heteroscedasticity of the measurement of interest. A fractional polynomial of degree m is then fitted by least squares regression of the measurement of interest against age to create a suitable function for μ_t with the powers as numbers chosen from the set $\{-2, -1, -0.5, 0, 0.5, 1, 2, 3\}$. An appropriate fractional polynomial is selected by comparing the difference in deviance between models having degrees m and $m + 1$ using a χ^2 variate on 2 degrees of freedom. Sometimes, several models may fit approximately equally well, in which case the final choice is based on non-statistical grounds. The fitted values from the regression give the estimated mean curve and the 'scaled absolute residuals', σ_t . If the scaled absolute residuals appear to show no trend with age, the SD is estimated as that of the residual of the measurement of interest from the regression on age, otherwise polynomial regression analysis is performed to estimate an appropriate curve in the same way as for the mean. The model fit is assessed by calculating the standard deviation scores (Z-score) as $Z = \frac{\text{measurement} - \mu_t}{\sigma_t}$. The ordered Z-scores are plotted in order to provide a graphical check of normality. If normality is accepted, no further modeling is required. Goodness-of-fit methods employed were Q-tests exploring the moments of the Z-scores and permutation bands, which are a graphical way of examining adequacy of the models⁶. Centile curves for the desired reference interval are calculated by substituting the fitted curves of the mean and SD into the equation of C_p . When the variable being modeled is log-transformed, centile curves on the original scale are obtained by applying antilogs to the calculated curves. Influence of fetal gender was explored by adding the variable in the reference interval model.

RESULTS

General characteristics

There were 589 fetuses included in this study. The distribution of the number of fetuses as a function of gestational age is represented as a histogram in Figure 2. Gender was known in 372 cases (206 males and 166

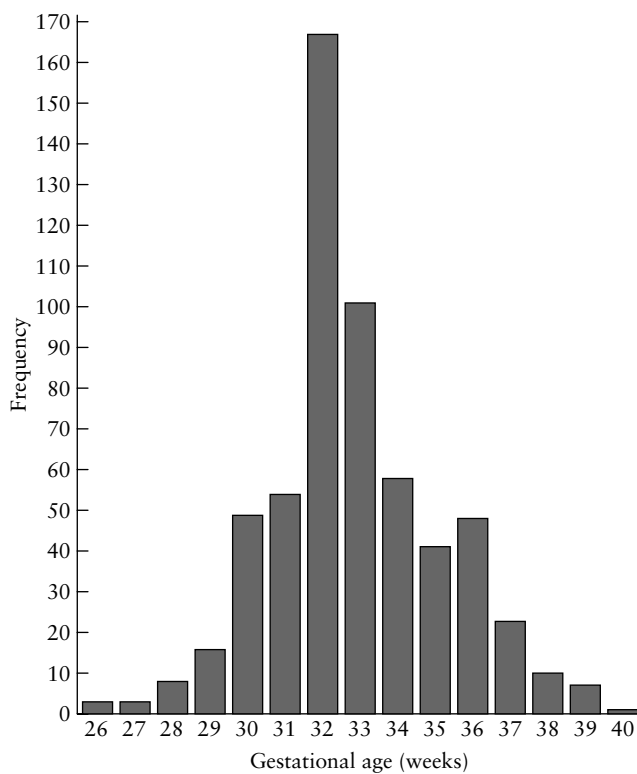


Figure 2 Distribution of numbers of fetuses providing data for the MRI reference values as a function of gestational age ($n = 589$).

females) and it was unknown in 217 cases, so the effect of gender on biometry was studied in 372 cases.

Ultrasound findings could be collected in 333 cases, but ultrasound examination was performed within 7 days before or after MRI in only 98 cases, so agreement between ultrasound and MRI biometry was evaluated in 98 cases. BPD and TCD were measured in 94 cases and 48 cases, respectively.

In five cases, the pregnancy was terminated for extracerebral reasons and no cerebral abnormality was observed at fetopathological examination. In the remaining cases, the pregnancy was continued until delivery, but many children were lost to follow-up. In retrospect, we found 82 children with clinical examination data collected during the first 5 years following delivery. We also found retrospectively that transfontanelar ultrasound was performed after delivery in 65 cases and postnatal cerebral MRI was performed in 20 cases. In all of these cases, all clinical and/or imaging examinations were normal.

Agreement (Table 1, Bland–Altman plots in Appendices S1 and S2 online)

Agreement between the two radiologists was excellent for bone FOD and BPD, cerebral FOD and BPD, TCD and vermian surface area (VS); it was substantial for APDP, left and right cerebral BPDs, LCC, APDV, vermian height (VH) and right atrial diameter; and it was moderate for index parameters and left atrial diameter (Table 1). The limits of agreement were considered acceptable for clinical purposes for all parameters with excellent or substantial

Table 1 Agreement of fetal cerebral biometric MRI parameters

Agreement/Parameter	Mean bias (SD)	95% LOA	ICC (95% CI)
Interobserver agreement			
Bone FOD (mm)*	-0.8 (1.8)	(-4.3; 2.7)	0.97 (0.94–0.98)
Bone BPD (mm)*	-0.4 (1.8)	(-3.9; 3.1)	0.97 (0.95–0.98)
Cerebral BPD (mm)*	0.8 (1.5)	(-2.1; 3.7)	0.95 (0.91–0.97)
Cerebral FOD (mm)*	1.2 (2.2)	(-3.1; 5.5)	0.94 (0.91–0.97)
TCD (mm)*	1.2 (1.3)	(-1.3; 3.7)	0.93 (0.88–0.96)
VS (mm ²)*	5.2 (16.6)	(-27.2; 37.7)	0.87 (0.79–0.93)
APDP (mm)*	0.2 (0.7)	(-1.2; 1.6)	0.80 (0.68–0.88)
Left cerebral BPD (mm)	-0.9 (2.4)	(-5.6; 3.8)	0.78 (0.65–0.87)
LCC (mm)*	1.1 (2.1)	(-3.0; 5.2)	0.75 (0.59–0.85)
Right cerebral BPD (mm)	-1.7 (2.5)	(-6.6; 3.2)	0.71 (0.55–0.83)
APDV (mm)*	0.1 (0.9)	(-1.5; 1.8)	0.70 (0.53–0.82)
VH (mm)*	1.1 (1.0)	(-0.8; 3.0)	0.67 (0.49–0.80)
Right AD (mm)	0.1 (1.2)	(-2.3; 2.5)	0.66 (0.46–0.79)
Fronto-occipital index†	-2.0 (2.2)	(-6.3; 2.3)	0.51 (0.28–0.70)
Left AD (mm)	0.9 (1.1)	(-1.3; 3.1)	0.47 (0.22–0.66)
Biparietal index‡	-1.4 (2.7)	(-6.7; 3.9)	0.42 (0.16–0.63)
Agreement of ultrasound and MRI measurements			
BPD/Bone BPD	1.4 (4.4)	(-7.2; 10.0)	0.85 (0.78–0.89)
TCD/TCD	-0.7 (3.0)	(-6.6; 5.2)	0.85 (0.76–0.90)
Agreement of right and left measurements			
Cerebral BPD (mm)	0.2 (2.5)	(-4.7; 5.1)	0.77 (0.73–0.80)
AD (mm)	-0.2 (1.5)	(-3.1; 2.7)	0.43 (0.36–0.49)

*Reference intervals were estimated for these parameters. †Ratio of difference between bone and cerebral fronto-occipital diameters (FODs) and bone FOD, evaluating size of anterior and posterior pericerebral spaces. ‡Ratio of difference between bone and cerebral biparietal diameters (BPDs) and bone BPD, evaluating size of lateral pericerebral space. AD, atrial diameter; APDP, anteroposterior diameter of the pons; APDV, anteroposterior diameter of the vermis; ICC, intraclass correlation coefficient; LOA, limits of agreement; LCC, length of the corpus callosum; MRI, magnetic resonance imaging; TCD, transverse cerebellar diameter; VH, vermian height; VS, vermian surface area.

agreement defined by ICC (Table 1). Therefore, reference interval modeling was restricted to the 10 parameters indicated with a * symbol in Table 1. The Bland–Altman plots (Appendix S1 online) showed no particular pattern. Agreement between ultrasound and MRI findings was excellent (Table 1 and Appendix S2 online). Comparison between the left and right cerebral hemispheres showed

good agreement for cerebral BPD but was poor for atrial diameter and atrial diameter/BPD ratio (Table 1 and Appendix S2 online).

Reference intervals

Figure 3 displays reference interval curves for the 10 chosen parameters, with values for particular percentiles

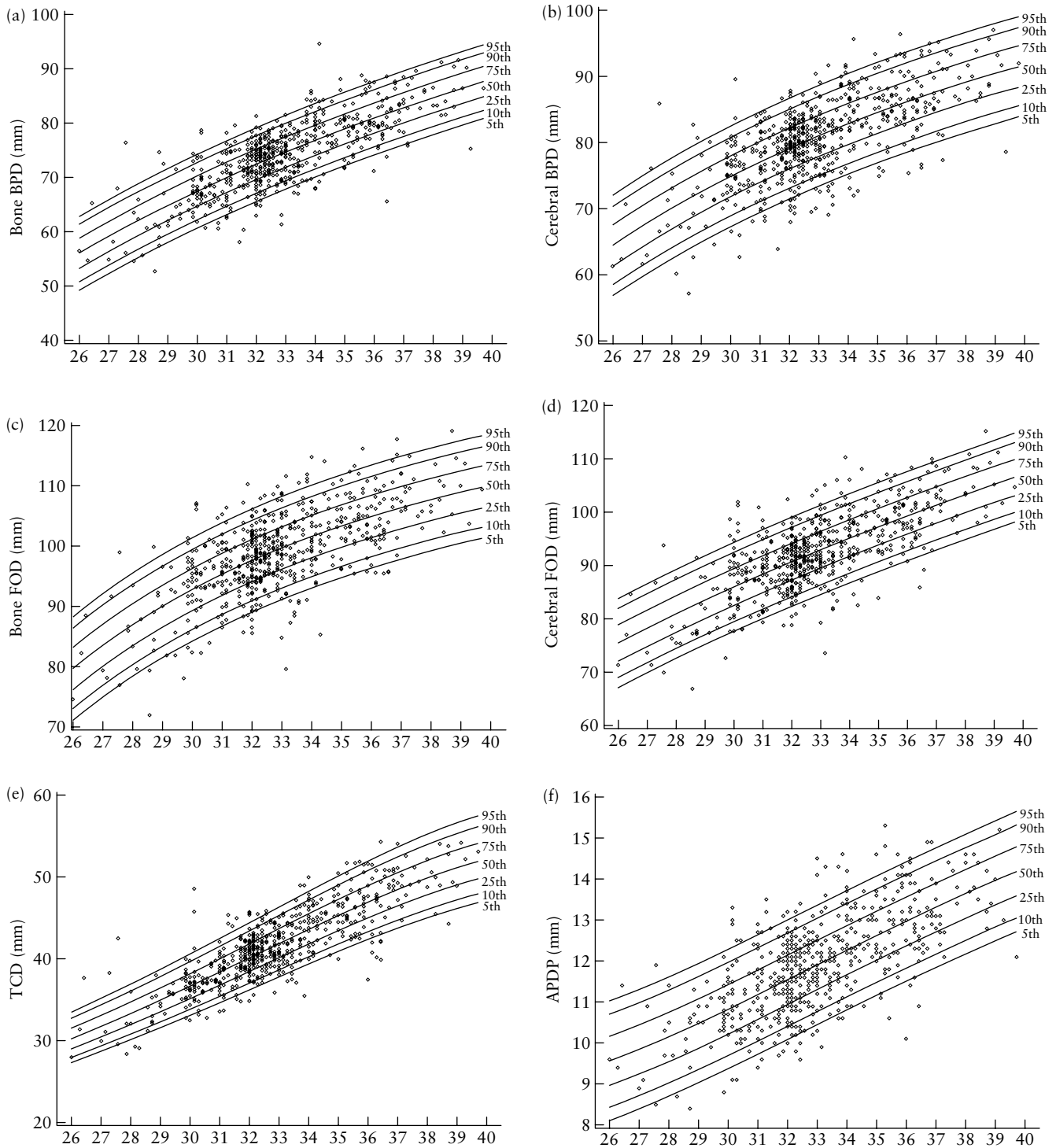


Figure 3 Reference intervals (5th, 10th, 25th, 50th, 75th, 90th and 95th centiles) for the 10 chosen fetal cerebral magnetic resonance imaging parameters. (a) Bone biparietal diameter (BPD); (b) cerebral BPD; (c) bone fronto-occipital diameter (FOD); (d) cerebral FOD; (e) transverse cerebellar diameter (TCD); (f) anteroposterior diameter of the pons (APDP); (g) vermian surface area (VS); (h) vermian height (VH); (i) length of the corpus callosum (LCC); (j) anteroposterior diameter of the vermis (APDV).

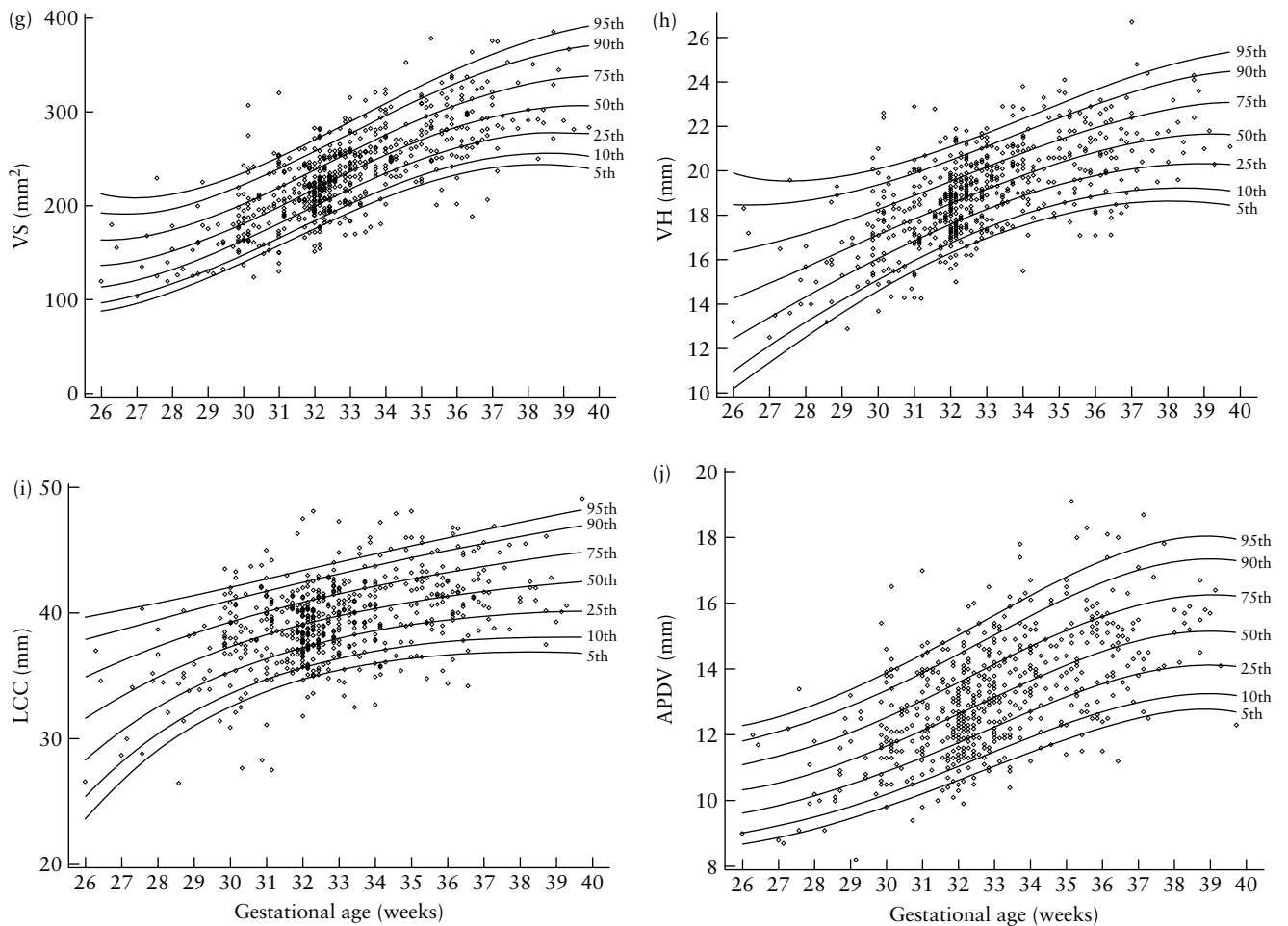


Figure 3 (Continued).

at different gestational ages given in Tables S1–S10 online. Formulae allowing estimation of Z-scores are given in Appendix S3 and a graphical check of normality is in Appendix S4 online.

Gender effect

There was a statistically significant gender effect for bone BPD, TCD and LCC (Figure 4), but the effect was so small it was not considered clinically meaningful: after adjusting for gestational age, the mean difference between males and females was 0.64 mm for LCC, -0.65 mm for TCD and -1.22 mm for bone BPD.

DISCUSSION

This study provides cerebral biometric data from a large cohort of fetuses ($n = 589$), from 26 to 40 gestational weeks, using a method recommended by the World Health Organization⁷ and allowing 5th and 95th percentile estimations. Our modeled curves were in accordance with clinical assumptions, even though for some of them (VS and VH) we observed a decrease in precision of the percentile estimates at extreme gestational ages. This was probably due to the small

number of observations and greater variability at these extremes.

So far, very few such series have been reported in the literature and it has proved difficult to collect data on large cohorts; volumetric measurements of the brain have also been reported only in very small series^{8,9}. Yet, biometric analysis is an important stage in the evaluation of the fetal brain for prenatal diagnosis. In contrast to ultrasound, MRI makes it possible to acquire true cerebral measurements rather than measurements of the skull vault. For example, in cases with abnormal BPD measured on ultrasound, MRI makes it possible to differentiate between true micrencephaly with enlarged pericerebral spaces and abnormal cerebral measurements with thin pericerebral spaces.

With this study, we added to the measurements of our first study^{1,4} a new parameter, the anteroposterior diameter of the pons. Other studies have determined the volume of the fetal posterior fossa as a function of gestational age¹⁰, or performed segmentation analysis of the structures of the posterior fossa¹¹. Evaluation of the pontine bulge is also important in the analysis of the posterior fossa^{12,13}. Nomograms of the anteroposterior diameter of the fetal pons have been provided

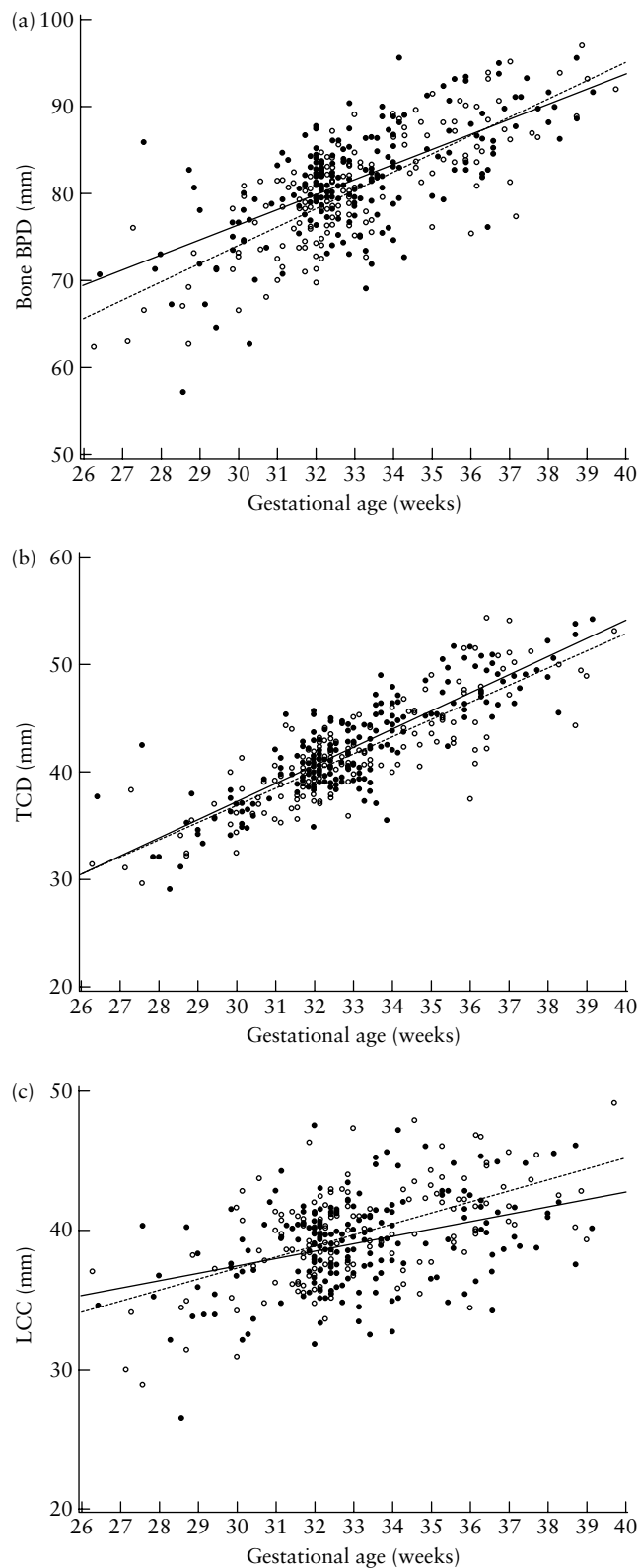


Figure 4 Investigation of gender effect for: (a) bone biparietal diameter (BPD), (b) transverse cerebellar diameter (TCD) and (c) length of the corpus callosum (LCC). Males, \bullet ; females, \circ .

for ultrasound examination, using the transfontanellar approach¹⁴. The brain stem can be depicted beautifully by MRI, independently of fetal position and maternal habitus, but so far, no MRI data for this parameter have

been available. Our norms are in good agreement with ultrasound data¹⁴.

The significance of increased or decreased pericerebral spaces is not well known in fetuses. There is a progressive decrease of this parameter throughout pregnancy⁴. With this study we have added another new parameter, the bone FOD, which makes it possible to calculate the fronto-occipital index and, therefore, to evaluate the anterior and posterior pericerebral spaces. The lateral component has been measured previously by means of the biparietal index.

Interobserver variability is not usually evaluated in articles providing new reference data for fetal head measurement^{15–17}. Our study showed high reproducibility, with a reproducibility index ranging from 0.42 to 0.97 (> 0.70 for most parameters). It must be stressed that the agreement between the two radiologists was lowest for fronto-occipital and biparietal indices. Therefore, in routine practice, evaluation of the pericerebral spaces is not reliable.

Another purpose of our study was to evaluate gender effect on cerebral biometry. However, it must be stressed that this study was conducted in a mixed population with different socioeconomic and even different geographic origin characteristics, which may also influence cerebral biometry. Some studies have reported a gender effect on fetal head growth and BPD was found significantly larger in males^{18–20}. Our findings regarding gender effect on bone BPD are in agreement with these data, but this effect is so small it cannot be considered clinically meaningful in common practice. Furthermore, it should be noted that we did not find any gender effect on cerebral BPD. According to Achiron *et al.*²¹, the LCC was not significantly different between males and females. We observed a slight gender difference, with a trend towards the LCC being larger in females from 31 weeks onwards. In agreement with previous studies²², we observed that the atrial diameter was slightly larger in males than in females. However, for these parameters also, the difference is not clinically meaningful.

Statistical analysis did not reveal any significant difference between right and left BPDs. Development of the central nervous system is influenced by genetic and environmental factors. Language and other cognitive functions are organized along the left–right axis, generating development of cerebral asymmetry. The latter is strongly correlated with handedness²³. Snijders *et al.*²⁴ suggested measuring each hemisphere separately but did not compare measurements of left and right hemispheres. In a study conducted between 20 and 22 weeks, Achiron *et al.*²⁵ obtained hemispheric ultrasound measurements from an axial section of the fetal head and found a mean difference between hemispheres of < 1.7 mm, the left hemisphere being slightly larger than the right one, with no gender-related difference. There is some degree of asymmetry of the lateral ventricles, which can be detected on ultrasound²⁵, but predominance of one ventricle over the other has not been reported. This is in agreement

with our results; statistical analysis could not find any significant difference between right and left ventricular measurements.

We have already reported good agreement between fetal ultrasound and MRI in the measurement of atrial diameter on a coronal slice²⁶. In the present study, we found good agreement between modalities in the measurement of bone BPD and TCD. These results confirm findings of Reichel *et al.*² in a series of 22 fetuses without cerebral abnormalities.

One weakness of this study was the large number of children lost to follow-up after delivery and, therefore, the impossibility of ascertaining brain normality even in cases in which there were no abnormalities detected during pregnancy, either with ultrasound or with MRI. However, it is interesting to note that most studies designed to assess charts of fetal size with ultrasound do not take into account follow-up after birth^{15–17,27}, some emphasize the necessity of collecting clinical data during pregnancy and until birth^{27,28}, while others do not even mention this issue¹⁷.

In conclusion, our study provides normal biometric MRI data of the fetal brain from a large cohort of fetuses, from 26 to 40 gestational weeks. Statistical analysis revealed high interobserver reproducibility of measurements, a clinically insignificant gender effect, good agreement between measurements of right and left hemispheres, right and left atria, and ultrasound and MRI measurements of BPD and TCD.

ACKNOWLEDGMENT

This study was funded by grant AOR 05 048 from the Hospital Clinical Research Program (Ministry of Health).

REFERENCES

- Garel C. Fetal cerebral biometry: normal parenchymal findings and ventricular size. *Eur Radiol* 2005; 15: 809–813.
- Reichel TF, Ramus RM, Caire JT, Hynan LS, Magee KP, Twickler DM. Fetal central nervous system biometry on MR imaging. *AJR Am J Roentgenol* 2003; 180: 1155–1158.
- Twickler DM, Reichel T, McIntire DD, Magee KP, Ramus RM. Fetal central nervous system ventricle and cisterna magna measurements by magnetic resonance imaging. *Am J Obstet Gynecol* 2002; 187: 927–931.
- Garel C. Development of the fetal brain. In *MRI of the Fetal Brain*, Garel C (ed). Springer: Berlin, 2004; 11–130.
- Wright EM, Royston P. Simplified estimation of age-specific reference intervals for skewed data. *Stat Med* 1997; 16: 2785–2803.
- Royston P, Wright EM. Goodness-of-fit statistics for age-specific reference intervals. *Stat Med* 2000; 19: 2943–2962.
- Borghi E, de Onis M, Garza C, Van den Broeck J, Frongillo EA, Grummer-Strawn L, Van Buuren S, Pan H, Molinari L, Martorell R, Onyango AW, Martines JC. Construction of the World Health Organization child growth standards: selection of methods for attained growth curves. *Stat Med* 2006; 25: 247–265.
- Gong QY, Roberts N, Garden AS, Whitehouse GH. Fetal and fetal brain volume estimation in the third trimester of human pregnancy using gradient echo MR imaging. *Magn Reson Imaging* 1998; 16: 235–240.
- Grossman R, Hoffman C, Mardor Y, Biegon A. Quantitative MRI measurements of human fetal brain development in utero. *Neuroimage* 2006; 33: 463–470.
- Chen SC, Simon EM, Haselgrove JC, Bilaniuk LT, Sutton LN, Johnson MP, Shera DM, Zimmerman RA. Fetal posterior fossa volume: assessment with MR imaging. *Radiology* 2006; 238: 997–1003.
- Claude I, Daire JL, Sebag G. Fetal brain MRI: segmentation and biometric analysis of the posterior fossa. *IEEE Trans Biomed Eng* 2004; 51: 617–626.
- Adamsbaum C, Moutard ML, Andre C, Merzoug V, Ferey S, Quere MP, Lewin F, Fallet-Bianco C. MRI of the fetal posterior fossa. *Pediatr Radiol* 2005; 35: 124–140.
- Guibaud L. Practical approach to prenatal posterior fossa abnormalities using MRI. *Pediatr Radiol* 2004; 34: 700–711.
- Achiron R, Kivilevitch Z, Lipitz S, Gamzu R, Almog B, Zalel Y. Development of the human fetal pons: in utero ultrasonographic study. *Ultrasound Obstet Gynecol* 2004; 24: 506–510.
- Chitty LS, Altman DG, Henderson A, Campbell S. Charts of fetal size: 2. Head measurements. *Br J Obstet Gynaecol* 1994; 101: 35–43.
- Kurmanavicius J, Wright EM, Royston P, Wisser J, Huch R, Huch A, Zimmermann R. Fetal ultrasound biometry: 1. Head reference values. *Br J Obstet Gynaecol* 1999; 106: 126–135.
- Salomon LJ, Duyme M, Crequat J, Brodaty G, Talmant C, Fries N, Althuser M. French fetal biometry: reference equations and comparison with other charts. *Ultrasound Obstet Gynecol* 2006; 28: 193–198.
- Davis RO, Cutter GR, Goldenberg RL, Hoffman HJ, Cliver SP, Brumfield CG. Fetal biparietal diameter, head circumference, abdominal circumference and femur length. A comparison by race and sex. *J Reprod Med* 1993; 38: 201–206.
- Moore WM, Ward BS, Jones VP, Bamford FN. Sex difference in fetal head growth. *Br J Obstet Gynaecol* 1988; 95: 238–242.
- Schwarzler P, Bland JM, Holden D, Campbell S, Ville Y. Sex-specific antenatal reference growth charts for uncomplicated singleton pregnancies at 15–40 weeks of gestation. *Ultrasound Obstet Gynecol* 2004; 23: 23–29.
- Achiron R, Lipitz S, Achiron A. Sex-related differences in the development of the human fetal corpus callosum: in utero ultrasonographic study. *Prenat Diagn* 2001; 21: 116–120.
- Kramer RL, Yaron Y, Johnson MP, Evans MI, Treadwell MC, Wolfe HM. Differences in measurements of the atria of the lateral ventricle: does gender matter? *Fetal Diagn Ther* 1997; 12: 304–305.
- Geschwind DH, Miller BL, DeCarli C, Carmelli D. Heritability of lobar brain volumes in twins supports genetic models of cerebral laterality and handedness. *Proc Natl Acad Sci USA* 2002; 99: 3176–3181.
- Snijders RJ, Nicolaides KH. Fetal biometry at 14–40 weeks' gestation. *Ultrasound Obstet Gynecol* 1994; 4: 34–48.
- Achiron R, Yagel S, Rotstein Z, Inbar O, Mashiach S, Lipitz S. Cerebral lateral ventricular asymmetry: is this a normal ultrasonographic finding in the fetal brain? *Obstet Gynecol* 1997; 89: 233–237.
- Garel C, Alberti C. Coronal measurement of the fetal lateral ventricles: comparison between ultrasonography and magnetic resonance imaging. *Ultrasound Obstet Gynecol* 2006; 27: 23–27.
- Altman DG, Chitty LS. Charts of fetal size: 1. Methodology. *Br J Obstet Gynaecol* 1994; 101: 29–34.
- Lessoway VA, Schulzer M, Wittmann BK, Gagnon FA, Wilson RD. Ultrasound fetal biometry charts for a North American Caucasian population. *J Clin Ultrasound* 1998; 26: 433–453.

SUPPORTING INFORMATION ON THE INTERNET

The following supporting information may be found in the online version of this article:

Tables S1–S10 MRI reference values according to gestational age (GA) in 589 fetuses for: bone biparietal diameter (in mm); cerebral biparietal diameter (in mm); bone fronto-occipital diameter (in mm); cerebral fronto-occipital diameter (in mm); transverse cerebellar diameter (in mm); anteroposterior diameter of the pons (in mm); vermian surface area (in mm); vermian height (in mm); length of the corpus callosum (in mm); anteroposterior diameter of the vermian (mm).

Appendix S1 Bland–Altman plots for the 10 chosen fetal cerebral magnetic resonance imaging parameters: bone and cerebral biparietal diameters (BPDs), bone and cerebral fronto-occipital diameters (FODs), transverse cerebellar diameter (TCD), anteroposterior diameter of the pons (APDP), vermian surface area (VS), vermian height (VH), length of the corpus callosum (LCC) and anteroposterior diameter of the vermian (APDV).

Appendix S2 Bland–Altman plots for comparison between pairs of fetal cerebral magnetic resonance imaging parameters: cerebral and bone biparietal (BPD) and transverse cerebellar (TCD) diameters, and right and left cerebral BPDs and atrial diameters (ADs).

Appendix S3 Equations for the 10 chosen fetal cerebral magnetic resonance imaging parameters: bone and cerebral biparietal diameters (BPDs), anteroposterior diameter of the pons (APDP), anteroposterior diameter of the vermian (APDV), bone and cerebral fronto-occipital diameters (FODs), transverse cerebellar diameter (TCD), vermian height (VH), length of the corpus callosum (LCC) and vermian surface area (VS).

Appendix S4 Distribution of Z-scores for the 10 chosen fetal cerebral magnetic resonance imaging parameters: cerebral and bone biparietal diameters (BPDs), anteroposterior diameter of the pons (APDP), anteroposterior diameter of the vermian (APDV), cerebral and bone fronto-occipital diameters (DFOs), transverse cerebellar diameter (TCD), vermian height (VH), length of the corpus callosum (LCC) and vermian surface area (VS).