



ISUOG Basic Training

Assessing the Placenta & Amniotic Fluid in Singleton & Twin Pregnancies

Learning objectives

At the end of this session, you will be able to:

- Recognise the differences in ultrasound appearance between placentas that are low lying & those which are not
- Describe how to distinguish between normal & abnormal amniotic fluid volumes in singleton and twin gestations

Key questions

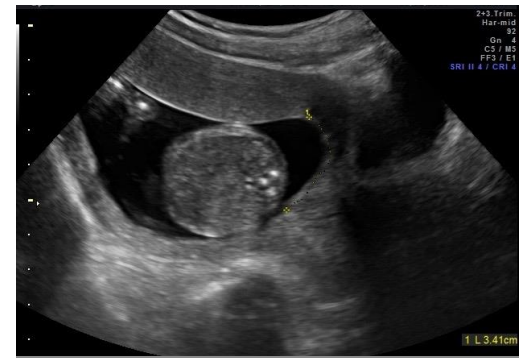1. What are the key features that should be included in the correct ultrasound assessment & reporting of placental site?
2. How should amniotic fluid be correctly assessed & reported?
3. What fetal conditions are most frequently associated with oligohydramnios?
4. What fetal conditions are most frequently associated with polyhydramnios?

Placenta

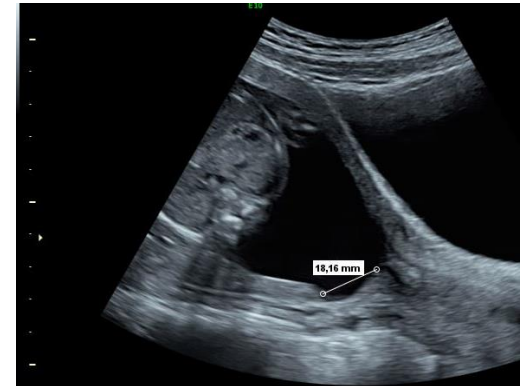- How to evaluate the placenta
- Placenta previa
- Morbidly Adherent placenta
- Placental Abruptio
- Placenta in twins

Placenta in the 2nd trimester

- Placental site
- Relationship of placenta to internal cervical os
- Distance from inferior edge of placenta to internal os, for assessment of potential *placenta previa*
- TV imaging preferable to TA



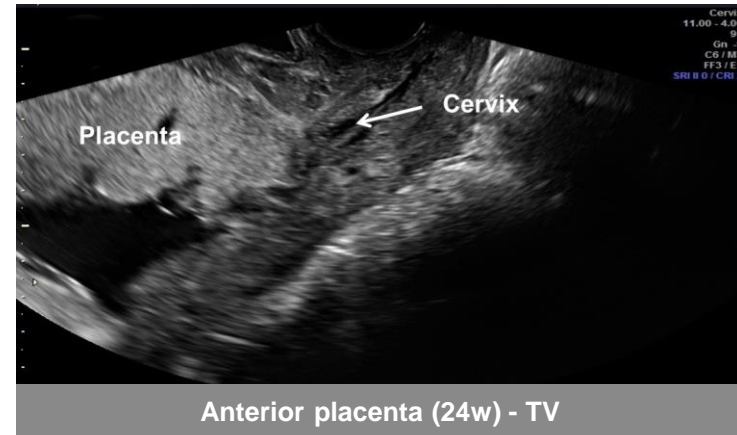
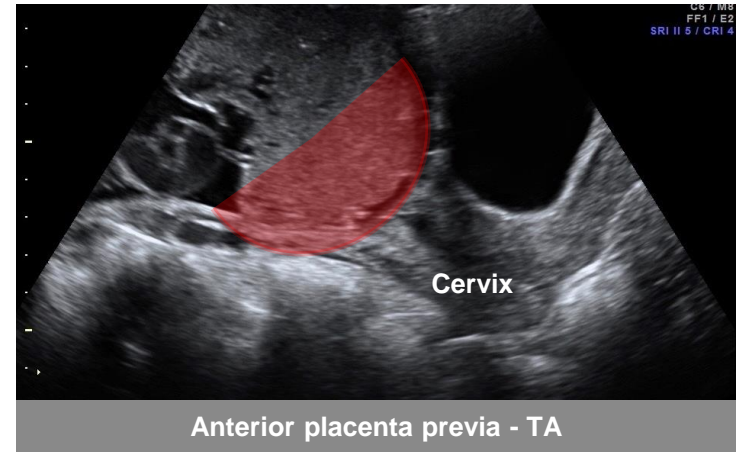
22w anterior placenta



22w posterior placenta

Placenta in the 2nd trimester

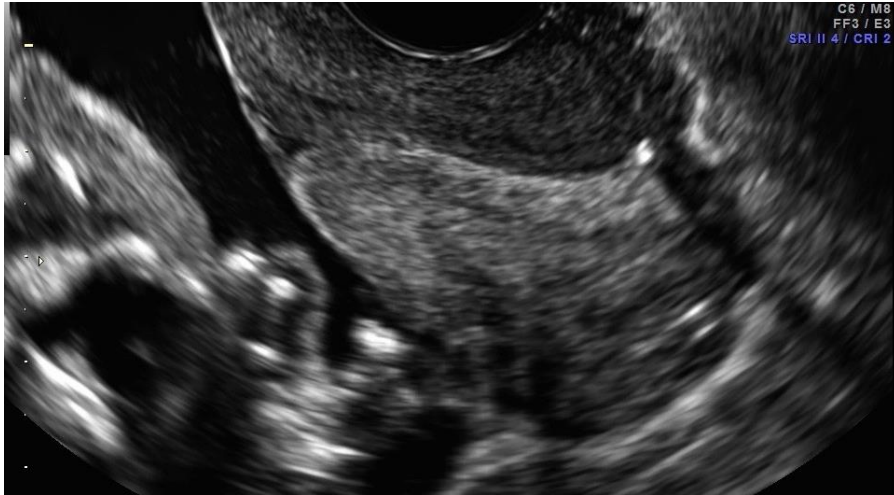
- Transabdominal ultrasound restricted by:
 - Need for full bladder
 - Maternal BMI or scars
 - Uterine contractures
- Transvaginal imaging preferable
- Safety is well established



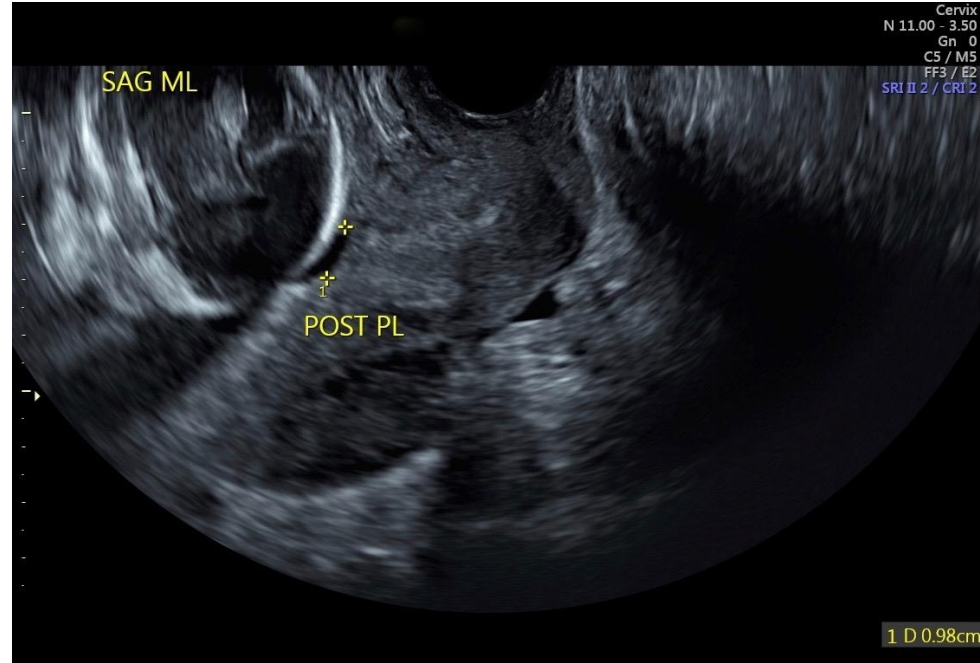
2nd trimester TV

Low lying

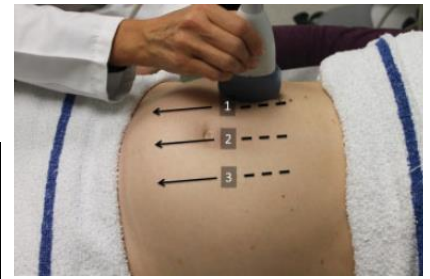
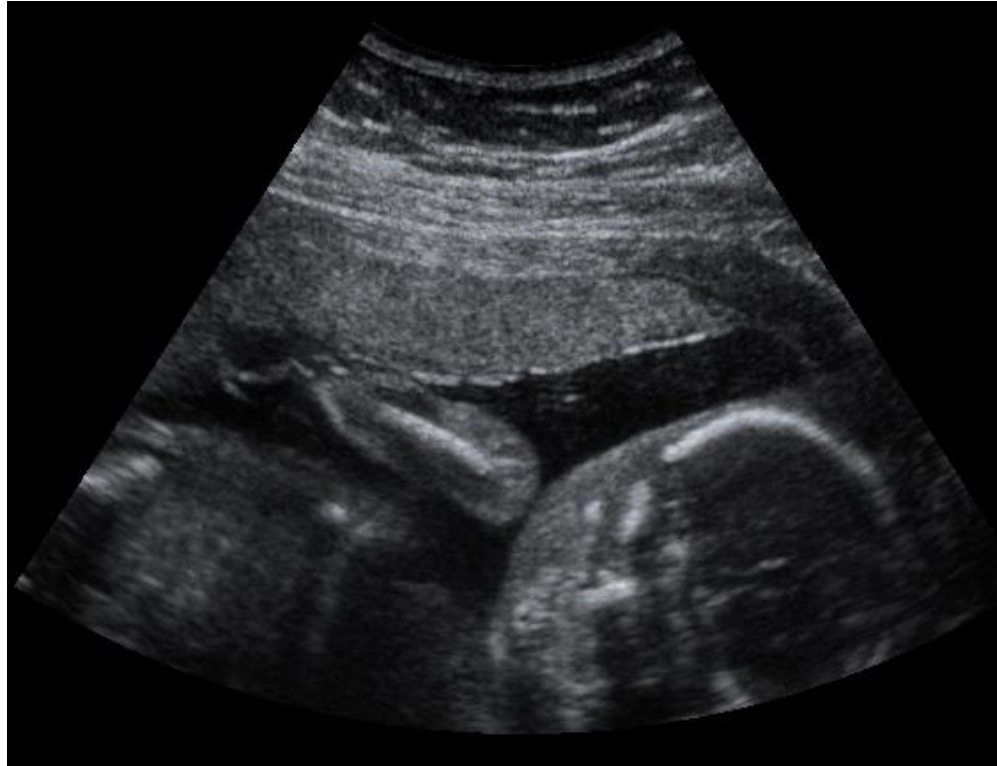Normal



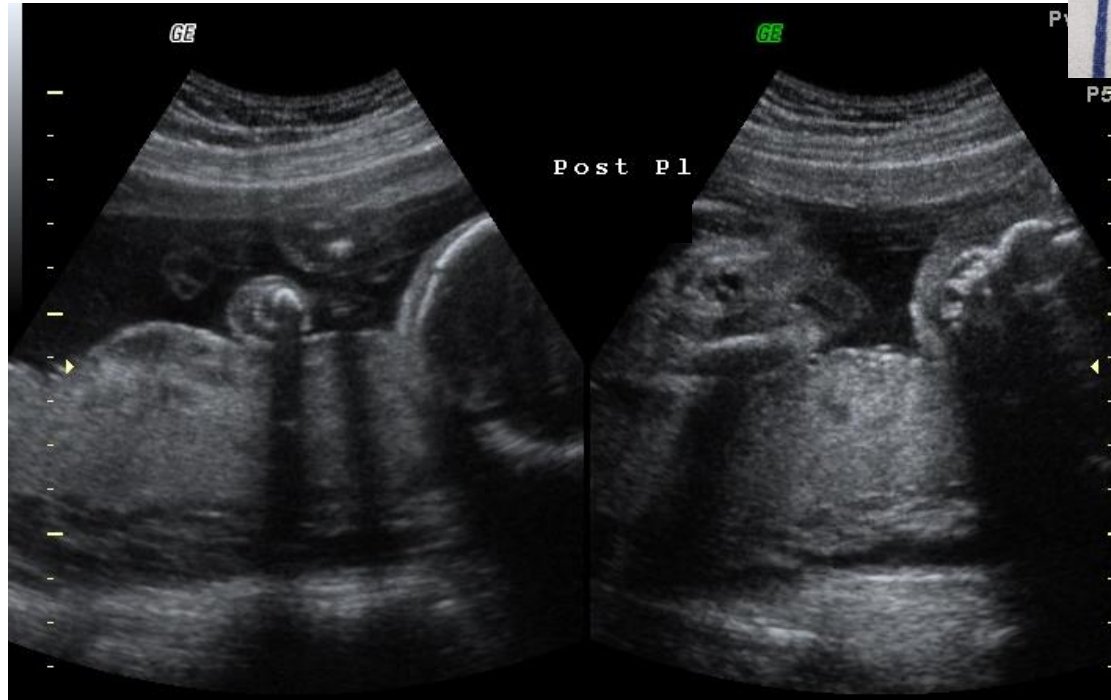
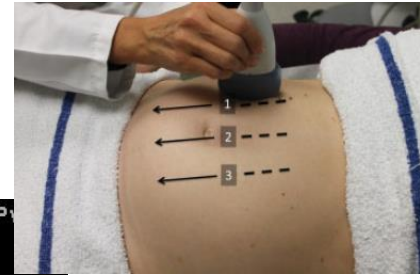
23 week singleton pregnancy



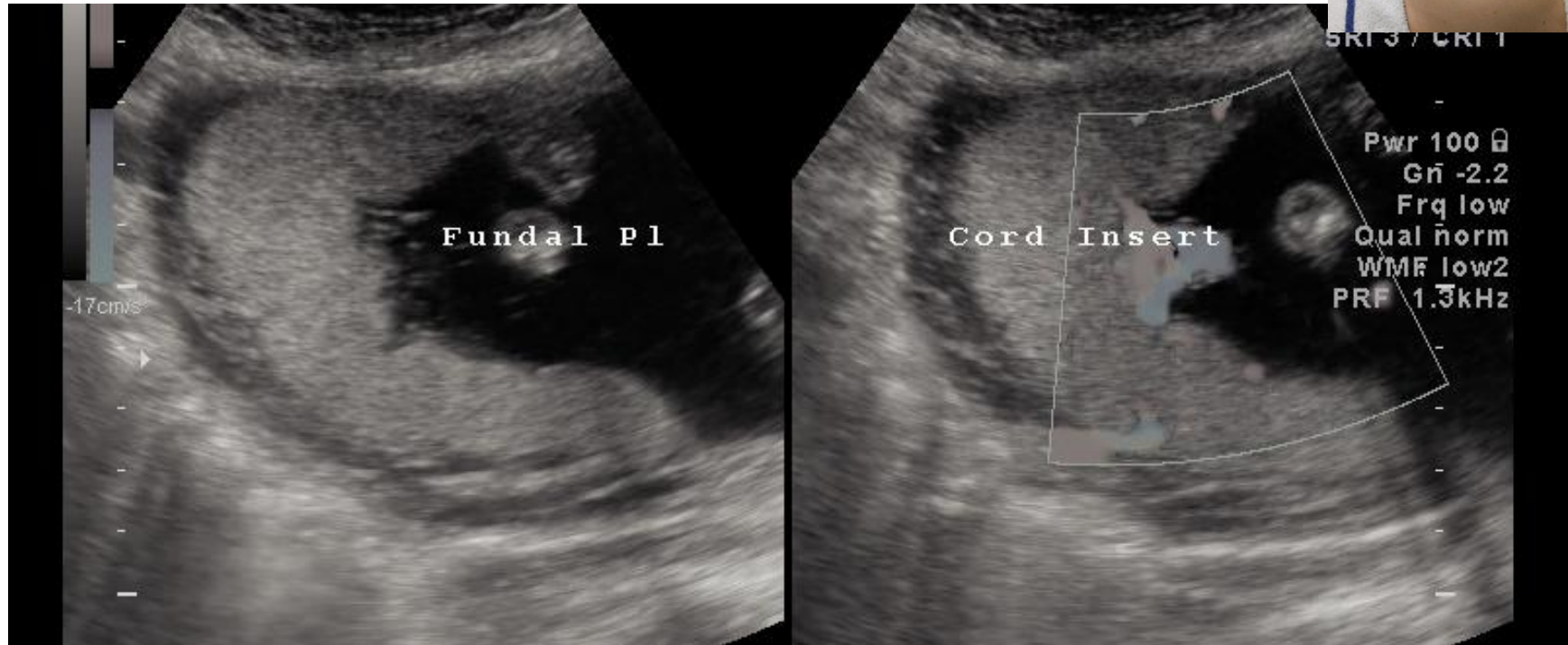
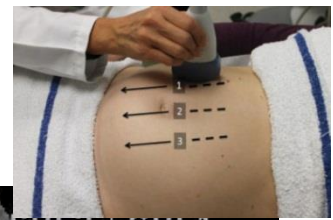
Anterior placenta



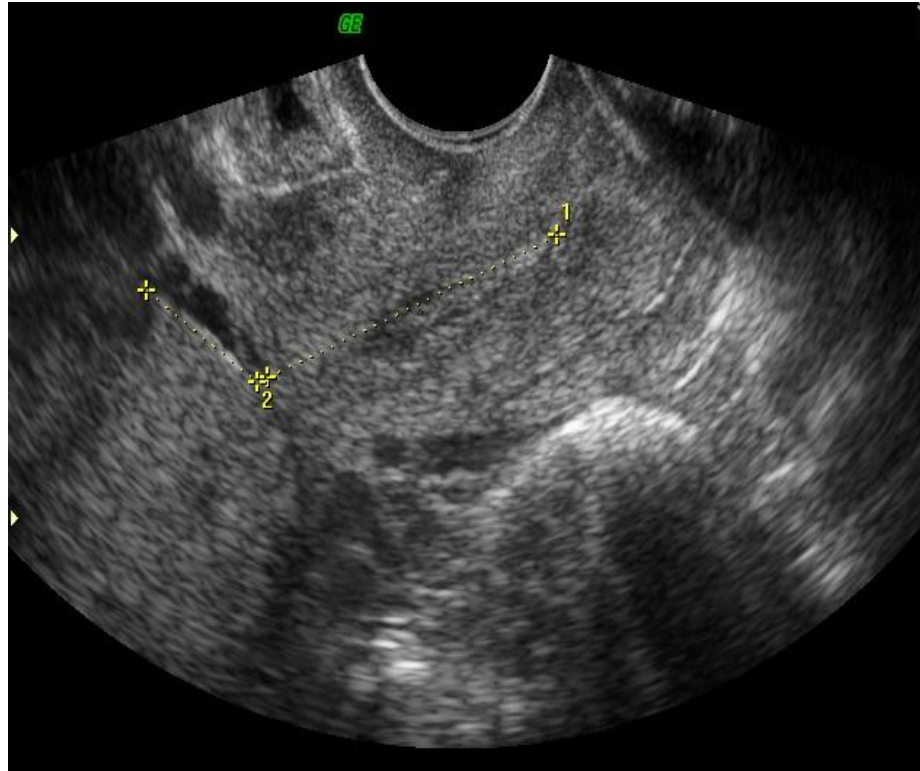
Posterior placenta



Fundal placenta



Placenta previa



Placenta previa

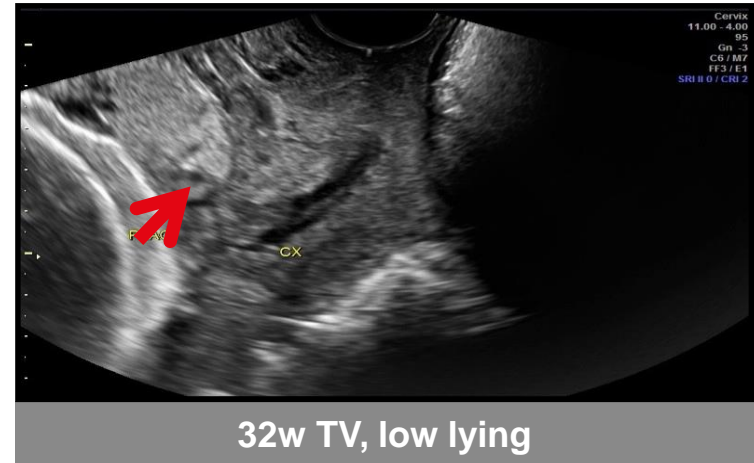
- Placenta covers part or all of the internal cervical os
- Incidence: 5/1,000 deliveries
- 2nd-3rd trimester painless vaginal bleeding, treat as previa until proven otherwise
- Clinical implications
 - Antepartum bleeding, transfusions
 - Hysterectomy
 - Sepsis
 - Maternal death
 - Prematurity, with 3-4 increase in perinatal mortality rate

Placenta previa

- Placental edge < 2 cm, or covering, internal os from 16 weeks
- Resolved with advancing gestation, “placental migration” from lower segment

Placenta relative to cervical os	Likelihood of resolution > 26 weeks
Covering os by >2cm	0
> 2 cm from os	100%
< 2 cm from os	89%

- 32 weeks TV, still present
- 36 weeks TV



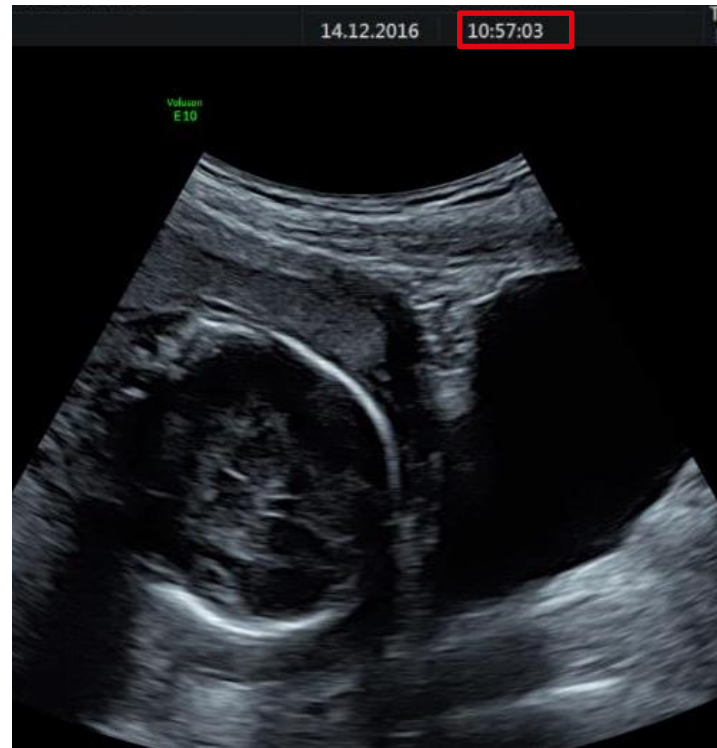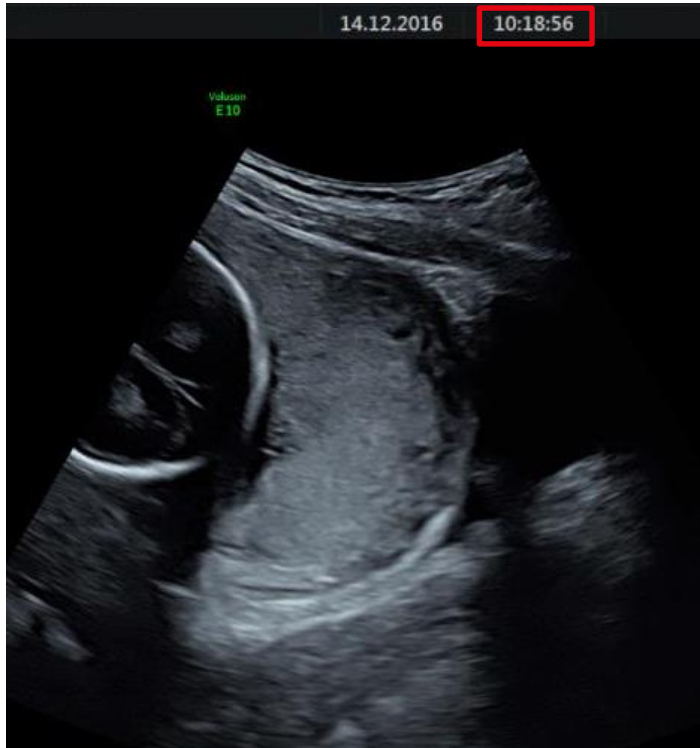
Oppenheimer L et al. UOG 2001,18:103-8

Risk factors for placenta previa

- History of prior Cesarean delivery
- Prior pregnancy termination
- Prior uterine surgery
- Maternal smoking
- Advanced maternal age
- Multiparity
- Cocaine use
- Multiple pregnancy

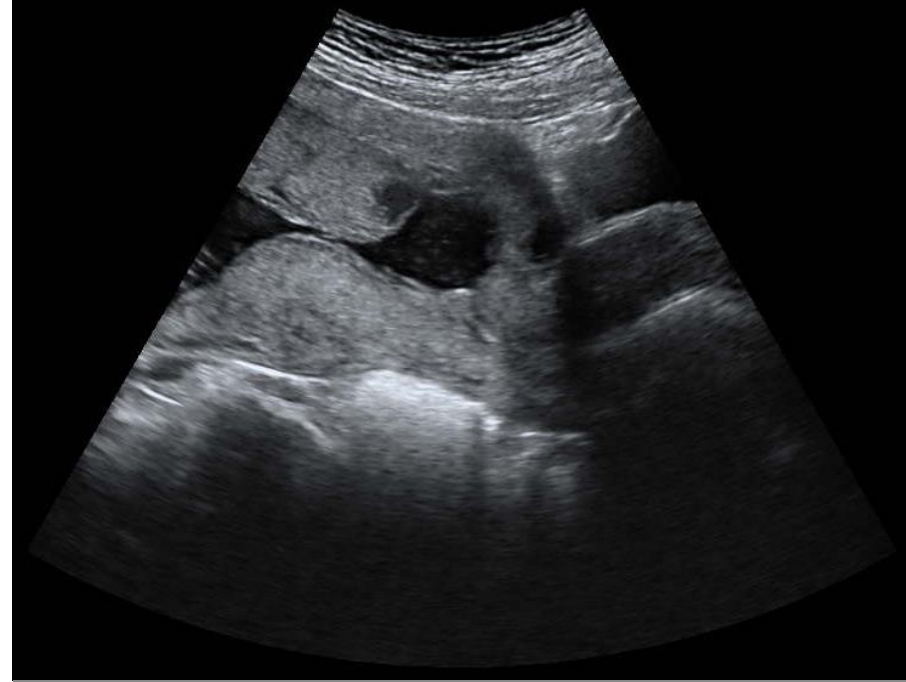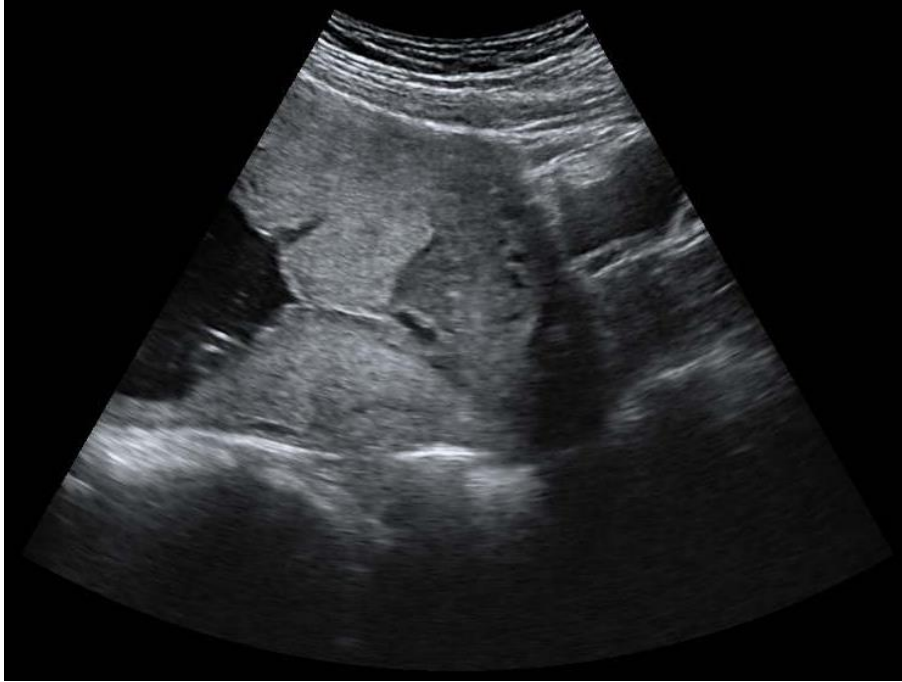Abuhamad et al. Ultrasound in Obstetrics & Gynecology: A Practical Approach, 2014

Pitfalls in diagnosing placenta previa



40 minutes later, note effect of maternal bladder filling

Pitfalls in diagnosing placenta previa



20 minutes later, note effect of uterine relaxation

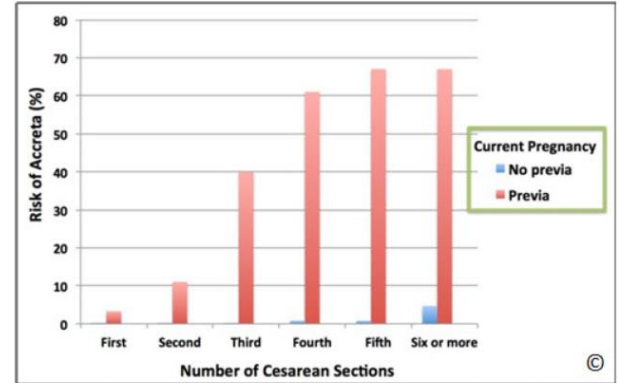
Morbidly adherent placenta

- Abnormal implantation of placenta into the uterine wall
 - Accreta: adherent to the myometrium (75%)
 - Increta: invades the myometrium (18%)
 - Percreta: through the myometrium (7%)
- Associated with massive haemorrhage, transfusion, hysterectomy, multi-system organ failure & maternal death

Prenatal diagnosis essential to optimise maternal-fetal outcomes

Risk factors for placenta accreta

- Placenta previa & prior Cesarean section
- Advanced maternal age
- Multiparity
- Uterine surgery or endometrial ablation
- Leiomyomas
- Uterine anomalies
- Hypertension
- Smoking

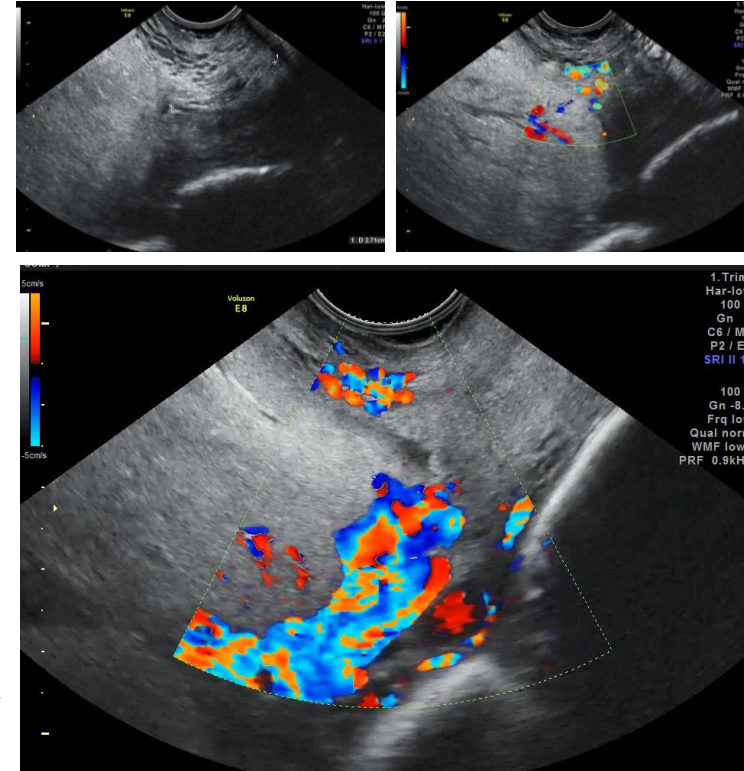


Graph 8.1: Risk for placenta accreta in pregnancies with and without a placenta previa and prior cesarean deliveries. Note that the risk of placenta accreta increases significantly as the number of prior cesarean deliveries increases in the presence of a placenta previa on ultrasound. When a placenta previa is not noted on ultrasound, the risk for placenta accreta remains small (< 1%), irrespective of the number of prior cesarean deliveries.

Abuhamad et al. *Ultrasound in Obstetrics & Gynecology: A Practical Approach*, 2014
Placental Abnormalities, *Ultrasound in OB/GYN Practical Guide*, 2014
Silver RM et al. *Obstet Gynecol.* 2006,107:1226-32

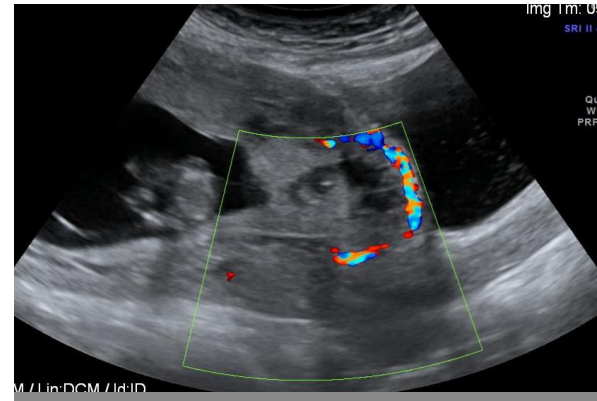
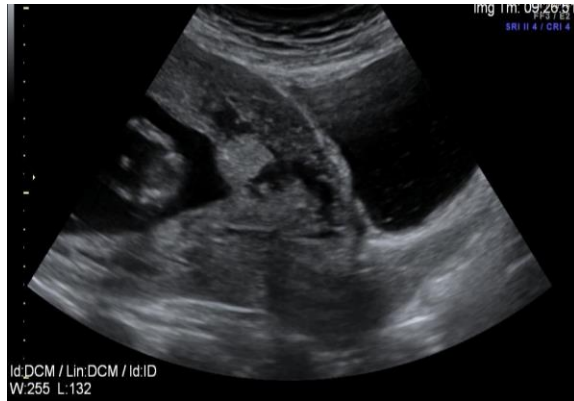Ultrasound findings in placenta accreta

- Gestation sac implanted:
 - In lower uterine segment
 - In cesarean section scar
- Multiple vascular lacunae in 2nd & 3rd trimesters
- Loss of normal hypoechoic retroplacental zone
- Abnormality in uterine-serosa-bladder interface
- Retroplacental myometrial thickness of < 1 mm
- Turbulent blood flow with colour Doppler through lacunae
- Extension villi into myometrium, serosa or bladder

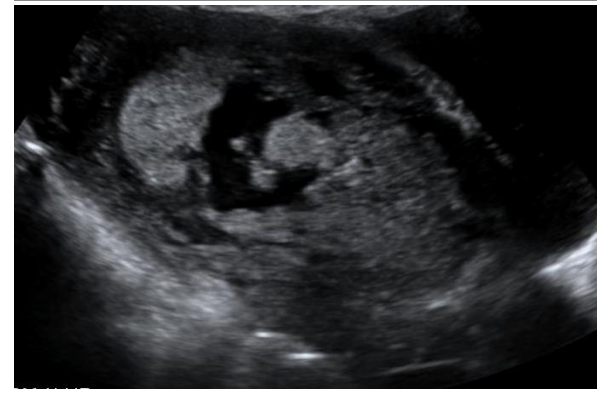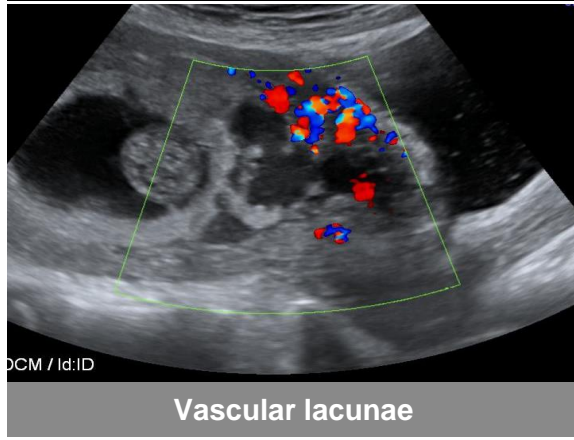


Abuhamad et al. Ultrasound in Obstetrics & Gynecology: A Practical Approach, 2014

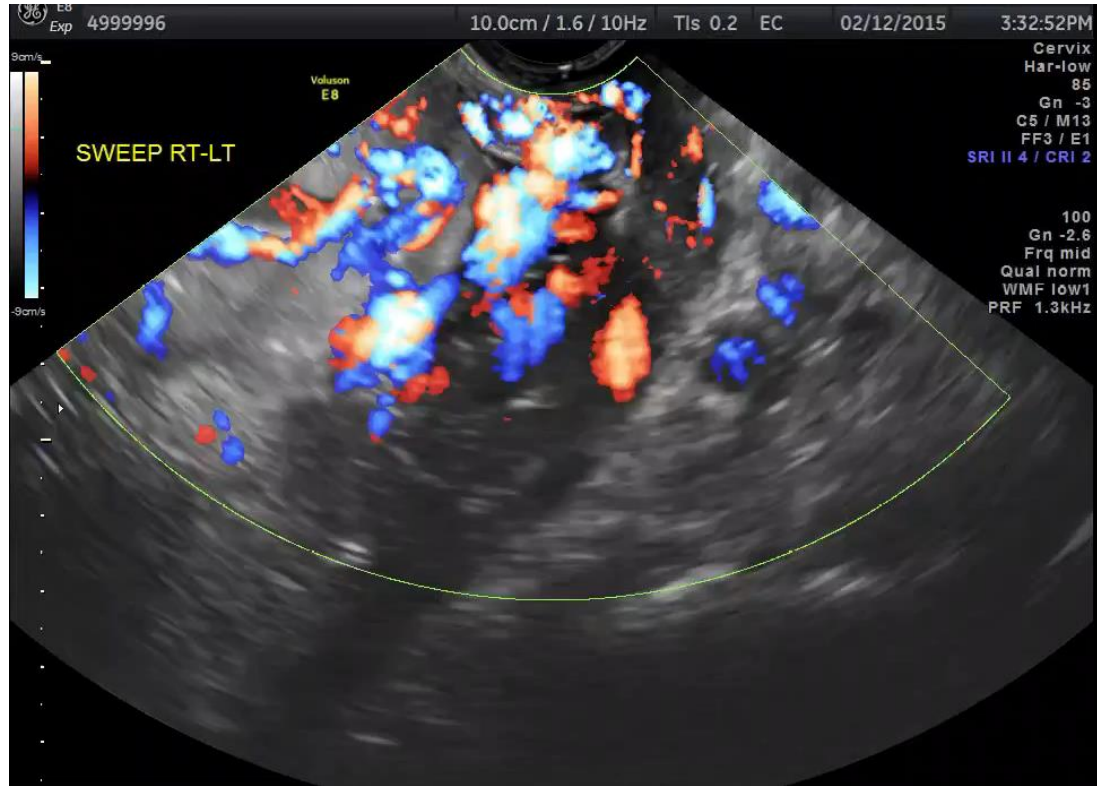
Ultrasound findings in placenta accreta



Loss of hypoechoic retroplacental zone



Placenta accreta 2nd & 3rd trimester TV



US identification of invasive placentation*

Diagnostic Method	Sensitivity	Specificity
Overall	91%	97%
Placental lacunae	77%	95%
Loss of hypoechoic space	66%	96%
Abnormal uterine bladder interface	50%	99%
Colour Doppler abnormal	91%	88%

* At risk population: history of uterine surgery with placenta previa or low lying

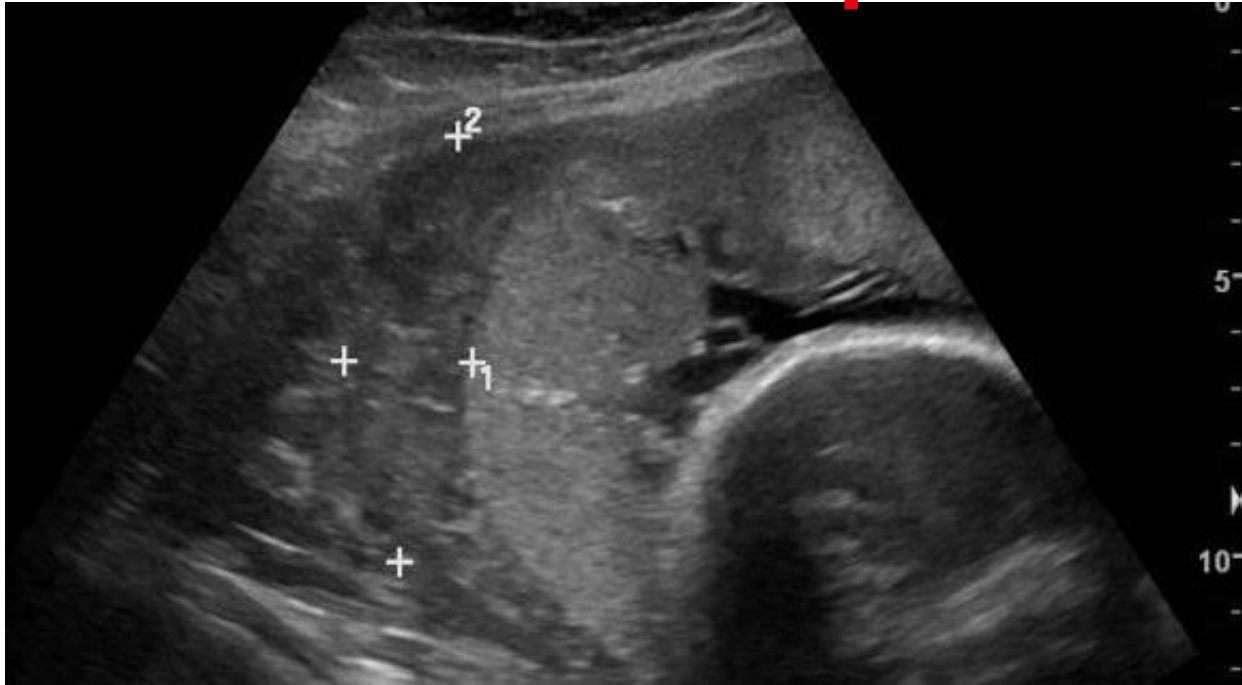D'Antonio F, et al. UOG, 2013, 42:509-17

Placenta abruptio

- Bleeding behind or within the placenta
 - Painful uterine or lower back
 - With contractions
- Incidence 0.5-1%
- Hypoechoic subchorionic thickening
- Ultrasound detection rate - 50%
 - Normal ultrasound does not rule out an abruptio

Placental separation with active bleeding - materno-fetal emergency, immediate triage required

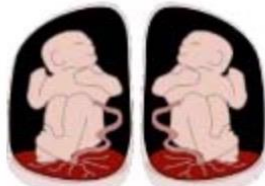Placental abruption



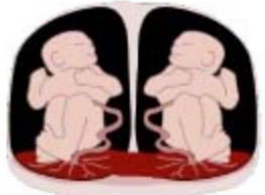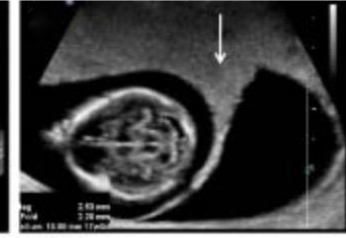
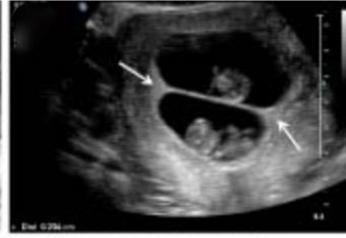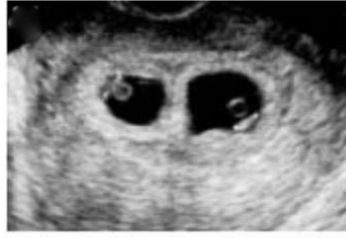Crescent of avascular, low echogenicity between placenta and uterine wall

Case courtesy of Dr Andrew Dixon, Radiopaedia.org, RID: 14281

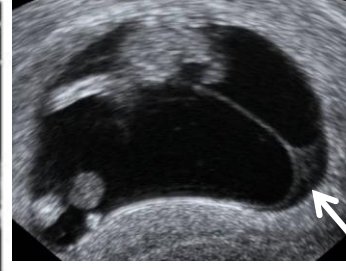
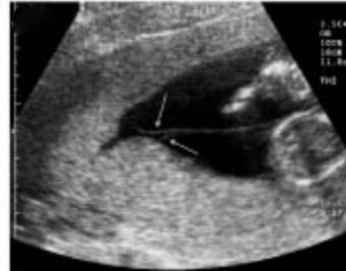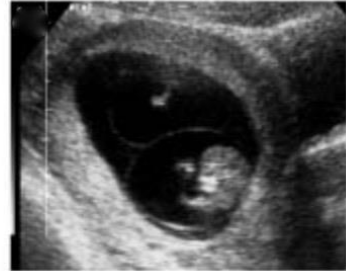
Twins: amnionicity & chorionicity



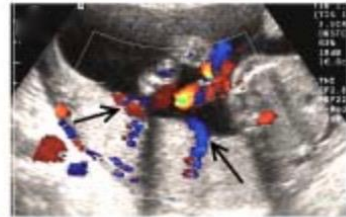Diamniotic-Dichorionic



Diamniotic-Monochorionic



Monoamniotic-Monochorionic



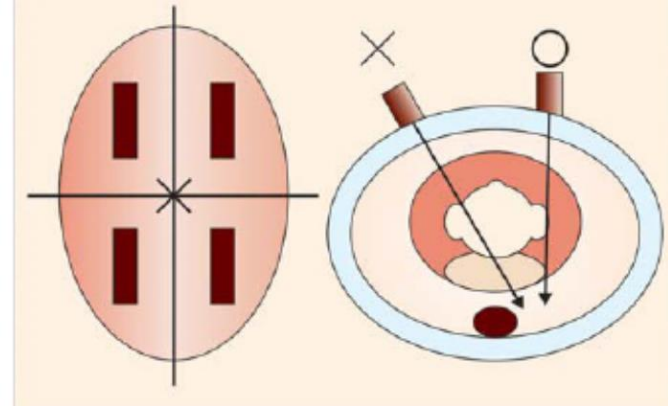
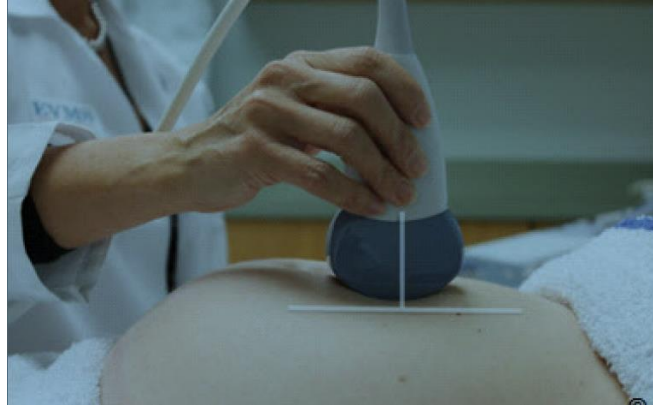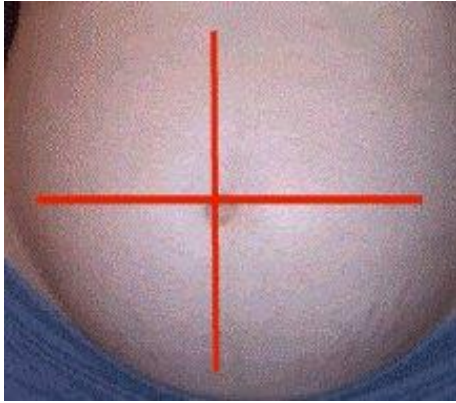
Amniotic fluid

- How to evaluate
- Polyhydramnios
- Oligohydramnios
- Twins

Amniotic fluid volume (AFV)

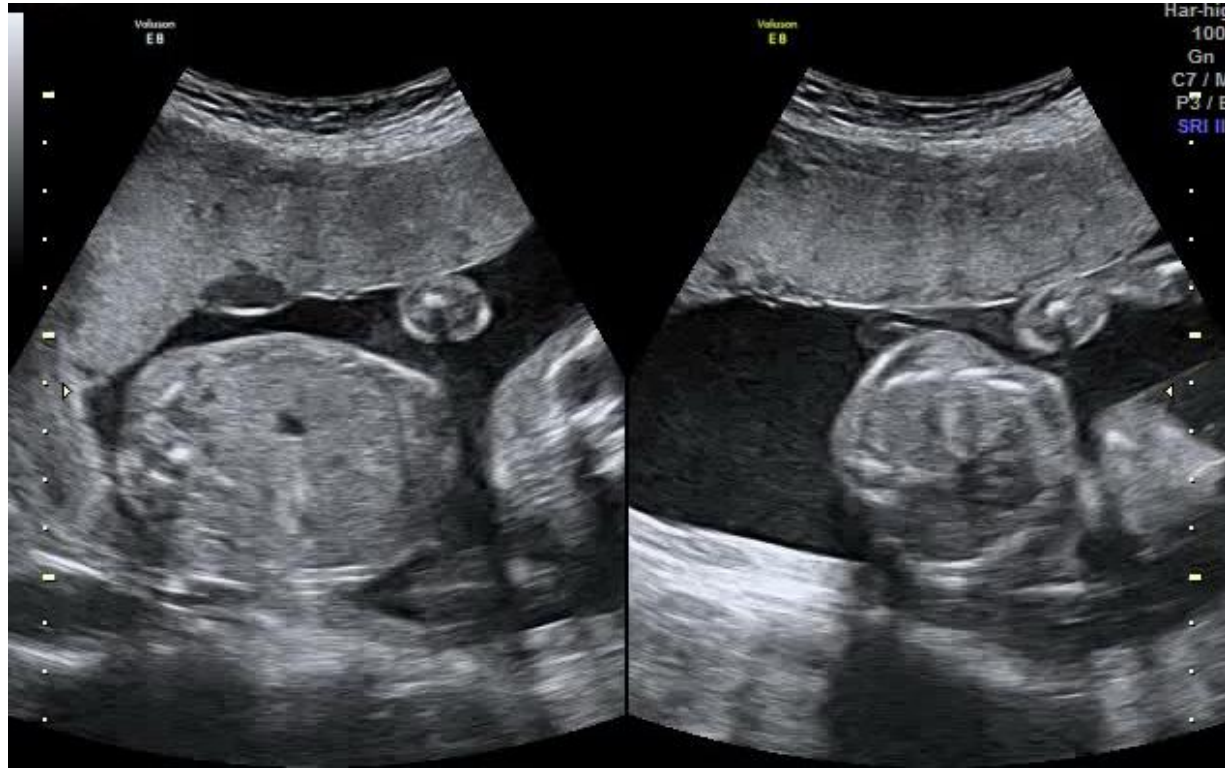
- 1st trimester
 - Production poorly understood
 - Multiple sources (maternal: placenta and membranes)
- 2nd & 3rd trimesters
 - Fetal urine major contributor, from 16 weeks' onwards (and lungs)
 - Assessment of AFV = assessment of fetal well being
- Abnormal amniotic fluid volume
 - Increased – polyhydramnios
 - Decreased – oligohydramnios
 - No fluid - anhydramnios

Measuring amniotic fluid



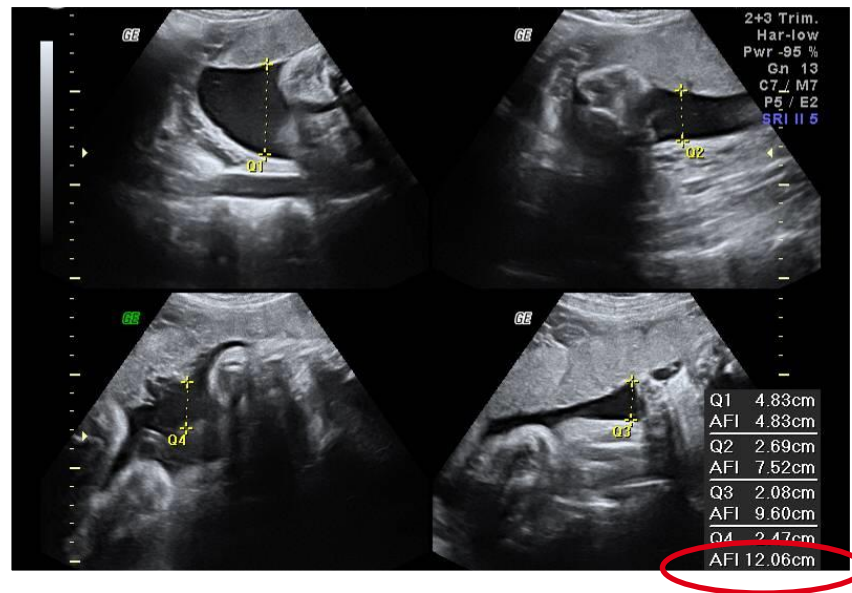
- Measurement of a pocket of amniotic fluid perpendicular to the floor

Technique: minimise pressure



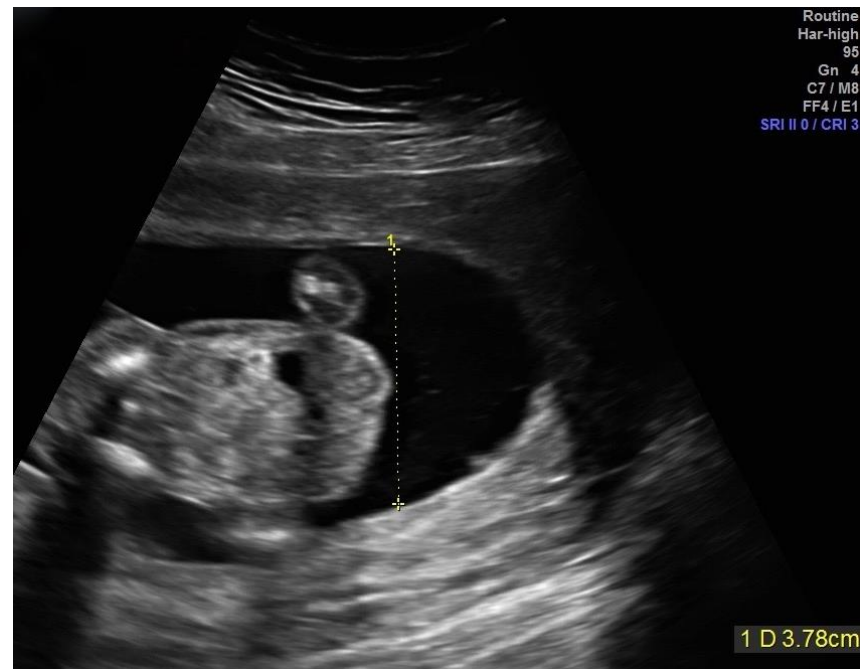Amniotic fluid index (AFI)

- Sum of deepest vertical pocket from 4 quadrants
- Measure > 16 weeks
- Normal AFI = 5 - 24 cm
- Oligohydramnios < 5 cm
- Polyhydramnios > 24 cm



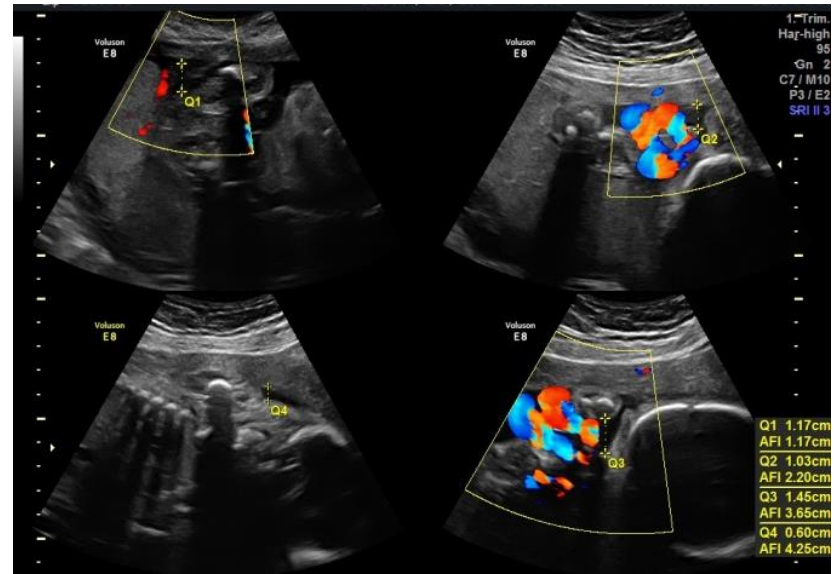
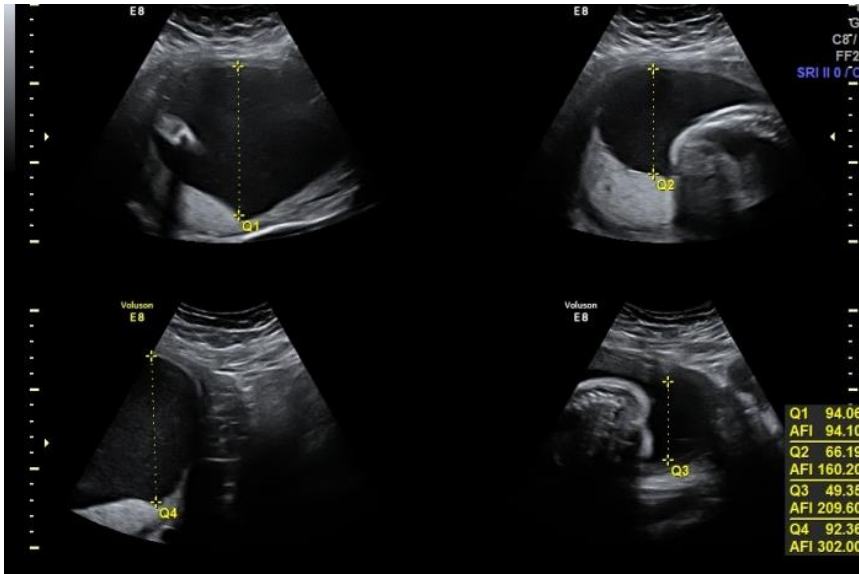
Deepest vertical pocket (DVP)

- Measure DVP in any quadrant of the uterus
 - Normal 2 - 8 cm
 - Oligohydramnios < 2 cm
 - Polyhydramnios > 8 cm
- DVP - diagnosis of oligohydramnios → fewer obstetrical interventions (with no difference in outcome) when compared to AFI



Moise KJ, Seminars Perinatology 2013;37:370-74

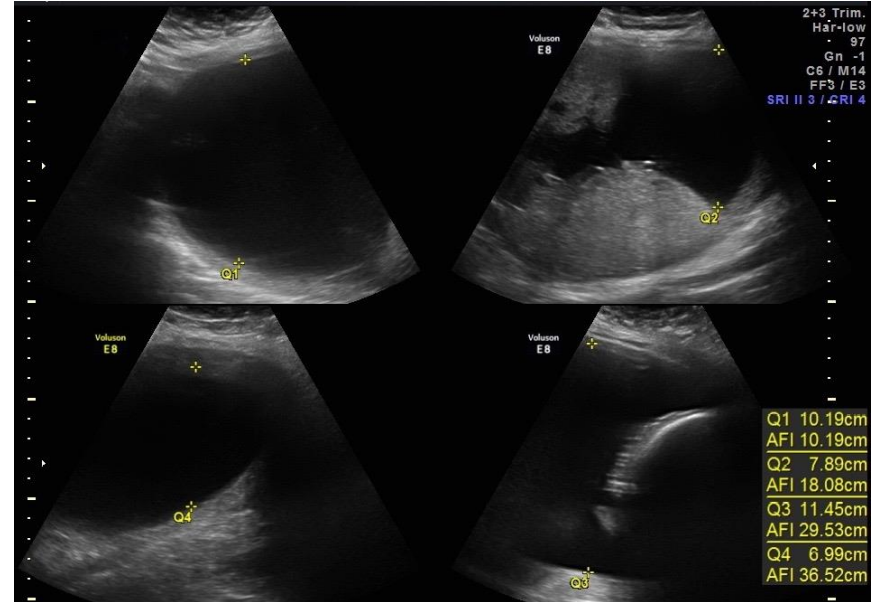
	Polyhydramnios	Oligohydramnios
DVP	≥ 8 cm	<2 cm
AFI	≥ 24 cm	<5 cm



Polyhydramnios

- Idiopathic
- Maternal diabetes
- Fetal
 - Anemia
 - Structural malformations
 - Chromosomal abnormal
 - Infections
 - Genetic syndromes
 - Complicated twins
- Increased incidence of preterm labor & delivery; abruption

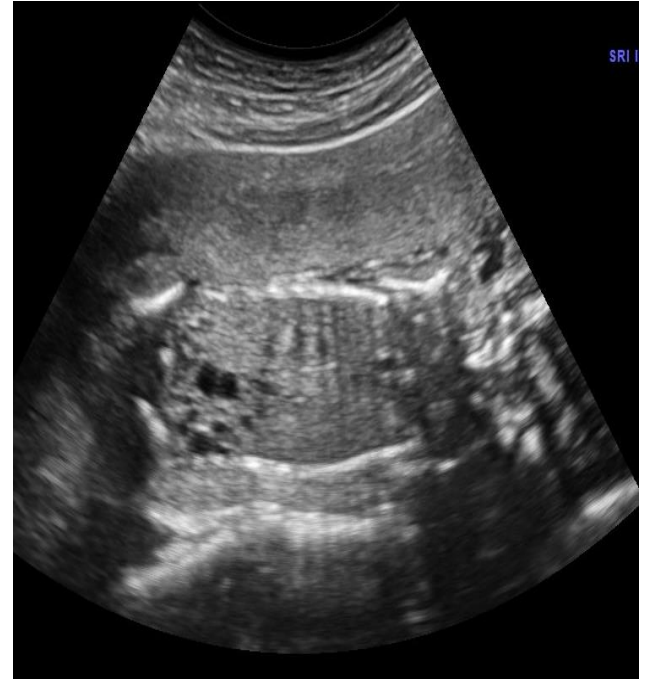
2-5 fold ↑ perinatal mortality



Oligohydramnios

- PROM - most common reason
- Fetal condition
 - Bladder obstruction
 - Renal failure
- Placental insufficiency - IUGR
- Maternal disorders
 - Hypertension
 - Renal disease
- Multiple pregnancy
 - Twin-twin transfusion syndrome
 - Selective fetal growth restriction
- Other
 - Maternal medication ingestion and substance abuse
 - Infections
- Increased Incidence of
 - Potter Cascade/deformations
 - Fetal heart rate abnormalities
 - Meconium stained fluid

15-50 fold ↑perinatal morbidity & mortality



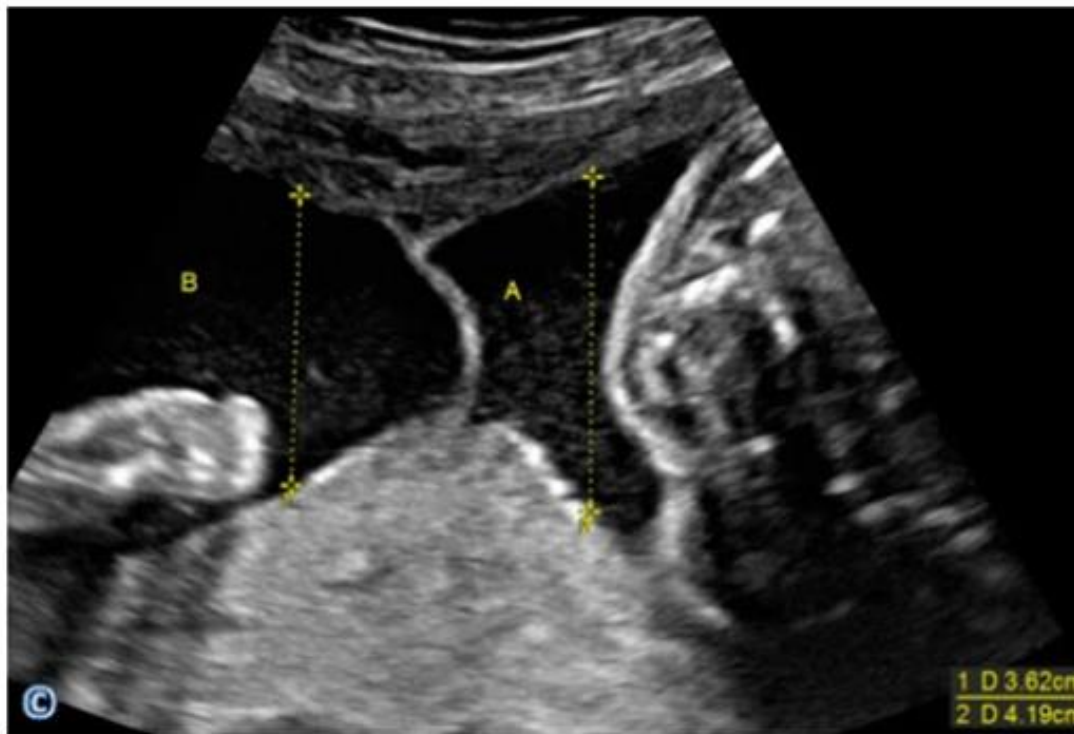
Keep in mind

- Measure AFI with the transduce held sagittally and perpendicular to the floor
- In case of suspected polyhydramnios, measure all 4 vertical fluid pockets
- In case of oligohydramnios, measure the single deepest vertical pocket
- Look for maternal disease/fetal structural abnormalities with abnormal AFI
- Follow progression closely by ultrasound

Amniotic fluid assessment in twins

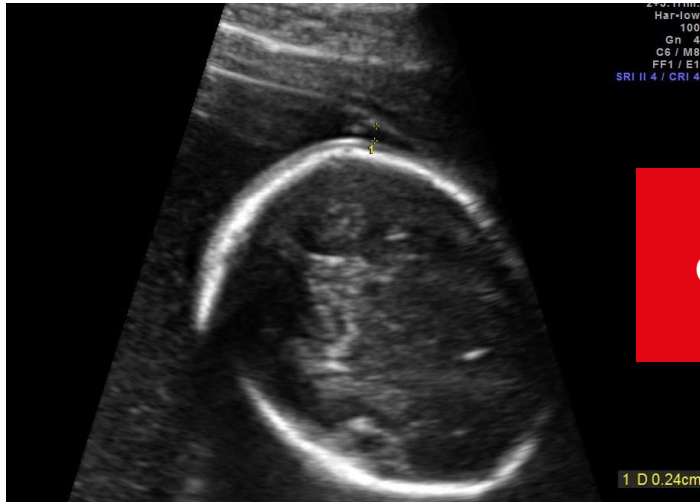- Use DVP not AFI
- DVP
 - AFV stable in normal Monochorionic (MC) & Dichorionic (DC) twins between 17 & 37 weeks
 - Definitions for oligohydramnios & polyhydramnios for twins same as for singletons
- Dichorionic etiologies comparable to those of singletons
- Monochorionic
 - Twin to twin transfusion syndrome (oligo/poly)
 - Selective fetal growth restriction (oligo/normal)

Amniotic fluid assessment in twins



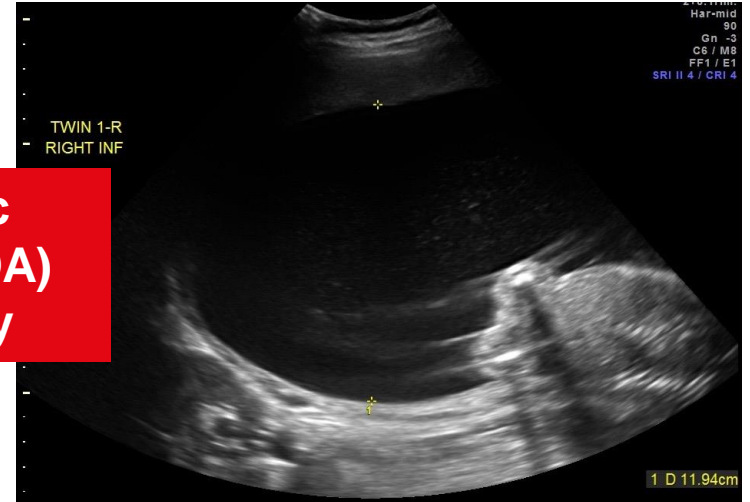
Abuhamad et al. Ultrasound in Obstetrics & Gynecology: A Practical Approach, 2014

Amniotic fluid assessment in twins



Twin 2 – DVP 2.4mm

**Monochorionic
diamniotic (MCDA)
twin pregnancy**



Twin 1 – DVP 11.9cm
(polyhydramnios)

Diagnosis - twin to twin transfusion syndrome

Key points

1. A placental edge < 2 cm from the internal os should be considered an “at risk pregnancy”, additional ultrasound scans are required
2. Vaginal bleeding with ultrasound evidence of placental separation is an obstetric *emergency*
3. Placenta accreta should be excluded in all cases of low anterior placenta with previous Cesarean section

Key points

4. Normal amniotic fluid volume:
 - AFI = 5 – 24 cm
 - DVP = 2 – 8 cm
5. DVP, not AFI, should be used in assessment of amniotic fluid volume in twin pregnancies
5. Polyhydramnios is associate with increased risk of poor outcome due to preterm delivery



ISUOG Basic Training by **ISUOG** is licensed under a **Creative Commons Attribution-NonCommercial-NoDerivatives 4.0 International License**.

Based on a work at **<https://www.isuog.org/education/basic-training.html>**.

Permissions beyond the scope of this license may be available at **<https://www.isuog.org/>**